

**ADDIS ABABA UNIVERSITY
COLLEGE OF HEALTH SCIENCES
SCHOOL OF GRADUATE STUDIES
DEPARTMENT OF RADIOLOGY**



Neonatal Hypoxic Ischemic encephalopathy; Late Magnetic Resonance Imaging findings correlated with clinical findings, at Yehuleshet Specialty Clinic, Addis Ababa, Ethiopia.

Principal investigator: Ilili Amin, MD, Radiologist, Neuroradiology Fellow

Advisors: Tequam Debebe, MD, Consultant Neuroradiologist

Amal Saleh, MD Consultant Neuroradiologist

Abebe Mekonen, MD Consultant Neuroradiologist

Amal Saleh, MD Consultant Neuroradiologist

Tewodros Endale, MD, consultant Neuroradiologist

A Senior Paper to be submitted to AAUCHS Radiology Department, Neuroradiology Unit, for partial fulfillment of the requirements for the post graduate Sub-Specialty study in Neuroradiology.

**ADDIS ABABA UNIVERSITY COLLEGE OF HEALTH AND MEDICAL SCIENCES
DEPARTMENT OF RADIOLOGY**

**Hypoxic Ischemic encephalopathy; Late Magnetic Resonance Imaging findings correlated
with clinical findings, at Yehuleshet specialty clinic, December 2023, Addis Ababa,
Ethiopia.**

**A senior paper to be submitted to AAU College of health sciences, Radiology Department,
Neuroradiology Subspecialty Fellowship Training for partial fulfillment of the
requirements for the post graduate Subspecialty study in Neuroradiology**

Primary investigator

Ilili Amin, MD, Radiologist, Neuroradiology Fellow

Email: ruqanaliye@gmail.com

Advisors

Tequam Debebe, MD, Consultant Neuroradiologist

Email: tequamrad2018@gmail.com

Amal Saleh, MD Consultant Neuroradiologist

Email: salehamal12@gmail.com

Abebe Mekonen, MD Consultant Neuroradiologist

Email: yotam2004@yahoo.com,

Tewdros Endale, MD, consultant Neuroradiologist

Email: teddy.endale7@gmail.com

December, 2023

Addis Ababa, Ethiopia

Contents

Tables And Figures	v
Acronyms and operational definition	vi

Acknowledgment	vii
Abstract.....	viii
Introduction	1
Background	1
Statement of the problem	1
Significance of the study.....	2
Literature Review	3
MRI imaging pattern in perinatal asphyxia.....	3
Objectives	5
General Objective	5
Specific objectives	5
Methods and materials.....	6
Study Area	6
Study Tool	6
Study Period.....	6
Study Design:.....	6
Source population	6
Inclusion criteria	6
Exclusion criteria	6
Sample size and Technique.....	6
Measures	7
Dependent variable	7
Independent variables	7
Operational Definitions.....	7
Data collection and procedures	7
Data Quality control, processing and Analysis	7
Dissemination of the results.....	8
Ethical consideration.....	8
Result	9
Discussion.....	14
Limitation	17
Conclusion.....	18
Recommendation.....	19

References	20
Annexes.....	24
Data Collection Tool.....	24

Tables And Figures

Table 1 Gestational age and 5th minute Apgar score.....	9
Table 2 Antenatal and Perinatal Risk factors	9
Table 3 MRI findings with distribution and comparison of antenatal and perinatal risk factors of HIE among pediatric patients having history of perinatal asphyxia.....	10
Table 4 Association between gestational age and MRI finding patterns among infants with abnormal MRI findings, Total cases having abnormal MRI findings 53 (Fisher Exact test).	11
Table 5 Distribution pattern of MRI findings in preterm, full-term, and post-term infants, among children with abnormal MRI findings n=53.....	12
Table 6: Part1- Socio-demographic and Part2-Clinical Data	24
Table 7: Part 3: MRI findings.....	25

Acronyms and operational definition

AAU=Addis Ababa University

PA- Perinatal Asphyxia

SPSS=Statistical Package for Social Sciences

MRI= Magnetic Resonance Imaging

CT= computed tomography

USG= ultrasonography

PVL= Periventricular Leukomalacia

DWI= diffusion-weighted imaging

FLAIR= Fluid attenuated inversion recovery

WHO= World Health Organization

HIE= hypoxic ischemic encephalopathy

MCE= multicystic encephalomalacia

Acknowledgment

I would like to forward my appreciation to the department of Radiology, CHS, and Addis Ababa University for allowing me to undertake this research.

I would like to express my deepest gratitude to my advisors for their invaluable and constructive comments during the development of this paper. I would like to thank all the staffs working at Neurology Unit of Yehuleshet Specialized clinic.

Abstract

Introduction: Neonatal Hypoxic Ischemic Encephalopathy is a brain injury that occurs when oxygen or blood flow to the brain is reduced or stopped before, during, or shortly after birth. Birth asphyxia is the main contributor to both long-term neurodevelopmental problems and infant mortality in low- and middle-income nations. MRI examination can assist in elucidating the type of injury, the timing of injury, the pattern of pathological evolution, and changes in brain metabolism over time.

Objectives: To explore the late Brain MRI patterns and associated clinical findings of children who had clinical diagnosis of perinatal asphyxia in Addis Ababa, Ethiopia.

Methodology: The study is conducted in pediatric neurology clinic with MRI facility in Addis Ababa, Ethiopia. A total of 797 pediatric patient's charts were identified who had Brain MRI imaging evaluation. Of these, 70 cases with clinical diagnosis of perinatal asphyxia were included. Using a structured questioner, demographic data, pre and perinatal history of patients was collected. The MRI reports were reviewed by the principal investigator in a systematic pattern.

Result: The age at time of MRI evaluation ranges from 2 months to 14 years. Gestational age was assessed of which 74.3% are term and 25.7% are preterm. 42.9% of our patients received antenatal care (ANC) during gestation and 55.7% were delivered at a healthcare facility Global Developmental Delay (GDD), observed in 61.4% of the cases followed by Seizures occurring in 21.4% of patients. 62.5% of preterm infants had periventricular leukomalacia on MRI as compared with those full-term (10.8%) infants, (P-value<0.001). And, (64.9%) of term infants had Subcortical/ deep watershed border zone hyperintensities on MRI as compared to with preterm (12.5%) infants. MRI findings suggestive of chronic injury, thinning of corpus callosum and cerebral cortical atrophy were seen 31.35 & 40% and 31.3% 37.3% respectively in preterm and term infants.

Conclusion: The study reveals high magnitude of perinatal asphyxia (8.8%) among pediatric Neurology clinic visits. Brain MRI imaging showed abnormality in majority of cases with specific dominant patterns seen being periventricular leukomalacia and subcortical/deep watershed hyperintensities for preterm and term infants respectively indicating that brain MRI should be used as primary diagnostic work up for these patients.

Key words: *MRI pattern, Prenatal asphyxia, Neonatal HIE, Global Developmental Delay, Addis Ababa, Ethiopia*

Introduction

Background

Neonatal Hypoxic Ischemic Encephalopathy is a brain injury that occurs when oxygen or blood flow to the brain is reduced or stopped before, during, or shortly after birth, according to the National Institute of Neurological Disorders and Stroke (NINDS).(1) Hypoxic Ischemic Encephalopathy occurs when the fetus does not receive enough oxygen due to impaired blood flow to the brain, typically during labor and delivery.(2) This increases the risk of death (stillbirth or neonatal death) or permanent disability in the newborn, and it can also be predicted that cognitive difficulties will arise due to the pattern of brain injury associated with neonatal encephalopathy.(3,4)

Birth asphyxia is the main contributor to both long-term neurodevelopmental problems and infant mortality in low- and middle-income nations. (5) The primary cause of newborn mortality in East Africa in 2015 (31.6%) was birth asphyxia; the region's neonatal mortality rate varies from 11 to 102 per 1000 live births. (6) In Ethiopia, birth asphyxia ranks as the second leading cause of neonatal mortality (26.7%) and the fourth most common cause of death for children under five (11.3%). (7)

Neither an ultrasound nor a CT scan can demonstrate the specific HIE neuropathology(8). The recommended first line imaging for HIE is MRI(8,9).The most popular methods for diagnosing and assessing HIE are MRI routine scan sequences, MRI-diffusion weighted imaging (DWI), and magnetic resonance spectroscopy (MRS), which offer comprehensive data on damage, development, and brain metabolism(8). A thoughtful choice of MRI examination can assist in elucidating the type of injury, the timing of injury, the pattern of pathological evolution, and changes in brain metabolism over time. It can also help to direct HIE treatment and objectively assess the prognosis(10–12).

Perinatal Hypoxic ischemic injury patterns differ among term and preterm infants and also depends on duration and severity of insults(13). The four patterns of MRI findings associated with HIE are: the mixed pattern, the widespread injury of the entire brain, the watershed prominent pattern affecting the white matter in the centrum semi ovale and subcortical zones, and the pattern involving the posterior limb, thalamus, and basal ganglia of the internal capsule (14). In appropriate clinical setting with no arterial territorial pattern, atypical imaging patterns of unequal injury of unilateral, bilateral but asymmetric involvement of either deep gray nuclei or watershed infarct involving the cortex or subcortical white matter can occur(13). By assessing the extent and severity of the prenatal damage, estimating the prognosis, and formulating treatment plans, MRI plays a crucial role in the early diagnosis of fetal asphyxia and the diagnosis of accompanying sequelae.

Statement of the problem

Perinatal hypoxia is a critical condition that has the potential to result in neurological damage in neonates. MRI imaging is a powerful tool for detecting brain injury in children who have

experienced perinatal asphyxia(15). However, there is limited research on MRI findings pattern, common sites of brain injury that emerge in children who have experienced asphyxia(16).

Neonatal HIE can have well known, predictable MRI imaging patterns as well as atypical Brain involvement which this study aims to investigate and raise a possibility of neonatal HIE in children presented with neurologic disorder, typical underlying risk factor and clinical diagnosis of perinatal asphyxia. Retrospective Study was done by reviewing reports of Brain MRI scans of children who have experienced perinatal asphyxia. The imaging patterns were analyzed, and clinical presentations were reviewed.

The problem we aim to address is that there is limited research on the MRI imaging patterns that emerge in children who have experienced perinatal asphyxia. Furthermore, there is a notable scarcity of comprehensive data regarding the MRI imaging patterns subsequent to perinatal asphyxia and the factors linked to it, both in Ethiopia as a whole and particularly within the specific study environment.

Significance of the study

The purpose of this study is to assess the burden of perinatal asphyxia among pediatric patients in Specialty center in Addis Ababa, Ethiopia and assess the role of MRI in clinical work up of patients with perinatal asphyxia. The study aims to see if there are specific MR imaging patterns of Neonatal Hypoxic ischemic encephalopathy following perinatal asphyxia and clinical presentation and correlation with prenatal and perinatal risk factors which can further guide in intervening this complication.

Perinatal asphyxia represents a notable contributor to both morbidity and mortality among newborns on a global scale. (17,18) Despite advances in neonatal care, there is still a lack of understanding regarding the Pathophysiology of perinatal asphyxia and its long-term effects on brain development. The study includes the clinical presentation of patients with perinatal asphyxia which explains some of the long-term complications are associated with perinatal asphyxia.

Apart from study done on developmental delay, there is limited published information on the imaging pattern following perinatal asphyxia, clinical presentation and associated pre and perinatal risk factors according to my literature search in Ethiopia. This research can serve as a foundation for subsequent extensive prospective investigations.

Literature Review

MRI imaging pattern in perinatal asphyxia

Magnetic resonance imaging (MRI) is a useful tool for diagnosing HIE, assessing its severity & predicting its outcomes.(19,20) The MRI patterns of HIE depend on the severity of the injury and the timing of the scan as well as the stage of brain maturity.(13,19,21)

A study by Bobba et al., done in 2022 analyzed the MRI diffusion-weighted imaging (DWI) of 33 term neonates with hypoxic ischemic encephalopathy (HIE) and found that the location and volume of hypoxic ischemic lesions varied according to the severity of HIE. The study categorized HIE into mild, moderate, and severe based on clinical criteria and reported that infarct volumes and neonatal scores were significantly different among the categories. The study also showed that mild and moderate HIE mainly affected the subcortical and deep white matter regions near the boundaries of arterial supply territories, while severe HIE additionally involved the basal ganglia, hippocampus, and thalamus. Furthermore, the study identified the brain regions that were more likely to be injured with increasing severity of HIE, such as the hippocampus, thalamus, and lentiform nucleus. The study concluded that severe HIE had a distinctive pattern of injury compared to mild/moderate HIE in term neonates.(22)

An institutional based descriptive retrospective study done by Reddy R, assessed distribution patterns of MRI findings of 50 infants with HIE, 18 of whom were preterm and 32 of whom were full-term. Additionally, the study stated that there were 35 (70%) male and 15 (30%) female, with developmental delay being the most prevalent clinical feature in both groups. In the research findings, it was observed that periventricular leukomalacia presented as the predominant feature in 36% of premature individuals, whereas subcortical and periventricular white matter hyperintensities detected on T2-weighted and Fluid Attenuated Inversion Recovery (FLAIR) sequences were identified as the prevailing characteristic in 64% of term-born patients. The study also noted that MRI findings varied depending on the brain maturity at the time of imaging. According to the study, in preterm and full-term patients with HIE, MRI can reveal various patterns of injury resulting from birth asphyxia and ischemia insult and can give predictive information with routine follow-up scans.(15)

A review study done in Poland by Cabaj et al., done in 2012 emphasized the role of MRI in detecting and diagnosing HIE in preterm and term neonates with perinatal risk factors. The authors stated that MRI can reveal three classic patterns of HIE: periventricular leukomalacia/watershed infarction, basal ganglia and/or thalamus lesions, and multicystic encephalopathy, which have different prognostic implications for the infant development. The authors also acknowledged the remarkable plasticity and recovery potential of the child brain, which can sometimes lead to unexpected outcomes.(23)

A study by Heinz and Provenzale, done in 2009 examined the MRI Findings in the neonate with severe, total hypoxia. The authors delineated four primary indicators that can assist in identifying severe hypoxia in newborns: abnormal elevation in signal intensity observed in the basal ganglia and thalamus on T1-weighted images, lack of the typical heightened signal intensity in the posterior limb of the internal capsule on T1-weighted images (known as the "absent posterior

limb sign"), and the presence of diffusion restriction in the basal ganglia, thalamus, and posterior limb of the internal capsule. The authors also described findings in prolonged partial hypoxia as more pronounced cortical changes with normal basal ganglia. Three patterns of hypoperfusion injuries are described according to the gestation age with periventricular leukomalacia pattern in preterm infants and superficial and deep watershed patterns in term neonates(13,24). The authors elucidated the underlying mechanisms and timing of these features and their implications for prognosis. They reported that severe hypoxic injury was associated with poor neurologic outcome and death, whereas mild or moderate injury had variable outcomes depending on the extent and location of damage. The authors also contrasted MRI with other imaging methods such as CT and sonography for evaluating neonatal hypoxia. They concluded that MRI was superior to CT and sonography in terms of sensitivity, specificity, and interobserver agreement for detecting and diagnosing HIE in term neonates(24).

In a review article published in 2022, the Authors reviewed the literature on HIE and its MRI findings and patterns. According to the review, patterns of MRI findings in HIE can be classified into four: the basal ganglia, thalamus, and posterior limb of internal capsule pattern; the watershed predominant pattern affecting the white matter in the centrum semi ovale and subcortical zones; the minimal focal/multifocal injury of white matter; and the extensive injury of the entire brain. The authors found that, these patterns are determined by several factors combined, including brain maturation, time, duration, and strength of cerebral blood flow impairment.(20,24)

A study done in United states which assessed HIE imaging findings from birth to adulthood found that the range of HIE findings on magnetic resonance imaging (MRI) varies depending on the severity and length of birth asphyxia as well as the stage of brain maturity. For instance, patterns of perinatal asphyxia-related hypoxic-ischemic damage in preterm neonates (37 weeks' gestational age) are obvious and distinct from those in full-term neonates (>37 weeks' gestational age) (21).

Objectives

General Objective

- To explore the late Brain MRI patterns and associated clinical findings of children who had clinical diagnosis of perinatal asphyxia at Yehuleshet Specialty clinic.

Specific objectives

- To determine different brain MRI findings and patterns associated with perinatal asphyxia in pediatric patients with history of perinatal asphyxia who underwent brain MRI imaging.
- To determine the Socio-demographic characteristics of pediatric patients with history of perinatal asphyxia who underwent brain MRI imaging.
- To assess the Clinical presentation and peri and prenatal risk factors of a child diagnosed with perinatal asphyxia and who have brain MRI
- Prenatal and perinatal risk factors of pediatric patients with history of perinatal asphyxia who underwent Brain MRI imaging.

Methods and materials

Study Area: The study was conducted at Yehuleshet Specialty Clinic, which is located in Addis Ababa, Ethiopia. Yehuleshet Specialty clinic is a private health facility that provides primary and secondary health care services to the residents of Addis Ababa and its surrounding areas. Both Adult and pediatric Neurology service takes major clinical services provided in this clinic. Pediatric Neurology Patients are evaluated by Pediatric neurologists.

The clinic has siemens 0.35T MRI with high number of neurology Brain MRI cases which are reported by Neuroradiologists.

Study Tool: Brain MRI study for pediatrics patient presented with neurologic symptoms is performed using axial and coronal inversion recovery sequences. Routine spin echo sequences (T1, T2 and FLAIR is done with axial and sagittal reconstruction). DWI/ADC is obtained. Reports of two Neuroradiologists were used to assess Brain MRI patterns in children diagnosed with perinatal asphyxia.

Study Period: The study was conducted in pediatric patients <14 years of age who had brain MRI presented with neurologic findings and has clinical diagnosis of perinatal asphyxia between March 2022 to March 2023 GC

Study Design: Institution-based Retrospective descriptive Cross-sectional study.

Source population: All pediatric patients who had brain MRI during the study period at Yehuleshet specialty clinic between March 2022 to March 2023 GC.

Inclusion criteria

- All pediatric patients with MRI evaluation done between March 2022 to March 2023 GC at Yehuleshet specialty clinic and Clinical Diagnosis of perinatal asphyxia.

Exclusion criteria

- Children of unknown gestational age at birth, and
- Children diagnosed with congenital malformations or known syndromes that could affect brain development or MRI findings.

Sample size and Technique

- The sample size was determined by using the formula for single population proportion considering a prevalence of 42% which is taken from similar study done in resource limited setup in South Africa in 2023(16).
- The sample was calculated by assuming a Confidence interval of 95%, 5% margin of error, & 10% non-response rate.
$$n = (Z\alpha/2)^2 \times P(1-p) / d^2$$
- Where: n = Sample size; P = 42%; d= margin of error; Z ($\alpha/2$)²= confidence interval and significance level
$$n = 0.42(1-0.42) (1.96)^2 / (0.05)^2 = 374$$
- The calculated sample size is 374, However, considering for a contingency that might happen during data collection due to incomplete charts or any other factors, 10% of calculated sample size is added.
Sample size= 374 + 37 = 411 patients

- In our study a total of 797 pediatric patients had brain MRI evaluation during the one-year study period at, and only 70 patients had history of perinatal asphyxia. So, we decided to include all pediatric patients with history of perinatal asphyxia and who had MRI evaluation done within the study period.

Measures

Dependent variable

- MRI Findings see Annexes

Independent variables

- Age
- Sex
- Gestational Age at Birth.
- Clinical presentation
- Delivery place
- Maternal illness
- Any obstetric complications

Operational Definitions

- Hypoxia- Decreased O₂ to cells or tissue
- Ischemia- Decreased blood flow to cells or organs that is inadequate to maintain physiologic function.
- HIE- Clinical evidence of encephalopathy with objective data to support a hypoxic-ischemic (HI) mechanism as the underlying cause for the encephalopathy
- Watershed pattern: subcortical and deep white matter injury (perisylvian, parasagittal, anterior inter arterial watershed and posterior inter arterial white matter injury)
- Encephalomalacia: area of cerebral parenchymal loss which is not in territory of watershed infarction or not classified under multicystic encephalomalacia
- Pediatric age group: Age <14 yrs. used in this study
- Prenatal asphyxia: Low APGAR score and history of Neonatal Encephalopathy

Data collection and procedures

Data was extracted by the principal investigator using structured questionnaire. A total of 797 pediatric patient's charts were identified who had Brain MRI imaging evaluation. Of these, 70 cases with clinical diagnosis of perinatal asphyxia were included. Using a structured questioner, demographic data, pre and perinatal history of patients was collected. The MRI reports were reviewed by the principal investigator in a systematic pattern.

The data extraction was held from July 10th to 7th of October 2023 G.C.

Data Quality control, processing and Analysis

All the data was checked for completeness and internal consistency by cross-checking and then was coded and double entered into Epi Data version 4.2 computer software packages and cleaned for inconsistency. For further analysis, the data was exported to Statistical Package for Social

Science (SPSS) version 26 software. The descriptive analysis of the data was indicated using numerical summary measures and presented using frequency tables, figures, and graphs/charts. Cross tabulation (contingency table) analysis using Fisher-exact test was used to analyze the presence of a pattern, difference or relationship/ association between dependent and independent categorical variable, by building an R x C contingency table for the variables and comparing their column or row frequencies (proportions), and p value <0.05 was considered statistically significant.

Dissemination of the results

The results of the study will be presented to Addis Ababa University, College of health sciences, Radiology department. The results of the study will also be sent to reputable journals for publication.

Ethical consideration

All medical documents used in this study were handled by Health professionals working at the Yehuleshet Specialty Clinic.

The study protocol was submitted for approval to research and ethical review committees of the Department of Radiology, school of medicine, college of health sciences, Addis Ababa University.

Result

Sociodemographic data and Risk factors among all patients who underwent MRI evaluation following history of perinatal asphyxia at Yehuleshet specialty clinic.

The study included a total of 70 pediatric patients with a history of perinatal asphyxia who underwent MRI evaluation at Yehuleshet specialty clinic. The age at time of MRI evaluation ranges from 2 months to 14 year. Gestational age was assessed of which 74.3% are term and 25.7% are preterm. 42.9% of our patients received antenatal care (ANC) during gestation and 55.7% were delivered at a healthcare facility via SVD (spontaneous vaginal delivery) or assisted vaginal delivery 62.9%. The presence of prolonged labor, fetal distress, maternal RVI serostatus, gestational diabetes mellitus (GDM), and maternal preeclampsia/eclampsia (PE/EC) was not documented in most cases. **Table 1 & Table 2**

Table 1 Sociodemographic data and gestational age of pediatric patients having history of perinatal asphyxia

Variable		Frequency	Percent
Age	≤2 months	2	2.9
	3 to 12 months	8	11.4
	1 to 5 year	43	61.4
	>5 year	17	24.3
Sex	Female	21	30.0
	Male	49	70.0
Gestational Age	Pre-term	18	25.7
	Term	52	74.3

Table 2 Antenatal and Perinatal Risk factors

Variables	Frequency (percentage)			Total
	Yes	No	Not documented	
ANC follow-up	30(42.9)	14(20.0)	26(37.1)	70(100.00%)
Prolonged Labor	9(12.9)	9(12.9)	52(74.3)	
Fetal Distress	17(24.3)	9(12.9%)	44(62.9)	
Maternal RVI	1(1.4)	13(18.6)	56(80.0)	
Maternal GDM	-	15(21.4)	55(78.6)	
Maternal PE/EC	1(1.4)	18(25.7)	51(72.9)	
Health care delivery	39(55.7)	11(15.7)	20(28.6)	
Mode of Delivery	SVD/assisted=44(62.9)	CS=18(25.7)	8(11.4)	

Additionally, the clinical presentation of pediatric patients included in this study is variable. Global Developmental Delay (GDD), observed in 61.4% of the cases followed by Seizures occurring in 21.4% of patients. Cerebral Palsy and extremity weakness were each reported in

approximately 7.1%, while microcephaly specifically was documented in 5.7% of cases. Additionally, other presentations were documented in 12.9% of patients. **Figure 1**

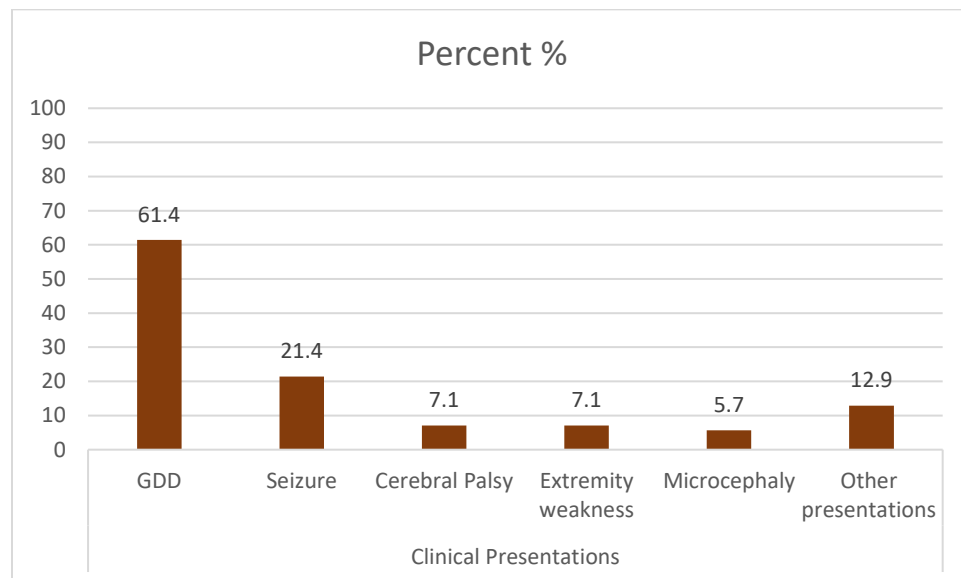


Figure 1 Distribution of clinical presentation of pediatric patients

Distribution and Patterns of MRI findings

Among 70 patients included in this study, 53 (75.7%) had abnormal MRI findings and the rest 17 (24.3%) had normal MRI findings. Distribution by the gestational age showed, 52 (74.3%) are term and 18 (25.7%) are preterm. Overall, from a total of 52 term infants and 18 preterm infants, the incidence of abnormal MRI findings was 71.2% (37/52) and 88.9% (16/18) respectively.

Table 3

Table 3 MRI findings with distribution and comparison of antenatal and perinatal risk factors of HIE among pediatric patients having history of perinatal asphyxia

Variable		Abnormal MRI finding, n=53	Normal MRI finding, n=17
		Frequency (Percentage)	Frequency (Percentage)
Age (Range 2 month to 14 year)	≤2 months	2 (100)	-
	3 to 12 months	7 (87.5)	1(12.5)
	1 to 5 years	32 (74.4)	11(25.6)
	>5 year	12 (70.6)	5(29.4)
Sex	Female	16 (76.2)	5(23.8)
	Male	37 (75.5)	12(24.5)
GA	Pre-term	16 (88.9)	2(11.1)
	Term	37 (71.2)	15(28.8)
ANC follow- up	YES	20(66.7)	10(33.3)
	NO	12(85.7)	2(14.3)
	Not documented	21(80.8)	5(19.2)
	HC	28(71.8)	11(28.2)

Site of Delivery	Home	11(100.0)	-
	Not documented	14(70.0)	6(30.0)
Mode of Delivery	SVD/Assisted	33(75.0)	11(25.0)
	CS	14(77.8)	4(22.2)
	Not documented	6(75.0)	2(25.0)
Prolonged Labor	No	9(100.0)	-
	Yes	6(66.7)	3(33.3)
	Not documented	38(73.1)	14(26.9)
Fetal Distress	No	8(88.9)	1(11.1)
	Yes	14(82.4)	3(17.6)
	Not documented	31(70.5)	13(29.5)
Presentation	GDD	29(67.4)	14(32.6)
	Seizure	12(80)	3(20)
	Cerebral palsy	4(80)	1(20)
	Extremity weakness	5(100)	-
	Microcephaly	4(100)	-
	Other	9(100)	-

The Fisher Exact test revealed significant associations between gestational age and specific MRI findings among infants with abnormal MRI findings. 62.5% of preterm infants had periventricular leukomalacia on MRI as compared with those full-term (10.8%) infants, (P-value<0.001). And, (64.9%) of term infants had Subcortical/ deep watershed border zone hyperintensities on MRI as compared to with preterm (12.5%) infants (P-value = 0.001). **Table 4**

Table 4 Association between gestational age and MRI finding patterns among infants with abnormal MRI findings, Total cases having abnormal MRI findings 53 (Fisher Exact test).

MRI finding		Frequency (percentage)		P-value
		Pre-term	Term	
Subcortical/watershed border zone hyperintensities	Yes	2(12.5)	24(64.9)	0.001
	No	14(87.5)	13(35.1)	
Encephalomalacia	Yes	4(25)	16(43.2)	0.21
	No	12(75)	21(56.8)	
Thinning of corpus callosum	Yes	5(31.3)	14(40)	0.52
	No	11(68.8)	22(59.5)	
Cerebral cortical atrophy	Yes	5(31.3)	14(37.8)	0.65
	No	11(68.8)	23(62.2)	
Delayed myelination	Yes	-	8(21.6)	0.08
	No	16(100)	29(78.4)	
Periventricular leukomalacia	Yes	10(62.5)	4(10.8)	<0.001
	No	6(37.5)	33(89.2)	
Cortical signal intensity change	Yes	1(6.3)	3(8.1)	-
	No	15(93.8)	34(91.9)	
Thalamic abnormality	Yes	-	3(8.1)	0.6
	No	16(100)	34(91.9)	
Basal ganglia abnormality	Yes	-	3(8.1)	0.6
	No	16(100)	34(91.9)	

Considering MRI findings suggestive of chronic injury, thinning of corpus callosum and cerebral cortical atrophy were seen 31.35 & 40% and 31.3% 37.3% respectively in preterm and term infants. Whereas patterns indicative of profound/severe hypoxic ischemic injury were only seen in term infants, thalamic and basal ganglia abnormality, each seen in 3 (8.1%) of term infants. No cases of peri-Rolandic cortex or brain stem involvement.

Early Brain MRI abnormalities following perinatal asphyxia such as T1 hyperintensity, and DWI/ADC abnormalities were not found in this study. **Table 4**

Table 5 Association between pattern of MRI findings and GDD and Seizure, among children with abnormal MRI findings n=53

MRI finding		Frequency (percentage)		P-value	Frequency (percentage)		P-value
		GDD			Seizure		
		yes	No		Yes	No	
Subcortical/watershed border zone T2/FLAIR abnormalities	Yes	14(48.3)	12(50)	0.9	4(33.3)	22(53.7)	0.22
	No	15(51.7)	12(50)		8(66.7)	19(46.3)	
Encephalomalacia	Yes	14(48.3)	6(25)	0.08	5(41.7)	15(36.6)	0.75
	No	15(51.7)	18(75)		7(58.3)	26(63.4)	
Cerebral cortical atrophy	Yes	7(24.1)	12(50)	0.051	5(41.7)	14(34.1)	0.74
	No	22(75.9)	12(50)		7(58.3)	27(65.9)	
Periventricular leukomalacia	Yes	7(24.1)	7(29.2)	0.68	4(33.3)	10(24.4)	0.71
	No	22(75.9)	17(70.8)		8(66.7)	31(75.6)	
T2/FLAIR Cortical signal intensity change	Yes	2(6.9)	2(8.3)	-	2(16.7)	24.9()	0.21
	No	26(89.7)	22(91.7)		10(83.3)	39(95.1)	
Thalamic abnormality	Yes	3(10.3)	-	0.24	-	3(7.3)	-
	No	26(89.7)	24(100)		12(100)	38(92.7)	
Basal ganglia abnormality	Yes	2(6.9)	1(4.2)	0.7	1(8.3)	2(4.9)	0.6
	No	27(93.1)	23(95.8)		11(91.7)	39(95.1)	

Subcortical/watershed border zone abnormalities and encephalomalacia were observed in 48.3% of patients who presented with GDD each, with no significant difference between those patients presenting with or without GDD. Encephalomalacia occurred in 48.3% of patients, with a higher percentage noted than in those without GDD (25%). Cerebral cortical atrophy and periventricular leukomalacia were present in 24.1% of patients who presented with GDD each, with no substantial difference based on presentation with or without GDD. Whereas, Subcortical/watershed border zone hyperintensities and Periventricular leukomalacia were identified in 33.3% of patients presenting with seizures each, with no significant difference between those patients presenting with or without seizures. Encephalomalacia and Cerebral cortical atrophy was noted in 41.7% of seizure cases each, similarly no significant difference seen between those patients presenting with or without seizures. **Table 5**

Discussion

In this study, out of 797 pediatric patients who had Brain MRI evaluation during the one -year study period at Yehuleshet specialty clinic, 70 (8.8%) patients had history of perinatal asphyxia. This result is consistent with earlier research evaluating the prevalence of perinatal asphyxia, especially in low- and middle-income nations such as Nigeria (21.1%), India (6.6%), and Cameron (8.5%) (25). However, the prevalence of birth asphyxia in our study was lower than other studies done in different hospitals of Ethiopia, Dilla (32.8%), Gondar referral public Hospital (27.1%), and Aykel, North central Ethiopia (11.11%)(26–28). this could be the result of differences in the study's sample size, research design, and—most importantly—its objective, since our study only looked at the patterns of MRI findings in patients presented with neurologic symptoms following perinatal asphyxia , while the previously mentioned studies emphasized more on the magnitude of perinatal asphyxia in newborns at the referral centers for prenatal asphyxia.

There is limited information on the prevalence and risk factors of perinatal asphyxia in low-income countries like Ethiopia, even though prenatal hypoxia considerably increases neonatal morbidity and mortality in developing nations.

In this study, we analyzed a total of 70 pediatric patients who had MRI evaluations at Yehuleshet specialty clinic and had a history of prenatal asphyxia. Out of 70 patients with clinical diagnosis of prenatal asphyxia, 53 (75.7%) has abnormal MRI findings which is comparable with other studies analyzing abnormal MRI findings in child with developmental delay showed abnormality attributed to prenatal asphyxia in majority of the cases(4,29). The age of patients at time of MRI evaluation ranged from 2 months to 14 years of age and majority of our patients 43 (61.4%) were presented for neurologic symptoms at the age group of 1 to 5 years. Most patients in this study are male (70%) in line with other study done in India and Australia, which reported higher proportion of male patients, 70% and 54.1%, than female patients, 30% and 45.9%, respectively (15,29).

However, the prevalence of certain risk factors such as prolonged labor, fetal distress, maternal RVI serostatus, gestational diabetes mellitus (GDM), and maternal preeclampsia/eclampsia (PE/EC) was not documented in our cases, limiting our ability to draw direct comparisons with other studies. These is mainly attributable to that our study was a retrospective study done by reviewing patients' chart and most of those variables were not recorded on charts. Future research should aim to investigate if these risk factors have any correlation with perinatal asphyxia and impact on MRI findings pattern in patients with hypoxic ischemic encephalopathy.

Global Developmental Delay (GDD), seen in 61.4% of the individuals in this study, was the most common clinical manifestation. Seizures were the second most common presentation, occurring in 21.4% of patients. Cerebral Palsy and extremity weakness were each reported in approximately 7.1%, while microcephaly specifically was documented in 5.7% of cases. Additionally, other presentations were documented in 12.9% of patients. These findings are consistent with previous studies that have correlated late Magnetic Resonance Imaging (MRI) findings with clinical outcomes in patients with Hypoxic Ischemic Encephalopathy (HIE). Study done in Ethiopia by Balcha TE in children undergone brain Magnetic Resonance Imaging (MRI)

evaluation for the developmental delay, 45.7% has imaging pattern attributed to Hypoxic-ischemic insults(4). An institutional study done in India in 2022 GC, observed that developmental delay was the most commonly associated clinical entity, with periventricular leukomalacia and subcortical/periventricular white matter hyperintensities being the most prevalent MRI findings in preterm and full-term patients, respectively(15). These studies highlight the importance of MRI in assessing the severity of hypoxic-ischemic injury and predicting neurodevelopmental outcomes in HIE patients. (30–35). Our study, however did not find statistically significant association between MRI imaging patterns and clinical presentations.

The results of our study show that, in infants with abnormal MRI findings, there is a substantial correlation between gestational age and a pattern of MRI findings. In our study majority of the patients with clinical diagnosis of perinatal asphyxia had term delivery 52(74.3%) and 18(25.7%) are preterm. Among patients with abnormal MRI findings, preterm showed higher percentage 88.9% (16/18) while term had 71.2% (37/52) which consistent with other studies (15,29).

Consistent with previous research, our study found a significantly higher proportion of preterm infants with periventricular leukomalacia on MRI compared to full-term infants (62.5% vs. 10.8%, respectively; p-value < 0.001) (36,37). For example, a study done in Australia found periventricular leukomalacia on MRI in 66.6% of preterm infants which is in line with our finding (62.5%)(29). Additionally, this finding highlights the vulnerability of immature brain/germinal matrix zone in preterm infants which is susceptible to hypoxic ischemic injury.

Additionally, our study revealed that term infants had a significantly higher proportion of subcortical/watershed border zone hyperintensities on MRI compared to preterm infants (64.9% vs. 12.5%, respectively; p-value = 0.001). These findings are consistent with various previous studies that have reported that subcortical/watershed border zone hyperintensities is most common in term infants with hypoxic-ischemic encephalopathy in the setting of mild to moderate hypoxia with a prolonged duration (9,15,23,24,29,34,37–40).

In this study, Corpus callosum thinning and cerebral cortical atrophy were seen in 40% term, 31.3% preterm infants and 37.8% of term, 31.3% preterm respectively for each cases indicating that chronic changes after HIE were common MRI findings. This is consistent with recent research that found that as an injury progresses from acute to chronic, the damaged zones exhibit corpus callosum thinning and cerebral cortical atrophy. (36)

Only three (8.1%) of the term infants in this study had thalamus and basal ganglia abnormalities each. Nonetheless, thalamic and basal ganglia abnormalities have been shown in previous studies to have characteristic MRI patterns that serve as the main predictor of profound hypoxia injury in term and preterm infants(37). Brainstem, and cerebellum infarctions are also associated with severe hypoxic injury(37). Furthermore, other various studies reported that the presence of basal ganglia abnormalities on conventional MR images and on diffusion-weighted MR images portend a poor outcome.(41–43)

This study did not find statistically significant correlation between clinical presentation and specific Brain MRI pattern as opposed to study done by Shankaran S et al which showed basal ganglia and thalamic involvement has association with motor disorders while cortical involvement is associated with cognitive disability(44).

Understanding these associations can aid in the diagnosis and management of infants with hypoxic-ischemic encephalopathy, allowing for more targeted interventions and improved outcomes.

Limitation

The study is subject to several limitations. First, the retrospective nature of the study, relying on chart reviews, resulted in incomplete documentation of certain key variables, such as risk factors (prolonged labor, fetal distress) and Apgar scores in a significant number of cases. This incomplete data limits the ability to draw comprehensive conclusions and comparisons with other studies. Additionally, the lack of information on certain risk factors hinders a thorough exploration of their correlation with perinatal asphyxia and their influence on MRI findings.

Conclusion

This study conducted in Addis Ababa, Ethiopia showed high magnitude of perinatal asphyxia (8.8%) among pediatric patients with neurology clinic visits. Brain MRI imaging showed abnormality in majority of cases with specific dominant patterns seen being periventricular leukomalacia and subcortical/deep watershed hyperintensities for preterm and term infants respectively indicating that brain MRI should be used as primary diagnostic work up for these patients. Global Developmental Delay (GDD) followed by seizure are the commonest clinical presentations in this study. Prenatal and perinatal risk factors were unknown in majority of cases, hence their impact on MRI findings were not assessed.

Recommendation

- Need for prospective studies that rigorously collect comprehensive data on risk factors associated with perinatal asphyxia, including prolonged labor and fetal distress. This would facilitate a more thorough analysis of the relationship between these factors, prenatal asphyxia and MRI findings, enhancing diagnostic precision.
- Complete and accurate documentation of Apgar scores in pediatric cases undergoing MRI evaluations for prenatal asphyxia to improve the understanding of neonatal outcomes.
- Lastly, further research should focus on developing interventions and strategies tailored to the specific MRI findings using better quality and early Brain MRI utilization among patients with clinical diagnosis of prenatal asphyxia, to enhance the diagnosis and management of infants with hypoxic-ischemic encephalopathy.

References

1. Hypoxic Ischemic Encephalopathy. 2023.
2. Kurinczuk JJ, White-Koning M, Badawi N. Epidemiology of neonatal encephalopathy and hypoxic–ischaemic encephalopathy. *Early Hum Dev.* 2010 Jul;86(6):329–38.
3. Diaz-Rosello J, Gisore P, Niermeyer S, Paul V, Quiroga A, Saugstad O, et al. Guidelines on basic newborn resuscitation 2012 [Internet]. Geneva: World Health Organization ; 2012. 2012 [cited 2012 Jan 1]. Available from: <https://www.ncbi.nlm.nih.gov/books/NBK137871/>
4. Balcha TE, Woldeyohannes AM, Neknek GA. Brain magnetic resonance imaging findings in patients with developmental delay in Addis Ababa, Ethiopia. *Ethiop J Health Sci* [Internet]. 2022 Sep 19 [cited 2024 Jan 5];32(4):773–80. Available from: <https://www.ajol.info/index.php/ejhs/article/view/232198>
5. Brain research to ameliorate impaired neurodevelopment–home-based intervention trial (BRAIN-HIT) - PubMed. 2010.
6. Neonatal mortality in East Africa and West Africa: a geographic analysis of district-level demographic and health survey data - PubMed. 2017.
7. Mekonnen W, Assefa N, Asnake W, Sahile Z, Hailemariam D. Under five causes of death in Ethiopia between 1990 and 2016: Systematic review with meta-analysis *The Ethiopian Journal of Health Development.* 2020.
8. Barkovich AJ, Miller SP, Bartha A, Newton N, Hamrick SEG, Mukherjee P, et al. MR Imaging, MR Spectroscopy, and Diffusion Tensor Imaging of Sequential Studies in Neonates with Encephalopathy.
9. Rutherford M, Ward P, Allsop J, Malamateniou C, Counsell S. Magnetic resonance imaging in neonatal encephalopathy - PubMed. *Early Hum Dev* [Internet]. 2005 Jan [cited 2023 Jul 3]; Available from: <https://pubmed.ncbi.nlm.nih.gov/15707711/>
10. Thayyil S, Chandrasekaran M, Taylor A, et al. Cerebral magnetic resonance biomarkers in neonatal encephalopathy: a meta-analysis - PubMed [Internet]. 2010 [cited 2023 Jul 3]. Available from: <https://pubmed.ncbi.nlm.nih.gov/20083516/>
11. Rutherford M, Ramenghi LA, Edwards AD, Brocklehurst P, Halliday H, Levene M, et al. Assessment of brain tissue injury after moderate hypothermia in neonates with hypoxic–ischaemic encephalopathy: a nested substudy of a randomised controlled trial. *Lancet Neurol.* 2010.
12. Cheong JLY, Coleman L, Hunt RW, Lee KJ, Doyle LW, et al. Prognostic utility of magnetic resonance imaging in neonatal hypoxic-ischemic encephalopathy: substudy of a randomized trial - PubMed [Internet]. 2012 [cited 2023 Jul 3]. Available from: <https://pubmed.ncbi.nlm.nih.gov/22751877/>
13. Venkatakrisna SSB, Elsinger M, Worede F, Curic J, Andronikou S. Unequal Cerebral Magnetic Resonance Imaging Changes in Perinatal Hypoxic Ischemic Injury of Term Neonates. *J Comput Assist Tomogr* [Internet]. 2023 Nov 1 [cited 2024 Jan 5];47(6):913–8. Available from:

/articles/journal_contribution/Unequal_Cerebral_Magnetic_Resonance_Imaging_Changes_in_Perinatal_Hypoxic_Ischemic_Injury_of_Term_Neonates/24850524/1

14. Okerefor A, Allsop J, Counsell SJ, Fitzpatrick J, Azzopardi D, Rutherford MA, et al. Patterns of Brain Injury in Neonates Exposed to Perinatal Sentinel Events. 2008.
15. Reddy R. Magnetic Resonance Imaging Evaluation of Perinatal Hypoxic Ischemic Encephalopathy: An Institutional Experience. *J Neurosci Rural Pract.* 2022 Jan;13:87–94.
16. Lorentz Id L, Mahomed Id N, Pillay T. MRI findings of children with suspected hypoxic ischaemic injury at a Tertiary Academic Hospital in Johannesburg, South Africa. *Wits J Clin Med [Internet].* 2023 [cited 2024 Jan 13];5(1):31. Available from: <http://dx.doi.org/10.18772/26180197.2023.v5n1a5>
17. Respiratory and Cardiovascular Support in the Delivery Room. 2018.
18. Spector JM, Daga S. Preventing those so-called stillbirths. 2008;
19. Ouwehand S, Smidt L, Dudink J, Benders M, de Vries L, Groenendaal F, et al. Predictors of Outcomes in Hypoxic-Ischemic Encephalopathy following Hypothermia: A Meta-Analysis. *Neonatology.* 2020;117(4):411–27.
20. Tabban HA, Hassan IA, ABHS-R, Salem KY, Salem TA, Ibrahim S. Hypoxic Ischemic Encephalopathy MRI Findings and Patterns Review, Revisited. *OMICS J Radiol* 11: 415. 2022 Dec;Vol 11(12): 415.
21. Hypoxic-ischemic brain injury: imaging findings from birth to adulthood - PubMed. 2008.
22. Bobba PS, Malhotra A, Sheth KN, Taylor SN, Ment LR, Payabvash S. Brain injury patterns in hypoxic ischemic encephalopathy of term neonates. *Journal of Neuroimaging.* 2022 Sep;33(1):79–84.
23. Cabaj A, Bekiesińska-Figatowska M, Mądzik J. MRI patterns of hypoxic-ischemic brain injury in preterm and full term infants - classical and less common MR findings. *Pol J Radiol* 2012 Jul;77(3):71-6. 2012;
24. Heinz ER, Provenzale JM. Imaging Findings in Neonatal Hypoxia: A Practical Review. *American Journal of Roentgenology [Internet].* 2009;192(1):41–7. Available from: <https://doi.org/10.2214/AJR.08.1321>
25. WHO. Global health observatory data repository world health organization. 2015. - Google Search.
26. Alemu A, Melaku G, health GAP, medicine undefined, 2019 undefined. Prevalence and associated factors of perinatal asphyxia among newborns in Dilla University referral hospital, Southern Ethiopia–2017. Taylor & Francis [Internet]. [cited 2023 Dec 22]; Available from: <https://www.tandfonline.com/doi/abs/10.2147/PHMT.S196265>
27. Admasu FT, Melese BD, Amare TJ, Zewude EA, Denku CY, Dejenie TA. The magnitude of neonatal asphyxia and its associated factors among newborns in public hospitals of North Gondar Zone, Northwest Ethiopia: A cross-sectional study. *PLoS One [Internet].* 2022 Mar 1 [cited 2023 Dec

- 22];17(3):e0264816. Available from:
<https://journals.plos.org/plosone/article?id=10.1371/journal.pone.0264816>
28. Tibebe NS, Emiru TD, Tiruneh CM, Getu BD, Abate MW, Nigat AB, et al. Magnitude of birth asphyxia and its associated factors among live birth in north Central Ethiopia 2021: an institutional-based cross-sectional study. *BMC Pediatr*. 2022 Jul;22(1).
 29. YIN R, Reddihough DS, Ditchfield MR, Collins KJ. Magnetic resonance imaging findings in cerebral palsy. *J Paediatr Child Health*. 2000 Dec;36(2):139–44.
 30. Twomey E, Twomey A, Ryan S, Murphy J, Donoghue VB. MR imaging of term infants with hypoxic-ischaemic encephalopathy as a predictor of neurodevelopmental outcome and late MRI appearances. *Pediatr Radiol*. 2010 May;40(9):1526–35.
 31. Barkovich AJ, Hajnal BL, Vigneron D, et al. Prediction of neuromotor outcome in perinatal asphyxia: evaluation of MR scoring systems - PubMed. *AJNR Am J Neuroradiol* [Internet]. 1998 Jan [cited 2023 Dec 18];19(1):143–9. Available from:
<https://www.ncbi.nlm.nih.gov/pmc/articles/PMC8337350/>
 32. Rutherford MA, Pennock JM, Counsell SJ, et al. Abnormal magnetic resonance signal in the internal capsule predicts poor neurodevelopmental outcome in infants with hypoxic-ischemic encephalopathy - PubMed. *Pediatrics*. 1998 Aug;102:323–8.
 33. Fatemi A, Fatemi A, Wilson MAA, Johnston M V. Hypoxic-Ischemic Encephalopathy in the Term Infant. *Clin Perinatol*. 2009;
 34. Logitharajah P, Rutherford M, Rutherford MA, Cowan FM, Cowan FM. Hypoxic-Ischemic Encephalopathy in Preterm Infants: Antecedent Factors, Brain Imaging, and Outcome. *Pediatr Res*. 2009;
 35. Ahearne C, Boylan GB, Murray DM. Short and long term prognosis in perinatal asphyxia: An update. *World J Clin Pediatr*. 2016;
 36. Ghei SK, Zan E, Nathan JE, Choudhri A, Tekes A, Huisman TAGM, et al. MR Imaging of Hypoxic-Ischemic Injury in Term Neonates: Pearls and Pitfalls. *RadioGraphics*. 2014 Jul;34(4):1047–61.
 37. Chao CP, Zaleski CG, Patton AC. Neonatal Hypoxic-Ischemic Encephalopathy: Multimodality Imaging Findings. *RadioGraphics*. 2006 Dec;26(suppl1):S159–S172.
 38. Bano S, Chaudhary V, Garga U. Neonatal hypoxic-ischemic encephalopathy: A radiological review. *J Pediatr Neurosci*. 2017;12(1):1.
 39. Barkovich A. Pediatric neuroimaging [Internet]. 2005 [cited 2023 Dec 22]. Available from:
<https://books.google.com/books?hl=en&lr=&id=1Pm5yS0gBfgC&oi=fnd&pg=PA1&dq=Barkovich+AJ.+Pediatric+neuroimaging.+4th+ed.+Philadelphia,+Pa:+Lippincott+Williams+%26+Wilkins,+2005%3B+17%E2%80%93369,+190%E2%80%93279.&ots=YOiHRtVVjz&sig=zOy3SSjDF8AG-vR1sWf9pPBRusw>
 40. Volpe JJ, Pasternak JF. Parasagittal cerebral injury in neonatal hypoxic-ischemic encephalopathy: Clinical and neuroradiologic features. *J Pediatr*. 1977 Dec;91(3):472–6.

41. Ferriero DM. Neonatal Brain Injury. *New England Journal of Medicine*. 2004 Nov;351(19):1985–95.
42. Zarifi MK, Astrakas LG, Poussaint TY, Plessis A du, Zurakowski D, Tzika AA. Prediction of Adverse Outcome with Cerebral Lactate Level and Apparent Diffusion Coefficient in Infants with Perinatal Asphyxia. *Radiology*. 2002 Dec;225(3):859–70.
43. Boichot C, Walker PM, Durand C, Grimaldi M, Chapuis S, Brunotte F. Term neonate prognoses after perinatal asphyxia: contributions of MR imaging, MR spectroscopy, relaxation times, and apparent diffusion coefficients. *Radiology*. 2006 Dec;239(3):839–48.
44. Shankaran S, McDonald SA, Laptook AR, Hintz SR, Barnes PD, Das A, et al. Neonatal Magnetic Resonance Imaging Pattern of Brain Injury as a Biomarker of Childhood Outcomes following a Trial of Hypothermia for Neonatal Hypoxic-Ischemic Encephalopathy. *J Pediatr* [Internet]. 2015 Nov 1 [cited 2024 Jan 13];167(5):987-993.e3. Available from: <https://pubmed.ncbi.nlm.nih.gov/26387012/>

Annexes

Data Collection Tool

Questionnaire Code _____

Instructions to the data collectors

This questionnaire contains two parts; Read each part carefully and encircle appropriate number of responses. If more than one response is needed, it's possible to encircle more than one response only in response column.

Table 6: Part1- Socio-demographic and Part2-Clinical Data

	Variables	Response
1	Study number I care/Chart number
Part 1: Socio-demographic profile		
2	Gender	1. Male 2. Female
3.	Age (months/years)	_____ yrs _____ months
4.	Address	1. Rural 2. Urban
Part II: Clinical profile		
5.	ANC follow-up	
6.	Gestational age at delivery	1 preterm 2 Term 3 Post term
7.	Mode of delivery	1) SVD 2) Instrumental vaginal delivery

		3) C-Section
8.	Site of delivery	1) Health center/Hospital 2) Clinic 3) Home
9.	Any risk factor for HIE	1) Yes 2) No
10.	Type of risk factor	1) Prolonged labour 2) Any cardiac abnormality on CTG
11.	Duration of injury	1) Prolonged 2) Short
12.	Degree of injury	1) Mild to moderate 2) Severe

Table 7: Part 3: MRI findings

Part III: MRI findings		
11	Age at which MRI is taken	1) neonate ,specify dates 3) Less than six month 4) 6month -2yrs 5) 2yrs-5yrs 6) >5yrs
12.	Any MRI findings	1) Yes

		2) No
13.	T1 basal ganglia hyper intensity	1)yes 2)N0
14.	T1 thalamic hyper intensity	1)yes 2) No
15.	Absent posterior limb sign	1) Yes 2) No
16.	DWI/ADC abnormality	1) Yes 2) No
17.	Cortical signal intensity change	1) Yes 2) No
18.	Periventricular leukomalacia	1) Yes 2) No
19.	Water shed infarct	1) yes if yes Deep white matter/superficial 2)No