

# **Amebiasis in Ethiopia: Problems in diagnosis and determination of prevalence of infection**

By

**AMHA KEBEDE**

**A dissertation submitted to the School of  
Graduate Studies, Addis Ababa University  
In Partial fulfilment for the Degree of  
Doctor of Philosophy in Parasitology**

**Department of Biology  
Addis Ababa University  
Addis Ababa, Ethiopia  
Feb 2005**

SCHOOL OF GRADUATE STUDIES

**ADDIS ABABA UNIVERSITY  
SCHOOL OF GRADUATE STUDIES**

Amebiasis in Ethiopia: Problems in Diagnosis and  
Determination of Prevalence of Infection

By

Amha Kebede

**Amebiasis in Ethiopia: Problems in diagnosis and  
determination of prevalence of infection**



**AMHA KEBEDE**

February 2005

**ADDIS ABABA UNIVERSITY  
SCHOOL OF GRADUATE STUDIES**

**Amebiasis in Ethiopia: Problems in Diagnosis and  
Determination of Prevalence of Infection**

**By  
Amha Kebede**

*A Thesis Presented to the School of Graduate Studies of the Addis  
Ababa University in Partial Fulfillment of the Requirements for the  
Degree of Doctor of Philosophy in Biology (Biomedical Science)*

**Approved by Examining Board:**

Dr. Leonardus Gerardus Visser (External Examiner)


Prof. Shibru Tedla (Internal Examiner)

Dr. Beyene Petros (Internal Advisor)

Dr. Tsehaynesh Messele (Internal Advisor)

Dr. Ton Polderman (External Advisor)

Dr. Dawit Abate (Chairman)



Handwritten signatures in blue ink over horizontal lines, corresponding to the names listed on the left. The signatures are: a large circular signature for Dr. Leonardus Gerardus Visser, a signature for Prof. Shibru Tedla, a signature for Dr. Beyene Petros, a signature for Dr. Tsehaynesh Messele, a signature for Dr. Ton Polderman, and a signature for Dr. Dawit Abate.

February, 2005



## ACKNOWLEDGMENTS

When this study was initiated in 2000, we expected it to be very smooth taking into account the already existing Ethio-Netherlands AIDS Research Project (ENARP) cohorts set-up. But the reality was not as we had imagined it. Finding the real *E. histolytica* was more of a mirage than a common infection. In a way the ever-elusive *E. histolytica* was as tricky as it was one hundred years ago. There were many times I was contemplating to give up the whole activity and move onto something else, more straightforward. But the wise and careful guidance of my advisors, Dr. Beyene Petros and Dr. Anthon Polderman, was always there to push me forward. I owe a great deal to both of them for their enlightened ideas, insights and support throughout the study period. Thank you for holding me in many painful moments, and for guiding my safe passage through uncertain road!

There are many people I need to thank for the support and encouragement I enjoyed all the time. But due to space constraints, I will have to restrict myself only to few. I would like to express my deepest gratitude to Dr. Tsehaynesh Mesele (Current EHNRI Director), Dr. Abera Geyid (former EHNRI Director) and Ato Tilahun Woldemichael (former EHNRI D. Director) for their support in every aspect. Thank you for your faith in me and for making all this possible.

I thank all Parasitology Laboratory members and ENARP staff for their collegial support. My sincere thanks to Wonji and Akaki cohort staff. My fellow PhD students at ENARP were always a source of inspiration and I thank them all. I would also like to extend my sincere appreciation to the Department of Biology, Addis Ababa University, particularly to Dr. Kifle Dagne for facilitating this training.

I thank Leiden University Medical Center for allowing me to do part of the lab work there. A special thanks to Dr. Jaco Verweij who has always been supportive in the quest to track down the illusive invasive *E. histolytica* with all sorts of available molecular techniques. Thanks also to Professor Dr. Roel Coutinho and Mrs Maria Oud for being always there for any unexpected assistance from the Amsterdam side.

I am most grateful to the Ethiopian Health and Nutrition Research Institute and the Dutch Ministry for Development Co-operation for making possible this study with the financial support needed. And, finally, I thank my families and friends for being always supportive.

## LIST OF ABBREVIATIONS

|         |   |   |
|---------|---|---|
| ABTS    | = | 2,2' Azino-bis 3 Ethylbenz-Thiazoline-6-Sulfonic Acid |
| ALA     | = | Amebic Liver Abscess                                  |
| ATP     | = | Adenine Triphosphate                                  |
| Bp      | = | Base pair   |
| BSA     | = | Bovine serum albumin                                  |
| DEA     | = | Diethyl amine   |
| DIG     | = | Digoxigenin   |
| DNA     | = | Deoxyribonucleic acid                                 |
| dNTP    | = | Deoxyribonucleotide triphosphate                      |
| EIA     | = | Enzyme Immuno Assay                                   |
| ELISA   | = | Enzyme Linked Immunosorbant Assay                     |
| ENARP   | = | Ethio-Netherlands AIDS Research Project               |
| Gal     | = | Galactose   |
| IHA     | = | Immuno Haemagglutination Assay                        |
| Kb      | = | Kilo base   |
| MGB     | = | Minor groove binding                                  |
| $\mu$ l | = | Micro-liter   |
| Nac     | = | N-Acetyl galactosamine                                |
| nm      | = | Nanometer   |
| OD      | = | Optical density                                       |
| PBS     | = | Phosphate buffered saline                             |
| PCR     | = | Polymerase Chain Reaction                             |
| PhHV-1  | = | Phocid herpesvirus type-1                             |
| Pmol    | = | Pico mole   |

|          |   |   |
|----------|---|---|
| PNPP     | = | p-nitrophenyl Phosphate, disodium 6H <sub>2</sub> O |
| PVPP     | = | Polyvinylpolypyrrolidone                            |
| RBC      | = | Red Blood Cell                                      |
| RPM      | = | Round per minute                                    |
| SSU-rRNA | = | Small subunit ribosomal Ribonucleic Acid            |
| SAF      | = | Sodium Acetic Acid Formalin                         |
| SHELA    | = | Soluble Hybridisation Enzyme Linked Assay           |
| s.l.     | = | Sensu lato  |
| s.s.     | = | Sensu stricto                                       |
| SSC      | = | Sodium Chloride Sodium citrate                      |
| WHO      | = | World Health Organization                           |

# TABLE OF CONTENTS

|  | Page |
|--|------|
| ACKNOWLEDGMENTS.....   | i    |
| ABBREVIATIONS.....   | iii  |
| TABLE OF CONTENTS.....   | v    |
| LIST OF TABLES.....  | viii |
| LIST OF FIGURES.....   | x    |
| ANNEX.....   | xi   |
| ABSTRACT.....  | xii  |
| <br>   |      |
| 1. INTRODUCTION.....   | 1    |
| 1.1. The Disease Amebiasis.....  | 1    |
| 1.2. The Organism: <i>Entamoeba histolytica</i> s. s.....                    | 3    |
| 1.2.1. Life Cycle and Transmission.....                                      | 5    |
| 1.2.2. The Two species Concept.....  | 7    |
| 1.2.3. Clinical Manifestations.....  | 9    |
| 1.2.3.1. Asymptomatic colonization.....                                      | 9    |
| 1.2.3.2. Amebic dysentery and colitis.....                                   | 10   |
| 1.2.3.3. Extraintestinal amebiasis.....                                      | 12   |
| 1.3. Specific Detection of <i>E. histolytica</i> and <i>E. dispar</i> . .... | 14   |
| 1.3.1. Isoenzyme analysis.....   | 15   |
| 1.3.2. Serological diagnosis.....  | 18   |
| 1.3.3. Coproantigen detection.....   | 20   |
| 1.3.4. Polymerase Chain Reaction (PCR) in diagnosing Amebiasis.....          | 22   |
| 1.4. Epidemiology of Amebiasis.....  | 25   |
| 2. STATEMENT OF THE PROBLEM.....   | 28   |
| 3. AIMS OF THE STUDY.....  | 30   |
| 4. MATERIALS AND METHODS.....  | 31   |
| 4.1. Study Subjects.....   | 31   |
| 4.1.1. Cohort participants.....  | 31   |
| 4.1.2. Amebic Liver abscess: A retrospective study.....                      | 31   |

|          |  |    |
|----------|--|----|
| 4.1.3.   | Diarrheal patients.....  | 32 |
| 4.1.4.   | Amebiasis in school children and prisoners.....  | 32 |
| 4.1.5.   | Cases of suspected clinical amebiasis.....   | 33 |
| 4.2.     | Stool sample Collection.....   | 33 |
| 4.3.     | Laboratory Methods.....  | 34 |
| 4.3.1.   | Microscopy.....  | 34 |
| 4.3.2.   | DNA isolation.....   | 35 |
| 4.3.2.1. | Direct freezed faeces.....   | 35 |
| 4.3.2.2. | Absolute ethanol preserved faeces.....   | 35 |
| 4.3.3.   | Polymerase Chain Reaction- Solution Hybridisation Enzyme Linked<br>Immuno Assay (PCR-SHELA).....   | 36 |
| 4.3.3.1. | DNA Amplification.....   | 36 |
| 4.3.3.2. | Solution hybridisation enzyme linked immuno assay (SHELA) for<br>detection of <i>E. histolytica</i> and <i>E. dispar</i> PCR products..... | 37 |
| 4.3.4.   | Real-Time PCR.....   | 38 |
| 4.3.5.   | Copro-antigen detection.....   | 40 |
| 4.3.5.1. | <i>Entamoeba</i> genus- specific detection ELISA.....  | 40 |
| 4.3.5.2. | <i>E. histolytica</i> specific ELISA.....  | 41 |
| 4.3.6.   | Serology of amebiasis.....   | 42 |
| 4.3.6.1. | Detection of <i>E. histolytica</i> IgG by ELISA using crude antigen....  | 42 |
| 4.3.6.2. | Detection of <i>E. histolytica</i> IgG by ELISA using recombinant surface<br>antigen <i>E. histolytica</i> .....                           | 43 |
| 4.3.7.   | HIV screening and CD4+ and CD8+ T lymphocytes quantification.....  | 44 |
| 4.4.     | Data Analysis.....   | 44 |
| 5.       | RESULTS.....   | 45 |
| 5.1.     | Retrospective Analysis of Reported “Amebiasis”.....  | 45 |
| 5.1.1.   | Prevalence of intestinal parasites in Wonji Hospital.....  | 45 |
| 5.1.2.   | Prevalence of amebiasis and other intestinal parasites in Wonji and Akaki<br>cohorts population by routine stool examination.....          | 48 |
| 5.2.     | Retrospective Assessment of Patients with Liver Abscess.....   | 50 |
| 5.3.     | Misdiagnosis/Overdiagnosis of Amebiasis by Microscopy.....   | 54 |
| 5.3.1.   | Cohort participants.....   | 54 |
| 5.3.2.   | Diarrheal patients.....  | 56 |
| 5.4.     | Seroprevalence of <i>E. histolytica</i> IgG in Wonji and Akaki cohorts.....  | 62 |

|   |     |
|---|-----|
| 5.5. Prevalence of <i>E. histolytica</i> and <i>E. dispar</i> in Different Population Groups..... | 65  |
| 5.5.1. School children and prisoners.....   | 65  |
| 5.5.2. Reported haematophagous trophozoites.....  | 70  |
| 5.5.3. HIV/AIDS patients and Amebiasis.....   | 75  |
| 6. DISCUSSION.....  | 78  |
| 7. CONCLUSIONS .....  | 94  |
| 8. RECOMMENDATIONS.....   | 97  |
| 9. REFERENCES.....  | 99  |
| 10. ANNEX.....  | 114 |

## LIST OF TABLES

|  |    |
|--|----|
| Table 1. Prevalence of intestinal protozoa and helminth infections among 1236 cohort participants of ENARP in Wonji and Akaki at enrolment, as determined by routine microscopy examination of direct wet mount and concentration (1997-1999).....   | 49 |
| Table 2. Cases of liver abscess at Tikur Anbessa Hospital over 20 years among admitted patients based on Hospital record, discharge summaries, and death certificates (1982-2002).....   | 50 |
| Table 3. Admission and discharge diagnosis of liver abscess at Tikur Anbessa Hospital by year based on the Hospital record, discharge summaries and death certificates (1982-2002) .....   | 51 |
| Table 4. Common clinical signs and symptoms among admitted liver abscess cases in Tikur Anbessa Medical Wards for whom the Hospital card was available (1995-2002).....  | 53 |
| Table 5. Intestinal protozoan parasite prevalence among 225 cohort participants from Wonji and Akaki, as determined by microscopy with direct and formol-ether concentration and specific <i>E. dispar</i> prevalence as determined by PCR-SHELA (May-November 2000) .....   | 55 |
| Table 6. Comparison of microscopy finding of <i>E. histolytica</i> / <i>E. dispar</i> with specific PCR-SHELA finding of <i>E. dispar</i> on stool samples of 225 cohort participants from Wonji and Akaki , Ethiopia (May-November 2000).....   | 56 |
| Table 7. Prevalence of <i>E. histolytica</i> / <i>E. dispar</i> based on microscopic diagnosis of stool samples with regard to study site, age, sex, HIV status and treatment of 246 study subjects presenting with diarrrhea from Akaki and Wonji cohort participants and their family members (April- Dec 2001)..... | 58 |
| Table 8. Prevalence of <i>E. histolytica</i> / <i>E. dispar</i> based on microscopic diagnosis of stool samples with regard to the clinical history of 246 study subjects presenting with diarrrhea from Akaki and Wonji cohort participants and their family members (April- Dec 2001).....                           | 59 |
| Table 9. Prevalence of intestinal protozoan infections among 246 study subjects with diarrhea from Wonji and Akaki, as determined by microscopic diagnosis (April- Dec 2001).....  | 60 |
| Table 10. Comparison of microscopy and coproantigen ELISA with PCR-SHELA, specific for <i>E. dispar</i> , on stool samples of patients presenting with diarrrhea (April-December 2001).....  | 62 |

|   |    |
|---|----|
| Table 11. Sero-prevalence of anti- <i>E. histolytica</i> IgG antibodies by crude antigen ELISA and recombinant surface antigen (P-Antigen) ELISA from samples selected randomly from Wonji and Akaki cohort participants (Feb 1997 - Dec 2000).....   | 64 |
| Table 12. Comparison of <i>E. histolytica</i> diagnosis by microscopy and recombinant surface antigen (P-Antigen) ELISA by using samples selected randomly from Wonji and Akaki cohort participants (Feb 1997- Dec 2000).....   | 64 |
| Table 13. Prevalence of <i>E. histolytica</i> / <i>E. dispar</i> infections as determined by microscopy by using formol-ether concentration technique from SAF preserved stool specimens from 363 children in three primary school and 409 inmates in three prisons in Ethiopia (April-May 2003)..... | 66 |
| Table 14. Prevalence of intestinal protozoan infections among 363 subjects from three primary school children in Ethiopia as determined by microscopy by using formol-ether concentration technique from SAF preserved stool specimens (April- May 2003).....   | 67 |
| Table 15. Prevalence of intestinal protozoan infections among 409 subjects from three prisons in Ethiopia as determined by microscopy by using formol-ether concentration technique from SAF preserved stool specimens (April-May 2003).....  | 68 |
| Table 16. Comparison of microscopical detection of <i>Entamoeba histolytica</i> / <i>E. dispar</i> cyts and trophozoites from primary school children and prisoners with those of the real-time PCR detection (Apri-May 20030).....   | 69 |
| Table 17. Real-time PCR characterization of haematophagous trophozoites reported from eight hospitals and twelve health center laboratories (January- June 2003).....   | 71 |
| Table 18. Prevalence of <i>E. histolytica</i> / <i>E. dispar</i> based on microscopy of direct and formol-ether concentration by sex, age and hospital among 137 HIV patients presenting with diarrhea in Ethiopia (March 2002- Dec 2003).....  | 76 |
| Table 19. Real-Time PCR characterization of microscopic findings of <i>E. histolytica</i> / <i>E. dispar</i> among 137 HIV +ve diarrheal patients (March 2002-Dec 2003).....  | 77 |
| Table 20. Prevalence of <i>E. dispar</i> as determined by Real-Time PCR in relation to CD4 counts among 119 HIV patients presenting with diarrhea (March 2002-Dec 2003).....  | 77 |



## LIST OF FIGURES

- Fig 1. The Life Cycle of *E. histolytica* infection is initiated by ingestion of fecally contaminated water or food containing *E. histolytica* cysts. The infective cyst form of the parasite survives passage through the stomach and small intestine. Excystation occurs in the bowel lumen where invasive forms penetrate the intestinal mucosa and invade the liver and other organs. In most infections, the small vegetative ameba aggregate in the large intestine, resulting in self-limited, and asymptomatic infection. The trophozoite form converts to a precyst form, and matures into potentially infective tetranucleated cyst as it migrates down and out of the colon..... 6
- Fig 2. Intestinal parasite prevalence at Wonji Hospital based on routine direct microscopy (1988-1998)..... 46
- Fig 3. Intestinal protozoan parasite prevalence trend by year in Wonji Hospital based on routine direct microscopy result (1988-1998)..... 47
- Fig 4. Helminth parasite prevalence trend by year period in Wonji Hospital based on routine direct microscopy result (1988-1998)..... 47
- Fig 5. An example of amplification plot of *E. dispar* positive samples from 213 DNA specimens collected from primary schools and prisons. *E. dispar* specific amplification was detected with threshold cycles between 19 and 46 (median 33)..... 70
- Fig 6. Amplification plot of positive specimen for *E. histolytica* from Gondar Teaching Hospital with a Ct value of 25.2 (black arrow). The other six lines represent the serial dilution of the positive control..... 72
- Fig 7. Six cases of microscopically positive *Entamoeba* trophozoites that were believed to be engulfing RBC. The pictures were taken under 40 x 10 magnification from SAF preserved stool specimens in direct wet mount. A-C were negative by PCR for *E. histolytica* and/or *E. dispar*; D-I were all *E. dispar* by PCR..... 74

## ANNEX

- I. Questionnaire diarrhea study from unscheduled visit of the cohort participants and their family..... **114**
- II. Proforma sheet of liver abscess cases admitted at Tikur Anbesa Hospital..... **117**

# **Amebiasis in Ethiopia: Problems in diagnosis and determination of prevalence of infection**

## **ABSTRACT**

Although in Ethiopia intestinal amebiasis is believed to be associated with many cases of diarrhea, diagnosis is based on examination of fresh stool samples by microscopy, a method that cannot discriminate the potential invasive *Entamoeba histolytica* from the commensal *Entamoeba dispar*. The annual reports from Wonji Hospital and the Ethio-Netherlands AIDS Research Project indicate intestinal amebiasis to be a common infection with the highest prevalence compared to other parasites. Despite a considerably high reporting of intestinal amebiasis, a twenty-year hospital records among 117080 admitted patients showed only 47 suspected liver abscess cases, suggesting overdiagnosis. Though the prevalence of *E. histolytica/E. dispar* by microscopy was 24.9 % in Wonji and Akaki, the specific PCR did not confirm the presence of any *E. histolytica* infection. Even after careful microscopic analysis, by using quality control measures on 246 patients with diarrhea, microscopy demonstrated 40 % positivity of *Entamoeba* infection. However, application of PCR, a molecular diagnostic method that can distinguish *E. histolytica* from *E. dispar* did not confirm any *E. histolytica*, only 9% harboured *E. dispar*. Coproantigen detection ELISA in the same patients showed clear lack of sensitivity and specificity whereby only 11.4 % specimens in the genus *Entamoeba* specific ELISA were in agreement with the PCR, and none of the eight *E. histolytica* antigen positive was confirmed. The absence of *E. histolytica* infection in Wonji and Akaki was better justified with lower seropositivity (3 %) finding, using recombinant surface antigen of *E. histolytica*. Further study among healthy primary-school students and

prisoners emphasize the high occurrence of *E. dispar* infection. Each of these samples was checked for *Entamoeba* infection, by careful microscopy with ocular measurement, of formol–ether concentrates. DNA was then extracted from the 213 samples (27.6%) found *Entamoeba*-positive, and run in a real-time PCR with primers, based on the SSU-rRNA gene sequences of *E. histolytica* and *E. dispar*, that allow DNA from the two species to be distinguished. Although *E. dispar* DNA was identified in 195 (91.5%), no *E. histolytica* DNA was detected. This finding is consistent with the previous investigation that many amebic infections in Ethiopia are incorrectly attributed to *E. histolytica* and then treated unnecessarily. In order to further confirm the actual occurrence of *E. histolytica*, 110 suspected haematophagous trophozoites were collected from different hospitals and health centers. Only three (2.7 %) *E. histolytica* cases were detected by real-time PCR, while 71.3 % were *E. dispar*. The finding was similar among HIV/AIDS patients with diarrhea where microscopy revealed 12 % *E. histolytica/E. dispar*, but none with *E. histolytica*. The tradition of microscopy in a routine diagnostic set-up appears unsatisfactory to reliably differentiate RBC-engulfing ameba from non-invasive ameba. The public health implication of this study is that patient management and validity of epidemiological surveys are questionable as long as microscopy is the only diagnostic tool. There is also a need to continue work to establish the aetiology of diarrhea wrongly associated with amebae and explain the enigma of patients recovering following “anti-amebic” treatment. The commonly reported complaints of bloody mucoid diarrhea and association of low CD4 with *E. dispar* infection among AIDS patients require alternative explanation. Training in microscopy needs improvement, if not to diagnose the infection accurately, at least to minimize the over-reporting. This work emphasizes the necessity of capacity building for important diarrheal pathogens with molecular diagnostics at referral level

# 1. INTRODUCTION

## 1.1. The Disease Amebiasis

Classically, amebiasis is defined as infection of the human gastrointestinal tract by a protozoan parasite *Entamoeba histolytica* sensu lato (s.l.) with or without overt clinical symptoms (WHO, 1997). However, only *E. histolytica* sensu stricto (s.s.) is capable of invading the intestinal mucosa and may spread to other organs, mainly the liver and rarely the lung, brain and kidney (Ravdin & Petri, 1995). As a result, *E. histolytica* is unique, because it is able to invade tissues, and the clinical presentation may range from an asymptomatic infection to an invasive potentially fatal disease.

Infection with *E. histolytica* s.s. is ubiquitous, but the highest prevalence is usually found in poor communities with inadequate sanitation. Most infected individuals are healthy carriers of the protozoa, since as a commensal it induces no signs or symptoms; however, as a pathogen it is the cause of invasive amebiasis, with varying magnitude from country to country (Sepulveda & Martinez-Palomo, 1984). The incubation period in humans may vary from two days to four months, with about 96 % of experimental infections being diagnosed in the first two weeks after inoculation (Beaver *et al.*, 1956). The median incubation period was reported to be about 21 days in the Chicago outbreak study (Feachem *et al.*, 1983).

In the earlier days of amebiasis research, there was a great uncertainty among investigators that ameba may cause dysentery. In India, Lewis in 1870 and Cunningham in 1871 (Cited in Clark, 1998) reported intestinal ameba from fecal samples of cholera patients, without

realizing the ameba they discovered was pathogenic. It was Fedor Lösch in 1875 (Cited in Bruckner, 1992) who for the first time described motile trophozoites of ameba ingesting red blood cells, in a patient with chronic dysentery, which he named "*Amoebae coli*". He observed very active amebae, consistently containing red blood cells with bloody mucus in stool samples. Autopsy of the patient, who died after 5 months of illness, showed gross ulcers in the wall of the large intestine that were full of amebae. Despite this observation, Lösch was hesitant to attach aetiological significance to the presence of trophozoites in the stools of the patient. He thought that the dysentery was caused by concomitant bacteria with ameba merely serving to create the inflammatory reaction.

Other researchers, during the following few years, confirmed Lösch's observation of concomitant infections with bacteria and ameba, although unable to establish the association between the presence of ameba and dysentery. Detailed pathological investigations by Councilman and Lafleur (Cited in Rees, 1955) revealed the presence of "*Amebae*" in bacteriologically sterile liver abscesses, thereby demonstrating the pathogenic potential of the organism independent of concomitant infection by bacteria. Thus, in 1891, they provided the clinical evidence for involvement of ameba in dysentery (Cited in Rees, 1955), and they showed that amebic dysentery was different from the diphtheria form of dysentery caused by pathogenic bacteria. They also introduced terms such as "amebic dysentery" and "amebic liver abscess", and carried out detailed pathological studies, confirming the presence of ameba in the lesion.

Quinle and Roos in 1893 (Cited in Faust and Russel, 1970) described the cyst form, and also succeeded in producing dysentery by feeding cysts, or by injecting trophozoites in the rectum of cat. In an experiment on human volunteers that were infected by ameba cysts

from Manila water supply, Walker and Sellards (1913) provided a definite proof about ameba, causing dysentery (Cited in Clark, 1998). Some of these volunteers developed dysentery, with ameba in their stools, following ingestion of fecal material from cases of amebiasis, while others turned out to be merely carriers. The experiment provided the first evidence for the existence of asymptomatic carriers of ameba that were capable of causing dysentery in other individuals. Besides, it was demonstrated that infection with “*E. histolytica*” does not necessarily result in dysentery, the majority of infections being asymptomatic (Cited in Clark, 1998).

Schaudinn (1903) established the generic name *Entamoeba*, and reserved the name *Entamoeba coli* for the non-pathogenic species asymptotically harbored by healthy individuals (cited in Bruckner, 1992). He also introduced the name *Entamoeba histolytica* for the dysentery-producing ameba. Dobell (1919) further clarified the situation in which the distinguishing characteristics of the four species of commensal amebae and the pathogenic *E. histolytica* were so clearly described and illustrated (Cited in Jackson, 1998). The commensal species were *Entamoeba coli*, *Endolimax nana*, *Iodamoeba bütschlii*, and *Dientamoeba fragilis*.

## **1.2. The Organism: *Entamoeba histolytica* s. s.**

*Entamoeba histolytica* s.s. is an enteric protozoan parasite that exists in either trophozoite or cyst form. It belongs to the pseudopod forming protozoan superclass Rhizopoda within the subphylum Sarcodina (Levine *et al.*, 1980). Species that infect humans within their

family Entamoebidae, order Amoebida, and class Lobosea include *E. histolytica*, *E. hartmanni*, *E. polecki*, and *E. gingivalis*. *Entamoeba hartmanni*, previously referred to as “small race” *E. histolytica*, is a distinct species by virtue of morphology, unique antigens, and isoenzyme analysis (Bhattacharya *et al.*, 1991). Classification of the family *Entamoeba* is based on morphology, antigenic differences, DNA characterization, isoenzyme analysis, drug susceptibility, host specificity, *in vitro* growth characters, and *in vivo* virulence (Tachibana *et al.*, 1991).

Only *E. histolytica* s.s. is invasive of the *Entamoeba* group, which includes *E. dispar*, *E. hartmanni*, *E. polecki*, *E. coli*, and *E. gingivalis*. Clinical disease in humans, such as amebic colitis and liver abscess is associated with *E. histolytica* s.s. alone (WHO, 1997). Trophozoites of this parasite contain a single nucleus, and nuclear division occurs without the formation of condensed metaphase chromosomes and no sexual forms of the parasite have been identified (Singh & Petri, 2001). The genome size of *E. histolytica* is relatively small for a eukaryote ( $3.2 \times 10^7$  bp) and extremely adenine and thymine rich i.e., 67 % within coding regions and 78 % overall (Tannich & Horstmann, 1992).

*E. histolytica* is a eukaryotic organism with unusual cellular characteristics lacking organelles that morphologically resemble the rough endoplasmic reticulum, Golgi apparatus or mitochondria (Clark & Roger, 1995). Nuclear-encoded mitochondrial genes such as pyridine nucleotide transhydrogenase and heat shock protein 60 (hsp60), however, suggest that *E. histolytica* at one time contained mitochondria (Singh & Petri, 2001). Ribosomes form aggregated crystalline arrays in the cytoplasm of the trophozoite and the ribosomal RNA genes are found on multicopy circular DNA molecules. The ribosomal RNA is encoded on a circular 24 kb DNA episome, located outside the nucleus

(Bhattacharya *et al.*, 1989). The other unique features of *E. histolytica* include lack of glutathione and enzymes of glutathione metabolism, use of pyrophosphate instead of ATP at several steps in glycolysis and its inability to synthesize purine nucleotides *de novo* (Petri, 1996).

### 1.2.1. Life cycle and transmission

The life cycle of *E. histolytica* consists of an infective cyst and trophozoite form that could be either invasive in some or non-invasive in the majority of cases (Fig 1). Infection occurs when cysts are ingested from fecally contaminated food or water. Excystation occurs in the small intestine where a cyst undergoes nuclear followed by cytoplasmic division to form eight trophozoites. The trophozoites can then colonize and/or invade the large intestine. In the majority of cases (90 %), the parasite is commensal and infection is asymptomatic and self-limiting (Gathiram & Jackson, 1987; Gatti *et al.*, 2002). Figure 1 illustrates that small vegetative amebae are commensal and are responsible for the production of cysts necessary for transmission to new hosts. The commensal amebae are sometimes termed as "luminal amebiasis" and they are synonymous with the meaning of "cyst passer" (Elsdon-Dew, 1968).

Under some circumstances invasion of the colonic intestinal epithelium by trophozoites leads to the formation of flask-shaped ulcers and dissemination to other organs, mainly the liver. The capacity of *E. histolytica* to penetrate the wall of the large intestine and to spread extraintestinally accounts for the clinical symptoms (Ackers, 2002). In amebic dysentery the trophozoites are larger (up to 60  $\mu\text{m}$ ) and many are haematophgous,

sometimes having enormous numbers of condensed, contracted erythrocytes in the cytoplasm (Elsden-dew, 1968).

Cysts are never found within invaded tissues (Singh & Petri, 2001). There is a general agreement that amebae do not encyst in tissues and certainly the amebae in liver abscess have no chance of posterity (Elsden-dew, 1968). The cyst is 10-15  $\mu\text{m}$  in diameter and contains four or fewer nuclei. The quadrinucleate cyst is the infectious form of the parasite that is resistant to chlorination, and can survive for several weeks in a moist environment.

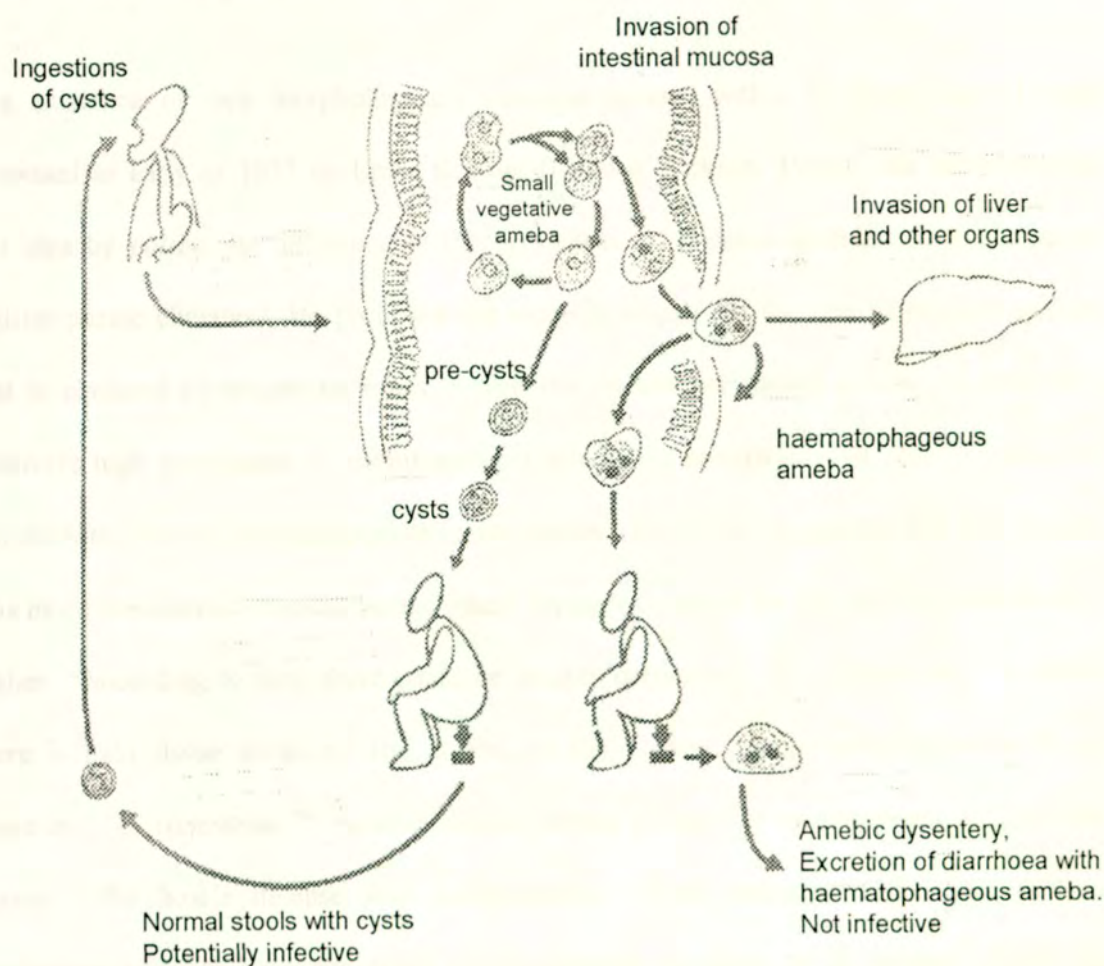


Fig 1. The Life cycle of *E. histolytica* infection is initiated by ingestion of fecally contaminated water or food containing *E. histolytica* cysts. The infective cyst form of the parasite survives passage through the stomach and small intestine. Excystation occurs in the bowel lumen where invasive forms penetrate the intestinal mucosa and invade the liver and other organs. In most infections, the small vegetative ameba aggregate in the large intestine, resulting in self-limited, and asymptomatic infection. The trophozoite form converts to a precyst form, and matures into potentially infective tetranucleated cyst as it migrates down and out of the colon (Polderman, 1999).

### 1.2.2. The two species concept

The existence of two morphologically identical species within *E. histolytica* s.l. was proposed as early as 1925 by Emile Brumpt (Cited in Jackson, 1998). He came up with this idea by noting the difference in the prevalence of invasive amebiasis in the tropical and temperate climates. He proposed the name *E. dispar* for the non-pathogenic species that is confined to temperate zones, where the disease prevalence is low, in spite of a relatively high prevalence of asymptomatic carriers. He postulated that only "*Entamoeba dysenteriae*" to be the pathogenic invasive ameba. He further suggested that this species was more prevalent in tropical zones, where the prevalence of the disease was considerably higher. According to him, there could be healthy carriers of "*E. dysenteriae*" in whom there is mild tissue invasion. The ameba, in such cases, could feed predominantly on bacteria. "*E. dysenteriae*" invades deeper tissues giving rise to symptoms, if for some reason, the host's defense was compromised. Such changes in the host defense mechanisms did not have any effect on the invasive capability of *E. dispar*. Both *E. dysenteriae* and *E. dispar* produce quadrinucleated cysts, which are identical, and both had

Fig 1. The Life cycle of *E. histolytica* infection is initiated by ingestion of fecally contaminated water or food containing *E. histolytica* cysts. The infective cyst form of the parasite survives passage through the stomach and small intestine. Excystation occurs in the bowel lumen where invasive forms penetrate the intestinal mucosa and invade the liver and other organs. In most infections, the small vegetative ameba aggregate in the large intestine, resulting in self-limited, and asymptomatic infection. The trophozoite form converts to a precyst form, and matures into potentially infective tetranucleated cyst as it migrates down and out of the colon (Polderman, 1999).

### 1.2.2. The two species concept

The existence of two morphologically identical species within *E. histolytica* s.l. was proposed as early as 1925 by Emile Brumpt (Cited in Jackson, 1998). He came up with this idea by noting the difference in the prevalence of invasive amebiasis in the tropical and temperate climates. He proposed the name *E. dispar* for the non-pathogenic species that is confined to temperate zones, where the disease prevalence is low, in spite of a relatively high prevalence of asymptomatic carriers. He postulated that only "*Entamoeba dysenteriae*" to be the pathogenic invasive ameba. He further suggested that this species was more prevalent in tropical zones, where the prevalence of the disease was considerably higher. According to him, there could be healthy carriers of "*E. dysenteriae*" in whom there is mild tissue invasion. The ameba, in such cases, could feed predominantly on bacteria. "*E. dysenteriae*" invades deeper tissues giving rise to symptoms, if for some reason, the host's defense was compromised. Such changes in the host defense mechanisms did not have any effect on the invasive capability of *E. dispar*. Both *E. dysenteriae* and *E. dispar* produce quadrinucleated cysts, which are identical, and both had

independent life cycles. This explanation gained little support until there was convincing experimental evidence, when Sargeant and Williams (1978) performed studies on isoenzyme typing that differentiated between pathogenic and non-pathogenic *E. histolytica* strains.

The main reason for lack of support for Brumpt's hypothesis was the findings of Walker and Sellards (Cited in Jackson, 1998), where by they presented a very good evidence for the existence of asymptomatic carriers of amebae that were capable of causing invasive disease in other individuals. Consequently, it was believed that individuals could be infected with *E. histolytica*, and might never develop disease. Such infections would resemble *E. dispar* proposed by Brumpt. The second objection to Brumpt's proposition was that it was practically impossible to differentiate the two organisms by light microscope and hence, it was not possible to determine the species present and decide whether or not to treat the patient.

The confusion on whether *E. histolytica* is a single or two species had resolved significantly in the last decade and as a result, *E. histolytica* had been reclassified into two species that are morphologically identical, but genetically distinct (Diamond & Clark, 1993). The two species can thus be differentiated by isoenzyme analysis (Sargeant & Williams, 1978), typing by monoclonal antibodies to surface antigens (Strachan *et al.*, 1988), by restriction fragment length polymorphisms and by PCR (Tannich *et al.*, 1989; Tannich & Burchard, 1991; Clark & Diamond, 1991).

### 1.2.3. Clinical manifestations

Infections with *E. histolytica* have no symptoms in many individuals, and most can clear their infection without any signs of disease (Ravdin & Petri, 1995). For unexplainable reason, however, 4-10 % of asymptomatic individuals infected with *E. histolytica* develop disease over a year (Gathiram & Jackson, 1987; Haque *et al.*, 2001). In other words, different studies indicate that in upto 90 % of *E. histolytica* infections, the symptoms are absent or very mild (Gati *et al.*, 2002). There is a wide spectrum of clinical presentations of *E. histolytica* infection (Wanke *et al.*, 1988). Symptomatic amebiasis is primarily an intestinal disease, and when it becomes extraintestinal, it usually involves the liver.

#### 1.2.3.1. Asymptomatic colonization

Asymptomatic colonization is a common presentation of *E. histolytica* infection, and patients may frequently have nonspecific gastrointestinal complaints, but for the most part tolerate the infection well. The aetiology of asymptomatic colonization is difficult to determine (Singh & Petri, 2001). Symptoms such as colicky lower abdominal pain and increased frequency of bowel movements with liquid stools are common, and they may be intermittent and chronic in nature. This kind of colonization is non-invasive intestinal infection, established by a lack of haematophagous trophozoites, hemocult-negative stools, and normal mucosa on colonoscopy (Ravdin & Petri, 1995).

There is no reliable controlled prospective study evaluating the outcome, and clinical significance of “non-invasive amebiasis”. In New Delhi, India, which is a highly endemic area for amebiasis, a study was conducted to examine if *E. histolytica* is the cause of

various intestinal complaints among a selected population of 184 cyst passers (Nanda *et al.*, 1984). No correlation, however, between a positive stool culture for *E. histolytica* (found in 18.7 %) and symptoms was observed. This could probably be due to the high prevalence of symptom (42 % were with diarrhea). As this study did not include species-specific test, it is difficult to differentiate the clinical significance, if any, of asymptomatic *E. histolytica* compared to *E. dispar* infection.

There are reports that asymptomatic infection with pathogenic *E. histolytica* results in serum antibody response (Ravdin *et al.*, 1990) and in serum antigenemia (Abd-Alla *et al.*, 1993). A study in Japan indicates that colonization with *E. histolytica* s.l. in the male gay population could result in 13-20 % seropositivity for *E. histolytica* infection (Takeuchi *et al.*, 1989). The situation in Japan is in sharp contrast to what is found in the United States and Europe, where almost all *E. histolytica/dispar* isolates from colonized homosexual males are *E. dispar* (Goldmeier *et al.*, 1986). It is believed that individuals that are colonized with *E. histolytica* are at high risk for future development of invasive disease months to even years later and should be treated (Takeuchi *et al.*, 1989; Iruzen *et al.*, 1992).

### **1.2.3.2. Amebic dysentery and colitis**

Dysentery or colitis is the main complications of infection with *E. histolytica*. Typical amebic ulcers occur in the colon, primarily in the cecum, the sigmoid colon, and the rectum (Perez-Tamayo, 1986). In a patient with diarrhea, containing visible or microscopic blood, it is very important to make a distinction amongst infectious causes such as *Shigella*, *Salmonella*, *Campylobacter* and enteroinvasive and enterohemorrhagic *E.*

*coli* (Ravdin & Petri, 1995). All of these pathogens are associated with grossly bloody or heme positive stools. In amebic infection, significant leukocytes are less common than bacterial dysentery, and patients usually are afebrile (Speelman *et al.*, 1987). It is also essential to take into consideration non-infectious causes like inflammatory bowel disease, ischemic colitis and gastrointestinal bleeding secondary to diverticulosis (Upinder & Petri, 2001). Because of potentially serious complications of steroid treatment in acute amebiasis, amebic infection must be ruled out by biopsy, and serology before instituting therapy for inflammatory bowel disease (Wopnick, 1973; Patel *et al.*, 1989).

Patients with amebic colitis present with bloody diarrhea and abdominal pain and tenderness (Stanley, 2003). They commonly report duration of symptoms lasting several weeks, suggesting the chronic nature of the infection. A number of small volume mucoid stools are common, but profuse, watery diarrhea could be noted. Patients' stools are invariably haem-positive, even though no blood is seen, as *E. histolytica* invades the colonic mucosa (Adams & MacLeod, 1977). Presentation of amebic colitis sometimes could be atypical, with non-bloody diarrhea and lack of systemic symptoms such as fever, rendering diagnosis difficult (Singh & Petri, 2001). Laboratory diagnosis, in such patients, is unreliable, since a single stool exam for parasites is insensitive, histopathologic confirmation of infection on biopsy specimens may be demanding, and serologic tests for antiamebic antibodies are not always positive in the acute setting (Petri, 1996).

Rectal bleeding, mainly in children, without diarrhea could be seen (Jammal *et al.*, 1985). White blood cells can be present in the stool, and in severe cases pus can be visible, but fecal leucocyte numbers are generally not as high as in shigellosis (Speelman *et al.*, 1984). Fever is observed in less than 40 % of patients, whereas weight loss and anorexia can be

present. Occasionally, individuals develop fulminant amebic colitis, with profuse bloody diarrhea, fever, pronounced leucocytosis, widespread abdominal pain, often with peritoneal inflammation, and extensive involvement of the colon (Aristizabal *et al.*, 1991). Fulminant colitis is an infrequent presentation of amebic infection that has a very high mortality and a predisposition for occurring in the malnourished (Wanke *et al.*, 1988), pregnant women (Lewis & Antia, 1969), recipients of corticosteroids (Kanni & Knight, 1969), or the very young (Fuchs *et al.*, 1988).

Ameboma is also another form of intestinal amebiasis occurring very infrequently (Perez-Tamayo, 1986). It is found most often in the cecum and ascending colon, as a rather large (5-10 cm) and well-defined tissue mass occupying the wall and the lumen. Although ameboma is usually a single lesion, occasionally there may be more than one and, in rare cases, most of the colonic wall is involved.

### **1.2.3.3. Extraintestinal Amebiasis**

Amebic liver abscess (ALA) is the most frequent manifestation of extraintestinal amebiasis (Bruckner, 1992). Abscess complicates amebiasis in 3 to 9 % of patients (Frey *et al.*, 1989). The clinical presentation is highly variable, ranging from weight loss, weakness, and low-grade fever or an acute to febrile illness. Pain may include vague right-upper-quadrant discomfort, point tenderness between ribs on palpation, or pleuritic discomfort, spreading to the right shoulder. Patients, who present acutely with symptoms of less than two weeks of duration, have more prominent abdominal pain with fevers and rigors (Katzenstein *et al.*, 1982). Anemia, leukocytosis, and elevated alkaline phosphatase

concentrations are often noted, but jaundice, striking transaminase elevation, and eosinophilia are unusual (Guerrant, 1986).

Older patients tend to present with chronic illness, lasting longer than two weeks. They have less fever (only 30 %), and may have a wasting disease with significant weight loss (Katzenstein *et al.*, 1982). The number of patients presenting with acute ALA seems to be increasing, possibly reflecting earlier diagnosis and better access to medical care. ALA is characterized by a significant male preponderance and it is a disease seen most commonly in patients who reside in or have emigrated from an endemic area (Hugs & Petri, 2000).

It remains unclear why extraintestinal amebiasis is more common in men, although it has been suggested that alcohol use may play a role (Seeto & Rocky, 1999). Having alcohol consumption (> 150 g per day) is another common finding in patients with ALA. There is a speculation that alcohol renders the liver more susceptible to amebic infection by impairing Kupffer cell function or by impairing both cellular and humoral immunologic response (Seeto & Rocky, 1999). Only few patients, less than 30 %, have active diarrhea at the time of presentation with ALA (Reed, 1998). At the time of diagnosis of ALA, trophozoites are rarely found in the stool (18 % of cases), although they can be identified by culture in the majority of patients (Petri, 1996).

*E. histolytica* trophozoites reach the liver through the portal venous system causing periportal inflammation (Reed, 2000). Dissemination through the blood stream and survival is possible by the resistant nature of *E. histolytica* trophozoites to the lytic action of complement (Reed & Gigli, 1990; Braga *et al.*, 1992). Such kind of virulence property is common to many pathogens causing disseminated infection (Harriman *et al.*, 1982;

Joiner *et al.*, 1984). Even though the same early influx of acute inflammatory cells are seen in amebic colitis, trophozoites rapidly lyse inflammatory and host cells, causing rapid expansion of the abscess filled with necrotic, proteinaceous debris (Reed, 2000). If at all trophozoites are present, they are only detectable in the edge of the abscess (Katzenstein *et al.*, 1982).

Impaired host defences could be important in allowing the establishment of hepatic infection with subsequent abscess formation. The abscess is usually solitary and in the right lobe (Gibney, 1990). Ultrasonography and other imaging techniques are useful in confirming the presence of a mass or masses, but cannot distinguish between pyogenic and amebic abscess (Ralls *et al.*, 1987).

Stool examination and stool antigen detection tests are usually unhelpful because most patients with ALA do not have detectable parasites in their stool (Petri & Singh, 1999). Serologic testing with enzyme immuno assay (EIA) specific for *E. histolytica* circulating antibodies is diagnostic of choice for ALA (Haque *et al.*, 1999). In most cases, medical management alone is sufficient to treat uncomplicated cases. Metronidazole remains the drug of choice for treatment of ALA followed by a luminal agent to eradicate the asymptomatic carrier state (Freeman *et al.*, 1997).

### **1.3. Specific Detection of *E. histolytica* and *E. dispar***

Microscopy has become obsolete and unreliable diagnostic method, since the recognition of two morphologically identical species: *E. histolytica* and *E. dispar* (Petri, 1996). The

sensitivity of microscopy is no more than 33 % to 50 % in a patient with amebic colitis, from examination of a single stool specimen (Petri *et al.*, 1993; Haque *et al.*, 1997). Even though erythrophagocytic amebae are more likely to be *E. histolytica* than *E. dispar* (Gonzalez-Ruis *et al.*, 1994), *E. dispar* trophozoites have also been found to contain ingested red blood cells, making the criterion difficult (Haque *et al.*, 1995). Therefore, the need for species-specific diagnosis of *E. histolytica* and *E. dispar* is unquestionable. Microscopic identification of the parasite in stools, liver abscess, or colonic biopsies is neither sensitive nor specific, and should be replaced with *E. histolytica* specific diagnostic tests (Petri, 1996). A number of species specific diagnostic tests have been developed over the past two decades, such as isoenzyme analysis, molecular probes (Garfinkel, *et al.*, 1989), PCR, and coproantigen detection ELISA. Microscopy is still the mainstay of routine diagnosis in many endemic countries because of lack of an appropriate method easy to apply.

### 1.3.1. Isoenzyme analysis

Martinez-Palomo and colleagues' (1973) investigations on lectin agglutination and erythrophagocytosis revived the old idea of recognizing *E. dispar* as a distinct species. They demonstrated that only invasive strains agglutinated in concanavalin A, with the first indication of a biochemical division within what was being called "*E. histolytica*". Thus, for the first time, it was possible to show difference in agglutination between *E. histolytica* isolated from individuals with disease, and from those with asymptomatic infections.

The major breakthrough, however, came in 1978 from analysis of electro mobility properties of certain amebic isoenzymes (Sargeant & Williams, 1978). Isoenzyme

patterns (zymodemes) of *E. histolytica* isolated from thousands of asymptomatic and symptomatic human cases, using four glycolytic isoenzymes (hexokinase, glucosephosphate isomerase, phosphoglucomutase and L-malate) resulted in the characterization of at least 20 distinct zymodemes (Sargeant, 1985). Depending on the clinical picture of the source of the isolate, these zymodemes were placed in one of two categories: pathogenic, with two fast advancing hexokinase bands or non-pathogenic, where the two bands are less advancing (Sargeant, 1985).

Two isoenzyme patterns, the hexokinase and phosphoglucomutase, were found to differ in their electrophoretic migration in pathogenic and non-pathogenic *E. histolytica*. The pathogenic isoenzyme patterns, which are the minority of cases, are usually derived from individuals with positive serology, and history of some clinical symptoms. The non-pathogenic zymodemes, on the other hand, with few exceptions, belong to isolates from asymptomatic carriers with negative serology. In this manner, Sargeant and Williams (1978) had shown that band patterns obtained after starch-gel electrophoresis with the enzymes hexokinase and phosphoglucomutase correlate very closely with clinical findings. Similar results have been obtained by other groups, using different electrophoretic media (Mirelman *et al.* 1986; Moss & Mathew, 1987), leading to debate about the need to treat patients shedding cysts of a non-invasive zymodeme (Editorial, 1986).

Mirelman and colleagues (1986) described conversion of non-pathogenic to pathogenic zymodeme during axenic culture. Others reported correlation with increased virulence of the ameba, accompanied by immunological and genetic alterations (Bracha *et al.*, 1990). Clark and Diamond (1993a), on the other hand, showed that the reported conversion of non-pathogenic to pathogenic form was due to contamination of *E. dispar* cultures with *E.*

*histolytica* during axenization. They demonstrated, this possibility, using a method that allows distinguishing among individual isolates of *E. histolytica* (Clark & Diamond, 1993b). The idea of conversion, from non-pathogenic to pathogenic or vice versa, was never demonstrated in longitudinal culture studies where no evidence of alteration of isoenzyme patterns was encountered. Neither the finding of a non-pathogenic zymodeme, in conjunction with a pathogenic one in any single host, has ever been reported (Sargeant, 1985). Moreover, short-term interaction (for 1 hour) of axenically grown amebae with bacteria, which markedly enhanced their virulence, did not cause any changes in their pathogenic zymodeme (Bracha & Mirelman, 1984).

Extensive analysis of isoenzyme patterns of *E. histolytica* from different geographical regions, since late 1970s, has laid the foundation of our understanding of the existence of a species complex within amebiasis (Sargeant, 1987). As the isoenzyme electrophoresis findings concurred with clinical and epidemiological observations, it was clear to Sargeant (1987) that *E. histolytica* was responsible for invasive amebiasis, while more commonly occurring, morphologically identical *E. dispar* gave rise to asymptomatic infections. It has been suggested that zymodemes can be used as biochemical markers to distinguish between the two different "*E. histolytica*" species. Therefore, individuals harboring ameba with non-pathogenic zymodemes may not require treatment, a suggestion that has been put forward much earlier than its official acceptance by the World Health Organization (WHO, 1997).

Isoenzyme analysis in practice has several disadvantages: culturing of microscopically cyst-positive specimen is very often unsuccessful (Blanc & Sargeant, 1991; Sehgal *et al.*, 1995). The technique is rather cumbersome, and it could take seven to fourteen days to

grow enough trophozoites for preparation of the lysates. It is now hardly used for clinical diagnosis and for research purposes, even if the original procedure involving starch-gel electrophoresis of four enzymes is simplified to merely examining hexokinase mobility in agarose mini-gels (Strachan *et al.*, 1988).

### 1.3.2. Serological diagnosis

Most people with intestinal amebic infection in endemic areas are exposed repeatedly to *E. histolytica* antigens. Yet, in the majority of cases the usual symptoms associated with *E. histolytica* may not always present (Lotter *et al.*, 1995). Therefore, definitive diagnosis by detection of antibody with crude antigen is difficult, especially in developing countries because of the inability to distinguish current from past infection (Gathiram & Jackson, 1987; Caballero-Salcedo *et al.*, 1994). Serological diagnosis, with crude antigen, could be useful for identification of *E. histolytica* infection in developed countries, where *E. histolytica* infection is not endemic (Weinke *et al.*, 1989; Walderich *et al.*, 1997; Ohnishi & Murata, 1997; Verweij *et al.*, 2000a). It is particularly useful in diagnosing amebic liver abscess, since specific antibodies detected in symptomatic patients is high (Knobloch & Manweiler, 1983; Zengzhu *et al.*, 1999).

Serum antibodies to *E. histolytica* can be detected in 75 to 85 % of patients with symptomatic *E. histolytica* infection (Ravdin *et al.*, 1990). Assays such as immuno haemagglutination assay (Hung *et al.*, 1999), counterimmunoelectrophoresis (Bapat & Bhave, 1990), amebic gel diffusion test (Jackson *et al.*, 1984), complement fixation (Knobloch & Mannweiler, 1983; Lotter *et al.*, 1993), indirect fluorescence assay (Tachibanna *et al.*, 2000), latex agglutination (Lotter *et al.*, 1993; Cummins *et al.*, 1994),

and ELISA (Lotter *et al.*, 1993; Lotter *et al.*, 1995; Braga *et al.*, 1996) have been used to detect serum antibodies to *E. histolytica*.

Lack of accurately defined “gold standard” is a major problem in the assessment of the sensitivity of the antibody detection techniques currently in use. ELISA, based on a recombinant *E. histolytica* surface antigen, proves to be highly sensitive and specific for serodiagnosis of invasive amebiasis even in endemic countries (Lotter *et al.*, 1992; Blessman *et al.*, 2002). This assay is capable of detecting antibodies to *E. histolytica* for approximately 6-12 months after successful anti-amebic therapy (Lotter *et al.*, 1995).

Serological detection of antibodies against *E. histolytica* gives a general picture of the disease, because serum antibodies are not expected to develop during *E. dispar* infection, which is the most common amoeba (Ravdin *et al.*, 1990). ELISA for detection of specific IgG, IgM and IgA antibodies is more sensitive and specific than IHA, and is the method of choice (Healy, 1986). Practically, all patients with invasive amebiasis have *E. histolytica*-specific IgG, and the presence of these antibodies is indicative of current or previous infection (Arvind *et al.*, 1988). Serum response is not always observed when colonization is confined to the intestinal lumen.

The presence of specific *E. histolytica* IgM antibodies by ELISA, with specific IgG, indicates active infection in 90-95 % of patients with hepatic amebiasis at the time of hospital admission (Attia *et al.*, 1995). *E. histolytica*-specific IgM antibodies generally disappear within 6 weeks of successful treatment, making them useful for distinguishing current from past infection, and could be useful for monitoring therapy. Despite IHA titers of 1:256 or greater are generally specific for amebiasis, it cannot distinguish extraintestinal

from intestinal amebiasis either by titer or persistence alone. ELISA is known to be more sensitive than counter immunoelectrophoresis (CIE) in patients with liver abscess (Restrepo *et al.*, 1996).

### 1.3.3. Coproantigen detection

Different investigators have developed ELISA that detects amebic antigens in fresh stool samples with a sensitivity approaching that of positive stool culture (Randal *et al.*, 1984; Grundy *et al.*, 1987; Haque *et al.*, 1993). It is, however, only one antigen detection test from TechLab, Inc. (Blacksburg Va) that is specific for *E. histolytica*, and is commercially available for clinical use (Haque *et al.*, 1995). This test uses a monoclonal antibody against an amebic adherence lectin that is inhibitable by galactose (Gal) or N-Acetyl galactosamine (GalNAc). The lectin is conserved, and highly immunogenic. Because of antigenic differences between the lectins of *E. histolytica* and *E. dispar*, it can be used to identify the pathogenic species (Petri & Schnaar, 1995).

Antigen detection ELISA is claimed to be more sensitive and specific than wet-film microscopy or culture (Haque *et al.*, 1998). The sensitivity of this method for detection of antigens in stools of patients with amebic colitis is indicated to be greater than 85 %, and its specificity when compared with that of the stool culture method is greater than 90 %. It is difficult to assess whether antigen detection produces false positive results, as culture test, the “gold-standard”, requires cultivation of the organism, which is known not to be 100 % sensitive (Sehgal *et al.*, 1995). According to Haque and colleagues (1998), PCR results suggest that most culture or microscopy negative, but antigen positive samples are true positives.



There is indication that antigen detection ELISA could be useful for the detection of *E. histolytica* lectin antigen in sera of patients with amebic colitis and liver abscess. For instance, in patients from Egypt, 42 % of asymptomatic *E. histolytica* infections, and 57 % of symptomatic colitis had detectable levels of antigen in their serum samples (Abd-Alla *et al.*, 1993). In Dhaka, Bangladesh, 94 % of patients with ALA had detectable levels of lectin antigen in their serum samples before treatment. The sensitivity of this method was only 16 % after 7 days of treatment with metronidazole (Haque *et al.*, 2000).

Antigen detection ELISA directly from faeces is much less user dependent and much more sensitive than microscopy, and it could be the preferred test for diagnosis in the future (Petri, 1996). It is not generally used in endemic areas, and its reported sensitivity and specificity still needs to be confirmed with independent techniques such as PCR (Mirelman *et al.*, 1997; Pillai *et al.*, 1999).

#### 1.3.4. Polymerase Chain Reaction (PCR) in diagnosing Amebiasis

The polymerase chain reaction has revolutionized molecular diagnosis of various parasitic infections, because it allows a billion-fold amplification of a given piece of DNA *in vitro* within a very short time (De Bruijn, 1988). This is even more apparent in the field of amebiasis, where the epidemiology of the disease has been a riddle for quite some time, because of lack of appropriate techniques for two morphologically identical, but genetically distinct species (Weiss, 1995). There is still a strong need for the development of sensitive and specific diagnostic tests that are fit for diagnostic purposes, and for large-scale studies in endemic areas. Walsh (1986) extrapolated that some 500 million people were infected by "*E. histolytica*". Yet, it has long been known that at most only 10 % will suffer from invasive disease, with the remainder being asymptomatic cyst passers (Gathiram & Jackson, 1987). It is not clear what proportions of patients infected with *E. histolytica* s.s are asymptomatic, and development of techniques to fill this gap is clear. In this regard, PCR techniques for the detection of *E. histolytica* DNA in stools and liver abscesses are encouraging (Weiss, 1995). PCR can also be used to distinguish among isolates of *E. histolytica*, which should prove useful for epidemiologic purposes as well as in determining the virulence characteristics of different isolates (Tannich *et al.*, 1991; Acuna-Soto *et al.*, 1993; Clark & Diamond, 1993b).

Various sequence differences between homologous genes in *E. histolytica* and in *E. dispar* make PCR easily applicable for identifying these two species. A number of PCR-based methods have been published (Tannich & Burchard, 1991; Acuna-Soto *et al.*, 1993; Katzwinkel-Waldarsch *et al.*, 1994; Aguirre *et al.*, 1995; Britten *et al.*, 1997; Troll *et al.*,

1997; Evangelopoulos *et al.*, 2000; Verweij *et al.*, 2000b). Tannich and Burchard (1991) made use of genomic DNA differences for amplification between pathogenic *E. histolytica* and non-pathogenic *E. dispar* from two cDNA clones, representing coding genomic sequences of the two species. The problem with this PCR method was its dependency on subsequent restriction fragment analysis, and culturing the organism prior to DNA extraction.

The epidemiology of *E. histolytica* and *E. dispar* has been extensively studied in a rural community of Mexico by PCR, using formalin-fixed stool samples and in the Philippines (Acuna-Soto *et al.*, 1993; Rivera *et al.*, 1996). The PCR was based on differences in highly repetitive sequences in the non-coding region of rRNA gene. This technique is simple, avoids culturing of organisms and it is claimed to possess high sensitivity and specificity with a good potential for large-scale epidemiologic studies. The major disadvantage of this particular PCR technique is that formalin is a known inhibitor of amplification, making it prone to false-negative results (Ramos *et al.*, 1999).

The protocol described by Katzwinkel-Waldarsch and colleagues (1994), for direct amplification of *E. histolytica* and *E. dispar* from stool specimens, is based on sequences from the 16S small subunit ribosomal RNA gene (Clark & Diamond, 1991). High sensitivity is expected as the target sequences are repetitive in nature, where they can be found in about 200 copies for each trophozoite (Sehgal *et al.*, 1994). The entire protocol can be performed at room temperature without DNA precipitation, but the subsequent nested PCR, and the need for verification of the final amplification product with restriction endonucleases digest makes it unsuitable for large-scale epidemiological studies.

Diagnosis of *E. histolytica* and *E. dispar* can be achieved in clinical specimens by PCR and colorimetric detection of the amplified product (Aguirre *et al.*, 1995; Verweij *et al.*, 2000b). These PCR methods are based on amplification of a 125 bp and 133 bp repetitive regions from extrachromosomal circular DNA in *E. histolytica* and in *E. dispar*, respectively. Specific internal sequences in the PCR products are detected colorimetrically by a solution hybridization procedure after PCR. Compared to the previous PCR protocols, this PCR is so robust and more specific in the differential diagnosis of the two species.

Most conventional PCR methods of amplification of ameba DNA are very sensitive and specific to detect *E. histolytica* and *E. dispar* from human faeces. All of them, however, require further processing of the PCR product, which is time-consuming and prone to false-positive results due to possible cross contamination. There is now a recently developed closed-tube, real-time PCR protocol, which can circumvent these problems (Wittwer *et al.*, 1997). Real-time PCR allows specific detection of the amplicon by binding to one or two fluorescence-labeled probes during PCR. Therefore, further downstream analysis is not required, reducing the time needed to obtain results. Moreover, the closed reaction tube minimizes the potential for cross-contamination, and the assay output is quantitative rather than qualitative, allowing appropriate diagnostic statistics to be applied (Blessmann *et al.*, 2002).

## 1.4 Epidemiology

Amebiasis is widely distributed throughout the world, and it is responsible approximately for 100, 000 deaths per year, mainly in Central and South America, Africa, and India, as well as for considerable morbidity manifested as invasive intestinal or extraintestinal clinical manifestations (Walsh, 1986; WHO, 1997; Jackson, 2000). According to World Health Organization, amebiasis is the second most common cause of mortality due to protozoan parasitic infection after malaria (WHO, 1997).

The global estimation of amebiasis was made in 1986, based on a retrospective analysis of the existing literatures, and it was suggested that approximately 500 million people to be infected with *E. histolytica* worldwide (Walsh, 1986). Our understanding of the epidemiology of amebiasis, however, has changed tremendously since the discovery that the organism once called *E. histolytica* on the basis of its morphology is, in fact, composed of two genetically distinct species: potentially invasive *E. histolytica* and non-invasive *E. dispar* (Diamond & Clark, 1993). It is now well recognized that many of the formerly estimated 500 million individuals infected with *Entamoeba* are colonized by *E. dispar*, never associated with amebic disease, or mucosal invasion even in patients with AIDS (Allason-Jones *et al.*, 1986; Reed *et al.*, 1991). Therefore, most of the previous data on the worldwide distribution of *E. histolytica* are of limited value.

*E. histolytica/E. dispar* infections are endemic in most tropical climates, in the developing world. Antibody prevalence rates (reflecting past or present infection) exceed 50 % (Chouduri *et al.*, 1991; Caballero-Salcedo *et al.*, 1994), or it could reach as high as 80 %

by the age of 15 years in some tropical countries with poor sanitary conditions (Hossain *et al.*, 1983). Although such high number of infection rate could be due to the crude antigen used, nevertheless it gives a rough picture of the true magnitude. Therefore, keeping in mind the current two species concept, it is believed that instead of 500 million people, amebiasis could directly affect over 50 million people worldwide, causing loss of manpower, and subsequent economic damage (Jackson, 2000).

Various surveys and routine diagnosis in Ethiopia indicate that amebiasis is one of the most widely reported diseases (Kloos & Tesfayohannes, 1993). It is generally believed to be considerably associated with complaints of diarrhea, particularly dysenteric, leading to indiscriminate treatment with metronidazole, an easily available anti-protozoan drug. A prevalence of amebiasis as high as 55 % was reported in a survey conducted among Saysay indigenous population, in the Blue Nile gorge (Torrey, 1965). A survey on nutrition, in 5 administrative regions of the country, indicates 30 % of infection with what was then called "*E. histolytica*" and the prevalence was reported to be highest (59 %) in one of the border towns, in the Eastern part of Ethiopia (Anon., 1959). In another survey of 50 communities, covering the central plateau of Northern Ethiopia, the parasite was reported in 94 % of the communities, with prevalence rate ranging from 3 % to 55 %. Among the examined school children, 18.9 % were carriers (McConnell & Armstrong, 1976).

Prevalence of "*E. histolytica*", in Gondar, was reported as 1.5 % out of 1203 students sampled, whereas it was much higher (12.3 %) in the general population (Wang, 1965). Analysis of three-years medical admissions record to Gondar Hospital revealed 2.5 % "amebic dysentery" and 1.5 % "amebic liver abscess" out of 11750 admissions (Molineaux, 1966). There was a report of a more alarming figure of 82 % infection

prevalence of "*E. histolytica*" among food handlers at the former Haile Sellassie I Hospital in Addis Ababa, after repeated stool examination (Tsega & Nadew, 1972). More recently a 24.6 % prevalence of *E. histolytica*/*E. dispar* was reported among employees of Akaki Fiber Factory and Wonji Sugar Estate, with a probable association of amebic and HIV infections (Fontanet *et al.*, 2000).

The main diagnostic method in Ethiopia, in all surveys and in the routine diagnostic set-ups, is microscopic examination of wet smears of fresh stool specimens for motile trophozoites, or formol-ether concentration for the characteristic quadrinucleated cysts of "*E. histolytica*". What used to be considered a single species of "*E. histolytica*" on the basis of its morphology alone, however, is composed of two genetically distinct species (WHO, 1997). Microscopy is unsuitable as screening techniques for epidemiological studies, and for patient care as well, since these two species are morphologically indistinguishable (Stanley, 2003), except when the trophozoite is seen engulfing red blood cells (Gonzalez-Ruiz *et al.*, 1994). Recent work indicates that the majority of the trophozoites and cysts reported belong to the non-invasive *E. dispar*, even though past epidemiological studies have erroneously always considered the two organisms together (Diamond & Clark, 1993; Jackson, 2000). Moreover, dysentery due to pathogens such as shigella or campylobacter could easily be misdiagnosed as amebic colitis if microscopy is the sole diagnostic criterion (Stanley, 2003). This is likely to be the case in Ethiopia as well.

## 2. STATEMENT OF THE PROBLEM

As almost all surveys, previously done, relied on stool analysis by microscopy, there is no reliable data on the epidemiology of *E. histolytica* in Ethiopia. It is not only in Ethiopia, but also in the world in general that the current epidemiology of amebiasis is confusing, mainly because of the recently appreciated distinction between *E. histolytica* and *E. dispar*. Until relatively recently, *E. histolytica* and *E. dispar* were not differentiated, and infection with either of the two species was referred to as "amebiasis", resulting in an overestimation of the true prevalence. This fact is well illustrated by one of the highest prevalences (55 %) of intestinal amebiasis reported from the Blue Nile gorge, Western Ethiopia (Torrey, 1965).

The problem lies in the laboratory identification of the parasite, and in the clinical recognition of the disease. Microscopy, apart from its inability to distinguish the two morphologically identical species, is subjective. Trophozoites of other intestinal protozoa are wrongly identified as "*E. histolytica*" and the misidentification of leukocytes as *E. histolytica* has also been reported to be common (Walsh, 1986; Bruckner, 1992). On clinical diagnosis, too, there is a great tendency to associate all dysenteries, not proved otherwise, with amebic infection. Clinical diagnosis of amebiasis is difficult because of the non-specific nature of symptoms. It is easily confused with bacillary dysentery caused by *Shigella* spp, *Salmonella typhi*, *Campylobacter jejuni*, *Yersinia enterocolitica*, or enteroinvasive *Escherichia coli*, which are associated with grossly bloody or heme positive stools (Patel & DeRider, 1989; Martinez-Palomo & Espinoza-Cantellano, 1999).

This inaccurate practice continued despite the recognition a long time ago that dysentery with or without the presence of *Entamoeba* spp trophozoites cannot be a criterion for accurate diagnosis of intestinal amebiasis (Elsdon-dew, 1968). The World Health Organization recommends that *E. histolytica* should be specifically identified and if present, treated; but if only *E. dispar* is identified, treatment is unnecessary (WHO, 1997). In spite of the recommendation, infection with "*E. histolytica*" still features top in the annual reporting of most hospitals and clinics in Ethiopia, because of erroneous diagnostic practices. This has resulted in a widespread use of anti-amebic drugs.

Surveys that determine prevalence of amebiasis by examining stools predominantly measure *E. dispar*, as this species is more common (Gathiram & Jackson, 1987; Haque *et al.*, 1997). Serologic surveys, on the other hand, reflect the occurrence of *E. histolytica* infection, since *E. dispar* infection does not result in a positive serologic test (Jackson *et al.*, 1985; Ravdin *et al.*, 1990). Unfortunately, even a rough idea of the true prevalence of the disease is not possible because of no seroepidemiological survey of amebiasis has ever been done in Ethiopia.

In Ethiopia, no attempt is made to differentiate cysts and trophozoites of morphologically identical *E. histolytica* and *E. dispar*, because diagnosis is based entirely on microscopical examination of fresh stool specimens. The only survey, which tried to do species-specific diagnosis, was that of Gatti *et al.* (1998) in Wonji area, Central Ethiopia. They found two isolates, with an *E. histolytica* and 27 isolates with *E. dispar* zymodeme out of 29 cultured amebic isolates, from 123 study participants suspected for intestinal amebiasis. Apart from this, very little information is available on the prevalence of the two species.

The unreliability of data, collected on the distribution of *E. histolytica* in Ethiopia, will make it appropriate to assess the situation for better estimates of the burden of true intestinal amebiasis by using improved diagnostic methods. These methods, such as polymerase chain reaction (PCR) and coproantigen detection enzyme linked immunoabsorbent assay (ELISA), have been shown to be highly sensitive and specific. Reliable epidemiological information about the magnitude of amebiasis is vital for the clinical and public health management of the disease. The need for reliable diagnostic methods that would provide correct epidemiological information is also relevant in view of the recent advances in amebiasis vaccine development (Stanley, 1997; Huston & Petri, 1998).

### **3. AIMS OF THE STUDY**

#### **General Objective**

To evaluate the widespread impression that amebiasis is a common symptomatic intestinal infection in Ethiopia.

#### **Specific Objective**

- 3.1. To determine the possible correlation between routine microscopic diagnostic reports of amebiasis and diarrheal disease in the study populations.
- 3.2. To determine the species-specific prevalence of *E. histolytica* and *E. dispar* among the study populations.
- 3.3. To determine the possible association of *E. histolytica* and *E. dispar* infections with HIV infection.

## **4. MATERIALS AND METHODS**

### **4.1. Study Subjects**

#### **4.1.1. Cohort participants**

The Ethiopian-Netherlands AIDS Research Project (ENARP) cohort started in 1997 among the Wonji Sugar Estate and Akaki Fiber Factory workers (Fontanet & Woldemichael, 1999). Wonji is 110 kms and Akaki is 25 kms away from Addis Ababa. Until 2001, a total of 1679 individuals joined the cohort study from both factories. After informed consent is obtained, participants get counselling for HIV testing, provide information on socio-demographic characteristics, and sexual behaviours, medical history, and provide blood and stool for various laboratory analysis. The same procedures are repeated during regular follow-up visits every six months.

#### **4.1.2. Amebic liver abscess: A retrospective study**

A 20-year retrospective study, from 1982 to 2002, was conducted using clinical records of patients admitted to the Medical Wards of Tikur Anbessa Hospital, Addis Ababa, Ethiopia, because of liver abscess. Four fifth year medical students of Addis Ababa University reviewed all medical record books, discharge summaries, and death certificates of patients admitted in the Medical Wards over the specified period of time. In addition, patients' charts of all suspected liver abscess cases were retrieved from the archive of the Hospital and they were reviewed, using their card numbers.

The diagnosis of amebic liver abscess was based on clinical symptoms and signs such as weight loss, fever, abdominal pain, tenderness, ultrasound results (reduction in abscess

size), and a good response to therapy with metronidazole, as shown by disappearance of clinical symptoms and signs. Demographic data such as age, sex, place of origin, clinical features including duration, vital signs, physical findings and laboratory data, ultrasound, chest x-ray, outcome of treatment and complications were sorted out from the individual medical cards and were recorded in a pre-designed questionnaire.

#### **4.1.3. Diarrheal patients**

This study was carried out between April and December 2001 at the two cohort sites in Wonji and Akaki. Patients enrolled were either participants in the cohort or their family members. The entry criterion was the patients' complaint of diarrhea, for which he or she presented to the cohort physicians. Each patient submitted a single stool specimen for parasitological examination.

#### **4.1.4. Amebiasis in school children and prisoners**

The fecal samples investigated (one/subject) came from 772 apparently healthy individuals who live in various regions of Ethiopia. The subjects were either children attending one of the three primary schools or inmates of one of the three prisons (Table 14 & 15). The schools and prisons investigated were all in areas where, according to the records of local hospitals or the results of previous parasitological surveys based on microscopical diagnosis, there was a relatively high prevalence of intestinal infection with *E. histolytica/E. dispar*.

#### 4.1.5. Cases of suspected clinical amebiasis

From January- June 2003, experienced technicians from 8 different hospitals and 12 health centers in different parts of the country were asked to preserve stool specimens from patients in whom RBC-engulfing trophozoites were found. Prior to collection of such specimens, all collaborating technicians were briefed on the problems and existence of genetically distinct, but morphologically identical species. It was explained to all of them that true *E. histolytica* infection could only be morphologically recognized on the basis of finding RBC-containing trophozoites. All laboratories involved preserved samples thought to contain RBC-engulfing trophozoites by mixing in absolute ethanol (2 ml/g of faeces) and they were sending it to ENARP laboratory for DNA isolation. Confirmation was achieved through real-time PCR based on the small subunit ribosomal RNA gene sequences for *E. histolytica* and *E. dispar* as described elsewhere (Verweij *et al*, 2004).

#### 4.2. Stool sample Collection

Stool specimen was collected from cohort participants for *E. histolytica* diagnosis during their regular follow-up visits of every six months. Fresh stool specimens were examined with direct saline for motile trophozoites. Part of the sample was preserved in Sodium-acetic-acid-formalin (SAF) for formol-ether concentration technique and additional stool specimen was directly freezed in an eppendorf tube and kept at  $-20^{\circ}$  C till DNA extraction. Final diagnosis was achieved with PCR-SHELA according to Verweij (2000b). A trained technician for its consistency and the presence of blood or mucus macroscopically inspected each sample. Intestinal parasites were identified by the

following methods: direct saline and iodine for any motile trophozoites and cysts. Additional stool specimen was prepared in diluent for fecal antigen detection ELISA. For each patient standard questionnaire, containing information on symptom and treatment, was provided which the examining physician completed.

Systematic random sampling was used to select 10 % of healthy prisoners/school children at each site, and a single stool specimen was provided in a clean and labeled container. Part of each specimen was preserved in Sodium-acetic-acid-formalin (SAF), for later microscopical examination, and mixing with absolute ethanol (approximately 2 ml/g faeces), and storage preserved the rest, at 4<sup>0</sup> C, for DNA isolation. Final diagnosis was achieved through real-time PCR based on the small subunit ribosomal RNA gene sequences for *E. histolytica* and *E. dispar* as described elsewhere (Verweij *et al*, 2004a).

### **4.3. Laboratory Methods**

#### **4.3.1. Microscopy**

Fresh stool samples were examined for the presence of blood and mucus, visible to the naked eye for appearance and consistency. Smears of faeces were made in 0.9 % saline and Lugol's iodine and examined by microscopy at 40 times magnification for the presence of moving trophozoites and cysts of *Entamoeba* spp. In addition, stool samples were concentrated using formal-ether concentration technique for identification of cysts and helminth ova (Cheesbrough, 2001). Differentiation of the various *Entamoeba* spp cysts was done by size measurement with ocular micrometer along with use of nuclear and morphological characteristics.

## **4.3.2. DNA isolation**

### **4.3.2.1. Direct freezed faeces**

One gram of faeces was suspended in 2 ml of 2 % pvpp (polyvinylpolypyrrolidone), and was stored at  $-20^{\circ}\text{C}$  till DNA extraction. An aliquot of 200  $\mu\text{l}$  of the suspension was separated in an eppendorf tube, and was heated in heatblock at  $100^{\circ}\text{C}$  for 10 minutes. After sodium dodecyl sulphate-proteinase K treatment with an equal volume (2 hours at  $55^{\circ}\text{C}$ ), DNA was isolated with QIAamp Tissue Kit spin columns (QIAGEN, Germany) (Verweij *et al.*, 2001). Adding 400  $\mu\text{l}$  AL Buffer, the suspension was mixed thoroughly by vortexing, and it was incubated at  $70^{\circ}\text{C}$  for 10 minutes. The supernatant was transferred to an eppendorf containing 400  $\mu\text{l}$  absolute ethanol after a short spin, and it was mixed thoroughly by vortexing. A numbered QIAamp spin column was placed in a 2 ml collection tube, and the mixture with absolute ethanol was applied to the spin column without moistening the rim, and it was centrifuged at 10000 rpm for 1 minute. Adding 500  $\mu\text{l}$  of AW1 buffer and centrifuging at 10000 rpm for 1 minute achieved the first washing step. Emptying the collection tube, adding 500  $\mu\text{l}$  of AW2 buffer, and centrifuging 3 minutes at full speed completed the washing step. The DNA was eluted with 200  $\mu\text{l}$  AE buffer (10 mM Tris.Cl; 0.5 mM EDTA; pH 9.0) after centrifugation at 10000 rpm for 1 minute.

### **4.3.2.2. Absolute ethanol preserved faeces**

Approximately 2 ml/ g faeces was preserved in absolute ethanol and stored at  $4^{\circ}\text{C}$  till DNA extraction. The procedure for isolating DNA in this case is exactly the same as directly

frozen faeces, except that there is a need for washing the ethanol initially. About 250 µl of an ethanol-faeces suspension was applied to a clean eppendorf tube, and was centrifuged for 1 minute at 10000 rpm. The ethanol was removed with a micropipette, and the pellet was washed with 750 µl of PBS by centrifuging for 1 minute at 10000 rpm. Removing the PBS with micropipette, the pellet was resuspended with 200 µl of 2 % pvpp as if it was fresh stool specimen. The rest of the step is the same as described above for the direct-frozen faeces (4.3.2.1).

### **4.3.3. Polymerase Chain Reaction- Solution Hybridization Enzyme Linked Immuno Assay (PCR-SHELA)**

Amplification of DNA samples for the cohort participants and their families was achieved using polymerase chain reaction and soluble hybridization enzyme linked immuno assay (PCR-SHELA). On the other hand, real-time PCR based on the small subunit ribosomal RNA gene sequences for *E. histolytica* and *E. dispar* was used for DNA samples from school children, prisoners, hospital-based diarrhea study, and suspected RBC-engulfing trophozoites.

#### **4.3.3.1. DNA Amplification**

DNA amplification and colorimetric detection of the product was carried out as described previously (Aguirre *et al.*, 1995; Verweij *et al.*, 2000b). Briefly, two PCR were performed on each DNA sample, one with *E. histolytica*- and the other with *E. dispar* – specific primers. One primer of each pair was labeled with digoxigenin (DIG).

The primers for *E. histolytica* were P1 5<sup>1</sup> TCA AAA TGG TCG TCG TCT AGG C 3<sup>1</sup> (forward) and P2 5<sup>1</sup>CAG TTA GAA ATT TTG ACT TGT A 3<sup>1</sup> (reverse) while for *E.*

*dispar* they were NP1 5<sup>1</sup> GGA TCC TCC AAA AAA TAA AGT TT 3<sup>1</sup> (forward) and NP2 5<sup>1</sup>ACA GAA CGA TAT TGG ATA CCT AGT A 3<sup>1</sup> (reverse). A PCR mix was prepared for 10 stocks of 475 µl for *E. histolytica* and *E. dispar*, respectively by mixing 500 µl 10X supertaq buffer, 40 µl 100X dNTP mix, 12.5 µl 100X primer 1 and primer 2, respectively, and 4175 µl distilled water. It was mixed well and dispensed in 475 µl aliquots and stored at -20°C until used.

For each PCR-mix before amplification, one µl Super Taq polymerase (15units/µl)/ 475 µl was added, and was mixed well. Dispensing in 38 µl aliquots in 0.2 ml thin walled PCR tubes, 2 µl of DNA solution was added. The PCR amplification condition was 2 minutes at 94°C for denaturation; 35 cycles for 30 seconds at 94°C, 30 seconds for 60°C, and 30 seconds for 70°C; final extension was for 2 minutes at 72°C. The PCR product was visualized on 2 % agarose gel. In every amplification run, positive controls for *E. histolytica* (HM1) and *E. dispar* (Saw 167) together with non-template (water) controls were included. Microscopically positive samples, randomly selected, in which no specific DNA was amplified, were checked for inhibition by spiking those samples with *E. histolytica* DNA and subsequent specific PCR amplification.

#### **4.3.3.2. Solution hybridisation enzyme linked immuno assay (SHELA) for detection of *E. histolytica* and *E. dispar* PCR products**

Colorimetric detection of the PCR product was achieved by hybridising with 5 pmol of 5<sup>1</sup>-biotin- conjugated probes specific for *E. histolytica* and *E. dispar*, respectively. The specific probes sequences were p3bio 5<sup>1</sup>GAG GTT CTT AGG AAA TCG AAA A3<sup>1</sup> (*E. histolytica*) and np3bio 5<sup>1</sup>GGT GAG GTT GTA GCA GAG ATATT 3<sup>1</sup> (*E. dispar*).

Denaturation (10 minutes at 99°C) and hybridization (60 minutes at 60°C) in the PCR machine was done after adding 1 µl biotinlated probe solution (5 pmol/µl) to 20 µl of PCR product. After hybridization, 200 µl PBS/Tween solution (0.035M, pH=7.6) was added for dilution and the reaction was placed on ice. Prior to hybridization, a NUNC Maxisorp titration plate (MaxiSorp™) was coated with 100 µl coating solution per well (1000 µg/ml streptavidin in 10 ml 1X SSC buffer), and was incubated overnight at 4°C. The plate was washed 3 times with 400 µl PBS/Tween. Every well was filled completely with postcoating solution (1 gm BSA /100 ml PBS plus 200 µl Salmon Sperm DNA, 10 ng/ml solution), and was incubated at room temperature for one hour. The plate was washed 3 times with 400 µl PBS/Tween. The diluted samples (100 µl) after hybridization per well were added in duplicate to the coated and washed titration plate, and in the blank row only 100 µl PBS/Tween was added. The plate was covered and incubated at room temperature for one hour. It was washed with 200 µl PBS/Tween (to avoid overspilling) before 3 times washing with 400 µl PBS/Tween and 100 µl of conjugate solution per well was added. It was covered and incubated for one hour at room temperature before washing 3 times with PBS/Tween and one time with PBS. Finally 100-µl p-NPP substrate solution (10 mg/10 ml DEA buffer) was added. Absorbance was recorded at 405 nm after incubation for one hour at room temperature in the dark.

#### 4.3.4. Real-Time PCR

The real-time PCR described by Verweij *et al.* (2004) was used to amplify, detect, and distinguish the SSU-rRNA sequences of *E. histolytica* and *E. dispar*. The forward (Ehd-

239F; 5'-ATT GTC GTG GCA TCC TAA CTCA-3' N) and reverse (Ehd-88R; 5'-GCG GACGGC TCA TTA TAACA-3'N) primers used amplify a 172-bp fragment inside the SSU-rRNA gene, common to the two species. Two minor-groove-binding (MGB) TaqMan<sup>®</sup> probes, one specific for *E. histolytica* (histolytica-96T; VIC<sup>™</sup> -5'-TCA TTG AAT GAA TTG GCC ATTT-3'-non-fluorescent quencher; Applied Biosystems, Foster City, CA), and one specific for *E. dispar* (dispar-96T; FAM-5'-TTA CTT ACA TAA ATT GGC CAC TTTG-3'-non-fluorescent quencher; Applied Biosystems), were then used to distinguish the two species. Other PCR primers [PhHV-267s, forward (5'-GGG CGA ATC ACA GAT TGA ATC-3') and PhHV-337, reverse (5'-GCG GTTCCA AAC GTA CCAA-3')], and a double-labeled detection probe (PhHV-305tq; Cy5-5'-TTTTTA TGT GTC CGC CAC CAT CTG GATC-3'-Black Hole Quencher 2), all from Biolegio (Malden, The Netherlands), were used to amplify and detect the phocid herpesvirus type-1 (PhHV-1) used as the internal control (Niesters, 2002). Each set of amplification reactions was performed in a 50- $\mu$ l reaction mixture, containing PCR buffer (HotStart Taq master mix; Qiagen), 5 mM MgCl<sub>2</sub>, 25 pmol of each *E. histolytica*/*E. dispar*-specific primer, 15 pmol of each PhHV-1-specific primer, 5 pmol of the *E. histolytica*-specific MGB TaqMan probe, 5 pmol of the *E. dispar*-specific MGB TaqMan probe, 2.5 pmol of the PhHV-1-specific double-labelled probe, and 5  $\mu$ l of the DNA sample.

To the first 6 PCR tubes, 5  $\mu$ l of a standard solution for *E. histolytica* with linearly sloping concentration was made. To the next PCR tubes, 5  $\mu$ l of an *E. dispar* standard solution was applied. For the negative control, 5  $\mu$ l of H<sub>2</sub>O was used, and 5  $\mu$ l each DNA isolates were added to the other tubes. A Bio-Rad I thermocycler (Bio-Rad, Hercules, CA) was set to give 15 min at 95°C followed by 50 cycles, each of 15 s at 95°C, 30 s at 60°C and 30 s

at 72°C. After the 50 cycles, the temperature was kept at 60°C. The fluorescence of the different labels were measured during all the cycles, the in-built software making it visible in graphs. A sample was considered to be false positive if the curve deviated largely from the standard curves. The moment that the fluorescence of a given sample exceeded the marginal value it was indicated with the number of the cycle in which this occurred.

### 4.3.5. Copro-antigen detection

#### 4.3.5.1. *Entamoeba* genus- specific detection ELISA

The *Entamoeba* ELISA test was developed and manufactured by TECHLAB® (Blacksburg VA). It is designed to detect, but not to differentiate the antigens of *E. histolytica* and *E. dispar* in stool specimens, using antibodies to the adhesin of the organism. The microtiter wells contain immobilized polyclonal antibody specific for the adhesin of either *E. histolytica* or *E. dispar*. The fecal specimen is diluted by adding 400 µl diluent either to 400 µl liquid stool or approximately 0.2 g solid stool. One drop of conjugate (mouse monoclonal antibody specific for adhesin from *E. histolytica* and *E. dispar* coupled to horseradish peroxidase) was added to each well. One drop of positive control, 100 µl negative control (i.e., diluent), and 100 µl of diluted fecal specimen were added to the test well. Covering the wells with adhesive plastic sheet, it was incubated for two hours at room temperature. The assay wells were washed five times with diluted wash solution. To all test wells, one drop of substrate A (tetramethylbenzidine) and substrate B (hydrogen peroxide) was added. The wells were incubated at room temperature for 10 minutes, and the reaction was stopped by adding one drop of stop solution (1M sulfuric acid). The conversion of the blue color to yellow color was measured at 450 nm on microplate ELISA reader (Titertek Multiscan; Flow laboratories, McLean, Va.). A specimen was considered

positive for adhesin of *E. histolytica* or *E. dispar* if the OD reading was 0.05, or higher after subtracting the negative control reading. Sensitivity was calculated as the number of true positives divided by number of true positives + number of false negatives (TP/TP+FN); specificity was calculated as the number of true negatives divided by number of true negatives + number of false positives (TN/TN+FP).

#### 4.3.5.2. *E. histolytica* specific ELISA

This test kit is also developed and manufactured by TECHLAB® (Blacksburg VA). The *E. histolytica* ELISA uses antibodies to the adhesin. The microtiter wells contain immobilized polyclonal antibody that binds adhesin of *E. histolytica*/*E. dispar*. The conjugate is a monoclonal antibody-peroxidase specific for *E. histolytica* adhesin. The fecal specimen is diluted by adding 400 µl diluent either to 400 µl liquid stool or approximately 0.2 g solid stool. One drop of conjugate (mouse monoclonal antibody specific for adhesin from *E. histolytica* coupled to horseradish peroxidase) to each well was added. One drop of positive control, 100 µl negative control (i.e., diluent), and 200 µl of diluted fecal specimen were added to the test well. Covering the wells with adhesive plastic sheet, it was incubated for two hours at room temperature. The assay wells were washed five times with diluted wash solution. To all test wells, two drops of substrate (tetramethylbenzidine and peroxide) was added. The wells were incubated at room temperature for 10 minutes and the reaction was stopped by adding one drop of stop solution (1M sulfuric acid). The conversion of the blue color to yellow color was measured at 450 nm on microplate ELISA reader. A specimen was considered positive for adhesin of *E. histolytica* if the reading was 0.05 or higher after the negative control reading has been subtracted.

#### 4.3.6. Serology of amebiasis

The prevalence of antibodies against *E. histolytica* was assayed among the cohort participants by using stored-serum (at  $-20^{\circ}\text{C}$ ). Crude *E. histolytica* antigen and recombinant surface antigen of *E. histolytica* were used for ELISA detection of anti *E. histolytica* IgG.

##### 4.3.6.1. Detection of *E. histolytica* IgG by ELISA using crude antigen

Polysorp (NUNC) microtiter plate was coated with 100  $\mu\text{l}$  antigen solution per well (5  $\mu\text{g/ml}$  HM1 antigen), and was incubated overnight at  $4^{\circ}\text{C}$ . The plate was stored at  $-20^{\circ}\text{C}$ , and it was washed with wash buffer before use (0.035 M PBS pH 7.8). A two fold serial dilution of serum samples was made in assay buffer (0.05 % PBS Tween/BSA 1 %), starting at 1/20, 100  $\mu\text{l}$  per well. It was incubated at  $37^{\circ}\text{C}$  for one hour, and was washed three times with wash buffer. Conjugate solution, rabbit anti human IgG/PO (Dako) in assay buffer, 100  $\mu\text{l}$  per well was added, and incubated at  $37^{\circ}\text{C}$  for 1 hour. The plate was washed three times with wash buffer. Substrate solution (100  $\mu\text{l}$  ABTS  $\text{H}_2\text{O}_2$ ) was added per well, and incubated at room temperature for 15 minutes. Adding 50  $\mu\text{l}$  stop solution stopped the reaction, and absorbance was read at 414 nm. The optical density (OD) value of 1/320 dilution of the positive control was used as the reference value. When the 1/40 OD value of a serum sample was higher than this reference value, the sample was regarded as positive.

#### 4.3.6.2. Detection of *E. histolytica* IgG by ELISA using recombinant surface antigen of *E. histolytica*

Microtiter plate (NUNC-polysorp) was coated with 100  $\mu$ l carbonate buffer, pH 9.5 containing recombinant P1 *E. histolytica* antigen in a dilution of 1:100. Having incubated at 4° C overnight, the plate was stored at -20 ° C. The first column of each plate was incubated with buffer only. Subsequently the plate was washed 3 times with PBS, containing 0.1 % Tween 20. Predilution of each sera (1:20) was made by adding 10  $\mu$ l serum in PBS, containing 3 % milk powder. A second dilution (1:400) was made by diluting the 1:20 dilution with 950  $\mu$ l PBS, containing 3 % milk powder. By adding to each well 100  $\mu$ l of patient sera in a dilution of 1:400, incubation was made at room temperature for 2 hours. The plate was washed 3 times with PBS, containing 0.1 % Tween 20. Incubation at room temperature for two hours was made after adding to each well 100  $\mu$ l of PBS, containing 3 % milk powder and alkaline phosphatase (AP)-conjugated anti-human IgG (1:10000). The plate was washed 3 times with PBS, containing 0.1 % Tween 20. Finally, the plate was incubated with pNPP substrate for one hour at room temperature in the dark and absorbance was read at 405 nm. The absorbance values  $\geq 0.2$  was considered positive for *E. histolytica* antibodies. Incubating two separate wells with each human serum sample made verification of the positive results. One well was coated with the P1 and the other with carbonate buffer only. Subtracting absorbance values from the two wells and values  $\geq 0.2$  were considered positive.

#### **4.3.7 HIV screening and CD4+ and CD8+ T lymphocytes quantification**

HIV-1 screening was performed by Determine (Abott, Japan) and ELISA (Vironostika HIV uni-form II plus O, Biomrieux, Boxtel, NL). All reactive or discrepant results were confirmed by Western blot (HIV Blot 2.2, Genelabs Diagnostics, Singapore).

CD4+ and CD8+ T- lymphocytes were quantified using three-color immunophenotyping using FACSCAN. The immunophenotyping was performed on whole blood. EDTA blood (100 µl) was incubated with combination of PE conjugated CD4+ or CD8+ MoAbs , FITC conjugated CD3 MoAbs and peridynyl chlorophyll-A protein (PercP) conjugated CD45 MoAbs for 20 minutes at room temperature in the dark. Then 450 µl lysing solution (FACSllyse; Becton Dickinson) was added to each tube and incubated at room temperature for 20 minutes in the dark. All molecular antibodies were purchased from Becton Dickinson (San Jose, CA). Acquisition and analysis was done on a FACScan flow cytometer (Becton Dickinson Immunocytometry systems, San Jose, Calif) using cellquest and multitest soft wares. A live gate was set around the lymphocytes in order to acquire a minimum of 2500 cells for analysis.

#### **4.4. Data Analysis**

Statistical analysis was performed with SPSS version 10.0 (SPSS, Chicago, Illinois, USA). Proportions were compared between groups using Chi-square or Fisher's exact test where appropriate; a P value either < 0.05 or 0.01, depending on the level of significance was considered significant.

## 5. RESULTS

### 5.1. Retrospective Analysis of Reported "Amebiasis"

#### 5.1.1 Prevalence of intestinal parasites in Wonji Hospital

The annual report of Wonji Hospital routine diagnostic laboratory was examined for the common protozoan and helminth parasites, starting from 1988 till 1998 (Fig 2). The record showed that in total 154,425 individuals were examined as outpatients and inpatients, on average 14,039 per year. Amebic infection, reported as "*E. histolytica*", was the highest followed by *Ascaris lumbricoides*, while *G. lamblia* and other helminths were reported in less and in varying degree (Fig 2). The yearly distribution of percentage positivity of *E. histolytica/E. dispar* and *G. lamblia* infection was compared (Fig 3). The result, in each year, consistently indicated that amebic infection was reported more than Giardia ( $P < 0.05$ ). The prevalence of *E. histolytica/E. dispar* was steadily increasing (range 24-31 %), except in 1994. *G. lamblia*, on the other hand, was not reported between 1988 and 1991, and all of a sudden it seems on the rise, probably due to problem in record keeping.

Though, *A. lumbricoides* was reported more frequently than the other helminths, there was a continuous decline from 1992 onwards, but greater compared to other helminths every year (Fig 4). There was no significant variation in annual prevalence of Hookworm spp, *Trichuris trichiura* and *Strongyloides stercoralis* reporting in the Hospital. There was a clear rise in *Schistosoma mansoni* prevalence between 1991 and 1994, declining then after.

Intestinal parasites trend by year in Wonji Hospital showed that "*E. histolytica*" was reported on a regular basis, and features top compared to other intestinal parasites. The

prevailing belief that the parasite is responsible for most complaints of diarrhea has led to indiscriminate treatment with the commonly available antiprotozoa drug, metronidazole or tinidazole.

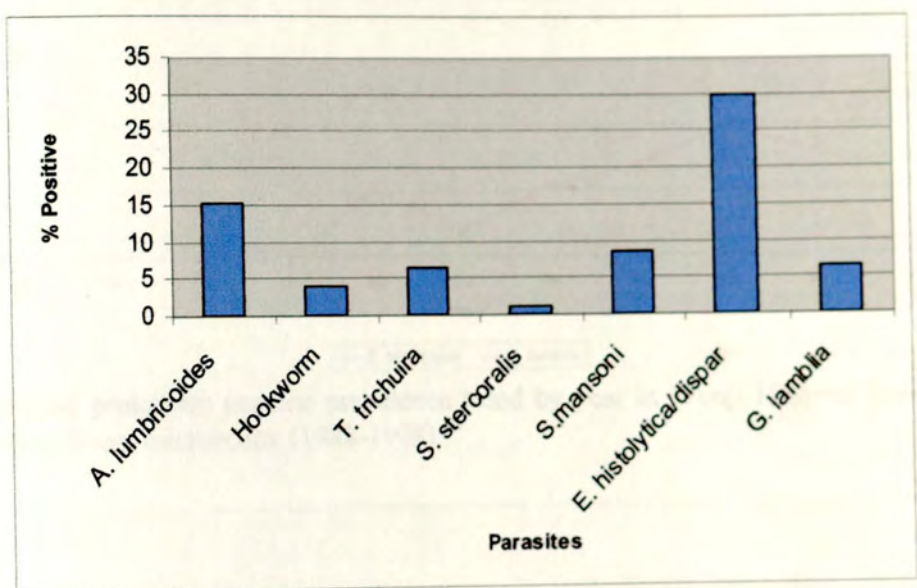


Fig 2. Intestinal parasite prevalence at Wonji Hospital based on routine direct microscopy (1988-1998).

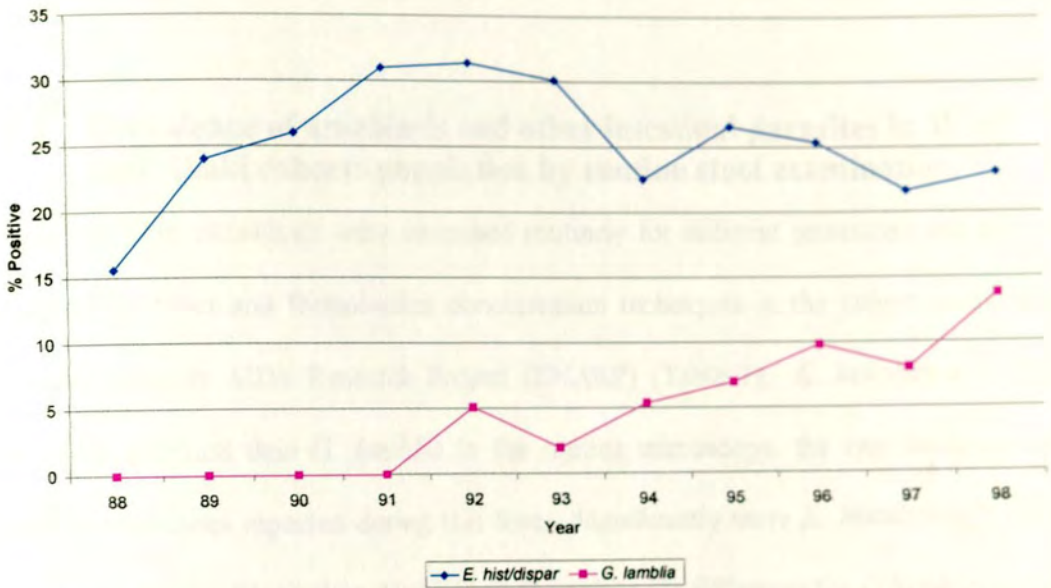


Fig 3. Intestinal protozoan parasite prevalence trend by year in Wonji Hospital based on routine direct microscopy (1988-1998).

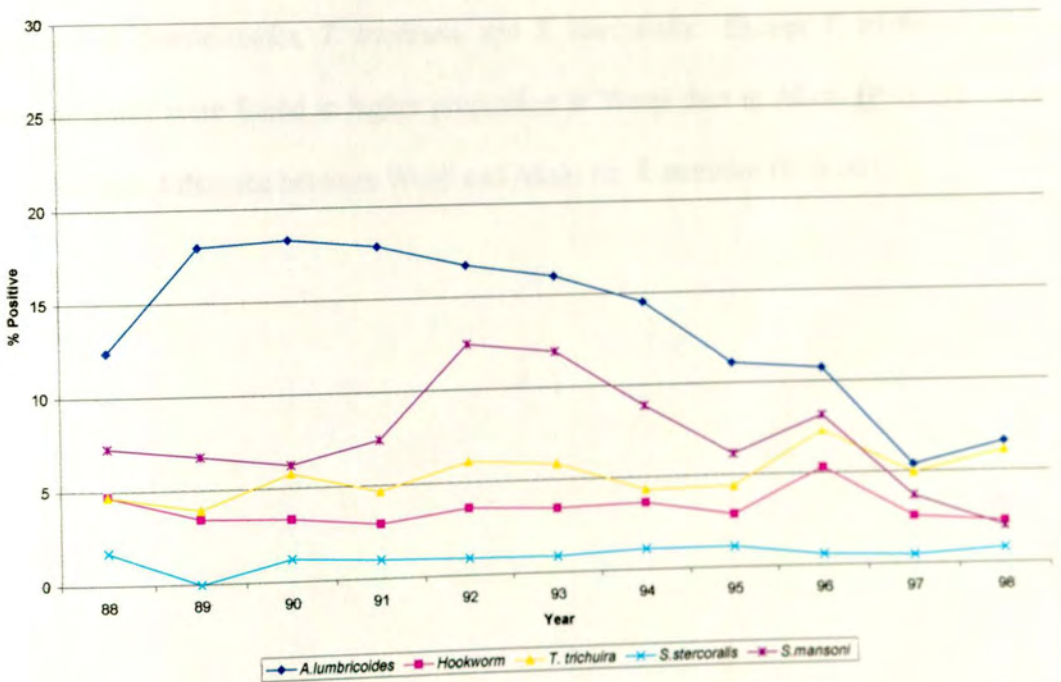


Fig 4. Helminth parasite prevalence trend by year in Wonji Hospital based on routine direct microscopy (1988-1998).

### 5.1.2 Prevalence of amebiasis and other intestinal parasites in Wonji and Akaki cohorts population by routine stool examination

A total of 1236 individuals were examined routinely for different protozoan and helminth parasites by direct and formol-ether concentration techniques in the cohort study of the Ethio-Netherlands AIDS Research Project (ENARP) (Table 1). *E. histolytica/E. dispar* was more common than *G. lamblia* in the routine microscopy, the two being the only protozoan parasites reported during this time. Significantly more *E. histolytica/E. dispar* was reported from Wonji than Akaki ( $P < 0.01$ ), while the difference for *G. lamblia* was not statistically significant ( $P > 0.05$ ). The commonest helminth infections detected in both sites were *A. lumbricoides*, *T. trichiura*, and *S. stercoralis*. Except *T. trichiura*, all the other helminths were found in higher proportion in Wonji than in Akaki ( $P < 0.05$ ). There was significant difference between Wonji and Akaki for *S. mansoni* ( $P < 0.001$ ).

Table 1. Prevalence of intestinal protozoan and helminth infections among 1236 healthy cohort participants of ENARP in Wonji and Akaki at enrolment, as determined by routine direct wet mount and concentration microscopy (1997 - 1999).

|                              | Wonji (N=472) |      | Akaki (N=764) |      | Total (N=1236) |      |
|------------------------------|---------------|------|---------------|------|----------------|------|
|                              | No. Positive  | %    | No. Positive  | %    | No. Positive   | %    |
| <b>PROTOZOA</b>              |               |      |               |      |                |      |
| <i>E. histolytica/dispar</i> | 117           | 27.8 | 59            | 7.7  | 176            | 14.2 |
| <i>Giardia lamblia</i>       | 17            | 3.6  | 18            | 2.4  | 35             | 2.8  |
| <b>HELMINTHS</b>             |               |      |               |      |                |      |
| <i>A. lumbricoides</i>       | 105           | 22.3 | 156           | 20.4 | 261            | 21.1 |
| <i>T. trichuira</i>          | 40            | 8.5  | 111           | 14.5 | 151            | 12.2 |
| <i>S. stercoralis</i>        | 57            | 12.1 | 59            | 7.7  | 116            | 9.4  |
| <i>S. mansoni</i>            | 41            | 8.7  | 4             | 0.5  | 45             | 3.6  |
| <i>Taenia spp</i>            | 12            | 2.5  | 11            | 1.4  | 23             | 1.9  |
| <i>Hookworm spp</i>          | 17            | 3.6  | 1             | 0.1  | 18             | 1.5  |
| <i>H. nana</i>               | 5             | 1.1  | 5             | 0.7  | 10             | 0.8  |
| <i>E. vermicularis</i>       | 3             | 0.6  | 3             | 0.4  | 6              | 0.5  |

## 5.2. Retrospective Assessment of Patients with Liver Abscess

On average 5854 patients per year, a total of 117,080 patients during the study period, were admitted and treated in the Medical Wards of Tikur Anbessa Hospital (Table 2). Based on the information found in the Hospital record books, discharge summaries, and death certificates, only 47 cases of liver abscesses were admitted and treated between 1982 and 2002. The incidence of liver abscess is 2.35 in 5854 cases per year, or 40.1 per 100,000 cases hospitalized in the medical wards.

Table 2. Cases of liver abscess at Tikur Anbessa Hospital over 20 years among admitted patients based on Hospital record, discharge summaries, and death certificates (1982-2002).

| Variables                     | Number of subjects |
|-------------------------------|--------------------|
| Total Admitted Patients       | 117,080            |
| Admission /Year               | 5854               |
| Liver Abscess                 | 47                 |
| Amebic                        | 35                 |
| Pyogenic                      | 3                  |
| Undetermined                  | 9                  |
| Dark brown pus(Anchovy paste) | 2                  |

Among all cases of liver abscess, the most common admission diagnosis was amebic liver abscess (74 %) followed by pyogenic abscess (6 %) and in 9 cases (19 %), the aetiology of the liver abscess remained undetermined (Table 3). Out of the four cases for which liver

aspiration was performed, two turned out to be dark brown (chocolate), which is typical of amebic liver abscess. The cumulative incidence of possible amebic liver abscess can be estimated to be 30.0 per 100,000 admissions at the Medical Wards of the Hospital (35 per 117,080). The cumulative incidence of pyogenic liver abscess is 7.7 per 100,000 admissions in 20 years (9 per 117,080 admissions). As far as discharge diagnosis was concerned, the figures were very similar to the admission diagnosis such that 36/47 (77 %) cases were amebic liver abscess. Although there was one fatal case, the death was not related to the amebic liver abscess (Table 3).

Table 3. Admission and discharge diagnosis of liver abscess at Tikur Anbessa Hospital based on the Hospital record, discharge summaries and death certificates (1982-2002).

|           | Admission Diagnosis (%) |          |       | Discharge Diagnosis (%) |      |        |          |
|-----------|-------------------------|----------|-------|-------------------------|------|--------|----------|
|           | ALA*                    | Pyogenic | LA*   | ALA                     | Dead | NM*    | Total(%) |
| 1982-1986 | 11(79)                  | 2(14)    | 1(7)  | 9(64)                   | 0    | 5(36)  | 14(30)   |
| 1987-1991 | 3(43)                   | 1(14)    | 3(43) | 6(86)                   | 0    | 1(14)  | 7(15)    |
| 1992-1996 | 12(80)                  | 0        | 3(20) | 14(93)                  | 0    | 1(7)   | 15(32)   |
| 1997-2002 | 9(82)                   | 0        | 2(18) | 7(64)                   | 1(9) | 3(27)  | 1(23)    |
| Total     | 35(74)                  | 3(6)     | 9(19) | 36(77)                  | 1(2) | 10(21) | 47(100)  |

\* ALA, Amebic Liver Abscess; LA, Liver Abscess; NM, status not mentioned

The Hospital cards were traced back from the archive only for 16 out of 47 patients, all of them admitted from 1995 till 2002 (Table 4). There were only two cases (2/16) with microscopy report of "*E. histolytica*" trophozoites in the stool. For the remaining 31 cases no records were available. The admission and discharge diagnosis of these 16 patients

were very similar to the total 47 from the record book alone. The mean age of the amebic liver abscess patients was 36 years (range 14-66) and there were more females (56 %) than males (44 %). The most common complaints were abdominal pain in the right upper quadrant pain (88%), fever (75%), hepatomegaly (69 %), night sweating (63 %), cough (56 %), and poor appetite (50 %) (Table 4). All sixteen patients were diagnosed on the basis of clinical symptoms and ultrasound findings, followed by improvement with metronidazole treatment. The right liver lobe was most commonly affected (94 %), whereas the left lobe was affected in two cases out of which one case had involvement of both lobes. A single abscess was recorded among 69 % of cases, while multiple abscesses were documented in 31 %.

Chest radiography abnormalities were noted in 13 of the 16 patients (81 %). Fever (75%), right upper quadrant pain (88%), tenderness and dullness to percussion (54 %) and decreased air entry in the right post lung fluid (46 %) were the most common physical findings recorded. The abnormalities included were elevation of the right hemidiaphragm, point tenderness on right lateral chest, right side pleural effusion or atelectasis, and right-sided chest pain with dry cough in the range of 8 % to 23 %. A wide variation and inconsistent recording was observed for clinical chemistry laboratory results of the 16 patients for whom the Hospital card was available. Most of the parameters were elevated i.e., erythrocyte sedimentation rate, creatinine, SGOT, SGPT, bilirubin total, bilirubin direct, and alkaline phosphatase.

Table 4. Percentage of cases of *E. histolytica*/*E. dispar* found by direct microscopy compared to common clinical signs and symptoms among admitted liver abscess cases in Tikur Anbessa Medical Wards for whom the Hospital card was available (1995-2002).

|                           | No. of ALA cases | <i>E.histolytica</i> / <i>E.dispar</i> (%) |
|---------------------------|------------------|--|
| SYMPTOM                   |                  |  |
| Right upper quadrant pain | 14               | 14.3                                       |
| Fever                     | 12               | 16.3                                       |
| Hepatomegaly              | 11               | 0  |
| Night sweating            | 10               | 10.6                                       |
| Cough                     | 9                | 11.1                                       |
| Nausea/Vomitting          | 9                | 22.2                                       |
| Poor appetite             | 8                | 12.5                                       |
| Weight loss               | 7                | 0  |
| Epigastric pain           | 4                | 8.3  |
| Abdominal cramps          | 2                | 0  |
| Splenomegaly              | 2                | 0  |
| ULTRASOUND                |                  |  |
| Right lobe affected       | 15               | 6.7  |
| Left lobe affected        | 2                | 50   |
| Single abscess            | 11               | 18.2                                       |
| Multiple abscess          | 5                | 0  |

ALA = Amebic liver abscess

### 5.3. Misdiagnosis/Overdiagnosis of Amebiasis by Microscopy

#### 5.3.1 Cohort participants

The routine microscopy data collected from Wonji and Akaki cohorts (Table 5) and the eleven-year annual report from Wonji Hospital (Fig 2) suggest that there might be a high transmission of "*E. histolytica*". Further report by Fontanet *et al.* (2000) in Wonji, for possible interaction of *E. histolytica*/*E. dispar* with HIV, made it necessary to examine the situation more closely. Therefore, differential microscopy diagnosis of various protozoan parasites was established in Wonji and Akaki for better morphological characterization, by measuring the cysts and trophozoites with ocular micrometer, separate from the routine practice.

Microscopy revealed various protozoan parasites from 225 apparently healthy individuals, when they report for their regular six monthly visit to each cohort study site (Table 5). *Entamoeba coli* (33.8 %), *Blastocystis hominis* (31.6 %), and *E. histolytica*/*E. dispar* (24.9 %) were more frequently encountered. The number of individuals infected with *E. coli*, *B. hominis*, and *E. hartmanni* were significantly higher ( $P < 0.05$ ) in Wonji than in Akaki, while there was no statistical difference for other protozoans including *E. histolytica*/*E. dispar* ( $P > 0.05$ ).

The specific PCR-SHELA, however, did not reveal any *E. histolytica* infection, while there were 41 (18.2 %) *E. dispar* cases (Table 5). There was a large discrepancy between the microscopy results of *E. histolytica*/*E. dispar* and PCR-SHELA. Overall, by microscopy 56 (24.9 %) *E. histolytica*/*E. dispar* were reported, while PCR confirmed only 17/56 (36.9

%) cases as *E. dispar*, and the remaining 39/56 (69.6 %) turned out negative either for *E. histolytica* or for *E. dispar* specific PCR (Table 6). On the other hand, additional 24 (14.2 %) *E. dispar* were found by the PCR that were missed by microscopy. The sensitivity of microscopy in detecting *E. histolytica/E. dispar* was 41.5 %, while the specificity was 78.8 % (Table 6). The positive predictive value for *E. dispar* by microscopy was rather poor (30.4 %) while the negative predictive value was relatively higher (86 %).

Table 5. Intestinal protozoan parasite prevalence among 225 healthy cohort participants from Wonji and Akaki, as determined by microscopy with direct and formol-ether concentration and specific *E. dispar* prevalence as determined by PCR-SHELA (May-November 2000)

| Protozoans detected             | Wonji (n = 110) |      | Akaki (n = 115) |      | Total (n = 225) |      |
|---------------------------------|-----------------|------|-----------------|------|-----------------|------|
|                                 |                 | %    |                 | %    |                 | %    |
| <i>E. coli</i>                  | 53              | 48.2 | 23              | 20.0 | 76              | 33.8 |
| <i>B. hominis</i>               | 44              | 40.0 | 27              | 23.5 | 71              | 31.6 |
| <i>E. histolytica/E. dispar</i> | 32              | 29.1 | 24              | 20.9 | 56              | 24.9 |
| <i>E. hartmanni</i>             | 18              | 16.4 | 9               | 7.8  | 27              | 12.0 |
| <i>C. mesnili</i>               | 9               | 8.2  | 13              | 11.3 | 22              | 9.8  |
| <i>G. lamblia</i>               | 6               | 5.5  | 13              | 11.3 | 19              | 8.4  |
| <i>I. butschlii</i>             | 6               | 5.5  | 10              | 8.7  | 16              | 7.1  |
| <i>E. nana</i>                  | 4               | 4.0  | 7               | 6.0  | 11              | 5.0  |
| <i>E. dispar</i> *              | 23              | 20.9 | 18              | 15.7 | 41              | 18.2 |

\* Detected by PCR-SHELA

Table 6. Comparison of microscopy finding of *E. histolytica*/*E. dispar* with specific PCR-SHELA finding of *E. dispar* on stool samples of 225 cohort participants from Wonji and Akaki (May-November 2000).

|            | PCR-SHELA |          |       |
|------------|-----------|----------|-------|
|            | Positive  | Negative | Total |
| Microscopy |           |          |       |
| Positive   | 17        | 39       | 56    |
| Negative   | 24        | 145      | 169   |
| Total      | 41        | 184      | 225   |

### 5.3.2 Diarrheal patients

Of the 246 patients included in this study, 164 (66.7 %) were males and 82 (34 %) were females (Table 7). Their age was between 1 to 68 years (median = 30 years); 181 (73.6 %) were adults between 19-68 years. Among the cohort participants, 34 out of 155 (21.9 %) were positive for HIV. The family members (91 individuals) did not go through HIV screening. Microscopy reporting of *E. histolytica*/*E. dispar* appears to be slightly more in Wonji, in older age groups (age >16), in females and in HIV positives, but the difference was not statistically significant ( $P>0.05$ ). Overall, 40/246 (16.3 %) had received antiprotozoan treatment, mainly metronidazole or tinidazole during the two months before the stool samples were submitted. In patients with complaints of diarrhea, the prevalence of *E. histolytica*/*E. dispar* identified by microscopy was not different from those who had not received treatment two months before ( $P>0.05$ ).

Duration of diarrhea, and symptoms, ranging from less than one week to as high as greater than four weeks was reported (Table 8). Less than one-week duration was most commonly reported 183/246 (74.4 %), while four weeks or more duration was comparatively rare (4.1 %). The result of microscopy for *E. histolytica*/*E. dispar* does not appear to be associated

with duration of diarrhea and symptoms. Abdominal pain, tenesmus, mucoid bloody diarrhea, and flatulence were the most common complaints (67.1-84.1 %), while fever, weight loss, and constipation were less common (4.5-31.3 %). The pattern of microscopy finding of *E. histolytica*/*E. dispar* was more or less similar with all symptoms except with complaints of constipation, where much higher frequency was observed (63.6 %).

Reporting of signs and symptoms was not significantly associated with duration of diarrhea ( $P>0.05$ ).

|                      | Abdominal pain | Tenesmus | Mucoid bloody diarrhea | Flatulence | Fever | Weight loss | Constipation |
|----------------------|----------------|----------|------------------------|------------|-------|-------------|--------------|
| Age                  |                |          |                        |            |       |             |              |
| <10                  | 25             | 15       | 4 (28.6)               | 1          | 1     | 1           | 1            |
| 11-20                | 8              | 5        | 2 (25.0)               | 1          | 1     | 1           | 1            |
| 21-30                | 45             | 35       | 25 (41.7)              | 15         | 10    | 10          | 10           |
| >30                  | 115            | 115      | 62 (41.3)              | 35         | 25    | 25          | 25           |
| Sex                  |                |          |                        |            |       |             |              |
| Male                 | 104            | 104      | 44 (29.0)              | 34         | 24    | 24          | 24           |
| Female               | 82             | 82       | 34 (41.5)              | 22         | 16    | 16          | 16           |
| HIV status           |                |          |                        |            |       |             |              |
| Positive             | 11             | 11       | 5 (45.5)               | 3          | 2     | 2           | 2            |
| Negative             | 112            | 112      | 43 (37.2)              | 32         | 23    | 23          | 23           |
| Duration of diarrhea |                |          |                        |            |       |             |              |
| <7 days              | 40             | 40       | 17 (32.5)              | 12         | 8     | 8           | 8            |
| >7 days              | 78             | 78       | 35 (31.3)              | 23         | 17    | 17          | 17           |

Table 7. Prevalence of *E. histolytica*/*E. dispar* based on microscopic diagnosis of stool samples with regard to study site, age, sex, HIV status and treatment of 246 study subjects presenting with diarrrhea from Akaki and Wonji cohort participants and their family members (April- Dec 2001).

| Variable                  |          | No. Examined | <i>E.histolytica</i> / <i>E.dispar</i> (%) |
|---------------------------|----------|--------------|--|
| Site                      | Wonji    | 139          | 59 (42.4)                                  |
|                           | Akaki    | 107          | 39 (36.4)                                  |
| Age                       | <10      | 28           | 8 (28.6)                                   |
|                           | 11-15    | 8            | 2 (25.0)                                   |
|                           | 16-25    | 57           | 25 (43.9)                                  |
|                           | >25      | 153          | 63 (41.2)                                  |
| Sex                       | Male     | 164          | 64 (39.0)                                  |
|                           | Female   | 82           | 34 (41.5)                                  |
| HIV status                | Positive | 34           | 15 (44.1)                                  |
|                           | Negative | 121          | 45 (37.2)                                  |
| Treatment (Metronidazole) | Yes      | 40           | 13 (32.5)                                  |
|                           | No       | 206          | 85 (41.3)                                  |

Table 8. Prevalence of *E. histolytica/E. dispar* based on microscopic diagnosis of stool samples with regard to the clinical history of 246 study subjects presenting with diarrhea from Akaki and Wonji cohort participants and their family members (April- Dec 2001).

| Variable         | Diarrheal cases | <i>E.histolytica/E.dispar</i> **<br>(microscopy) | <i>E. dispar</i> **<br>(PCR) |
|------------------|-----------------|--|------------------------------|
| Duration (Weeks) |                 |  |                              |
| <1               | 183             | 39.3   | 7.7                          |
| 1-4              | 53              | 43.4   | 11.3                         |
| >4               | 10              | 30   | 20                           |
| Symptoms*        |                 |  |                              |
| Abdominal pain   | 207             | 39.6   | 9.7                          |
| Tenesmus         | 204             | 40.2   | 9.8                          |
| Mucoid/bloody    | 196             | 39.3   | 9.2                          |
| Flatulence       | 165             | 37.6   | 10.3                         |
| Fever            | 77              | 45.5   | 7.8                          |
| Watery diarrhea  | 46              | 41.3   | 2.2                          |
| Weight loss      | 34              | 41.2   | 11.8                         |
| Constipation     | 11              | 63.6   | 0                            |

\* = The same study subjects may manifest more than one symptom

\*\* = Numbers indicate percentage

By far one of the most common protozoan infections reported among these diarrheal patients were *E. histolytica/E. dispar*: 39.8 % of the study subjects were thought to harbor trophozoites and/or four-nucleated cysts (Table 9). 'Amebiasis' being diagnosed, specific treatment with anti-protozoan drug was provided to large numbers of patients. The pattern of infection between Wonji and Akaki for most *Entamoeba* species and *G. lamblia* was similar, only there were significantly more *B. hominis* infections in Wonji than in Akaki ( $P<0.05$ ). The macroscopical stool inspection showed that 144/246 (58.5 %) was 'soft

stools', while 62/246 (25.2 %) was 'liquid stools', the rest 40/246 (16.3 %) was 'formed stools'.

Table 9. Prevalence of intestinal protozoan infections among 246 study subjects with diarrhea from Wonji and Akaki, as determined by microscopic diagnosis (April-December 2001).

| Detected parasites*             | Wonji (n=139) |      | Akaki (n=107) |      | Total (n=246) |      |
|---------------------------------|---------------|------|---------------|------|---------------|------|
|                                 |               | %    |               | %    |               | %    |
| <i>Blastocystis hominis</i>     | 69            | 49.6 | 33            | 30.8 | 102           | 41.5 |
| <i>E. histolytica/E. dispar</i> | 59            | 42.4 | 39            | 36.4 | 98            | 39.8 |
| <i>E. coli</i>                  | 30            | 21.6 | 18            | 16.8 | 48            | 19.5 |
| <i>Giardia lamblia</i>          | 23            | 16.5 | 24            | 22.4 | 47            | 19.1 |
| <i>E. hartmanni</i>             | 20            | 14.4 | 7             | 6.5  | 27            | 11.0 |
| <i>Endolimax nana</i>           | 11            | 7.9  | 8             | 7.5  | 19            | 7.7  |
| <i>Mononucleated cysts</i>      | 10            | 7.2  | 3             | 2.8  | 13            | 5.3  |
| <i>Chilomastix mesnili</i>      | 7             | 5.0  | 5             | 4.7  | 12            | 4.9  |
| <i>Iodamoeba buetschlii</i>     | 7             | 5.0  | 4             | 3.7  | 11            | 4.5  |

\* = More than one parasite may be detected in the same study participants

In an attempt to evaluate the performance of coproantigen detection from stools, the findings of *Entamoeba* ELISA and *E. histolytica* ELISA was compared only with specific findings of *E. dispar* PCR-SHELA, as the specific *E. histolytica* PCR did not detect any DNA (Table 10). The *Entamoeba* antigen detection ELISA revealed 70 positive cases for the presence of the two species complex, whereas the *E. histolytica* specific ELISA identified only 8 cases compared to the microscopy finding of 98 cases. Upon

confirmatory diagnostic analysis, using PCR-SHELA, only *E. dispar* was identified in 22 cases out of the 246 while no *E. histolytica* was detected. The PCR finding of 22/246 (8.9 %) *E. dispar* cases was in agreement with 12/98 (12.2 %) of the microscopy, 8/70 (11.4 %) of the *Entamoeba* ELISA and none of the *E. histolytica* specific ELISA results. The PCR, on the other hand, was able to detect additional *E. dispar* infection, 10/148 (6.8 %) that was negative by microscopy and 14/176 (8.0 %) that was negative by the *Entamoeba* ELISA. Considering PCR-SHELA as the "gold standard", the specificity and sensitivity of microscopy for *E. histolytica*/*E. dispar* was 61.6 % and 54.5 %, respectively, while for the *Entamoeba* ELISA it was 72.3 % and 36.4 %, respectively. In 12 of the 22 cases, in which *E. dispar* DNA was detected, *Entamoeba* trophozoites and/or four nucleated cysts were also found by microscopy. Thirty microscopical positive samples, which did not produce an amplicon in either one of the two PCRs (i.e. were "negative"), were tested for PCR inhibition. After spiking with *E. histolytica* DNA, all samples produced a specific product.

Table 10. Comparison of microscopy and coproantigen ELISA with PCR-SHELA, specific for *E. dispar*, on stool samples of patients presenting with diarrhea (April-December 2001).

| Diagnostic method           | PCR-SHELA specific for <i>E. dispar</i> |          |               |
|-----------------------------|---|----------|---------------|
|                             | Positive                                | Negative | Total (n=246) |
| <i>Microscopy</i>           |   |          |               |
| Positive                    | 12                                      | 86       | 98            |
| Negative                    | 10                                      | 138      | 148           |
| <i>Entamoeba</i> ELISA      |   |          |               |
| Positive                    | 8                                       | 62       | 70            |
| Negative                    | 14                                      | 162      | 176           |
| <i>E. histolytica</i> ELISA |   |          |               |
| Positive                    | 0                                       | 8        | 8             |
| Negative                    | 0                                       | 238      | 238           |

**N.B.:** PCR-SHELA was negative for *E. histolytica* in all cases.

#### 5.4. Seroprevalence of *E. histolytica* IgG in Wonji and Akaki cohorts

A total of 390 serums, collected from Wonji and Akaki and stored in  $-20^{\circ}\text{C}$  between February 1997 and December 2000, were screened for the sero-prevalence of *E. histolytica* IgG with crude and specific recombinant surface antigen (P-Antigen) of *E. histolytica* (Table 11). Overall, the result with the crude antigen showed that more than 36 % of the

study subjects had ELISA titers  $\geq 1:40$ , the recommended cut-off value used for diagnosis of invasive disease, which is valid in non-endemic countries, like The Netherlands.

At ELISA titers between 1:40 and 1:80, there was significantly higher titer in Wonji than in Akaki ( $P < 0.01$ ). In contrast, at higher titers (1:160 – 1:320), there seems to be more positivity in Akaki than in Wonji. In total 25 (6.4 %) of the 390 serum tested with the crude antigen ELISA had titres  $\geq 1:160$ , suggestive of invasive amebiasis. Of these 8 (2.0 %) were  $\geq 1:320$  titers. The sero-prevalence, on the other hand, was only 2.8 % with the recombinant surface antigen, which is more specific than the crude antigen, significantly more in Wonji than in Akaki ( $P < 0.01$ ).

The microscopic positivity of *E. histolytica/E. dispar* was compared with the specific seroprevalence of *E. histolytica* IgG (Table 12). By microscopy 108/390 (27.7 %) individuals were reported to be infected with *E. histolytica/E. dispar*, while only 6/108 (5.6 %) were seropositive with the recombinant antigen. The sero-prevalence was significantly more ( $P < 0.05$ ) with the positive microscopy report of *E. histolytica/E. dispar*.

Table 12. Comparison of microscopic diagnosis by microscopy and serological methods (ELISA) by using recombinant antigen from 390 study participants (Dec 1997-Dec 2000)

|            | Parity 1 ELISA |          | Total |
|------------|----------------|----------|-------|
|            | Positive       | Negative |       |
| Microscopy |                |          |       |
| Positive   | 108            | 182      | 290   |
| Negative   | 6              | 384      | 390   |
| Total      | 114            | 566      | 680   |

Table 11. Sero-prevalence of anti- *E. histolytica* IgG antibodies by crude antigen ELISA and recombinant surface antigen (P-Antigen) ELISA from samples selected randomly from Wonji and Akaki cohort participants (Feb 1997 - Dec 2000).

| Antigen used          | Study site      |                 |               |
|-----------------------|-----------------|-----------------|---------------|
|                       | Wonji (n = 231) | Akaki (n = 159) | Total (n=390) |
| <b>Crude- Antigen</b> |                 |                 |               |
| < 1:40                | 132 (57.1)*     | 115 (72.3)      | 247 (63.3)    |
| 1:40                  | 44 (19.0)       | 10 (6.3)        | 54 (13.8)     |
| 1:80                  | 45 (19.5)       | 19 (11.9)       | 64 (16.4)     |
| 1:160                 | 7 (3.0)         | 10 (6.3)        | 17 (4.4)      |
| 1:320                 | 2 (0.9)         | 4 (2.5)         | 6 (1.5)       |
| 1:640                 | 1 (0.4)         | 1 (0.6)         | 2 (0.5)       |
| <b>P-Antigen</b>      |                 |                 |               |
| Positive              | 10 (4.3)        | 1 (0.6)         | 11 (2.8)      |
| Negative              | 221 (95.7)      | 158 (99.4)      | 379 (97.2)    |

\* = Numbers in parenthesis indicate percentage

Table 12. Comparison of *E. histolytica* diagnosis by microscopy and recombinant surface antigen (P-Antigen) ELISA by using samples selected randomly from Wonji and Akaki cohort participants (Feb 1997- Dec 2000).

|                   | P-Antigen ELISA |            |            |
|-------------------|-----------------|------------|------------|
|                   | Positive        | Negative   | Total      |
| <b>Microscopy</b> |                 |            |            |
| Positive          | 6               | 102        | 108        |
| Negative          | 5               | 277        | 282        |
| <b>Total</b>      | <b>11</b>       | <b>379</b> | <b>390</b> |

## 5.5. Prevalence of *E. histolytica* and *E. dispar* in Different Population Groups

### 5.5.1 School children and prisoners

The study subjects, in total 772, were from various parts of Ethiopia either primary-school children (47 %) with a median age of 12 years, or prisoners (57 %) with a median age of 27 years (Table 13). There were more males than females, as almost all prisoners were males. Prevalence of *E. histolytica/E. dispar* by microscopy was higher in prison than in school ( $P < 0.05$ ). An increasing linear trend in infection with *E. histolytica/E. dispar* with age was noted, significantly higher in older age groups than in younger ones ( $P < 0.01$ ). The difference for *E. histolytica/E. dispar* infection was not associated with sex ( $P > 0.05$ ).

Infection with *E. histolytica/E. dispar* species complex was one of the most common parasitic infections in all schools, ranging from 22.1 % to 32.9 % (Table 14). There was more *E. histolytica/E. dispar* infection from Sirba Abay elementary school compared to either Nekemte or Arsi ( $P < 0.01$ ). Among the other protozoan infections, *B. hominis* was the highest (48.5 %) in Nekemte School, followed by Sirba Abay (28.9 %) and almost no *B. hominis* infection from Arsi elementary school (1.2 %). The difference for *B. hominis* infection was highly significant between Nekemte and Sirba Abay ( $P < 0.001$ ). By microscopy, 71.1 % of the school children appeared to harbor one or more intestinal parasites.

Table 13. Prevalence of *E. histolytica*/*E. dispar* infections as determined by microscopy by using formol-ether concentration technique from SAF preserved stool specimens from 363 children in three primary school and 409 inmates in three prisons in Ethiopia (April-May 2003).

| Variable   |        | No. examined | <i>E. histolytica</i> / <i>E. dispar</i> (%) |
|------------|--------|--------------|--|
| Study site | School | 363          | 97 (26.7)                                    |
|            | Prison | 409          | 133 (32.5)                                   |
| Age        | 6-10   | 126          | 29 (23.0)                                    |
|            | 11-15  | 178          | 47 (26.4)                                    |
|            | 16-25  | 120          | 38 (31.7)                                    |
|            | 25-35  | 263          | 86 (32.7)                                    |
|            | >35    | 85           | 30 (35.3)                                    |
| Sex        | Male   | 587          | 182 (31.0)                                   |
|            | Female | 185          | 48 (25.9)                                    |

Table 14. Prevalence of intestinal protozoan infections among 363 healthy or asymptomatic subjects from three primary school children in Ethiopia as determined by microscopy, using formol-ether concentration technique from SAF preserved stool specimens (April- May 2003).

| PROTOZOA                      | No, and (%) of subjects found infected |                      |                  |                    |
|-------------------------------|--|----------------------|------------------|--------------------|
|                               | Sirba Abay<br>(n = 146)                | Nekemte<br>(n = 136) | Arsi<br>(n = 81) | Total<br>(n = 363) |
| <i>E.histolytica/E.dispar</i> | 48 (32.9)                              | 30 (22.1)            | 19 (23.5)        | 97 (26.7)          |
| <i>B. hominis</i>             | 42 (28.9)                              | 66 (48.5)            | 1 (1.2)          | 128 (30.0)         |
| <i>E. coli</i>                | 41(28.1)                               | 41 (30.2)            | 24 (29.6)        | 106 (29.2)         |
| <i>I. buetschlii</i>          | 33 (22.6)                              | 18 (13.2)            | 10 (12.3)        | 61 (16.8)          |
| <i>G. lamblia</i>             | 18 (12.3)                              | 9 (6.6)              | 0                | 27 (7.4)           |
| Mononucleated cyst            | 12 (8.2)                               | 10 (7.4)             | 3 (3.7)          | 25 (6.9)           |
| <i>E. nana</i>                | 2 (1.4)                                | 15 (11.0)            | 0                | 17 (4.7)           |
| <i>Sarcocystis</i> spp        | 15 (10.2)                              | 0                    | 1(1.2)           | 16 (4.4)           |
| <i>E. hartmanni</i>           | 7 (4.8)                                | 7 (5.2)              | 1 (1.2)          | 15 (4.1)           |
| <i>C. mesnili</i>             | 8 (5.5)                                | 2 (1.5)              | 0                | 10 (2.8)           |

From three different prisons, 409 participants were examined for different parasites by microscopy, and 32.5 % of them were infected with *E. histolytica/ E. dispar* (Table 15). There was no statistically significant difference between the three prisons for *E. histolytica/E. dispar* infection ( $P>0.05$ ). In contrast, overall there were more *E. histolytica/E. dispar* infections in prisons than in primary schools ( $P<0.05$ ). Except *E. hartmanni* infection, all other non-pathogenic protozoan parasites and giardia were much less common in Shoa Robbit prison. The prevalence of *G. lamblia* was significantly higher in Ziway than the other two prisons ( $P<0.01$ ).

Table 15. Prevalence of intestinal protozoan infections among 409 healthy or asymptomatic subjects from three prisons in Ethiopia as determined by microscopy, using formol-ether concentration technique from SAF preserved stool specimens (April-May 2003).

| PROTOZOA                      | No, and (%) of subjects found infected |                    |                         |                    |
|-------------------------------|--|--------------------|-------------------------|--------------------|
|                               | Nekemte<br>(n = 146)                   | Ziway<br>(n = 138) | Shoa Robit<br>(n = 125) | Total<br>(n = 409) |
| <i>E.histolytica/E.dispar</i> | 48 (32.9)                              | 48 (34.8)          | 37 (29.6)               | 133 (32.5)         |
| <i>B. hominis</i>             | 53 (36.3)                              | 55 (39.9)          | 16 (12.8)               | 124 (30.3)         |
| <i>E. coli</i>                | 50 (34.3)                              | 47 (34.1)          | 26 (20.8)               | 123 (30.1)         |
| <i>I. buetschlii</i>          | 17 (11.6)                              | 14 (10.1)          | 14 (11.2)               | 45 (11)            |
| Mononucleated cyst            | 6 (4.1)                                | 13 (9.4)           | 12 (9.6)                | 31 (7.6)           |
| <i>E. hartmanni</i>           | 4 (2.7)                                | 2 (1.5)            | 13 (10.4)               | 19 (4.7)           |
| <i>G. lamblia</i>             | 3 (2.1)                                | 10 (7.3)           | 5 (1.0)                 | 18 (4.4)           |
| <i>E. nana</i>                | 6 (4.1)                                | 5 (3.6)            | 1 (0.8)                 | 12 (2.9)           |
| <i>C. mesnili</i>             | 5 (3.4)                                | 4 (2.9)            | 2 (1.6)                 | 11 (2.7)           |

A sub sample of 213 DNA samples, microscopically positive for *E. histolytica/E. dispar* cysts and/or trophozoites, were retested with real-time PCR from the three primary schools and prisons (Table 16). The PCR result indicated that 195 (91.5 %) out of the 213 samples were positive for *E. dispar*, whereas none was PCR-positive for *E. histolytica*. *E. dispar*- specific amplification could be detected after 19-46 cycles (median=33) and usually before 35 cycles (Fig 5). Only 3 out of 111 (2.7 %) cyst-positive cases were negative in the PCR. Whereas among cases in which microscopic diagnosis was based on

the finding of trophozoites only, PCR was negative in 15 out of 102 cases (14.7%). When every PCR-negative sample was retested in the PCR, each was again found PCR-negative. In all samples except one, amplification of the internal control was detected at the expected threshold of approximately 33 cycles. The sample that did not show amplification of the control was one of the cyst-positive samples that appeared PCR-negative for *Entamoeba*.

Table 16. Comparison of microscopical detection of *Entamoeba histolytica*/*E. dispar* cysts and trophozoites from primary school children and prisoners with those of the real-time PCR detection (April-May 2003).

| Microscopy             | Real-Time PCR |          |       |
|------------------------|---------------|----------|-------|
|                        | Positive      | Negative | Total |
| Cysts only             | 79            | 1        | 80    |
| Trophozoites only      | 87            | 15       | 102   |
| Cysts and trophozoites | 29            | 2        | 31    |
| Total                  | 195           | 18       | 213   |

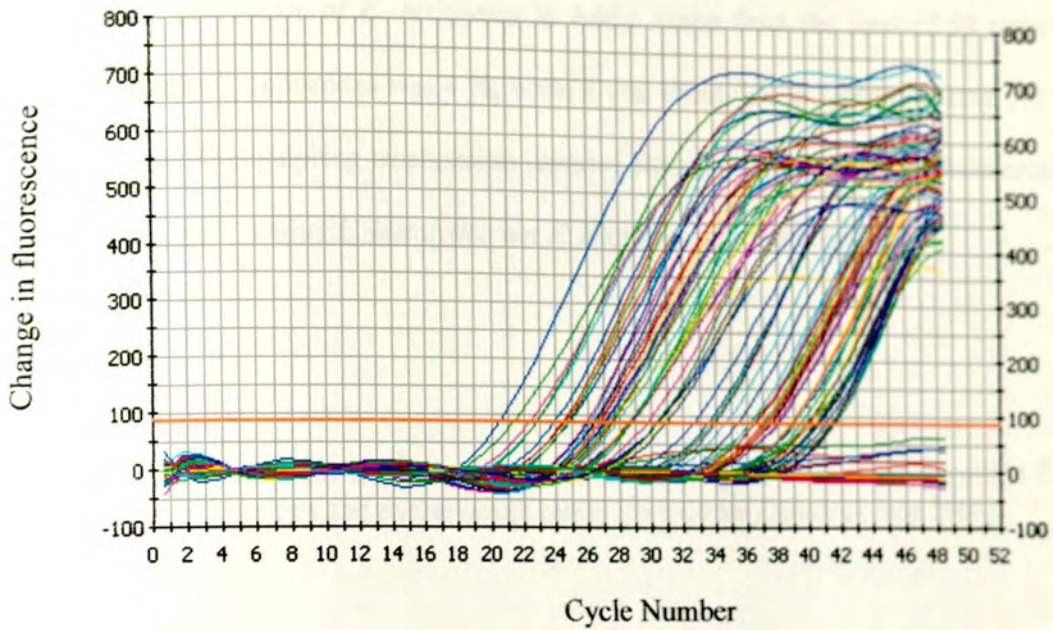


Fig 5. An example of amplification plot of *E. dispar* positive samples from 213 DNA specimens collected from primary schools and prisons. *E. dispar* specific amplification was detected with threshold cycles between 19 and 46 (median 33).

### 5.5.2 Reported haematophagous trophozoites.

Between January- June 2003, 110 stool samples thought to contain RBC-engulfing trophozoites of "*E. histolytica*" were collected from 8 different hospitals and 12 health centers laboratories from Addis Ababa and outside (Table 17). Out of 110 stool samples collected, Real- Time PCR was positive for *E. histolytica* only in three specimens, one collected from Gondar University Teaching Hospital and the other two from Teklehaimanot Health Center. The specimen from Gondar crossed the cut off value (threshold for positivity) after 25.2 cycles (Fig 6). With the great majority, the trophozoites seen apparently belonged to *E. dispar*, i.e., 77/110 (71.3), and the remaining 30 samples were negative for both species.



The specific prevalence of *E. histolytica* in Addis Ababa from the total of 50 reported haematophagous trophozoites was 4 %, while it was about 9 % in Gondar. Many (40 %) supposedly RBC engulfing trophozoites reported from different diagnostic laboratories in Addis Ababa were neither *E. histolytica* nor *E. dispar* as determined by PCR.

Table 17. Real-time PCR characterization of haematophagous trophozoites reported from eight hospitals and twelve health center laboratories (January- June 2003).

| Study site  | No. examined | Real-Time PCR         |                  |
|-------------|--------------|-----------------------|------------------|
|             |              | <i>E. histolytica</i> | <i>E. dispar</i> |
| Addis Ababa | 50           | 2                     | 28               |
| Wollega     | 26           | 0                     | 24               |
| Gondar      | 11           | 1                     | 8                |
| Wonji       | 8            | 0                     | 8                |
| Mekele      | 7            | 0                     | 4                |
| Assela      | 3            | 0                     | 2                |
| Hatat       | 3            | 0                     | 2                |
| Akaki       | 2            | 0                     | 1                |
| Total       | 110          | 3                     | 77               |

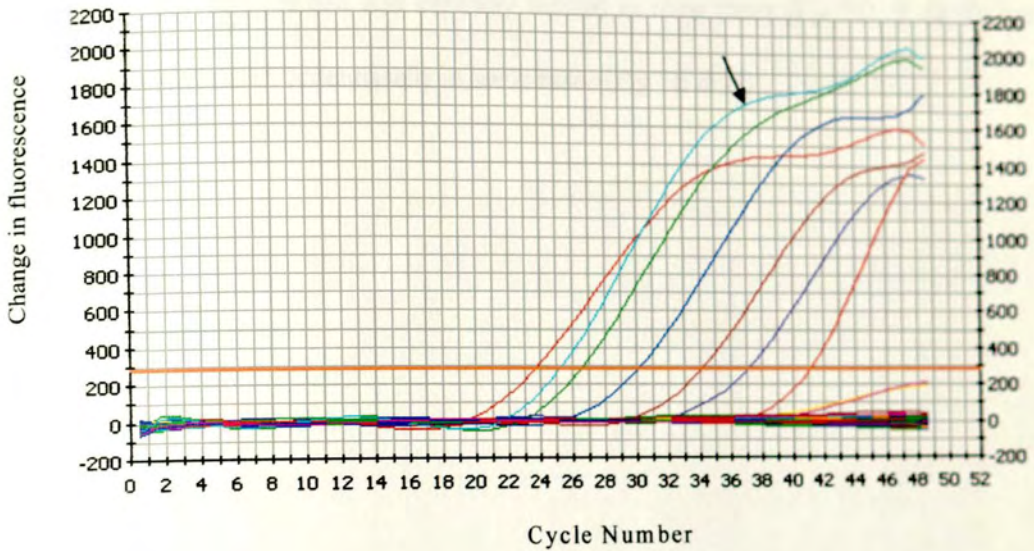


Fig 6. Amplification plot of positive specimen for *E. histolytica* from Gondar Teaching Hospital with a threshold value of 25.2 (black arrow). The other six lines represent the serial dilution of the positive control.

Six representative stool samples that were supposed to be with haematophagous trophozoites were preserved in SAF and their different morphological features is depicted in Figure 7A-I. The pictures were taken under 400 times magnification from direct mount of the SAF preserved specimens. Figures 7A to C were trophozoites that were neither *E. histolytica* nor *E. dispar* according to the Real-Time PCR. Figures 5D to I, on the other hand, were found to be *E. dispar* on the basis of the PCR, instead of *E. histolytica*.

The delicate nucleus strung with fine chromatin particles uniformly attached to the inside of the wall (Fig 7G-I) suggests that the trophozoites belong either to *E. histolytica* or *E. dispar*. However, large chromatin masses could sometimes be seen to the inner nuclear

wall (Fig 7D-F). The nuclei morphological characteristics appears quite different from *E. histolytica*/*E. dispar* for Fig 7A-C, the caryosome is rather dense and not well formed. The caryosome was well formed and centrally located in most cases (Fig 7D, F, G, I), but it was also found located eccentrically in some cases (Fig 7E & H).


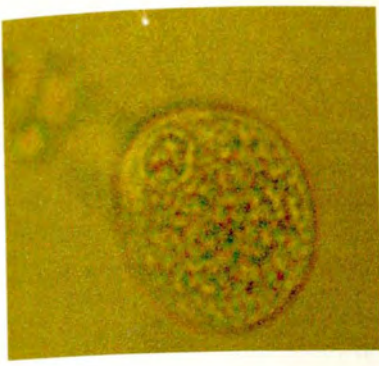
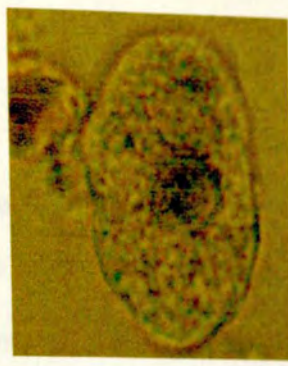


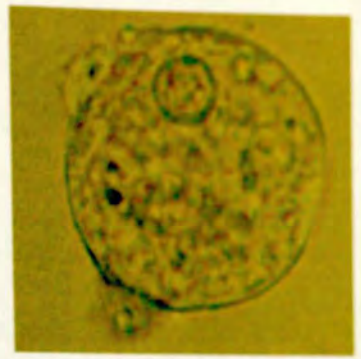
Fig 7. Micrographs of microscopically positive *Entamoeba* trophozoites that were believed to be *E. histolytica*/*E. dispar* based on their morphology. The pictures were taken under 40 x 10 magnification from preserved stool specimens in direct wet mount. A-C were prepared for *E. histolytica* and *E. dispar*, while D-F were all *E. dispar* by PCR.



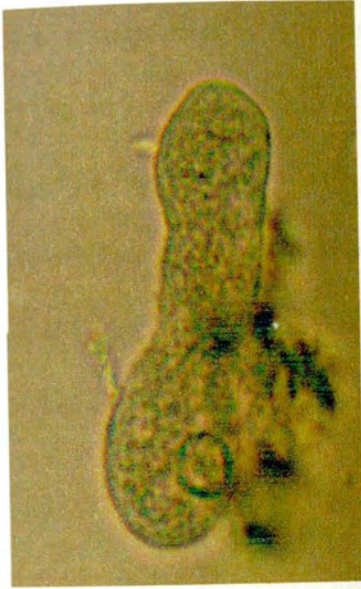
A



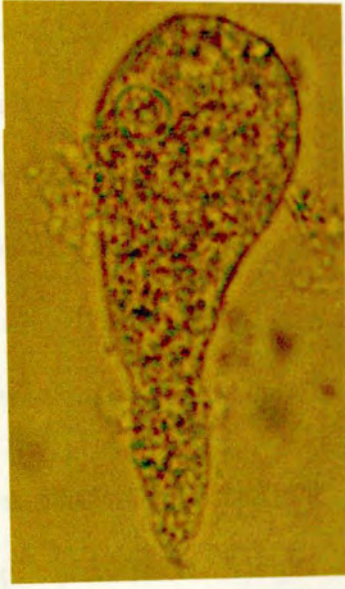
B



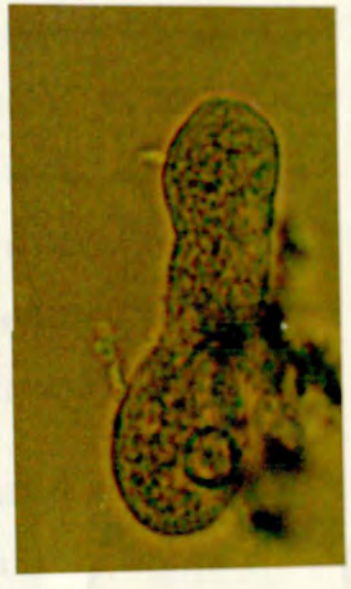
C



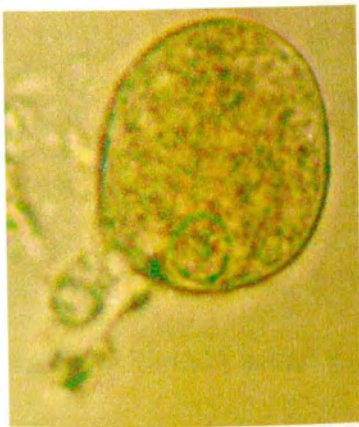D



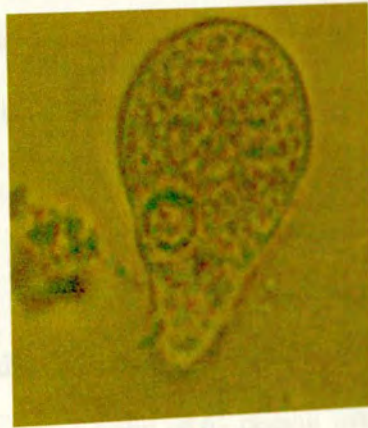E



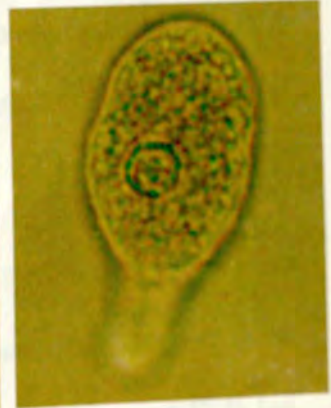F



G



H



I

Fig 7. Six cases of microscopically positive *Entamoeba* trophozoites that were believed to be engulfing RBC. The pictures were taken under 40 x 10 magnification from SAF preserved stool specimens in direct wet mount. A-C were negative for *E. histolytica* and/or *E. dispar*, while D-I were all *E. dispar* by PCR.

### 5.5.3 HIV/AIDS patients and Amebiasis

The prevalence of *E. histolytica/E. dispar* by microscopy was 11.7 % among 137 HIV/AIDS patients with complaints of diarrhea, from three Hospitals in Addis Ababa (Table 18). Almost all positive *E. histolytica/E. dispar* were *Entamoeba* trophozoites except a single case where quadrinucleated cysts were found together. There was more infection with *E. histolytica/E. dispar* in males than in females, and the difference was highly significant ( $P < 0.01$ ). A steady increment in infection rate was also noted as age increases with age groups above 45 years appearing to have significantly more infection with *E. histolytica/E. dispar* ( $P < 0.01$ ). There was no significant difference for *E. histolytica/E. dispar* infection between outpatients and inpatients ( $P > 0.05$ ).

All the 137 fecal samples were retested with real time PCR and no *E. histolytica* infection was confirmed. The actual specific prevalence of *E. dispar*, on the other hand, was 35/137 (25.5 %) by PCR versus 11.7 % *E. histolytica/E. dispar* identified by microscopy (Table 19). Only four out of the 16 microscopy-positives (25%) were in agreement with the PCR result. In contrast, the PCR detected additional 31 (88.6 %) *E. dispar* that were missed by microscopy.

Distribution of Real-Time PCR findings of *E. dispar* among 119 HIV/AIDS patients was compared with CD4 counts (Table 20). About 88 % of the patients had CD4 count in the range of 2-192 cells/ $\mu$ l with a median count of 61 cells/ $\mu$ l while the remaining 12 % had CD4 count in the range of 228-756 cells/ $\mu$ l with a median count of 295 cells/ $\mu$ l. The risk of getting infected with *E. dispar* appears to be twice more when CD4 count is less than 200 cells/ $\mu$ l (30.5 %) compared to when CD4 count is above 200 cells/ $\mu$ l (14.3 %). There

was no significant association between the presence of *E. dispar* and clinical symptoms ( $P>0.05$ ).

Table 18. Prevalence of *E. histolytica/E. dispar* based on microscopy of direct and formol-ether concentration by sex, age and hospital among 137 HIV patients presenting with diarrhea in Ethiopia (March 2002- Dec 2003).

| Variable   | No. examined | <i>E. histolytica/E. dispar</i> (%) |
|------------|--------------|-------------------------------------|
| Sex        |              |                                     |
| Male       | 96           | 15 (15,6)                           |
| Female     | 41           | 1 (2,4)                             |
| Age        |              |                                     |
| 16-25      | 18           | 1 (5,6)                             |
| 26-35      | 66           | 6 (9,1)                             |
| 36-45      | 36           | 4 (11,1)                            |
| 45+        | 17           | 5 (29,4)                            |
| Hospital   |              |                                     |
| Army       | 55           | 6 (10,9)                            |
| Police     | 47           | 9 (19,1)                            |
| St. Paul   | 35           | 1 (2,9)                             |
| Patient    |              |                                     |
| Inpatient  | 99           | 12 (12,1)                           |
| Outpatient | 38           | 4 (10,5)                            |
| Total      | 137          | 16 (11,7)                           |

Table 19. Real-Time PCR characterization of microscopic findings of *E. histolytica*/*E. dispar* among 137 HIV +ve diarrheal patients (March 2002- Dec 2003).

|            | Real-Time PCR specific for <i>E. dispar</i> |          |
|------------|---|----------|
|            | Positive                                    | Negative |
| Microscopy |   |          |
| Positive   | 4   | 12       |
| Negative   | 31  | 90       |
| Total      | 35  | 102      |

Table 20. Prevalence of *E. dispar* as determined by Real-Time PCR in relation to CD4 counts among 119 HIV patients presenting with diarrhea (March 2002-Dec

| CD4 cells/ $\mu$ l   | No. examined | <i>E. dispar</i> | %    | (95 % CI*)    |
|----------------------|--------------|------------------|------|---------------|
| 2-192 (median=61)    | 105          | 32               | 30.5 | (21.5 - 39.5) |
| 228-756 (median=295) | 14           | 2                | 14.3 | (4.9 - 23.7)  |

2003).

\* = 95 % confidence intervals for percentage of *E. dispar*

## 6. DISCUSSION

The data collected between 1997 and 1999 from the cohort study participants, by using microscopy, showed higher prevalence of both protozoan and helminth infections in Wonji than in Akaki. The most obviously raised prevalence was that of *E. histolytica/E. dispar*, *S. mansoni*, and *G. lamblia* infections. Although a study by Bekele *et al.* (1989) suggests that transmission of *S. mansoni* might possibly take place in Akaki, the high prevalence of *S. mansoni* infections in Wonji may easily be understood, as the area is known to be highly endemic to it. Furthermore, the Kato technique which is the standard method of detection (Fontanet & Woldemichael, 1999) for *S. mansoni* was part of the routine diagnostic in Wonji whereas it was not a routine practice in Akaki; thus reducing the chances of detection of *S. mansoni* ova.

Although non-significant, a somewhat higher prevalence of hookworm infection in Wonji, compared to Akaki, is to be expected because most study participants in Akaki are factory workers, while most participants in Wonji are workers in the Sugar Plantation, with more risk of exposure to soil-transmitted helminths.

Analysis of data from Wonji Hospital Annual Report indicated that *E. histolytica/E. dispar*, reported as "*E. histolytica*", and was the most prominent intestinal parasite in the routine diagnosis from 1988 to 1998. The reported annual prevalence of "amebic infection", which was greater than 24 %, throughout the reporting period, suggested a very high transmission of "intestinal amebiasis". Although the reported prevalence of infection

seemed to fluctuate somewhat, it essentially remained high during the eleven years. The annual trend in Wonji Hospital points that amebic infection was much higher than *Giardia* every year, showing that "*E. histolytica*" was reported on a regular basis. As the health insurance coverage for employees in the factory is full, it is possible that every positive case was treated. One could speculate this to be either an overdiagnosis due to error in microscopy, or due to intense transmission of the parasite. However, it is difficult to substantiate the later, since there was no species-specific and differential diagnosis from other *Entamoeba* species at this time.

The prevalence of "intestinal amebiasis" appears to be extremely high according to the Annual Reports of Wonji Hospital and the cohort routine data from Wonji and Akaki. Considering the unreliability of microscopy and clinical diagnosis of intestinal amebiasis, this study had attempted to undertake a retrospective analysis of amebic liver abscess (ALA), which is a more reliably diagnosable pathology, among hospitalised patients (Martinez-Palomo & Espinoza-Cantellano, 1999; Blessmann *et al.*, 2002). Since only few uncommon diseases such as pyogenic liver abscess present with a combination of symptoms and signs similar to those of an ALA, the clinical diagnosis is more reliable than that of intestinal amebiasis where other causes of intestinal diseases may closely mimic the latter. It is believed that reportedly predominant clinical features, such as right upper quadrant pain, fever and hepatomegaly together with the characteristic location of the abscess in the liver, would adequately define the ALA cases. (Gibney, 1990; Mondragon-Sanchez *et al.*, 1995; Sharma *et al.*, 1995).

Although record keeping at Tikur Anbessa Hospital was far from satisfactory, findings of the analysis of the accessible data on the diagnosis of ALA over the past 20 years was in

support of rarity of intestinal amebiasis among the study participants. Liver abscess in general appears to be very rare among admitted patients in the Hospital.

Furthermore, the low number of patients admitted with ALA over the past 20 years possibly is an indirect proof that invasive amebiasis in Ethiopia is rare. This is contrary to the reportedly high prevalence of intestinal amebiasis. The discrepancy suggests either a high under-reporting of cases of hepatic amebiasis or a significantly high over-reporting of intestinal amebiasis. However, the existing prevalence data show intestinal amebiasis to be one of the most commonly reported infections in Ethiopia (Kloos & TesfaYohannes, 1993), suggesting that high over-reporting would better explain the situation more accurately.

One of the strong indications for a liver abscess to be amebic abscess is the quick response to metronidazole treatment (Wynants *et al.*, 1995; Lee *et al.*, 1996; Moazam & Nazir, 1998). In all patients at Tikur Anbessa Hospital, classified as ALA was characterized by such a response. The classical darkbrown pus, which is a direct evidence for amebic liver abscesses, was obtained in two of the cases. The compatibility of laboratory findings, clinical diagnosis of "amebic liver abscess" was additional evidence. Only in two cases, the stool examination by microscopy had revealed *Entamoeba* trophozoites, suggesting the infrequent encounter of the parasite in the event of ALA. This was consistent with the report that only few patients have active diarrhea at the time of presentation with ALA (Reed, 1998). However, co-occurrence of *Entamoeba* trophozoites in the stool and amebic liver abscess has been shown by *in vitro* culture in the majority of patients (Clark & Diamond, 1991; Petri & Singh, 1999).

Only few records of extra-intestinal amebiasis exist in Ethiopia. From Ras Desta Hospital (Addis Ababa), a case of pleurisy due to *E. histolytica* in the effusion was reported (Spitzer, 1963). This case showed none of the classical signs of hepatic amebiasis, such as fever, leukocytosis, pain and tenderness. Although pleural effusion was seen in both sides, *E. histolytica* trophozoites were observed only in the right side. Similarly, two patients with left pleural effusion as a complication of amebic hepatic abscess were reported from Jimma Hospital (Gonzalez, 1986). In this report, the classic dark-brown (chocolate-like) fluid was withdrawn from one of the patients only, but both of them responded well to metronidazole treatment.

Thus, a mere number of 35 suspected cases over a period of 20 years in Tikur Anbessa Hospital with about 500 beds is very low when compared with hyperendemic areas like Mexico and Vietnam. In Mexico City in a given hospital, 50 confirmed ALA cases were admitted in five years (Mondragon-Sanchez *et al.*, 1995), which is 5 times higher than what was determined for Tikur Anbessa. Similarly, a high incidence of ALA, 21 per 100,000 inhabitants, has been reported from central Vietnam (Blessmann *et al.*, 2002). Also, in non-endemic countries in Western Europe (Belgium) 36 cases of ALA over a period of 8 years has been reported, which is about 5 cases per year (Wynants *et al.*, 1995). In Japan, a total of 69 ALA patients were reported among 227 patients with intestinal amebiasis over 12 years in one hospital (Lee *et al.*, 1996).

In contrast to the common reporting of intestinal amebiasis on the basis of routine microscopy, the record at Tikur Anbessa Hospital shows a very low incidence of ALA. The Ministry of Health report on the incidence of intestinal and extra-intestinal amebiasis from various regions of Ethiopia suggests notable differences in prevalence. Compared to

the record in Tikur Anbessa, analysis of three years medical admissions record at Gondar Hospital reveals lower prevalence "amebic dysentery" (2.5 %) and higher prevalence of ALA (5 %) out of 11750 admissions (Mollinaux, 1966).

In view of the present findings, the prevalence of ALA reported from Gondar appears to be much higher than what is expected even if clinical observations are thought to be reliable. The record in Tikur Anbessa, on the other hand, could be more reliable because of the availability of ultrasound. Besides, liver lesions can be identified clinically and in the laboratory or through post-mortem studies, making the frequency of ALA a reliable measure of rates of liver infection (Martinez-Palomo & Espinoza-Cantellano, 1999). Thus, whether the findings documented at Tikur Anbessa Hospital in Addis Ababa reflect the situation elsewhere in Ethiopia requires further study.

The most convincing evidence for accepting *E. histolytica* and *E. dispar* as two genetically different species is due to the significant difference in the gene sequences that have been identified in numerous genes of the two organisms (Mirelman, 2003). Therefore, such sequence differences between homologous genes in *E. histolytica* and *E. dispar* has made PCR the preferred method for identifying these two species (Ackers, 2002). The lack of confirmation by the species-specific PCR-SHELA for microscopic diagnosis of *E. histolytica/E. dispar* highlights the poor specificity of microscopy and shows how often the parasite is misidentified.

The discrepancy between microscopically positive cases of *E. histolytica/E. dispar* and *E. dispar* cases detected by PCR could also be either due to lack of sensitivity in the PCR or misdiagnosis of microscopy or both. Although it is also possible that PCR inhibition may result in false negative findings, the spin-column used during the DNA isolation is capable

of removing common inhibitors found in stools, and inhibition is very rarely seen (Verweij *et al.*, 2001). Moreover, no evidence of inhibition was obtained by spiking the microscopically positive samples with known DNA in repeated PCR assays.

The preponderance of various intestinal protozoan parasites in both Wonji and Akaki might have easily resulted in misidentification, and leading to many microscopically false positive *E. histolytica*/*E. dispar* infection reports. The microscopic prevalence of amebic infection among patients presenting with diarrhea for Wonji and Akaki were in the range of infection rates (3-55 %) described by Kloos and Tesfa Yohanes (1993). This is an indication of the over-estimation of prevalence by using the same diagnostic method. On microscopic diagnosis, the amebic infection appears to increase with age as it was observed in previous studies (Oyerinde *et al.*, 1977; Spirman & Shattach, 1984; Speelman *et al.*, 1987; Wanke *et al.*, 1988). In contrast to many other infections where infection rates are highest among children, infections with *E. histolytica*/*E. dispar* (on the basis of microscopy alone) are reported to show steady increases in frequency throughout life in endemic areas. As Guerrant (1986) suggested, this kind of pattern of increasing rate with age implies that there is little effective immunity against amebiasis.

Since infection with *E. histolytica* seems to exist with or without the presence of specific signs and symptoms, clinical signs and symptoms for intestinal amebiasis among diarrhea patients do not appear to be associated with the microscopic findings of *E. histolytica*/*E. dispar* infections. The parasite was also equally prevalent in acute (<1 week duration) or chronic (> 4 week) diarrhea. Diarrhea, which frequently is considered as a cardinal sign of amebiasis is easily confused with that caused by *Shigella* spp, *Campylobacter jejuni*, *Yersinia enterocolitica*, invasive *Escherichia coli*, and *Vibrio parahaemolyticus* (Gil & Bell,

1980). Furthermore, the chronic form of diarrheal syndrome of amebiasis may be indistinguishable from salmonellosis, giardiasis, toxigenic *E. coli* diarrhea, many other diarrheas of infectious origin, or the irritable bowel syndrome (Johnston *et al.*, 1980).

Although the microscopic finding of the present study with an overall prevalence of 39.8% *E. histolytica/E. dispar*, among diarrhea patients suggests that intestinal amebiasis to be the most common disease, differentiation of *E. histolytica* and *E. dispar* by using PCR-SHELA and coproantigen detection ELISA was necessary to confirm the finding. This is in line with the recommendation of WHO (1997) that "It may not be correct to regard the presence of the parasite (any trophozoite), be it in dysentery or otherwise, as adequate justification for administration of therapy, without species specific diagnosis".

Even though, evaluation of coproantigen detection ELISA in Bangladesh was reported to be more sensitive and specific than either wet-film microscopy or culture (Haque *et al.*, 1998, 2000), clear lack of sensitivity and specificity was noted in the present study. This was indicated by the fact that none of the eight *E. histolytica* positive cases, from the *E. histolytica* specific-ELISA, was confirmed by the PCR, the gold standard. Other investigators have also noted the poor performance of coproantigen detection ELISA (Mirelman *et al.*, 1997; Blessmann *et al.*, 2002; Gonin & Trudel, 2003).

The discrepancy between *E. dispar* detection by PCR and the microscopic detection of *E. histolytica/E. dispar* could be explained by either lack of sensitivity of PCR-SHELA or by overdiagnosis by microscopy or both. The overdiagnosis of microscopy was confirmed as the cause for the observed discrepancy by testing microscopically positive samples by using *E. histolytica* and *E. dispar* specific PCR, based on the small subunit ribosomal RNA

gene, (Clark and Diamond, 1991), which became negative.

Overdiagnosis of amebiasis has also support from clinical and diagnostic mistakes. Looking at the clinical oversight, most patients complained of diarrhea rather than chronic diarrhea, which is characteristic of amebiasis (Wanke *et al.*, 1988; Okhuysen, 2001), indicating that the aetiology of the diarrhea was not *E. histolytica*.

It is also noteworthy that the prevalence of *E. histolytica*/*E. dispar* detected by microscopy was similar in patients who had recently received treatment and those who had not, meaning that the parasite species involved was not *E. histolytica*. Furthermore since in more than 70 % of cases, the diagnosis of amebiasis was based on the finding of trophozoites only, without attention for details of structure of the nuclei, and due to the prevailing attitude to consider the common finding of *Entamoeba* trophozoites as "*E. histolytica*", and the habit to associate it with any diarrhea, particularly dysentery.

Also, the workload in a routine clinical diagnostic laboratory may not allow the technicians to devote enough time on a single slide to examine the different morphological characteristics. Clearly, the criteria for calling structures either trophozoites or cysts of '*E. histolytica*' are too liberal in diagnostic laboratory settings, like those in Wonji and Akaki. And, in reality the differentiation of *Entamoeba* species commonly found in human gut is by no means as easy as it is commonly imagined (Walsh, 1986).

The abundance of trophozoites and cysts of commensal protozoa and the impossibility to differentiate *E. dispar* from *E. histolytica*, together with the operational problems to implement such time consuming system, frustrated implementation of a system of microscopic quality control. Thus, the study had to stick to PCR results for confirmation.

The overall seropositivity with crude antigen for *E. histolytica*, at the recommended cut-off value, was too high to support the complete absence of the parasite in Wonji and Akaki. This could be due to cross-reaction with *E. dispar* because of the crude antigen used. In contrast, the crude antigen ELISA when applied to sera of European individuals has proved to be sensitive and specific for the detection of antiamebic antibodies (Lotter *et al.*, 1992; Lotter *et al.*, 1993; Verweij *et al.*, 2000a). Such specificity was not observed in this study, which is in agreement with Lotter *et al.* (1995) observations in Durban, South Africa. They have shown lack of specificity even at elevated titer, suggesting that individuals in an endemic area, like Durban, possess elevated background antibody titers against the crude soluble *E. histolytica* antigen.

The presence of other cross-reacting antibodies induced by infections with other parasites could also be another factor. The existence of such antibodies has been demonstrated in the case of superoxide dismutase of the ameba, which is recognized by sera from patients with various parasitic diseases unrelated to *E. histolytica* (Bruchaus *et al.*, 1992). The constant presence of *E. dispar* in the intestine for a prolonged period of time (at least 12 months) may induce stimulation of a secretory immune response that eventually may be reflected systemically, as has been observed in non-invasive intestinal infection due to other parasites (Char *et al.*, 1991). Lesions in the mucosa caused by other organisms could also allow the entry of *E. dispar* to present its antigens for the immune system. Therefore, crude *E. histolytica* antigen preparations are not recommended for the detection of antiamebic serum antibodies in areas endemic for a wide range of parasitic diseases (Lotter *et al.*, 1995).

A study by Gomez *et al.* (1997) that used Western blotting and showed that antibodies in

patients colonized by *E. dispar* cross-react with *E. histolytica* antigens is in support of this suggestion. Similarly, Jackson *et al.* (1985) had shown that up to 20 % of *E. dispar* infections might lead to cross-reactive seropositivity to *E. histolytica*. Therefore, considering the high prevalence of *E. dispar* in Wonji and Akaki, the crude antigen appears to over-estimate the seroprevalence of *E. histolytica* in both study areas.

The determination of seroprevalence based on the recombinant surface antigen, on the other hand, appears to be a more realistic estimate of invasive amebiasis in Wonji (4.8 %) and Akaki (0.6 %). The use of recombinant antigens and defined epitopes is more sensitive and specific than crude antigen, even though it does not eliminate the problem of persisting seropositivity that impairs sero-diagnosis (Lotter *et al.*, 1995; Stanley *et al.*, 1998). This is because individuals in endemic areas are repeatedly exposed to the parasite, as the result of which antibodies persist for months or years, following spontaneous or drug-induced loss of infection (Jackson *et al.*, 1985). The specific-serological findings on *E. histolytica* prevalence indicate that although the parasite was not detected by the PCR in Wonji and Akaki, it does not disprove its endemicity in these localities.

In symptomatic individuals, the presence of high titers of specific antibody is strongly correlated with the presence of invasive amebiasis in non-endemic countries (Bos *et al.*, 1980; Lotter *et al.*, 1995; Pillai *et al.*, 1999). Similarly, the fact that the recombinant surface antigen confirmed two cases of probably symptomatic individuals with high titers of specific antibody, as *E. histolytica* positive, is evidence for the endemicity of invasive amebiasis in the study sites. Thus, the use of selected, well-defined antigen preparations, such as surface recombinant antigen of *E. histolytica*, can be used as a more reliable

diagnostic method for invasive amebiasis in endemic countries.

Use of molecular diagnostic approach by using real-time PCR based on the SSU rRNA gene, to confirm endemicity of invasive amebiasis among high risk population, primary school children and prisoners from where high prevalence has been reported microscopically, was an additional proof that infection with *E. histolytica* is of low prevalence in Ethiopia. Thus, the low prevalence of *E. histolytica* in Wonji and Akaki could possibly be explained by the extensive use of metronidazole for treatment of erroneously diagnosed amebic infections.

The finding that specific DNA amplification did not detect any infection with *E. histolytica* among school children and prisoners, inspite of high prevalence report of *E. histolytica*/*E. dispar* infection by microscopy, is in agreement with what is already observed in Wonji and Akaki in the same study. Similar observations on specific DNA amplification detection of low prevalence of *E. histolytica* have been reported elsewhere in Africa, notably in Cote d'Ivoire and Ghana (Heckendorn *et al.*, 2002; Verweij *et al.*, 2004).

The three cyst-positive cases, from school children & prisoners, who were found negative in the real-time PCR, one showed inhibition (i.e. non-amplification of the internal control). When fecal samples from the other two cases were investigated further, by species-specific DNA hybridization after amplification of a part of the SSU-rRNA gene (Verweij *et al.*, 2003), they were found positive for *E. coli* and *E. hartmanni* or *E. coli*, *E. hartmanni* and an *E. polecki*-like *Entamoeba* species. In these two cases, the small cysts of *E. coli* or the larger ones of *E. hartmanni* or the *E. polecki*-like species were probably mis-identified microscopically as the cysts of *E. histolytica*/*E. dispar*.

The epidemiological picture of intestinal amebiasis seen in countries like Mexico, Bangladesh, and Vietnam (Palacio-Sanchez *et al.*, 1997; Haque *et al.*, 1997; Blessman *et al.*, 2002), where high proportions of cyst-excreters are reported to be infected with true and potentially invasive *E. histolytica* appears to be very different from what is seen in Ethiopia.

The better correlation of PCR results with the microscopic finding of *E. histolytica*/*E. dispar* cysts than with trophozoites indicates that the trophozoites are more easily confused with those of commensal *Entamoeba* and with fecal leukocytes. Therefore, using the cystic stage as a better criterion than the trophozoite stage may relatively reduce the difficulty of differentiating different species of *Entamoeba*.

The generally accepted view in Ethiopia that *E. histolytica* is a very common cause of intestinal infection seems to have prompted the lab-technicians to report most vegetative stages seen in stool examination as trophozoites of *E. histolytica*. This happened even though they were explicitly warned about the risks of such mistakes in advance. In the existing tradition of microscopy, in a diagnostic routine set-up, it appears very difficult to differentiate RBC-engulfing amoebae from non-engulfing, in wet smears. This is further supported by findings of the present investigation. It is possible that either trophozoites of other non-pathogenic intestinal amoebae or fecal macrophages are being misdiagnosed as *E. histolytica*. Furthermore, it is important to keep in mind that RBCs may be ingested but do not frequently appear in chronic amebic infections (Ackers, 2002).

Moreover, there are some reports of *E. dispar* ingesting RBCs (Haque *et al.*, 1995), making the criterion unreliable. The only published systematic study that tried to examine

the validity of the use of haematophagous trophozoites for diagnosis of invasive amebiasis was that of Gonzalez-Ruiz and colleagues (1994). In that study the authors suggest that 100 % specificity can be achieved using this microscopic criterion. However, their situation as a reference laboratory for amebiasis was far from being representative for routine diagnostic laboratories in endemic countries.

The application of PCR was to maximize the detection of genuine infection with *E. histolytica*, by focusing on haematophagous trophozoites, a morphological characteristic believed to be diagnostic (Gonzalez-Ruiz *et al.*, 1994), only providing confirmation to low prevalence of amebiasis. However, the fact that the technicians involved could not reliably make the distinction between small commensal trophozoites and large haematophageous trophozoites may have accounted for the underestimation of the prevalence. This presumably, may not be only due to the heavy workload of the technicians in the laboratories, but because of the tradition of identifying whatever motile amoeboid stages as trophozoites of *E. histolytica*. This shows that that the positive predictive value of microscopic diagnosis of *E. histolytica* is low and that alternative causes for the amebic complaints with which the patients present should always be taken seriously.

Invasive amebiasis appears to be absent according to this study even among HIV/AIDS patients with complaints of diarrhea in Ethiopia. The finding of significantly more *E. histolytica*/*E. dispar* infection by microscopy among HIV/AIDS male patients was different compared to Wonji and Akaki cohort diarrhea study participants where the proportion of infection between the two sexes was not significantly different. The age distribution, however, appears to follow similar pattern, increasing with age.

Only a few cases of invasive amebiasis in HIV-infected individuals have been reported in the literature. A single case with amebic colitis was reported from an autopsy series of 94 Mexican patients diagnosed with AIDS (Reed *et al.*, 1991). In another report, severe enterocolitis and peritonitis was ascribed for the death of an AIDS patient (Blanshard *et al.*, 1992). In this case, stool examinations for pathogens, including amebae, were negative, while a rectal biopsy showed histologic evidence for invasive amebiasis. There are also two reports from England (Sturgess *et al.*, 1992) and Japan (Ohnishi *et al.*, 1994) from homosexual AIDS patients with amebic dysentery, and a subsequent diagnosis of ulcerative colitis. But, none of these reports provide definitive evidence for the diagnosis of invasive amebiasis as the diarrhea could have been due to preexisting ulcerative colitis. Diagnosis of invasive amebiasis was also reported by biopsy in two patients with AIDS and Cytomegalovirus colitis (Fatkenheuer *et al.*, 1997). Most of these studies did not involve large number of study subjects and moreover, they did not do species specific diagnosis using molecular methods for *E. histolytica*.

There is no clear explanation for the rare occurrence of invasive amebiasis in HIV-infected patients in spite of the suggestion that the pathogenicity of the ameba could be enhanced by immunosuppression as was seen in those patients receiving corticosteroids (Eisert *et al.*, 1959; Kanani & Knight, 1969). It is well established that HIV infection can result in the impairment of cell-mediated immunity and patients with HIV infection would be expected to be more susceptible to invasive amebic infection.

The absence of infection with invasive *E. histolytica* among HIV/AIDS patients diagnosed by the species-specific real-time PCR is in agreement with other reports from the past. Burchard *et al.* (1986) had characterized and demonstrated all *Entamoeba* spp strains from

HIV-infected patients to be *E. dispar*. Also, in regions with high incidence of amebiasis, invasive disease is very rare in HIV-infected individuals (Jessurun *et al.*, 1992). As a result, amebiasis has not been included as an AIDS-defining infection by the Centers for Disease Control and Prevention (CDC, 1987 & 1993). The present study also reinforces this observation such that trophozoites observed in routine stool examination of HIV/AIDS patients have been determined to be *E. dispar*, when verified with species-specific diagnostic tests such as PCR.

Even though microscopy identified that a number of the study participants as infected with *E. histolytica/E. dispar*, it was only 25 % in agreement with the PCR finding. The rest apparently may have belonged to either the other commensal *Entamoeba* species or it could have been a misdiagnosis. The PCR, on the other hand, showed that 25 % of the study participants to be specifically infected with *E. dispar*, highlighting the high frequency of this parasite among AIDS patients.

Detection of twice more *E. dispar* infection in HIV/AIDS patients, when CD4 cells is less than 200 cells/ $\mu$ l calls for further detailed study to establish its possible association with immunosuppression. Thus, despite the general consensus for *E. dispar* to be non-pathogenic, its possible interaction with immunosuppression should not be completely dismissed as a subject of further investigation. This is because earlier reports had shown it to produce variable focal intestinal lesion in animals (Chadee *et al.*, 1985; Vohra *et al.*, 1989; Espinosa-Cantellano *et al.*, 1997) and to destroy epithelial cell monolayers *in vitro* (Espinosa-Cantellano *et al.*, 1998). There was also some evidence that it may cause pathological changes in some humans (McMillan *et al.*, 1984), though invasive lesions and

symptomatic infections have not been reported to date. Whether or not its implied pathogenic characteristics are strain dependant is unknown.

Considering the current practice of microscopic detection of quadrinucleated cysts and trophozoites as the only way to diagnose amebiasis, overreporting of infection with *E. histolytica* is likely to continue. In a survey in the Seychelles, Sargeant (1992) had demonstrated that replacing routine microscopy with culture and zymodeme characterization could drastically reduce the risk of overdiagnosing *E. histolytica* infections. But, these methods are tedious and time consuming, and are not fit for either routine diagnosis or research purposes in endemic countries.

## 7. CONCLUSIONS

The absence or low prevalence of infection with *E. histolytica* in this study appears to be consistent, both in areas with frequent utilization of metronidazole as well as in those where treatment is given less often. The implication of this for treatment and patient management are far reaching. Many people are treated with anti-amebic drugs for the mere presence of any ameba trophozoites because of the widespread impression of associating diarrhea with amebiasis. The result found among healthy study participants was consistent with the previous observations in Wonji and Akaki cohort population showing that there is an overdiagnosis of amebiasis while careful molecular analysis showed very low *E. histolytica* prevalence among diarrheal patients.

Demonstration of trophozoites or cysts in patients with diarrhea is the mainstay of diagnosis of intestinal amebiasis in many laboratories in endemic areas. For years this diagnosis was done by microscopic examination of stool, a technique that thought to identify most cases of amebic colitis with careful examination of at least three stool samples (Krogstad *et al.*, 1978). However, this method cannot distinguish between *E. histolytica* and *E. dispar*, it is unsuitable as a screening technique for epidemiological studies, and probably for patient care. Presumptive diagnosis of infection with *E. histolytica* can be made microscopically if trophozoites containing ingested red blood cells could be identified in the fecal specimens. Nevertheless, in view of the high frequency of *E. dispar* in many areas, dysentery due to entities such as shigellosis or campylobacteriosis will probably be misdiagnosed as intestinal amebiasis if microscopy is the sole diagnostic

criterion. Also, *E. dispar* is capable of ingesting red blood cells *in vitro* although this does not appear to occur in the colon. It is important to bear in mind that for this reason the presence of trophozoites without ingested red blood cells, even in a specimen with bloody diarrhea, does not enable the diagnosis of amebic dysentery to be made.

In the absence of appropriate diagnostic facilities for routine diagnosis of intestinal amebiasis, the existence of the two morphologically identical *Entamoeba* species presents a formidable challenge to all those prescribing antiprotozoan drugs. Given that many recommended treatments are based on prescriptions by outdated texts or "common practices", it is perhaps not surprising that traditional practices change slowly, if at all. Immediate treatment with the commonly available antiprotozoan drug, metronidazole, in many cases of diarrhea without specific diagnostic method is not appropriate and is not supported by epidemiological evidence (Butta & Vitry, 1996) as well as the findings of this study.

Data from this study suggest that all asymptomatic and nearly all patients with diarrhea infected with *Entamoeba* are colonized with *E. dispar*. Both *E. dispar* and *E. histolytica* being identical in their morphology, route of transmission and many other physiological characteristics, it might sound a bit bizarre to detect practically no *E. histolytica*. The most likely explanation lies in their very difference in terms of invasiveness and virulence. Such differences are even more difficult to assess in clinical practice but are demonstrable in animal inoculation studies in the laboratory.

Considering the non-invasive nature of *E. dispar*, it can be assumed the vast majority of asymptomatic cyst shedders would turn out to be infected with *E. dispar* and that all those infected with *E. histolytica* could be either clinically ill or probably would become so if not

treated. When confining its activity to the bowel lumen, *E. histolytica* produces the cysts necessary for transmission to new hosts, whereas under certain conditions, *E. histolytica* may go beyond the bounds of the mucosa, and invade the tissues. This invasive state is as abnormal for the ameba as it is for the host. Certainly those parasites, which have penetrated beyond the bowel wall, have ruled out all chances of a sustained posterity. Such amebae do not produce the cysts essential for survival in the external world contributing for the rare nature of *E. histolytica* compared to *E. dispar*.

Whatever the case, it does not reduce the need for the accurate, species-specific diagnosis of *E. histolytica* in faecal specimens. This is needed firstly because, since there is no way of knowing which infected persons will progress to clinical amebiasis, all should be treated; secondly because they are excreting cysts which can cause clinical amebiasis in others (as Walker and Sellards showed all those years ago) and thirdly, because only in this way we obtain accurate epidemiological data from which to make a better estimate of the burden of amebiasis on the health of the world.

## 8. RECOMMENDATIONS

Numerous studies, including the present one, have demonstrated the inadequacy of microscopic examination for diagnosis of intestinal amebiasis and liver abscess. Better approaches other than microscopy include either antigen detection or PCR to detect *E. histolytica* in stools. The available antigen detection test, unfortunately, suffers from the need to examine fresh or frozen (not preserved) stool specimens besides its poor sensitivity and specificity. There are now a number of well-validated PCR-based methods for distinguishing between *E. histolytica* and *E. dispar*. However, none is cheap and it is unlikely that they will be in routine use in many developing countries for sometime to come. Thus, further development of rapid, sensitive and cheap techniques for the diagnosis of amebiasis remain a major public health priority for the developing world.

There is a need for further work to establish the aetiology of diarrhea wrongly associated with amebae and explain the enigma of patients recovering following "anti-amebic" treatment. The commonly reported complaints of bloody mucoid diarrhea and the association of low CD4 with *E. dispar* infection among AIDS patients require alternative explanation. There is also a strong need for training and upgrading routine microscopic diagnosis of different *Entamoeba* species in order to minimize the overdiagnosis and overtreatment of intestinal amebiasis.

The wide spectrum of clinical manifestation observed among individuals infected with *E. dispar* is one of main questions, which has not been addressed fully. The existence of different strains of *E. dispar* in the same patient could be one of the reasons for the differences in signs and symptoms in infected individuals. Therefore, it is necessary to



## 9. REFERENCES

- Abd-Alla , M.D., T.F.H.G. Jackson , V. Gathiram , A.M. El-Hawey , and J.I. Ravdin . 1993. Differentiation of pathogenic *Entamoeba histolytica* infections from nonpathogenic infections by detection of galactose inhibitable adherence protein antigen in sera and feces. *J. Clin. Microbiol.* 31: 2845-2850.
- Ackers, J.P. 2002. The diagnostic implications of the separation of *Entamoeba histolytica* and *Entamoeba dispar*. *J.Biosci.* 27:573-578.
- Acuña-Soto, R., J. Samuelson, P. de Girolami, L. Zarate, F. Millan-Velasco, G. Schoolnick, and D. Wirth. 1993. Application of the polymerase chain reaction to the epidemiology of pathogenic and nonpathogenic *Entamoeba histolytica*. *Am. J. Trop. Med. Hyg.* 48:58-70.
- Adams, E.B. and I.N. MacLeod. 1977. Invasive amebiasis: amebic dysentery and its complications. *Medicine (Baltimore).* 56:315-324.
- Aguirre, A., D.C. Warhurst, F. Guhl, and I.A. Frame. 1995. Polymerase chain reaction-solution hybridization enzyme-linked immunoassay (PCR-SHELA) for the differential diagnosis of pathogenic and non-pathogenic *Entamoeba histolytica*. *Trans.R.Soc.Trop.Med.Hyg.* 89:187-188.
- Allason-Jones, E., A. Mindel, P.G. Sargeant, and P. Williams. 1986. *Entamoeba histolytica* as a commensal intestinal parasite in homosexual men. *N.Eng.J.Med.* 315:353-356.
- Anon. Nutrition Survey in Ethiopia. Report by the inter-departmental committee on nutrition for National Defense, U.S. 1959. Washington, D.C., Government Printing Press.
- Aristizabal, H., J. Acevedo, and M. Botero. 1991. Fulminant amebic colitis. *World J.Surg.* 15:216-221.
- Arvind, A.S., N. Shetty, and M.J.G. Farthing. 1988. Serodiagnosis of amebiasis. *Serodign.Immunother.Infect.Dis.* 2:79-84.
- Attia, R.A., H. Rizk, and S. Motawea. 1995. Importance of *E. histolytica* antigen in serodiagnosis and follow up of patients with amoebic liver abscess. *J.Egypt.Soc.Parasitol.* 25:485-490.
- Bapat, M.M. and G.G. Bhave. 1990. Counterimmunoelectrophoresis in the immunodiagnosis of amoebiasis. *J.Postgrad.Med.* 36:124-127.

- Bekele, M., B. Assefa, and C.T. Lo. 1989. Intestinal helminths in Akaki town, with special emphasis on epidemiology of *Schistosoma mansoni*. *Eth.Med.J.* 27:183-191.
- Beaver, P.C., R.C. Jung, H.J. Sherman, T.R. Reed, and T.A. Robinson. 1956. Experimental *Entamoeba histolytica* infections in man. *Am. J. Trop. Med. Hyg.* 5:1000-1009.
- Bhattacharya, S., A. Bhattacharya, L.S. Diamond, and A.T. Sodo. 1989. Circular DNA of *Entamoeba histolytica* encodes ribosomal RNA. *J. Protozool.* 36:455-458.
- Bhattacharya, A., R. Ghildyal, S. Bhattacharya, and S. Akther. 1991. Characterization of a monoclonal antibody that selectively recognizes a subset of *Entamoeba histolytica* identified by polymerase chain reaction. *J. Clin. Microbiol.* 29:2234-2239.
- Blanc, D. and P.G. Sargeant. 1991. *Entamoeba histolytica* zymodemes: exhibition of gamma and delta bands only of glucose phosphate isomerase and phosphoglucomutase may be influenced by starch content in the medium. *Expt. Parasitol.* 72:87-90.
- Blanshard, C., C. Collins, N. Francis, and B.G. Gazzard. 1992. Invasive amoebic colitis in AIDS patients. *AIDS.* 6:1043-1044.
- Blessmann, J., H. Buss, P.A. Ton Nu, B.T. Dinh, Q.T. Viet Ngo, A.L. Van, M.D. Abd-Alla, T.F.H.G. Jackson, J.I. Ravdin, and E. Tannich. 2002. Real-Time PCR for detection and differentiation of *Entamoeba histolytica* and *Entamoeba dispar* in fecal samples. *J. Clin. Microbiol.* 40:4413-4417.
- Bracha, R. and D. Mirelman. 1984. *Entamoeba histolytica* trophozoites : effects of bacteria, microaerobic conditions and metronidazole. *J. Expt. Med.* 160:353-369.
- Bracha, R., L.S. Diamond, J.P. Ackers, G.D. Burchard, and D. Mirelman. 1990. Differentiation of clinical isolates of *Entamoeba histolytica* by using specific DNA probes. *J. Clin. Microbiol.* 28:680-684.
- Braga, L.L., H. Ninomiya, J.J. McCoy, K. Adal, T. Wiedmer, C. Pham, P.J. Sims, and W.A. Petri, Jr. 1992. Inhibition of the complement membrane attack complex by the galactose-specific adhesin of *Entamoeba histolytica*. *Arch. Med. Res.* 23:133
- Braga, L.L., A.A.M. Lima, C.L. Sears, R.D. Newman, T. Wuhib, C.A. Paiva, R.L. Guerrant, and B.J. Mann. 1996. Seroepidemiology of *Entamoeba histolytica* in a slum in Northeastern Brazil. *Am. J. Trop. Med. Hyg.* 55:693-697.
- Britten, D., S.N. Wilson, R. McNERney, A.H. Moody, P.L. Chiodini, and J.P. Ackers. 1997. An improved colorimetric PCR-based method for detection and differentiation of *Entamoeba histolytica* and *Entamoeba dispar* in feces. *J. Clin. Microbiol.* 35:1108-1111.

- Bruchaus, I., N.W. Brattig, and E. Tannich. 1992. Recombinant expression, purification and biochemical characterization of a superoxide dismutase from *Entamoeba histolytica*. *Arch. Med. Res.* 23:27-29.
- Bruckner, D. 1992. Amebiasis. *Clin. Microbiol. Rev.* 5:356-369.
- Burchard, G.D., F.T. Hufert, and D. Mirelman. 1986. Characterization of 20 *Entamoeba histolytica* strains isolated from patients with HIV infection. *Infection.* 19:164
- Caballero-Salcedo, A., M. Viverose-Rogel, B. Salvatierra, R. Conyer, J. Sepulveda-Amor, G. Gutierrez, and L. Ortiz-Ortiz. 1994. Seroepidemiology of amebiasis in Mexico. *Am. J. Trop. Med. Hyg.* 50:412-419.
- CDC. 1987. Revision of the CDC surveillance case definition from acquired immunodeficiency syndrome. *Morb.Mortal.Weekly Rep.* 36:1-15.
- CDC. 1993. 1993 revised classification system for HIV infection and expanded surveillance case definition for AIDS among adolescents and adults. *Morb.Mortal.Weekly Rep.* 40:1-19.
- Chadee, K., J.M. Smith, and E. Meerovich. 1985. *Entamoeba histolytica*: electrophoretic isoenzyme patterns of strains and their virulence in the cecum of gerbils(*Meriones unguiculatus*). *Am.J.Top.Med.Hyg.* 34:870-878.
- Char, S., N. Shetty, M. Tnarasimham, E. Elliot, I.N. MacLeod, and M.J.G. Farthing. 1991. Serum antibody response in children with *Giardia lamblia* infection and identification of an immunodominant 57-kilodalton antigen. *Parasite Immunol.* 13:329-337.
- Cheesbrough, M. 2001. Parasitology tests. In *District Laboratory Practice in Tropical Countries*. M. Cheesbrough, editor. Cambridge University Press, Cambridge. 200-208.
- Choudhri, G., V. Prakash, A. Kumar, S.K. Shahi, and M. Sharma. 1991. Protective immunity to *Entamoeba histolytica* infection in subjects with antiamebic antibodies residing in a hyperendemic zone. *Scand.J.Infect.Dis.* 23:771-776.
- Clark, C.G. and L.S. Diamond. 1991. Ribosomal RNA genes of "pathogenic" and "nonpathogenic" *Entamoeba histolytica* are distinct. *Mol.Biochem.Parasitol.* 49:297-302.
- Clark, C.G. and L.S. Diamond. 1993a. *Entamoeba histolytica*: an explanation for the reported conversion of "nonpathogenic" amebae to the "pathogenic" form. *Exp. Parasitol.* 77:456-460.
- Clark, C.G. and L.S. Diamond. 1993b. *Entamoeba histolytica*: a method for isolate identification. *Exp. Parasitol.* 77:450-455.

- Clark, C.G. and A.J. Roger. 1995. Direct evidence for secondary loss of mitochondria in *Entamoeba histolytica*. *Pro. Natl. Acad. Sci.(USA)* 92:6518-6521.
- Clark, C.G. 1998. *Entamoeba dispar*, an organism reborn. *Trans. R. Soc. Trop. Med. Hyg.* 92:361-364.
- Cummins, A.J., A.H. Moody, K. Laloo, and P.L. Chiodini. 1994. Rapid latex agglutination test for extraluminal amoebiasis. *J.Clin.Pathol.* 47:647-648.
- De Bruijn, M.H.L. 1988. Diagnostic DNA amplification, no respite for the elusive parasite. *Parasitol. Today.* 4:293-295.
- Diamond, L.S. and C.G. Clark. 1993. A redescription of *Entamoeba histolytica* Schaudinn, 1903 (emended Walker, 1911) separating it from *Entamoeba dispar* Brumpt, 1925. *J.Euk.Microbiol.* 40:340-344.
- Editorial. 1986. On the three stages of amoebic research. *Lancet.* I:1133-1134.
- Eisert, J., J.E. Hannibal, and S.L. Sanders. 1959. Fatal amebiasis complicating corticosteroid management of pemphigus vulgaris. *N.Eng.J.Med.* 261:843-845.
- Elsdon-dew, R. 1968. The epidemiology of amoebiasis. *Trends In Parasitol.* 1:1-60.
- Espinosa-Cantellano, M., A. González-Robles, B. Chávez, G. Castañon, C. Argüello, A. Lázaro-Haller, and A. Martínez-Palomo. 1998. *Entamoeba dispar* : ultrastructure, surface properties, and cytopathic effect. *J.Euk.Microbiol.* 45:265-272.
- Espinosa-Cantellano, M., G. Castañon, and A. Martínez-Palomo. 1997. *In vivo* pathogenesis of *Entamoeba dispar*. *Arch. Med. Res.* 28(Suppl):S204-S206
- Evangelopoulos, A., G. Spanakos, E. Patsoula, N. Vakalis, and N. Legakis. 2000. A nested, multiplex, PCR assay for the simultaneous detection and differentiation of *Entamoeba histolytica* and *Entamoeba dispar* in faeces. *Ann. Trop. Med. Parasitol.* 94:233-240.
- Fätkenheuer, G., G. Arnold, H.-M. Steffen, C. Franzen, M. Schrappe, V. Diehl, and B. Salzberger. 1997. Invasive amoebiasis in two patients with AIDS and cytomegalovirus colitis. *J. Clin. Microbiol.* 35:2168-2169.
- Faust, E.C. and P.F. Russel. 1970. The tissue invading amebae, *Entamoeba histolytica*. In *Clinical Parasitology*. Lea & Febiger, editor. Philadelphia. 183-223.
- Feachem, R.G., D.J.G.H. Bradley, and D.D. Mara. 1983. Sanitation and Disease. In *Health Aspects of Excreta and Wastewater Management*. Wiley/World Bank, Chichester. 337-347.

- Fontanet, A.L. and T. Woldemichael. 1999. The Ethio-Netherlands AIDS Research Project (ENARP): description and major findings after four years of activities. *Eth.Med.J.* 37:9-24.
- Fontanet, A.L., T. Sahlu, T.R. de Wit, T. Messele, W. Masho, T. Woldemichael, H. Yeneneh, and R.A. Coutinho. 2000. Epidemiology of infections with intestinal parasites and human immunodeficiency virus (HIV) among sugar-estate residents in Ethiopia. *Ann.Trop.Med.Parasitol.* 94:269-278.
- Freeman, C.D., N.E. Klutman, and K.C. Lamp. 1997. Metronidazole: A therapeutic review and update. *Drugs.* 54:679-708.
- Frey, C.F., Y. Zhu, M. Suzuki, and S. Isaji. 1989. Liver abscesses. *Surgical Clinics of North America.* 69:259-271.
- Fuchs, G., G. Ruiz-Palacios, and L.K. Pickering. 1988. Amebiasis in the pediatric population. In Amebiasis: Human Infection by *Entamoeba histolytica*. J.I. Ravdin, editor. Churchill Livingstone, New York. 594-613.
- Gathiram, V. and T.F. Jackson. 1987. A longitudinal study of asymptomatic carriers of pathogenic zymodemes of *Entamoeba histolytica*. *S.Afr.Med.J.* 72:669-672.
- Gatti, S., R. Mahdi, A. Bruno, C. Cevini, and M. Scaglia. 1998. A survey of amoebic infection in the Wonji area of central Ethiopia. *Ann.Trop.Med.Parasitol.* 92:173-179.
- Gati, S., G. Swierczynski, F. Robinson, M. Anselmi, J. Corrales, J. Moreira, G. Mjontalvo, A. Bruno, R. Mascrati, Z. Bisoffi, and M. Scaglia. 2002. Amebic infections due to the *Entamoeba histolytica-Entamoeba dispar* complex: a study of the incidence in a remote rural area of Ecuador. *Am.J.Trop.Med.Hyg.* 67:123-127.
- Gibney, E.J. 1990. Amoebic liver abscess. *Br.J.Surg.* 77:843-844.
- Gill, G.V. and D.R. Bell. 1980. Persisting tropical diseases amongst former prisoners of war of the Japanese. *Practitioner.* 224:801-803.
- Goldmeier, D., P.G. Sargeant, and A.B. Price. 1986. Is *Entamoeba histolytica* in homosexual men a pathogen? *Lancet.* 1:641
- Gomez, A., O. Leyva, M.d.C. Martínez, G. Garduño, F. Ramos, P. Moran, E.I. Melendro, O. Muñoz, and C. Ximénez. 1997. Prospective study of *Entamoeba dispar* infection in a cohort of mothers and their infants: relationship to serum antibody response. *Am.J.Trop.Med.Hyg.* 57:530-537.
- Gonin, P. Haque, R., N.U. Mollah, I.K.M. Ali, K. Alam, A. Eubanks, D. Lysterly, and W.A. Petri, Jr. 2000. Diagnosis of amebic liver abscess and intestinal infection with the TechLab *Entamoeba histolytica* II antigen detection and antibody tests. *J.Clin.Microbiol.* 38:3235-3239.

- and L. Trudel. 2003. Detection and differentiation of *Entamoeba histolytica* and *E. dispar* isolates in clinical samples by PCR and enzyme-linked immunosorbent assay. *J.Clin.Microbiol.* 41:237-241.
- Gonzalez-Ruiz, A., R. Haque, A. Aguirre, G. Castañon, A. Hall, F. Guhl, G. Ruiz-Palacios, M.A. Miles, and D.C. Warhurst. 1994. Value of microscopy in the diagnosis of dysentery associated with invasive *Entamoeba histolytica*. *J. Clin. Pathol.* 47:236-239.
- Gonzalez, J.P. 1986. Left pleural effusion as a complication of amebic hepatic abscess: report of two cases. *Eth.Med.J.* 24:31-34.
- Grundy, M.S., A. Voller, and D. Warhurst. 1987. An enzyme-linked immunosorbent assay for the detection of *Entamoeba histolytica* antigens in fecal material. *Trans. R. Soc. Trop. Med. Hyg.* 81:627-632.
- Guerrant, R.L. 1986. The global problem of amebiasis: current status, research needs, and opportunities for progress. *Rev.Infect.Dis.* 8:218-227.
- Haque, R., K. Kress, S. Wood, T.F.H.G. Jackson, D. Lyerly, T. Wilkins, and W.A. Petri, Jr. 1993. Diagnosis of pathogenic *Entamoeba histolytica* infection using a stool ELISA based on monoclonal antibodies to the galactose-specific adhesin. *J.Infect.Dis* 167:247-249.
- Haque, R., L.M. Neville, P. Hahn, and W.A. Petri, Jr. 1995. Rapid diagnosis of *Entamoeba* infection by using *Entamoeba* and *Entamoeba histolytica* stool antigen detection kits. *J. Clin. Microbiol.* 33:2558-2561.
- Haque, R., A.S.G. Faruque, P. Hahn, D.M. Lyerly, and W.A. Petri, Jr. 1997. *Entamoeba histolytica* and *Entamoeba dispar* infection in children in Bangladesh. *J.Infect.Dis.* 175:734-736.
- Haque, R., I.K.M. Ali, S. Akther, and W.A. Petri, Jr. 1998. Comparison of PCR, isoenzyme analysis, and antigen detection for diagnosis of *Entamoeba histolytica* infection. *J. Clin. Microbiol.* 36:449-452.
- Haque, R., I.K.M. Ali, and W.A. Petri, Jr. 1999. Prevalence and immune response to *Entamoeba histolytica* infection in preschool children in Bangladesh. *Am. J. Trop. Med. Hyg.* 60:1031-1034.
- Haque, R., I.K.M. Ali, R.B. Sack, B.M. Farr, G. Ramakrishnan, and W.A. Petri. 2001. Amebiasis and mucosal IgA antibody against the *Entamoeba histolytica* adherence lectin in Bangladeshi children. *J.Infect.Dis.* 183:1787-1793.
- Harriman, G.R., E.R. Podack, A.L. Braude, L.C. Corbeil, A.F. Esser, and J.G. Curd. 1982. Activation of complement by serum-resistant *Neisseria gonorrhoeae*. Assembly of the membrane attack complex without subsequent cell death. *J.Expt.Med.* 156:1235-1249.

- Healy, G.R. 1986. Immunologic tools in the diagnosis of amebiasis: epidemiology in the United States. *Rev.Infect.Dis.* 8:239-246.
- Heckendorn, F., E.K. N'Goran, I. Felger, P. Vounatsou, A. Yapi, A. Oettli, H.P. Marti, M. Dobler, M. Traore, K.L. Lohourignon, and C. Lengeler. 2002. Species-specific field tests of *Entamoeba* spp. in an area of high endemicity. *Trans R Soc Trop Med Hyg* 96:521-528.
- Hossain, M.M., I. Lijungstorm, R.I. Glass, L. Lundin, B.J. Stoll, and G. Huldt. 1983. Amoebiasis and giardiasis in Bangladesh: parasitological and serological studies. *Trans. R. Soc. Trop. Med. Hyg.* 77:552-554.
- Hughes, M.A. and W.A. Petri. 2000. Amebic liver abscess. *Infectious Disease Clinics of North America.* 14:565-582.
- Hung, C.C., P.J. Chen, S.M. Hsieh, J.M. Wong, C.T. Fang, S.C. Chang, and M.Y. Chen. 1999. Invasive amoebiasis: an emerging parasitic disease in patients infected with HIV in an area endemic for amoebic infection. *AIDS.* 13:2421-2428.
- Huston, C.D. and W.A. Petri, Jr. 1998. Host-pathogen interaction in amebiasis and progress in vaccine development. *Eur. J. Clin. Microbiol. Infect. Dis.* 17:601-614.
- Irusen, E.M., T.F.H.G. Jackson, and A.E. Simjee. 1992. Asymptomatic intestinal colonization by pathogenic *Entamoeba histolytica* in amebic liver abscess - prevalence, response to therapy, and pathogenic potential. *Clin. Infect. Dis.* 14:889-893.
- Jackson, T.F.H.G., V. Gathiram, and A.E. Simjee. 1985. Seroepidemiological study of antibody response to the zymodemes of *Entamoeba histolytica*. *Lancet.* 1:716-719.
- Jackson, T.F.H.G. 1998. *Entamoeba histolytica* and *Entamoeba dispar* are distinct species; clinical, epidemiological and serological evidence. *Int.J.Parasitol.* 28:181-186.
- Jackson, T.F.H.G. 2000. Epidemiology. In Amebiasis. J.I.Ravdin, editor. Imperial College Press, London, United Kingdom. 47-63.
- Jammal, M.A., K. Cox, and B. Ruebner. 1985. Amebiasis presenting as rectal bleeding without diarrhea in childhood. *J.Pediatr.Gastroenterol.Nutr.* 4:294-296.
- Jessurun, J., L.P. Barrón-Rodríguez, G. Fernández-Tinoco, and M. Hernández-Avila. 1992. The prevalence of invasive amebiasis is not increased in patients with AIDS. *AIDS.* 6:307-309.
- Johnsten, J.H., J.B. Stewart, and D.M. Roberts. 1980. Intestinal amoebiasis for 36 years. *Postgrad.Med.J.* 56:802-803.

- Joiner, K.A., E.J. Brown, and M.M. Frank. 1984. Complement and bacteria: chemistry and biology in host defense. *Ann.Rev.Immun.* 2:491
- Kanani, S.R. and R. Knight. 1969. Relapsing amoebic colitis of 12 years' standing exacerbated by corticosteroides. *Br.Med.J.* 2:614
- Katzenstein, D., V. Rickerson, and A. Braude. 1982. New concepts of amebic liver abscess derived from hepatic imaging, serodiagnosis, and hepatic enzymes in 67 consecutive cases in San Diego. *Medicine (Baltimore)*. 61:237-246.
- Katzwinkel-Waldarsch, S., T. Loscher, and H. Rinder. 1994. Direct amplification of the polymerase chain reaction to the epidemiology of pathgenic and nonpathgenic *Entamoeba histolytica* DNA from stool specimens. *Am.J.Top.Med.Hyg.* 51:115-118.
- Kloos, H. and T.M. TesfaYohannes. 1993. Intestinal Parasites in Ethiopia. In Ecology of Health and Disease in Ethiopia. H.a.Z.A. Kloos, editor. West View Press, Oxford. 223-225.
- Knobloch, J. and E. Mannweiler. 1983. Development and persistence of antibodies to *Entamoeba histolytica* in patients with amebic liver abscess: Analysis of 216 cases. *Am. J. Trop. Med. Hyg.* 32:727-732.
- Krogstad, D.J., H.C. Spencer, and G.R. Healy. 1978. Current concepts in parasitology: amebiasis. *N.Engl.J.Med.* 298:262-265.
- Lee, K.C., O. Yamazaki, H. Hamba, Y. Sakaue, H. Kinoshita, K. Hirohashi, and S. Kubo. 1996. Analysis of 69 patients with amebic liver abscess. *J. Gastroenterol.* 31:40-45.
- Levine, N.D., J.O. Corliss, and F.E.G. Cox. 1980. A newly revised classification of the protozoa. *J.Protozool.* 27:37-58.
- Lewis, E.A. and A.U. Antia. 1969. Amoebic colitis: Review of 295 cases. *Trans. R. Soc. Trop. Med. Hyg.* 63:633-638.
- Lotter, H., E. Mannweiler, M. Schreiber, and E. Tannich. 1992. Sensitive and specific serodiagnosis of invasive amoebiasis by using a recombinant surface protein of pathogenic *Entamoeba histolytica*. *J.Clin.Microbiol.* 30:3163-3167.
- Lotter, H., E. Mannweiler, and E. Tannich. 1993. Crude or recombinant proteins applied to latex agglutination, complement fixation and enzyme linked immunosorbent assay for the diagnosis of invasive amebiasis. *Trop.Med, Parasitol.* 44:277-280.
- Lotter, H., T.F.H.G. Jackson, and E. Tannich. 1995. Evaluation of three serological tests for the detection of antiamebic antibodies applied to sera of patients from an area endemic for amebiasis. *Trop.Med, Parasitol.* 46:180-182.

- Martinez-Palomo, A., A. Gonzalez-Robles, and M. De la Torre. 1973. Selective agglutination of pathogenic strain of *Entamoeba histolytica* induced Con A. *Nat.New Biol.* 245:186-187.
- Martinez-Palomo, A. and M. Espinoza-Cantellano. 1999. Intestinal Amoeba. In *Microbiology and Microbial Infections*. L. Collier, A. Balows, and M. Sussman, editors. Oxford University Press, Inc., New York. 157-177.
- McConnel, E. and G.C. Armstrong. 1976. Intestinal parasitism in fifty communities on the central plateau of Ethiopia. *Eth.Med.J.* 14:159-168.
- McMillan, A.H., H.M. Gilmour, G. cNeillage, and G. Scott. 1984. Amoebiasis in homosexual men. *Gut.* 25:356-360.
- Mirelman, D., R. Brach, A. Chayen, A. Aust-Kettis, and L.S. Diamond. 1986. *Entamoeba histolytica* :effect of growth conditions and bacterial associates on isoenzyme patterns and virulence. *Expt.Parasitol.* 62:142-148.
- Mirelman, D., Y. Nuchamowitz, and T. Stolarsky. 1997. Comparison of use of enzyme-linked immunosorbent assay-based kits and PCR amplification of rRNA genes for simultaneous detection of *Entamoeba histolytica* and *E. dispar*. *J.Clin.Microbiol.* 35:2405-2407.
- Mirelman, D. 2003. Unresolved and Open Questions in Research. In *Amebiasis*. J. Ravdin, editor. Imperial College Press, London. 171-186.
- Moazam, F. and Z. Nazir. 1998. Amebic liver abscess: Spare the knife but save the child. *J.Pediatr.Surg.* 33:119-122.
- Molineaux, L., J. Plorde, and P. Sasony. 1966. Analysis of medical admissions to the Gondar Hospital (1963-1965). *Eth.Med.J.* 5:47-56.
- Mondragon Sanchez, R., T. Corte Espinoza, Y. Alonzo Fierro, M.I. Labra Villalobos, and R.B. Maldonado. 1995. Amebic liver abscess: 'A 5 year Mexican experience with a multimodality approach'. *Hepato-Gastroenterology.* 42:473-477.
- Moss, D.M. and H.M. Mathews. 1987. A fast electrophoretic isoenzyme technique for the identification of invasive and non-invasive *Entamoeba histolytica* and "*E. histolytica*-like" organisms. *J.Protozool.* 34:253-255.
- Niesters, H.G. 2002. Clinical virology in real time. *J.Clin.Virol.* 25:S3-S12
- Okhuysen, P.C. 2001. Traveler's diarrhea due to intestinal protozoa. *Travel Medicine.* 33:110-114.
- Ohnishi, K., M. Murata, and E. Okuzawa. 1994. Symptomatic amebic colitis in a Japanese homosexual AIDS patient. *Intern. Med.* 33:120-122.

- Ohnishi, K. and M. Murata. 1997. Present characteristics of symptomatic amebiasis due to *Entamoeba histolytica* in the east-southeast area of Tokyo. *Epidemiol.Infect.* 119:363-367.
- Oyerinde, J.P.O., O. Ogunbi, and A.A. Alonge. 1977. Age and sex distribution of infections with *Entamoeba histolytica* and *Giardia intestinalis* in the Lagos population. *Intl.J.Epidemiol.* 6:231-234.
- Palacio-Sanchez, A., R. Sandoval-Jabalera, L. Fonte, and A. Valdez. 1997. Epidemiological study of amoebiasis in Chihuahua, Mexico. *Arch Med Res* 28:309-310.
- Patel, A.S. and P.H. DeRidder. 1989. Amebic colitis masquerading as acute inflammatory bowel disease: the role of serology in its diagnosis. *J.Clin.Gastroenterol.* 11:407-410.
- Perez, T.R. 1986. Pathology of amoebiasis. In Amebiasis. A. Martinez-Palomo, editor. Elsevier, Oxford. 79-82.
- Petri, W.A., R. Haque, K. Kress, S. Wood, T. Wilkins, T.F.H.G. Jackson, and D. Lyerly. 1993. Predictive value of diagnostic tests and prevalence of invasive *Entamoeba histolytica* infection - reply [Letter]. *J. Infect. Dis.* 168:514-515.
- Petri, W.A. and R.L. Schnaar. 1995. Purification and characterization of galactose-specific and N-galactosamine-specific adhesin lectin of *Entamoeba histolytica*. *Meths.Enzymol.* 253:98-104.
- Petri, W.A. 1996. Recent advances in amebiasis. *Crit. Rev. Clin. Lab. Sci.* 33:1-37.
- Petri, W.A. and U. Singh. 1999. Diagnosis and management of amebiasis. *Clin. Infect. Dis.* 29:1117-1125.
- Pillai, D.R., J.S. Keystone, D.C. Sheppard, J.D. MacLean, D.W. MacPherson, and K.C. Kain. 1999. *Entamoeba histolytica* and *Entamoeba dispar*: Epidemiology and comparison of diagnostic methods in a setting of nonendemicity. *Clin. Infect. Dis.* 29:1315-1318.
- Polderman, A.M. 1999. Medische Parasitologie, handleiding bij de laboratoriumdiagnostiek, derde druk, Bohn stafleu van Loghum, HOuten/Diegem.
- Ralls, P.W., P.F. Barnes, D.R. Radin, P. Colletti, and J. Halls. 1987. Sonographic features of amebic and pyogenic liver abscesses: a blinded comparison. *AJR.* 143:499-501.
- Ramos, F., R. Zurabian, P. Moran, M. Ramiro, A. Gomez, C.G. Clark, E.I. Melandro, G. Garcia, and C. Ximenez. 1999. The effect of formalin fixation on the polymerase

chain reaction characterization of *Entamoeba histolytica*. *Trans. R. Soc. Trop. Med. Hyg.* 93:335-336.

- Randal, G.R., Goldsmith R.S., J. Shek, S. Mehalko, and D. Heynman. 1984. Use of the enzyme linked immunosorbent assay (ELISA) for detection of *Entamoeba histolytica* antigen in fecal samples. *Trans. R. Soc. Trop. Med. Hyg.* 78:593-595.
- Ravdin, J.I., T.F.H.G. Jackson, W.A. Petri, C.F.M. Murphy, B.L.P. Unger, V. Gathiram, J. Skillogiannis, and A.E. Simjee. 1990. Association of serum anti-adherence lectin antibodies with invasive amebiasis and asymptomatic pathogenic *Entamoeba histolytica* infection. *J.Infect.Dis.* 162:768-772.
- Ravdin, J.I. and W.A. Petri. 1995. *Entamoeba histolytica* (Amebiasis). In Principle and Practice of Infectious Diseases. G.L. Mandell, J.E. Benett, and R. Dolin, editors. Churchill Livingstone, New York. 2395-2407.
- Reed, S.L. and I. Gigli. 1990. Lysis of complement-sensitive *E. histolytica* by activated terminal complement components. Initiation of complement activation by an extracellular neutral cysteine proteinase. *J.Clin.Invest.* 86:1815-1822.
- Reed, S.L., D.W. Wessel, and C.E. Davis. 1991. *Entamoeba histolytica* infection and AIDS. *Am.J.Med.* 90:269-271.
- Reed, S.L. 1998. *Entamoeba histolytica* and other intestinal *Amoeba*. In Infectious diseases. S.L. Gorbach, J.G. Bartlett, and N.R. Blacklow, editors. W.B.Saunders Company, Philadelphia. 2393-2399.
- Reed, S.L. 2000. Clinical Manifestations and Diagnosis. In Amebiasis. J.I. Ravdin, editor. Imperial College Press, London. 113-126.
- Rees, C.W. 1955. Introduction. In Problems in Amoebiasis. Charles William Rees, editor. Thomas Publisher, Springfield, Illinois, USA. 3-15.
- Restrepo, M.I., Z. Restrepo, C.L. Elsa Villareal, A. Aguirre, and M. Restrepo. 1996. Diagnostic tests for amoebic liver abscess: comparison of enzyme-linked immunosorbent assay (ELISA) and counter immunoelectrophoresis (CIE). *Rev.Soc.Bras, Med.Trop.* 29:27-32.
- Rivera, W.L., H. Tachibana, M.R.A. Silva-Tahat, H. Uenura, and H. Kanbara. 1996. Differentiation of *Entamoeba histolytica* and *E. dispar* DNA from cysts present in stool specimens by polymerase chain reaction: its field application in the Philippines. *Parasitol Res.* 82:585-589.
- Sargeant, P.G. and J.E. Williams. 1978. The differentiation of invasive and non-invasive *Entamoeba histolytica* by isoenzyme electrophoresis. *Trans.R.Soc.Trop.Med.Hyg.* 72:519-521.

- Sargeaunt, P.G. 1985. Zymodemes expressing possible genetic exchange in *Entamoeba histolytica*. *Trans. R. Soc. Trop. Med. Hyg.* 79:86-89.
- Sargeaunt, P.G. 1987. The reliability of *Entamoeba histolytica* zymodemes in clinical diagnosis. *Parasitol. Today.* 3:40-43.
- Sargeaunt, P.G. 1992. A survey of *Entamoeba histolytica* and *Entamoeba dispar* (Brumpt) infections on Mahé, The Seychelles. *Arch. Med. Res.* 23:265-267.
- Seeto, R.K. and D.C. Rocky. 1999. Amebic Liver Abscess: Epidemiology, clinical features, and outcome. *West J.Med.* 170:104-109.
- Sehgal, D., V. Mittal, S. Ramachandran, S.K. Dhar, A. Bhattacharya, and S. Bhattacharya. 1994. Nucleotide sequence organisation and analysis of the nuclear ribosomal DNA circle of the protozoan parasite *Entamoeba histolytica*. *Mol.Biochem.Parasitol.* 67:205-214.
- Sehgal, R., M. Abd-Alla, A.H. Moody, P.L. Chiodini, and J.P. Ackers. 1995. Comparison of two media for the isolation and short-term culture of *Entamoeba histolytica* and *E. dispar*. *Trans. R. Soc. Trop. Med. Hyg.* 89:394
- Sepulveda, B. and A. Martínez-Palomo. 1984. Amebiasis. In Tropical Geographical Medicine. K.S. Warren and A.A.F. Mahmoud, editors. McGraw-Hill, New York. 305-318.
- Sharma, M.P., S. Dasarathy, S. Sushma, and N. Verma. 1995. Long term follow-up of amebic liver abscess: clinical and ultrasound patterns of resolution. *Trop.Gastroenterol.* 16:24-28.
- Singh, U. and W.A. Petri . 2001. Amebas. In Principles and Practice of Clinical Parasitology. S.H. Gillespie and R.D. Pearson, editors. John Wiley & Sons, LTD, New York. 197-218.
- Speelman, P., I. Kabit, and M. Islam. 1984. Distribution and spread of colonic lesion in Shigellosis: a colonoscopic study. *J.Infect.Dis.* 50:899-903.
- Speelman, P., R. McGlaughlin, I. Kabbir, and T. Butler. 1987. Differential clinical features and stool findings in shigellosis and amoebic dysentery. *Trans. R. Soc. Trop. Med. Hyg.* 81:549-551.
- Spirman, H.J. and J. Shattach. 1984. An outbreak of amoebic infection in a kibbutz population. *Trans. R. Soc. Trop. Med. Hyg.* 78:346-348.
- Spitzer, D.R. 1963. Pleurisy with *Entamoeba histolytica* in the effusion. *Eth.Med.J.* 1:125-126.
- Stanley, S.L. 1997. Progress towards development of a vaccine for amebiasis. *Clin. Microbiol. Rev.* 10:637-649.

- Stanley, S.L., T.F.H.G. Jackson, L. Foster, and S. Singh. 1998. Longitudinal study of the antibody response to recombinant *Entamoeba histolytica* antigens in patients with amebic liver abscess *Am. J. Trop. Med. Hyg.* 58:414-416.
- Stanley, S.L. 2003. Amoebiasis. *Lancet.* 361:1025-1034.
- Strachan, W.D., P.L. Chiodini, W.M. Spice, A.H. Moody, and J.P. Ackers. 1988. Immunological differentiation of pathogenic and non-pathogenic isolates of *Entamoeba histolytica*. *Lancet.* 1:561-563.
- Sturgess, I., S.M. Greenfield, J. Teare, and O'Doherty. 1992. Ulcerative colitis developing after amoebic dysentery in a haemophilic patient with AIDS. *Gut.* 33:408-410.
- Tachibana, H., S. Ihara, S. Kobayashi, Y. Kaneda, T. Tacheuchi, and Y. Watanabe. 1991. Differences in genomic DNA sequences between pathogenic and nonpathogenic isolates of *Entamoeba histolytica* identified by polymerase chain reaction. *J.Clin.Microbiol.* 29:2234-2239.
- Tachibana, H., S. Kobayashi, K. Nagakura, Y. Kandeda, and T. Takeuchi. 2000. Asymptomatic cyst passers of *Entamoeba histolytica* but not *Entamoeba dispar* in institutions for the mentally retarded in Japan. *Parasitol.Intl.* 49:31-35.
- Takeuchi, T., E. Okuzawa, and T. Nozaki. 1989. High seropositivity of Japanese homosexual men for amebic infection. *J.Infect.Dis.* 159:808
- Tannich, E., R.D. Horstman, J. Knobloch, and H.H. Arnold. 1989. Genomic DNA differences between pathogenic and non-pathogenic *Entamoeba histolytica*. *Proc.Natl.Acad.Sci.USA* 86:5118-5122.
- Tannich, E. and G.D. Burchard. 1991. Differentiation of pathogenic from nonpathogenic *Entamoeba histolytica* by restriction fragment analysis of a single gene amplified in vitro. *J.Clin.Microbiol.* 29:250-255.
- Tannich, E. and R.D. Horstman. 1992. Codon usage in pathogenic *Entamoeba histolytica*. *J.Mol.Evol.* 34:272
- Torrey, E.F. 1965. A medical survey of the Saysay people in the Blue Nile gorge. *Eth.Med.J.* 4:155-165.
- Troll, H., H. Marti, and N. Weiss. 1997. Simple differential detection of *Entamoeba histolytica* and *Entamoeba dispar* in fresh stool specimens by sodium acetate-acetic acid-formalin concentration and PCR. *J. Clin. Microbiol.* 35:1701-1705.
- Tsega, E. and D. Nadew. 1972. The threat of amoeba cyst carriers among hospital food handlers. *Eth.Med.J.* 10:47-52.
- Verweij, J.J., L. van Lieshout, C. Blotkamp, E.A. Brienen, S. van Duivenvoorden, M. van Esbroeck, and A.M. Polderman. 2000a. Differentiation of *Entamoeba*

*histolytica* and *Entamoeba dispar* using PCR-SHELA and comparison of antibody response. *Arch.Med.Res.* 31:S44-S46

- Verweij, J.J., J. Blotkamp, E.A.T. Brienen, A. Aguirre, and A.M. Polderman. 2000b. Differentiation of *Entamoeba histolytica* and *Entamoeba dispar* cysts using polymerase chain reaction on DNA isolated from faeces with spin columns. *Eur. J. Clin. Microbiol. Infect. Dis.* 19:358-361.
- Verweij, J.J., A.M. Polderman, and C.G. Clark. 2001. Genetic variation among human isolates of uninucleated cyst-producing *Entamoeba* species. *J.Clin.Microbiol.* 39:1644-1646.
- Verweij, J.J., D. Laeijendecker, E.A. Brienen, L. van Lieshout, and A.M. Polderman. 2003. Detection and identification of *Entamoeba* species by reverse line hybridization in stool samples. *J.Clin.Microbiol.* 41:5041-5045.
- Verweij, J.J., F. Oostvogel, E.A. Brienen, A. Nang-Beifubah, J. Ziem, and A. Polderman. 2004. Prevalence of *Entamoeba histolytica* and *Entamoeba dispar* in northern Ghana. *Trop.Med.Int.Hlth.* 8:1153-1156.
- Vohra, H., H.S. Bhatti, N.K. Ganguly, and R.C. Mahajan. 1989. Virulence of pathogenic and non-pathogenic zymodemes of *Entamoeba histolytica* (Indian strains) in guinea pigs. *Trans. R. Soc. Trop. Med. Hyg.* 83:648-650.
- Walderich, B., A. Weber, and J. Knobloch. 1997. Differentiation of *Entamoeba histolytica* and *Entamoeba dispar* from German travellers and residents of endemic regions. *Am. J. Trop. Med. Hyg.* 57:70-74.
- Walsh, J.A. 1986. Problems in recognition and diagnosis of amebiasis: estimation of the global magnitude of morbidity and mortality. *Rev.Infect.Dis.* 8:228-238.
- Wang, L. 1965. Helminthiasis in Begemdir and Semien Province. *Eth.Med.J.* 4:19-26.
- Wanke, C., T. Butler, and M. Islam. 1988. Epidemiologic and clinical features of invasive amebiasis in Bangladesh: a case-control comparison with other diarrheal diseases and postmortem findings. *Am.J.Top.Med.Hyg.* 38:335-341.
- Weinke, T., B. Friedrich-Janicke, P. Hopp, and K. Janitschke. 1989. Prevalence and clinical importance of *Entamoeba histolytica* in two high-risk groups: travelers return from the tropics and male homosexuals. *J.Infect.Dis.* 161:1029-1031.
- Weiss, J.B. 1995. DNA probes and PCR for diagnosis of parasitic infections. *Clin. Microbiol. Rev.* 8:113-130.
- WHO. 1997. WHO/PAHO/UNESCO report of a consultation of experts on amoebiasis. Mexico City, Mexico. 1-4.

- Wittwer, C.T., M.G. Herrmann, A.A. Moss, and R.P. Rasmussen. 1997. Continuous fluorescence monitoring of rapid cycle DNA amplification. *Bio. Techniques.* 22:130-138.
- Wopnick, S. 1973. The recognition of amebiasis in the acute abdomen. *Practitioner.* 211:71
- Wynants, H., J. Van den Ende, J. Randria, A. Van Gompel, E. Van den Enden, C. Brands, B. Cooremans, P. Michiels, L. Veerbist, and R. Colebunders. 1995. Diagnosis of amebic infection of the liver: report of 36 cases. *Ann. Soc. Belge. Med. Trop.* 75:297-303.
- Zengzhu, G., R. Bracha, Y. Nuchamowitz, W. Cheng-I, and D. Mirelman. 1999. Analysis by enzyme-linked immunosorbent assay and PCR of human liver abscess aspirates from patients in China for *Entamoeba histolytica*. *J.Clin.Microbiol.* 37:3034-3036.

## 10. ANNEX

### I. QUESTIONNAIRE DIARRHEA STUDY FROM UNSCHEDULED VISIT OF THE COHORT PARTICIPANTS AND THEIR FAMILY

LAB ID

#### 1. PERSONAL IDENTIFICATION

Subject ID (if participant)

Sex

Age

Name (if family member)

Date of visit

#### 2. ENROLMENT CRITERIA

DIARRHOEA: duration

< 1 week

1-4 weeks

>4 weeks

### 3. HISTORY

Put "✓" mark in the given boxes after identifying patients complaints/ signs & symptoms

#### 3.1 CLINICAL HISTORY

|                                       | YES                      | NO                       |
|---------------------------------------|--------------------------|--------------------------|
| Watery                                | <input type="checkbox"/> | <input type="checkbox"/> |
| Mucoid/bloody diarrhoea               | <input type="checkbox"/> | <input type="checkbox"/> |
| Tenesmus                              | <input type="checkbox"/> | <input type="checkbox"/> |
| Constipation                          | <input type="checkbox"/> | <input type="checkbox"/> |
| Increased gas (flatulence)            | <input type="checkbox"/> | <input type="checkbox"/> |
| Abdominal pain                        | <input type="checkbox"/> | <input type="checkbox"/> |
| Weight loss                           | <input type="checkbox"/> | <input type="checkbox"/> |
| Fever                                 | <input type="checkbox"/> | <input type="checkbox"/> |
| Metronidazole taken the last 2 months | <input type="checkbox"/> | <input type="checkbox"/> |

#### 3.2 SIGNS & SYMPTOMS

|                  | YES<br>NA*               | NO                       |                          |
|------------------|--------------------------|--------------------------|--------------------------|
| Liver tenderness | <input type="checkbox"/> | <input type="checkbox"/> | <input type="checkbox"/> |
| Sweats           | <input type="checkbox"/> | <input type="checkbox"/> | <input type="checkbox"/> |
| Chills           | <input type="checkbox"/> | <input type="checkbox"/> | <input type="checkbox"/> |
| Vomiting         | <input type="checkbox"/> | <input type="checkbox"/> | <input type="checkbox"/> |
| Weakness         | <input type="checkbox"/> | <input type="checkbox"/> | <input type="checkbox"/> |
| Mild jaundice    | <input type="checkbox"/> | <input type="checkbox"/> | <input type="checkbox"/> |

\* NOT APPLICABLE

### 4. LAB INVESTIGATION REPORT

#### a. Macroscopy

##### i. Consistency (one choice)

- Formed
- Soft
- Watery
- Diarrhea

Normal

ii. Appearance (one choice)

Bloody

Mucoid

Bloody/Mucoid

Normal

b. Microscopy

*E.histolytica/E.dispar*

Cyst

Trophozoite

Others \_\_\_\_\_

Treatment (Metronidazole) Given

Not given

Physician's Name: \_\_\_\_\_ Signature \_\_\_\_\_

Date \_\_\_\_\_

# II. PROFORMA SHEET OF LIVER ABSCESS CASES ADMITTED AT TIKUR ANBESA HOSPITAL

1. Hospital number

2. Address

3. Addis Ababa

4. Tigray

5. Amhara

6. SNNP (South)

7. Oromya

8. Others

9. Age

10. Sex  
 Male   
 Female

11. Marital Status  
 Single   
 Married   
 Not mentioned

12. Previous history of dysentery  
 Yes   
 No

13. If "Yes"  
 a. Number of attacks/year   
 b. Mode of diagnosis   
 1. Clinical  
 2. Laboratory  
 b. Treatment administered   
 1. \_\_\_\_\_  
 2. \_\_\_\_\_  
 3. \_\_\_\_\_

14. Admission symptoms

|     |                                |                          |
|-----|--------------------------------|--------------------------|
| 8.a | Fever                          | <input type="checkbox"/> |
|     | 8.a.1. Chills                  | <input type="checkbox"/> |
| 8.b | Sweating (night)               | <input type="checkbox"/> |
| 8.c | Right Upper Qadrant Pain (RUQ) | <input type="checkbox"/> |
|     | 8.c.1. Gauding                 | <input type="checkbox"/> |
|     | 8.c.2. Punch tenderness        | <input type="checkbox"/> |
| 8.d | Epigastric pain                | <input type="checkbox"/> |
| 8.e | Cough                          | <input type="checkbox"/> |
| 8.f | Haemoptysis                    | <input type="checkbox"/> |
| 8.g | Nausea and /or vomiting        | <input type="checkbox"/> |
| 8.h | Poor appetite                  | <input type="checkbox"/> |
| 8.i | Weight Loss                    | <input type="checkbox"/> |
| 8.j | Abdominal cramps               | <input type="checkbox"/> |
| 8.b | Diarrhoea                      | <input type="checkbox"/> |

8. b.a. Acute (<1 week)

8. b.b. Subacute (>1 wk<2 wk)

8. b.c. Chronic (>2 week)

8. b.d. No

8. c. Duration of illness

8.c.a. <1 week

8.c.b. 1-2 weeks

8.c.c. 2-4 weeks

8. d. Treatment offered before admission

8.d.a. \_\_\_\_\_

8.d.b. \_\_\_\_\_

8.d.c. \_\_\_\_\_

9. Signs

9.a. Right Upper Quadrant (RUQ) Tenderness

9.b. Epigastric pain

9.c. Intercostal tenderness

9.d. Hepatomegaly

9.e. Splenomegaly

9.f. Temperature (Fever)

9.g. Chest findings

9.g.a. \_\_\_\_\_

9.g.b. \_\_\_\_\_

9.g.c. \_\_\_\_\_

9.h. Signs of dehydration

9.h.a. Dryness of tongue \_\_\_\_\_

9.h.b. Loss of skin turgor \_\_\_\_\_

9.h.c. BO <100/60 mmHg

10. Laboratory Results

a. WBC  Differential:

1. >10000  1. Lympho

2. 10000-11000  2. Neut

3. 11000-12000  3. Eosino

4. >12000  4. Baso

b. Hg (HCT) \_\_\_\_\_

c. ESR \_\_\_\_\_

d. BUN \_\_\_\_\_

e. Creatinin \_\_\_\_\_

f. SGOT \_\_\_\_\_

g. SGPT \_\_\_\_\_

h. Bilrubin \_\_\_\_\_

1. Total

2. Direct

# II. PROFORMA SHEET OF LIVER ABSCESS CASES ADMITTED AT TIKUR ANBESA HOSPITAL

- i. Alkaline phos
- j. Serology
  - 1. Positive
  - 2. Negative
  - 3. Not done

- j. Ultrasound finding
- 1. Number of abscess
  - 1.1. one
  - 1.2. > one
- 2. Lobe affected
  - 2.1. Right
  - 2.2. Left

- K. Blood culture
  - K.1 yes
  - K.2 No
- If yes Type of organism identified
  - 1. \_\_\_\_\_
  - 2. \_\_\_\_\_
  - 3. \_\_\_\_\_

- l. Hepatic aspiration
  - 1. Yes
  - 2. No
- m. Color of abscess
  - m.1. Chocolate
  - m.2. Others
- n. Organism identified
  - \_\_\_\_\_
  - \_\_\_\_\_

- o. Stool examination
- o.1. E. histolytica
- o.2. Negative
- o.3. Not done

p. Others

- q. Outcome
  - q.1. Discharged improved
  - q.2. Discharged cured
  - q.3. Discharged with complication

Type of complication  
 \_\_\_\_\_  
 \_\_\_\_\_  
 \_\_\_\_\_

- 11. Cause of Death if any
  - 1. \_\_\_\_\_
  - 2. \_\_\_\_\_
  - 3. \_\_\_\_\_

## Declaration

I, the under signed, declare that this thesis is my original work and has not been presented for a degree in any other university and that all sources of material used for the thesis have been duly acknowledged.

Name: Amha Kebede Habtemichael 

Place and date of submission: Addis Ababa University, Department of Biology.

16 February, 2005