

**Thesis Ref Number:----**

**ISOLATION OF *HISTOPLASMA CAPSULATUM* VAR.*FARCIMNOSUM* AND  
CO-INFECTION BACTERIA FROM EPIZOOTIC LYMPHANGITIS INFECTED  
HORSES AND ASSESSMENT OF THE EFFECTS OF THE DISEASE IN THE  
COMMUNITY OF BISHOFTU AND AKAKI TOWNS**

**MSc THESIS**



**BY**

**KEYFALEW MIDEKSA SEIFU**

**Addis Ababa University, College of Veterinary Medicine and Agriculture,**

**Department of Veterinary Microbiology, Immunology and Public Health**

**JUNE, 2017**

**BISHOFTU, ETHIOPIA**

**ISOLATION OF *HISTOPLASMA CAPSULATUM* VAR.*FARCIMNOSUM* AND  
CO-INFECTION BACTERIAL FROM EPIZOOTIC LYMPHANGITIS INFECTED  
HORSES AND ASSESSMENT OF THE EFFECTS OF THE DISEASE IN THE  
COMMUNITY OF BISHOFTU AND AKAKI TOWNS**



**A Thesis Submitted to Addis Ababa University College of Veterinary Medicine and  
Agriculture in Partial Fulfillment of the Requirements for the Degree of Master  
of Veterinary Science in Veterinary Microbiology**

**By**

**Kefyalew Mideksa Seifu**

**June, 2017**

**Bishoftu, Ethiopia**

**Addis Ababa University**

**College of Veterinary Medicine and Agriculture**

**Department of Microbiology, Immunology and Public Health**

**ISOLATION OF *HISTOPLASMA CAPSULATUM* VAR.*FARCIMNOSUM* AND CO-  
INFECT BACTERIAL FROM EPIZOOTIC LYMPHANGITIS INFECTED HORSES  
AND ASSESSMENT OF THE EFFECTS OF THE DISEASE IN THE COMMUNITY  
OF BISHOFTU AND AKAKI TOWNS**

**Submitted by: Kefyalew Mideksa Seifu** \_\_\_\_\_

**Signature**

**Date**

**1. Dr. Asmelash Tassew (DVM, MSc, Asst. Prof)** \_\_\_\_\_

<b>Advisor</b>	<b>Signature</b>	<b>Date</b>
2. <b><u>Dr. Reta Tesfaye</u></b> (DVM, MSc, Asst. Prof)		_____
_____		

<b>Advisor</b>	<b>Signature</b>	<b>Date</b>
3. <b><u>Dr. Gezahegne Mamo</u></b> (DVM, MSc, PhD, Assoc. Prof.)		_____
_____		

<b>Department chairperson</b>	<b>Signature</b>	<b>Date</b>
-------------------------------	------------------	-------------

**Addis Ababa University**

**College of Veterinary Medicine and Agriculture**

**Department of Microbiology, Immunology and Public Health**

**As members of the Examining Board of the final MSc open defense, we certify that we have read and evaluated the Thesis prepared by: Kefyalew Mideksa, entitled “Isolation of *Histoplasma Capsulatum var.Farcimnosu* and co-infect bacterial from Epizootic lymphangitis infected horses and assessment of the effects of the disease in the community of Bishoftu and Akaki towns "and recommend that it be accepted as fulfilling the thesis requirement for the degree of Masters of Science in Tropical Veterinary Microbiology.**

**Dr. Hagos Ashenafi**

\_\_\_\_\_

\_\_\_\_\_

**Modulator**

**Signature**

**Date**

**Dr. Tedesa Eguale**

\_\_\_\_\_

\_\_\_\_\_

**External Examiner**

**Signature**

**Date**

**Dr. Addisu Demeke**

\_\_\_\_\_

\_\_\_\_\_

**Internal Examiner**

**Signature**

**Date**

**Dr. Asmelash Tassew**

\_\_\_\_\_

\_\_\_\_\_

**Advisor**

**Signature**

**Date**

**Dr. Reta Tesfaye**

\_\_\_\_\_

\_\_\_\_\_

**Advisor**

**Signature**

**Date**

**Dr. Gezahegne Mamo**

\_\_\_\_\_

\_\_\_\_\_

**Department chair person**

**Signature**

**Date**

## **DEDICATION**

**This thesis manuscript is dedicated and devoted to my kind father, Ato Mideksa Seifu and my elder brothers Dirbisa and Zerhun Mideksa who are deceased today but during their life, they had been good attitude for us to have educational back ground for the whole families as wells as affection and love and for their dedicated partnership in the family.**



**STATEMENT OF THE AUTHOR**

**First, I declare that this thesis is my work and that all sources of material used for this thesis have been duly acknowledged. This thesis has been submitted in partial fulfillment of the requirements for an advanced (MSc) degree at Addis Ababa University, College of Veterinary Medicine and Agriculture and is deposited at the University/College library to be made available to borrowers under rules of the Library. I solemnly declare that this thesis is not submitted to any other institution anywhere for the award of any academic degree, diploma, or certificate.**

**Brief quotations from this thesis are allowable without special permission provided that accurate acknowledgement of source is made. Requests for permission for extended quotation from or reproduction of this manuscript in whole or in part may be granted by the head of the major department or the Dean of the College when in his or her judgment the proposed use of the material is in the interests of scholarship. In all permission must be obtained from the author.**

**Name: Kefyalew Mideksa Seifu    Signature: \_\_\_\_\_**

**College of Veterinary Medicine and Agriculture, Bishoftu**

**Date of Submission: 16/06/2017**

## TABLE OF CONTENTS

Contents	Page
<b>TABLE OF CONTENTS</b> .....	<b>ix</b>
<b>ACKNOWLEDGEMENTS</b> .....	<b>x</b>
<b>LIST OF TABLES</b> .....	<b>xii</b>
<b>LIST OF FIGURES</b> .....	<b>xiii</b>
<b>LIST OF ABBREVIATIONS</b> .....	<b>xv</b>
<b>ABSTRACT</b> .....	<b>xvi</b>
<b>1. INTRODUCTION</b> .....	<b>1</b>
<b>2. LITERATURE REVIEW</b> .....	<b>3</b>
<b>2.1. The current knowledge on Epizootic Lymphangitis</b> .....	<b>3</b>
<b>2.2. Causative Agent</b> .....	<b>4</b>
<b>2.3. Epidemiology</b> .....	<b>4</b>
2.3.1. <i>Host range</i> .....	4
2.3.2. <i>Transmission</i> .....	5
2.3.3. <i>Morbidity and Mortality</i> .....	6
2.3.4. <i>Geographic Distribution</i> .....	6
2.3.5. <i>Prevalence of Epizootic lymphangitis in Ethiopia</i> .....	6
<b>2.4. Incubation period</b> .....	<b>7</b>
<b>2.5. Pathogenesis</b> .....	<b>7</b>
<b>2.6. pathology</b> .....	<b>9</b>
2.6.1. <i>Gross lesions</i> .....	9
2.6.2. <i>Necropsy</i> .....	9
<b>2.7. Clinical Signs</b> .....	<b>10</b>
<b>2.8. Diagnosis</b> .....	<b>14</b>
2.8.1. <i>Laboratory Identification of the Agent</i> .....	14
2.8.2. <i>Animal inoculation</i> .....	17
2.8.3. <i>Serological Tests</i> .....	17
2.8.4. <i>Skin hypersensitivity test</i> .....	18
2.8.5. <i>Differential Diagnosis</i> .....	18
<b>2.9. Treatment</b> .....	<b>19</b>
<b>2.10. Prevention</b> .....	<b>19</b>

2.11. Bacterial contaminant isolated from EL lesion.....	20
<b>3. MATERIALS AND METHODS .....</b>	<b>26</b>
3.1. Description of Study area .....	26
3.2. Study Animals .....	27
3.3. Study methods .....	27
3.3.1. <i>Clinical examination of the animals</i> .....	27
3.3.2 <i>Handling animals during sampling</i> .....	29
3.4. Sample collection, processing and examining .....	29
3.5. Study design and sampling method.....	30
3.6. Questionnaire survey .....	30
3.7. Data Management and Analysis.....	31
<b>4. RESULTS .....</b>	<b>32</b>
4.1. Microscopic examination of yeast under gram stain and macroscopic appearance of mycelia colony of HCF on SDA media.....	32
4.2 Bacterial isolates from horses with EL nodules with pus.....	33
4.2.1. <i>Microscopic examination of different bacteria under gram stain and its</i> .....	34
<i>macroscopic appearance of colony on different media</i> .....	34
4.3. Bacterial isolates from horses under treatment with topical iodine and new EL cases without treatment.....	39
4.4. Bacterial isolates from horses with different stages of EL cases. ....	40
4.5. Area based occurrence of isolated bacterial contaminant from EL Lesion .....	41
4.6. Questioner survey on the effect of epizootic lymphangitis among different groups of community .....	42
<b>5. DISCUSSION .....</b>	<b>44</b>
<b>6. CONCLUSION AND RECOMANDATIONS.....</b>	<b>48</b>
<b>8. ANNEXES .....</b>	<b>58</b>

## ACKNOWLEDGEMENTS

First of all I would like to express my deepest gratitude and appreciation for my supporter in all cases of my life and for the owner of knowledge's; for the almighty God. Besides I am grateful to my advisor, Dr. Asmelash Tassew, for his skillful and intellectual advice and dedication of his valuable time in checking of the manuscript. My genuine appreciation also goes to my co advisor Dr. Reta Tesfaye, SPANA veterinary clinician for his help in checking, advising and in correcting of this paper. My special thanks also goes to Addis Ababa University, College of Veterinary Medicine and Agriculture for their administrative act and continuous encouragement during my course follow up and support. I am very much indebted to Dr. Dinka Ayena, Addis Ababa University college of veterinary medicine and Agriculture Dean, Dr. Hagos Ashenafi post graduate Dean and Dr. Hana Zewdu SPANA CVMA A/project leader for their encouragement and moral support. I would like express pleasure to Mr. Alemayehu Fanta Donkey sanctuary CVMA project leader and Mr. Tekele Beyene Biomedical Science department, Mrs. Tigris Gizachew and Mrs. Tesfenesh Mogas for their encouragement and cooperation working facility in their laboratory during media preparation and sample processing and valuable moral support. I would like to express my special thank to Mr. Regasa Tolasa for his best wishes and moral support. Finally I would like to express my deepest gratitude to my wife, Mrs. Hawwi Deribu, for her heartily concern, love, patience and my beloved families for their continuous advice and moral support and contribution in realizing of this Manuscript.

## LIST OF TABLES

	Pages
Table 1: Prevalence of EL in horses and mules in some parts of Ethiopia.....	7
Table 2: Dominant bacterial isolates in closed and open equine histoplasmosis lesion observed in 24 carthorses from Mekelle town , Ethiopia, 2014 .....	22
Table 3: Criteria used for categorization of stages of Epizootic lymphangitis.....	28
Table 4: Bacteria isolated from pus of horses with EL lesions (n=72).....	33
Table 5: Bacterial isolation rate from horses under treatment and without treatment.	39
Table 6: Area based occurrence of isolated bacterial contaminant from EL lesion. ...	41
Table 7: Respondent reply result related to the effect of the disease within the community .....	43

## LIST OF FIGURES

	Pages
Figure 1: The way Epizootic lymphangitis invading of tissues susceptible animals.....	8
Figure 2: Cutaneous form of EL on Donkey (A) , Mule(B) and Horse(C) indifferent body part .....	11
Figure 3: Sever ulcers(A) and nodules(B) contained pus distributed on different .....	12
Figure 4: Button like growth on conjunctiva of EL infected donkey(A) and ocular form of EL in horse (B) .....	13
Figure 5: The respiratory form of EL indicating that bleeding (A), mucopurulent....	13
Figure 6: Microscopic appearance of EL lesion histology .....	15
Figure 7: Ovoid yeast bodies with in macrophages and librated .....	16
Figure 8: Map of the study area .....	26
Figure 9: Gram staining with lemon shape, round to oval and holo unstained capsule Yeast of HCF (A) and Dry, grey, white, granular with wrinkled/lined, cerebriform, convoluted mycelia colonies of HCF on SDA media (B) .....	32
Figure 10: Golden yellow pigmented colony on mantoli salt agar (A) and Gram positive with bunch of cocci (B) .....	34
Figure 11: Muroid colony on Edward Media (A), Heamolysis on blood agar (B) and Gram positive, chain forming cocci (C) .....	34
Figure 12: Shiny White pigmented colony of Micrococcus on nutrient agar media and subcultured (A&B), Microscopic examination of gram stained tetrad cocci (C) ..	35
Figure 13: Colony of corynebacterium grown on blood agar and showing no heamolysis (A) and Gram positive rod appearing with group of parallel cells or at sharp angle like 'Chinese' letter (B).....	35
Figure 14: Smooth muroid or Buffy colored with irregular edge colony on MSA (A) and Gram negative rod (B) .....	36
Figure 15: Gray Muroid, pale to pink rough edge colony (seems mucouse membrane) on nutrient agar (A), Pink colony on MacConkey (B) and gram negative rod (C). ....	36
Figure 16: Gray, wavy swarming muroid pink colony (A) and gram negative long rod (B). .....	37
Figure 17: Blue green colony (A) Pseudomonas grown on XLD agar (B) and Gram negative rod (C) .....	37
Figure 18: Distinctive green metallic sheen colony of <i>E.coli</i> on EMB agar (A) and gram negative small rod shape under microscope (B).....	38

Figure 19: Gram positive rod shape Bacilli with spore at one end which was not bulge mother cell ( A) and other gram positive rod shape bacillus (B).....38

Figure 20: Bacterial isolated from pus samples of different stages of EL infected horses explained using bars in percentage. ....40

Figure 21: Severely infected and abounded horses in middle of road (A) and in field (B) .....42

## LIST OF ABBREVIATIONS

BCS	Body Condition Score
BHIA	Brain Heart Infusion Agar
CFSPH	Center for Food Security and Public Health
EARO	Ethiopian Agricultural Research Organization
EH	Equine Histoplasmosis
EL	Epizootic Lymphangitis
EMB	Eosin Methyl Blue
ELISA	Enzyme Linked Immuno Sorbet Assay
H and E	Heamatoxlin and Eosin
HCC	<i>Histoplasma capsulatum var. capsulatum</i>
HCD	<i>Histoplasma capsulatum var. duboisii</i>
HCF	<i>Histoplasma capsulatum var. farciminosum</i>
NMSA	National Metreorological Service Agency
NA	Nutrient Agar
MSA	Manitol salt Agar
OIE	World organization for animal health
PPLONA	Pleuro -Pneumonia Like Organism Nutrient Agar
SDA	Sabouraud's Dextrose Agar
SPANNA	Society for the Protection of Animals Abroad
Spp	Species
UL	Ulcerative Lymphangitis
USD	United State Dollar
XLD	Xylose Lysine Deoxycholate

## ABSTRACT

Across sectional study was carried out from November 2016 up to May 2017 in Bishoftu and Akaki towns in order to isolate *Histoplasma capsulatum var farciminosum* (HCF) and other co-infect bacteria from local breeds of horses with characteristic lesion of epizootic lymphangitis. A questionnaire was also designed and administered to assess the socio-economic impact of the disease in the community. A total of 72 clinical specimens (pus) were collected aseptically using a purposive sampling technique. These specimens were examined under microscope to identify HCF. It was also cultured on Sabourad's Dextrose Agar media and various bacteriological culture media and selective media for isolation of fungus and bacteria respectively. Only (58.3%) of mycelia growth was recorded and (98.6 %) indicated positivity under microscope using stain. Regarding the isolation of co-infect bacteria, *Staphylococcus* (88.8 %), *Streptococcus* (41.2 %), *Micrococcus* (75 %), gram positive *Bacilli* (41.7%), *Corynebacterium* ( 22.2%), *Aeromona* (34.7%), *Proteus* (20.8%), *Klebssiella* (22.2%), *Pseudomonas* (20.8 %) and *E coli* (6.8%) were identified. The study animals were also classified as those which never get treatment and those horses taking therapy (topical iodide application) in the SPANA Clinics. The occurrences of co-infect bacteria was found greater in those horses which didn't take any therapy. But the treatment does not protect the emerging of new nodules and co-infect bacteria. Similarly, the study animals were grouped in to early, moderate and severe based on stage of the disease. The proportion of bacterial isolates was greater in those horses which were severely infected than those horses grouped in the moderate and early cases of the disease. The presence of co-infect bacteria were observed in both study area with some difference in proportion. The impact of the disease was assessed by asking various communities including users owners, traffic polices and workers from municipality whose their job related with urban hygiene and greener. The response of all respondents clearly indicated that the disease is causing lots of negative consequences in the community by reducing the income, performance and welfare of the animals. The current study revealed the presence of various bacterial species which may aggravate the disease and comprise the progress of treatment. As the impact of the disease is increasing in the societies, effective control measures like combined application of chemotherapy should be put in place.

*Key words: Akaki, Bacteria, Bishoftu, Epizootic lymphangiti, Histoplasma capsulatum var farciminosum, Horse, Isolation*

## 1. INTRODUCTION

In Ethiopia, the transportation infrastructure is at its lower stage particularly in the rural areas (Birhanu *et al.*, 2014). As a result, most of the transportation activities are performed by the use of Equines. Besides, in the northern and north-western part of the country, equines have also been used for ploughing activities showing their contribution in crop production. In some part of the country they are used as food source (Ameni *et al.*, 2006; EARO, 1999; SPANA, 2006). Despite their uses, equines suffer from many diseases, among which Equine histoplasmosis (EH) or Epizootic lymphangitis (EL) is one of the nastiest chronic diseases particularly in Africa, Middle East and Asia. Epizootic lymphangitis is called a 'fat leg' because it is known by swelling of legs. In Ethiopia EL is known as 'Biche' in Afan Oromo and 'Nidifit' in Ameharic (Ameni and Tilahun, 2003).

Epizootic lymphangitis is a chronic contagious rampant and debilitating fungal disease mainly of horses but also affects mules and donkeys. As the reports indicated that 90% of the cases were observed in horses followed by mules but the disease is less common in donkeys (Awad, 1960; Carter and Chegappa, 1991). The rate of infection varies among different geographical areas (Al-Ani and Ali-Delaim, 1986). Due to this disease the horse become debilitated and develop secondary infection and quit often they are abandoned and seen on the road sides without any feed and water (Ameni, 2006a, Getchew *et al.*, 2007, Tobianse *et al.*, 2016, SPANA, 2006).

Epizootic lymphangitis has major socio economic impact as a result of death of affected horses and decline in the net profit per day due to reduced working performance of affected horses (Birhan, *et al.*, 2014; Meles *et al.*, 2008). Because the passengers never use a horse with EL as healthy animals for transport (Pal, 2007). According to participatory studies conducted to prioritize diseases of working equine in Ethiopia, EL was ranked as the most important disease (Stephanie, 2014, Jagema and Jarso, 2016). Other study indicated that attentions given for this species of animals was less because of horses are not providers of meat and milk at least in Ethiopia so that is misconception of the owners about the

hardiness and tolerance of equines against adverse effects including diseases (Feseha, 1993).

The diagnosis of EL is based on characteristic clinical signs and laboratory confirmation through demonstration of the organism in smear. The organism has two forms; mycelial /saprophytic form is found in nature in the soil and the yeast form is found in tissues (Pal, 2007). Like other lesions, horse wounds have high risk of becoming infected due to environmental contamination. Infected wounds have high chance to harbor diverse population of microorganisms that cause failure to treatment responses in this disease. Healing of equine wounds particularly in the limbs is difficult due to hydrostatic factors and exposure to environmental contaminant which can lead to infection and delay healing (Tobianse *et al.*, 2016). *Bacillus*, *Aeromonas*, *Klebsiela*, *Staphylococcus*, *Micrococcus* and *Rhodococcus* bacterial contaminants were reported in and on EL lesions (Hadush *et al.*, 2008).

Regarding the treatment, none of the recommended anti-fungal drugs for the treatment of EL are available in Ethiopia veterinary clinics because of the high cost of the drug (SPANNA, 2006, Getachew *et al.*, 2007). So the fate of severely affected horses and mules or equines in general is to be left without proper treatment as they can be seen in the fields and road sides without any feed and water (Ameni, 2006a; SPANNA, 2006; Getachew *et al.*, 2007). Once the infected animals become abandoned on the road side, they become source of infection to other susceptible animals and their welfare is also abused. This study was aimed to find some major bacterial contaminants in EL lesions that may contribute to the failure of effective treatment of EL. Co-infect bacteria associated with EL had not been studied and there has no report from current study area. So the objectives of this research were:

- Identification of co-infect bacterial from epizootic lymphangitis lesion in horses.
- Isolation of *Histoplasma capsulatum var farcimnosum* from EL infected horses
- Assessment of the consequences of Epizootic lymphangitis in the community

## **2. LITERATURE REVIEW**

### **2.1. The current knowledge on Epizootic Lymphangitis**

Lymphangitis means inflammation of the lymphatic vessels that may be caused by infection or allergy which can occur anywhere in the body (Edward, 2005). The lymphatics are a type of tubular system that drains excess fluids and proteins from tissue and gradually routes it back into the main blood circulation. Lymphatic vessels are low-pressure vessels similar to veins that collect the fluid that surrounds cells and return it to the blood stream. Lymphatics are present practically everywhere in the body. The most common sites that encounter lymphatic problems in the horse are their legs and its infection response cause lymphangitis (Jubb *et al.*, 2006). Inflammation is the body's reaction to harmful or irritating stimuli, which could be anything from a burn, allergy, or cut, to a serious infection. Inflammation begins the process of healing. The typical signs of inflammation redness, heat, swelling, pain and sometime lost function, are indicators of it. Because lymphangitis is an inflammation, the swelling is partly due to lymph vessels and lymph nodes adjacent to the affected area responding to the presence of a potential invader. Inflammation is frequently confused with infection; however infection is caused by a bacterium, virus or fungus, while inflammation is the body's response to it that will occur also in response to infection (Mc Gavin & Zachary, 2010).

Lymphangitis has been recognized in Ethiopia since 1968 (Solomon, 1980). There are a number of disease conditions which causes lymphangitis, but here mentioned are the three more familiar causes for lymphangitis in horses. Those are Idiopathic/indolent lymphangitis, Ulcerative lymphangitis and Epizootic lymphangitis (Endebu, 1996; Ameni & Siyoum, 2002). Epizootic lymphangitis has been also known as African Farcy, cutaneous Farcy, Equine histoplasmosis, Equine blastomycosis, Equine cryptococcosis, Pseudo farcy (Giber, 1998; Pal, 2007; OIE, 2008). The disease is characterized by chord like inflammation lymphatic vessels and nodes of affected body part and serous pyogranulomatous lesion; chronic contagious and debilitating disease of horse followed by mules and donkey and has clinical manifestations of

suppurative, multifocal dermatitis, lymphangitis and lymphadenitis and ulceration Jubb *et al.*,1985; Radois *et al.*,1994;AL-Ani and AL-Delani, 1988).

Common affected body parts of animals include extremities, chest, upper eye lid, around nares and necks (Ameni, 2006).The organism invades open lesions via contaminated harness, castration, surgical utensil, grooming equipment, common feeding and watering tray and other abscess formations.

## **2.2. Causative Agent**

Epizootic lymphangitis is caused by dimorphic soil fungus called *Histoplasma capsulatum* var. *farcinosum* (HCF). The fungus is also named as *Histoplasma farcinosum*, *Blastomyas farcinosum*, *Cryptococcus farcinosum* and *sacromyces farcinosum*, *Zymonema farcinosum* (Radostis *et al.*,1994; Aiello and Mays,1998; Pal, 2007; OIE, 2008).The organism has two forms: septate hyphae (mycelial form) found in the soil and yeast form that is found in tissues of animal lesion or pus in nodules. The mycelial forms are found at room temperature while the yeast forms at 35-37 °C in tissues of animals (OIE, 2008).The fungus is mostly isolated from nitrogen rich soil and contaminated by excreta of birds and bat.As compared to *Histoplasma Capsulatum* var *Duboisii* (HCD) *Histoplasma Capsulatum* var*capsulatum* (HCC) the *Histoplasma capsulatum* var *farcinosum* has small yeast cell in tissue of susceptible animals that causes epizootic lymphangitis.In the body tissues, the ability mycelial form of *Histoplasma. Farcinosum* to be Converted to yeast form depend on temperature and nutrition as well as strain of the fungus (OIE, 2008).

## **2.3. Epidemiology**

### *2.3.1. Host range*

Epizootic lymphangitis is common infections disease of equines mainly of horses. It also affects mules and donkeys (Award, 1960; Gilbert, 1998; Ali-Ani, 1999). The disease may occur in camels, cattle, dogs, cats, chickens, rats, (Gilbert, 1998; Krishi, 2007 ). In rare case it has also public health issue of human infection with HCF have been encountered, the unequivocal identification of the etiologic agent

is lacking. As the fungus is excreted in the pus/exudates, precautions should be taken to prevent the possible infection of human (Aillo ,1968, Guerin *et al.*,1992, Pal M. 2007, OIE. 2008). There are no breeds, sex and age differences in epizootic lymphangitis indicating that all group of horses are affected equally (Ameni, 2006a; Kuastros, 2007).

### 2.3.2 Transmission

Even if the exact route of transmission is not known (Endebu and Ronger, 2003), the different route of transmission are suggested according to clinical signs and route of entry as cutaneous, ocular, respiratory and asymptomatic form (Singh, 1965; Pal, 2007). So, EL has four different forms. These are Cutaneous form or the skin form, the ocular form, respiratory form and asymptomatic form (Pal, 2007).

The skin form of the disease occurs when traumatized skin is contaminated with infected soil (Timony *et al.*,1988; Aiello and Mays, 1998; Gilbert, 1998) or fungal spores of infected skin, pus, nasal, ocular excretion or contaminated harness, whip, grooming equipment, bedding, feeding, watering utensil, flies and ticks (Radostits *et al.*, 1994; Pal, 2007). Report also indicated that flies have their own contribution for disease transmission because the prevalence of the disease is high during breeding season of flies, so it has seasonal variations (Endebu and Roger, 2003).

The conjunctival form of the disease is believed to be due to the biting flies especially of musca and stomoxys species that may indicate organism is isolated from alimentary tract of biting flies (OIE, 2008). As report indicated by other insects like ticks (*Amblyoma coharence* and *Boophilus species*) may also have role transmissions of EL (Aiello and Mays 1998; Ameni, 2007) while the *pulmonary form* is due to inhalation of spores of the organism (OIE, 2008). There is also report that indicates the transmission via copulation from diseased stallion to mare (Fawi, 1971; Gueds *et al.*, 2003). Six bacterial contaminant genera are isolated from lesions of epizootic lymphangitis and some of them are frequently found that they potentially contribute to the clinical signs, pathogenesis and to the severity of the disease, leading sometimes to death in severely infected horses (Hadush *et al.*, 2014).

### *2.3.3. Morbidity and Mortality*

Morbidity is high when large numbers of animals live together such as in military stations and racing area. The mortality is low and can be up to 10-15 % (Pal, 2007).

### *2.3.4. Geographic Distribution*

The disease is endemic in tropics and sub tropics like West, North and East Africa, Middle East, India and the Far East. Some part of Asia including Mediterranean sea, Pakistan and Japan (Gabal *et al.*, 1983b; Radostits *et al.*, 1994; Gilbert, 1998; OIE, 2008). The disease is common in warm and humid areas between 1500- 2300 m.a.s.l that favor condition for mycelia form of HCF (Ameni, 2006a).

### *2.3.5. Prevalence of Epizootic lymphangitis in Ethiopia*

Epizootic lymphangitis recognized in Ethiopia; locally it has been called 'Biche' (Afaan Oromo) or 'Nidifit' (Amharic) (Ameni and Tilahun, 2003). Report indicated that 2.75 million horses, 5.02 million donkeys as well as 0.63 million mules are at risk of infection by EL in Ethiopia (EARO, 1999). The overall prevalence of EL in 28 towns to be 10.4% to 26.2% was reported in Ethiopia from various parts of the country as indicated in Table 1

Table 1: Prevalence of EL in horses and mules in some parts of Ethiopia

Location (towns)	Number examined	Prevalence (%)	Species	Sources
Different areas (28towns)	1982	18.8	Horses	Ameni (2006)
Western (Bako and Ejaji)	309	21.0	Mules	Ameni and Terefe (2004)
Central Ethiopia (Debre Zeit and Akaki)	1100	10.4	Horses	Endebu and Roger (2003)
Central Ethiopia (Debre Zeit, Modjo, Nazareth)	2907	26.2	Horses	Ameni and Seyoum (2002)

#### 2.4. Incubation period

Once the organism enters to tissue of susceptible hosts, the incubation period varies from three weeks to two months depending on the forms of fungus (Ameni, 2006b; OIE, 2008). The yeast form takes about a month while the mycelia form takes over two months (Ameni, 2006b). According to OIE (2008), the incubation period takes up to six months.

#### 2.5. Pathogenesis

After gaining entry through wounds or skin trauma (particularly under the harness and on the extremities), HCF invades subcutaneous tissue, sets up a local granuloma or ulcer and disseminates through the lymphatics to regional lymph nodes or, in severe cases, to other organs and form nodules. Nodular lesions develop in the skin along the lymphatics and in the lymph nodes. These lesions eventually ulcerate and drain a thick, mucopurulent material containing yeast cells. Horses that have a heavy systemic burden of fungi may succumb to pneumonia or failure of other affected organs. (AL-Ani, 1999; Jubb *et al.*, 2006; Radostits *et al.*, 2006). The ocular form of the disease results from inoculation of the organism into

the eye, likely by biting flies (Radostits *et al.*, 2006). Both conjunctivitis and rhinitis may occurred as the extension of the skin form, because the animals will scratch the skin lesions by their teeth and lips, ther eby spreading it to the surrounding organs (Ameni, 2007).

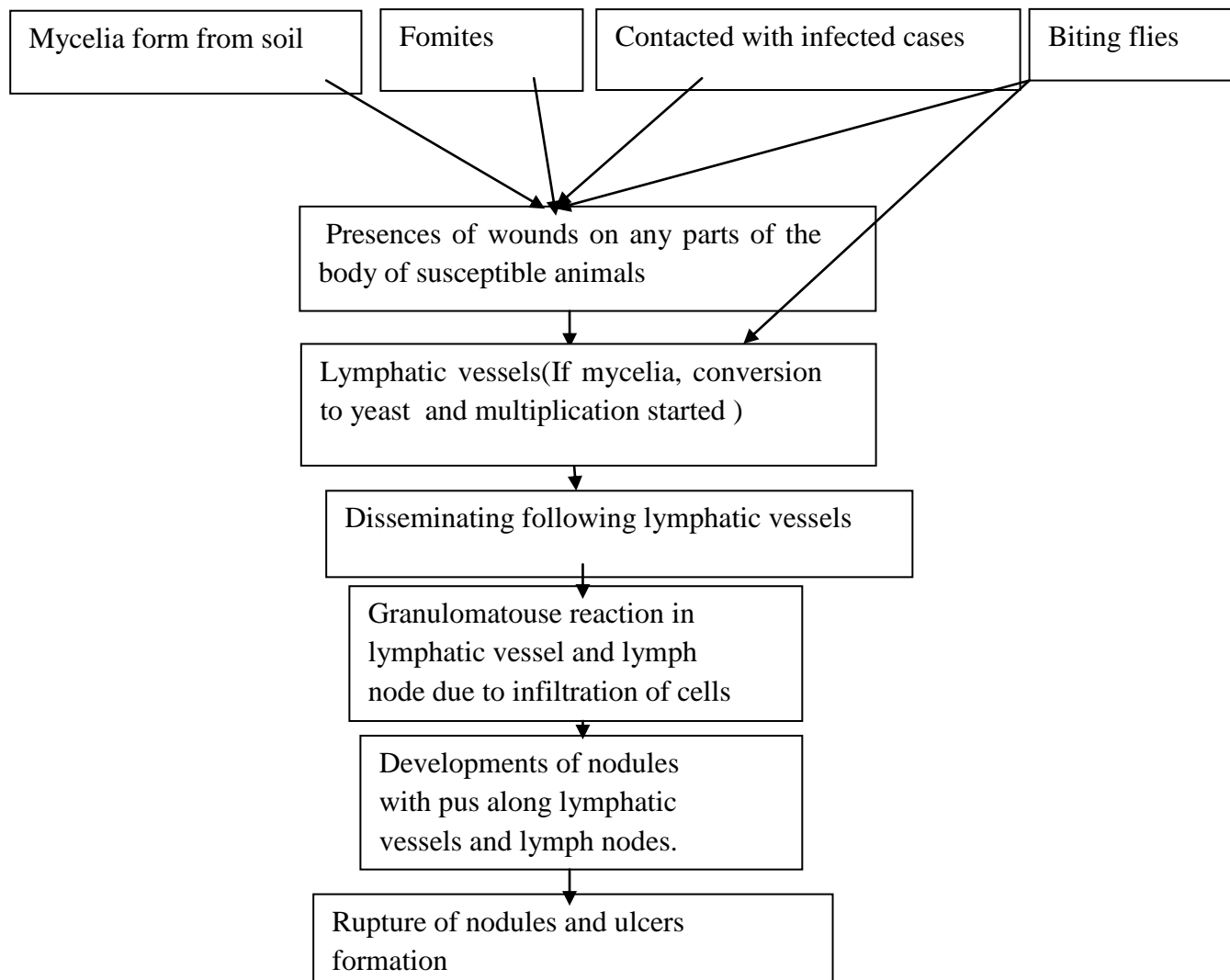


Figure 1: The way Epizootic lymphangitis invading of tissues susceptible animals

Source: Ameni (2010)

## **2.6. pathology**

### *2.6.1. Gross lesions*

Gross lesions are manifested by pyogranulomatous, purulent discharge of thickened superficial lymphatic vessels and enlargement and inflammation of regional lymph nodes (AL-Ani, 1999). Regional lymph nodes are swollen, soft, and reddened and may contain purulent foci. Lymphatic vessels may be found distended with pus (AL-Ani, 1999).

### *2.6.2. Necropsy*

Areas of the skin and subcutaneous tissue are thickened, and the skin may be fused to the underlying tissues. When the thickened skin is incised, it presents the lardaceous appearance of granulation tissue and it contains a number of small, yellow, purulent foci between which the lymphatics are dilated and filled with pus and serous fluid (Jubb *et al.*, 2006). In the early stages, the skin between the lesions remains normal and mobile, except in areas of extensive ulceration. The skin covering the nodules and the subcutaneous tissues may become thickened, fibrous, indurate, and firmly fused to the underlying tissues (Al-Ani *et al.*, 1998; Jubb *et al.*, 2006; Ameni, 2007). In the early stages, the swollen nodes contain many small foci of softening, but later the foci coalesce and are heavily encapsulated and they may rupture to form ulcers (Jubb *et al.*, 2006). There is often thickening, or ‘cording’, of lymphatics, with the formation of pyogranulomatous nodules that have a thick, fibrous capsule (OIE, 2008). Nodules in the skin have a thick, fibrous capsule and the affected lymphatic vessels are usually thickened or distended. Both nodules and lymphatics contain purulent exudates (IVIS, 2006). The forelimbs, neck, and head are common sites to observe the nodular and chronic suppurating lesions, however they are also observed on different body parts including the scrotal regions. In advanced cases, the nodules and ulcers may involve almost all body parts and may have unpleasant odor (Ameni, 2007).

## 2.7. Clinical Signs

The clinical signs of EL is described based on the four forms of the disease and root of entry. The four forms of EL are Cutaneous form, Respiratory form, Ocular form and Asymptomatic carriers. All forms of the disease are observed in horses, mules and donkeys (Al-Ani and Al-Delaim, 1986; Powell *et al.*, 2006). The disease get the name epizootic lymphagitis due to the cutaneous form which is major form of it (Awad, 1960; Ali-Ani and Al-Delaimi, 1986; Ameni, 2007). The lesion is most commonly seen on the skin, subcutaneous tissue, lymph vessel and nodes. It is characterized by thickening with freely movable pyogranulomatous nodules of lymph node and open granulomatous wounds the course lymphatic vessels (Aiello, 1968; Ali-Ani *et al.*, 1998; Gilbert, 1998).

Epizootic lymphangitis lesions are the most commonly observed on the fore limbs, the chest wall, necks and skin of ribs. In severe cases, skin of the entire body may be affected. These wounds tend to ulcerate or undergo alternating periods of discharges thick cream gray pus. They close for some weeks prior to healing spontaneously after 2-3 months with residual scar formation. If the scar is removed, there is creamy like pus under the scar. Regional lymph nodes may be enlarged, inflamed and variably painful with swelling of the affected limbs (Gabal *et al.*, 1983b; Radostis *et al.*, 1994; Rooney and Robertsons, 1996; Aiello and Mays, 1998; Ameni, 2007).

The forelimbs, neck, and head are common sites to observe the nodular and chronic suppurating lesions, however they are also observed on different body parts including the scrotal regions. In advanced cases, the nodules and ulcers may involve almost all body parts and may have unpleasant odor (Ameni, 2007)

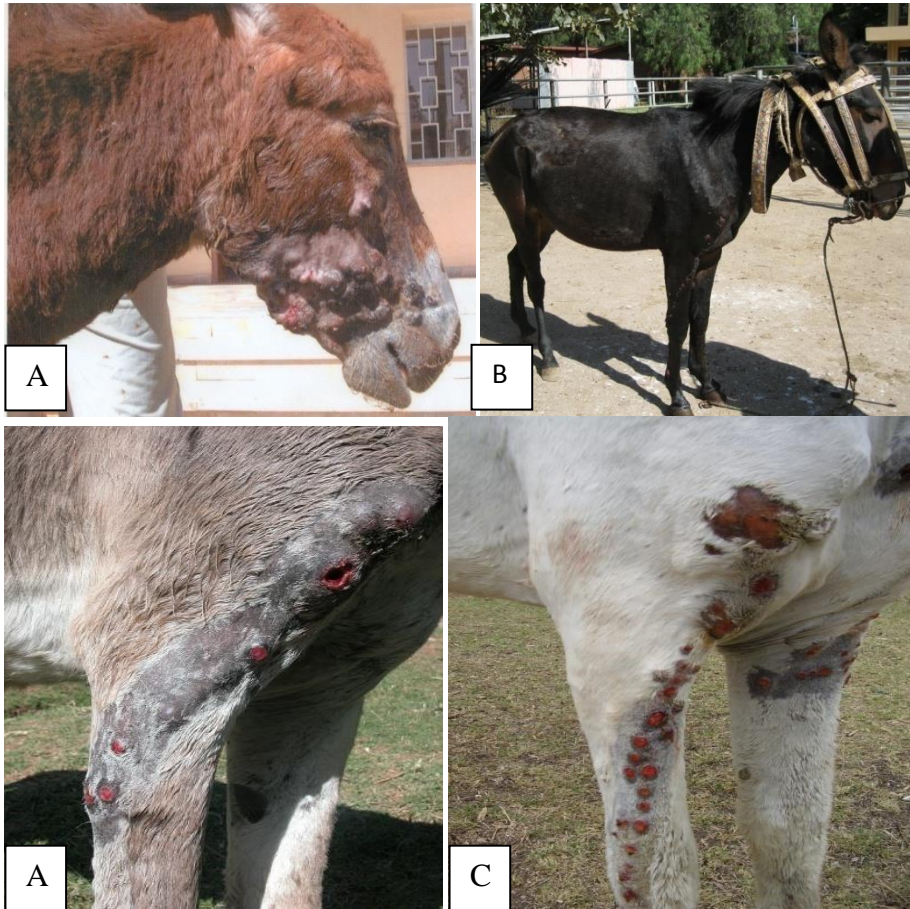


Figure 2: Cutaneous form of EL on Donkey (A) , Mule(B) and Horse(C) in different body part

Source: SPANA, 2006

In severe cases, the skin of whole body may be affected and sometimes involving joints and cause arthritis, peri-arthritis and periostitis. In most cases, there is no systemic reaction (Aiello and Mays, 1998; Ameni, 2007). The lesion is complicated with some bacterial infection, so it persists for long time. EL infected animals become restless and abandoned on the street road because flies (Roomy and Roberson, 1996). In infected horses, loss of appetite is common that increase with severity of the disease. When extensive lesions are observed in horses or in severe cases, it can end in death. This usually occurs in area where animals in poor condition, veterinary care limited and less awareness of owners (Ameni, 2007; CFSPH, 2009).




Figure 3: Sever ulcers(A) and nodules(B) contained pus distributed on different parts and 'Cord' like inflammation (C) of EL case in horses  
(Source: SPANA, 2006)

The ophthalmic form of the disease is less frequent and infection may occur as conjunctivitis, keratoconjunctivitis and naso-lachrymal infection. The infection becomes less generalized. The initial infection is characterized by watery discharge from one or both eyes and some swelling of eye lids, followed by development of papules and ulceration, button like growth on the conjunctiva and/or the nictitating

membrane (Ali-Ani and Ali- Delaimi, 1986; Ali-Ani *et al.*, 1998; Ali-Ani, 1999; Pascoe and Knothembelt, 1999).

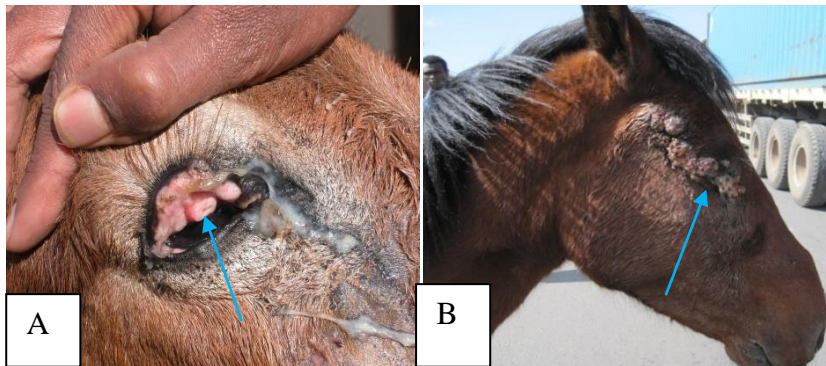


Figure 4: Button like growth on conjunctiva of EL infected donkey(A) and ocular form of EL in horse (B)

(Source: SPANA, 2006)

The respiratory form of the disease is characterized by lesions which are mostly confined to upper respiratory tract. This form usually occurs at a late stage of development in cutaneous form of the disease (Figure3). The lesions are usually found around external nares and may also occur in the lung, spleen, liver and tests (Radostits *et al.*, 1994; Aiello and Mays, 1998; Gilbert, 1998).The nasal mucosa may have multiple, small gray- white nodules or ulcer with raised borders and granulating that bleed easily. Pneumonia develops with evident serous or purulent nasal discharges containing large number of the fungus that cause dyspnoea which leads to death (Ani-Ani, 1999; Ameni, 2007).

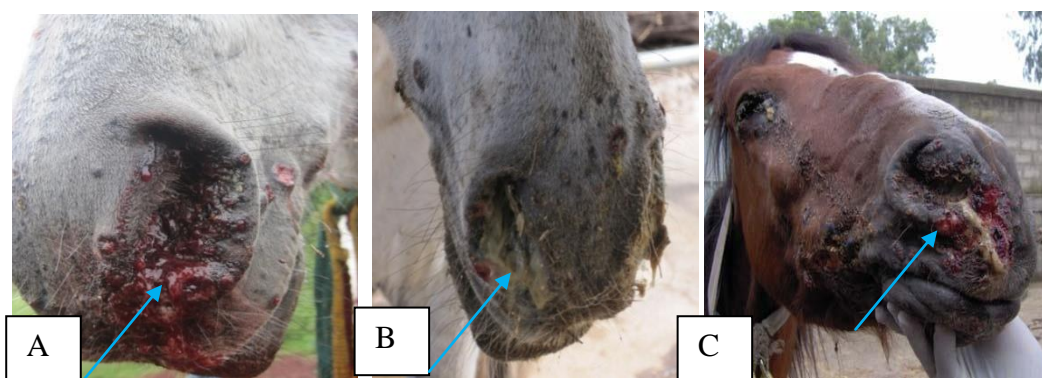


Figure 5: The respiratory form of EL indicating that bleeding (A), mucopurulent discharges (B) and ulcers of nares (C)

(Source: SPANA, Ethiopia, 2006)

Asymptomatic carrier can be identified clinically by fibro calcified skin lesions at the previous site of infection. Such equines will give a positive result to interadermal sensitivity (histofercin) test and positive reaction to serological test (Soliman *et al.*, 1985; Ali-Ani, 199; Pal, 2007).

## **2.8. Diagnosis**

The diagnosis of EL is mainly based on the laboratory tests including microscopic examination of yeast from EL pus, serological tests like Flourescent antibody tests, Enzyme Linked Immuno Sorbet Assay (ELISA) and skin hypersensitivity testing. Clinical examinations of the lesion of affected animals are also important (Ali-Ani, 1988; Gilbert, 1998). The sample should be transported to laboratory in properly secured way.

### *2.8.1. Laboratory Identification of the Agent*

Sample is collected by sterile material from un ruptured nodules and placed in liquid nutrient medium with antibacterial and kept in fridge until culturing soon after sampling. In case of direct examination swabs of lesion can be used for smear and fixed for stain and look under microscope. For histopathology, selection of lesion material included both visible and non visible tissue, should place in 10% neutral buffered formalin. Confirmation of the disease based on demonstration of organisms in smear (Gilber, 1998; OIE, 2008).

I) Direct smear Examination: Smear is directly by gram stain and examined for the typical yeast form of the organism. Diagnosis based on the typical yeast are Gram positive double contoured, pleomorphic, void to globose structure measuring 2.5 to 3.5 by 3 to 4 $\mu$ m (Gabal and khalifa, 1983, Selim *et al.*, 1985; Timony *et al.*, 1998; Endebu and Roger, 2005). The cytoplasm is violet using gram stain, pink in case of Periodic Acid Schiff (PAS) and blue giemsa stain. Since the cell is budding it occur single or in group in macrophage and outside. They are found either with unstained transparent or with faint blue cytoplasmic space; either free or intracellularly within mono-nucleated leucocytes mostly being phagocytized within the macrophages

The HCF may occur singly or in groups and may be found within macrophages or extracellular. The staining reaction and granulation of the yeast forms shows either

- (1) whole unstained transparent lemon-shaped spaces,
- (2) granules concentrated more at the wide end and little in the center,
- (3) granules arranged inside wall of the yeast,
- (4) granules almost filling the cell,
- (5) whole stained yeast forms filled with granules or
- (6) granules sparsely dispersed in the yeast. Of the above forms of the yeast, the second form is quite common. Monocytes and lymphocytes are observed in most of the smears Ameni and Siyoum, (2002).

II) Alcohol and hematological test marked increase in erythrocyte sediments rate and leucocytosis of neutrophil in chronic infection (Al- Ani and Al-Delaimi, 1986).

III) In heamatoxylin and eosin (H and E) stained histological section. So, its appearance consist of pyogranulomatous inflammation with fibroplastic. Typical nodules of foci have also been observed in pleura, spleen, liver and bone marrow (Ali- Ani, 1999; OIE 2009).

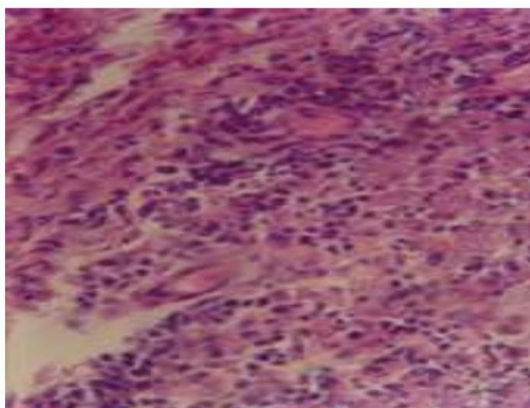


Figure 6: Microscopic appearance of EL lesion histology

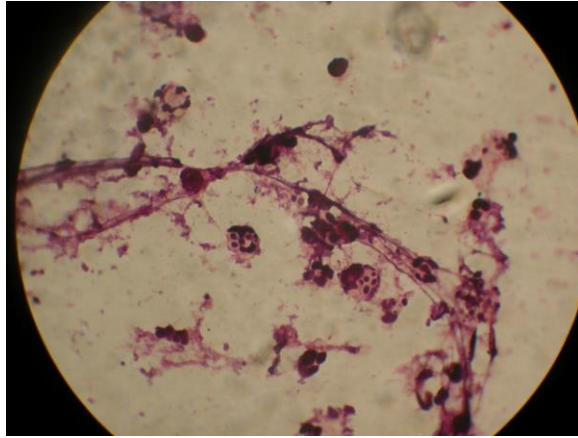


Figure 7: Ovoid yeast bodies with in macrophages and liberated  
(Source: Scantlebury, 2009).

IV) Culture: Both mycelia and yeast form cultivated in suitable temperature, media and CO<sub>2</sub> (Ali-Ani 1999). Mycobiotic agar used for isolation of organism include Sabourad's Dextrose Agar (SDA) enriched with 2.5% glycerol, Brain Heart Infusion Agar (BHIA), sublimated with 5% horse blood and pleuro pneumonia like organism medium (PPLO) nutrient medium with 2% dextrose and 2.5% glycerol and 7.4 pH at each media needs addition of antibiotic like cycloheximide (0.5g/liter) and chloran phenicol (0.5g/liter) and broad antibiotic like gentamicine (50g/liter) and penicillin G ( $6 \times 10^6$  unit/liter) are used instead of chloran phenicol (Selim.*et al.*,1985; Radostis *et al.*, 2007).

The growth of mycelia colony is slow, approximately 2-8 weeks at 26°C and it look dry, grey, white, granular with wrinkled mycelia and become brown with aging (Awad, 1960; Ali-Ani, 1999; Ameni and Siyoum, 2002; OIE, 2008). Confirmatory test of the yeast form that can be induced by subculturing of mycelium in BHI agar with 5% horse blood at 35-37°C in 5% CO<sub>2</sub>. Yeast colonies are flat, raised, wrinkled white to grayish brown and pasty consistency. But complete conversion of yeast phase may be achieved after 4-5 repeated serial transfer on fresh media every 8 days (Selim *et al.*, 1985; Ameni and Siyoum, 2002; OIE, 2008).The culturing technique is not totally reliable, a negative direct smear and /or culture should not be used as basis of excluding the possibility of infection. Hence culture of several samples on different occasion is needed (Ali- Ani and Ali-Delaimi, 1998).

#### V) Biochemical characteristics of mycelia form

Positive reaction to catalase and urease tests and ammonium sulphate is a source of nitrogen assimilation. But no fermentation of carbohydrate sugars, liquefaction of gelatin and reduction of nitrate source occurs (Ali-Ani, 1999; Endebu and Roger, 2003)

#### 2.8.2. *Animal inoculation*

Experiment conducted using laboratory animals like mice, Guinea pigs, and rabbits (Pal, 2007) indicated that immune suppressed mice are highly susceptible to experimental infection and used as diagnostic purpose. Antibodies usually develop at or just after onset of clinical sign (Rippor, 1988; Ali Ani, 1999; OIE, 2008). Experimentally, it was possible to produce the disease in horses (Ameni, 2006b).

#### 2.8.3. *Serological Tests*

There are published reports of various tests to detect antibodies as well skin hypersensitivity test for the detection of cell mediated immunity. Antibody usually develop at or just after onset of clinical signs. The *Histoplasma Capsulatum var.Farcimosum* causes the induction of both humeral and cellular immunity because of the form of organism that can reside both intracellular and extracellular. A significant anti-body titer has been demonstrated in sera of equine naturally infected with HCF (Gabal *et al.*,1985; khalifa, 1983).

Flourescent antibody tests is a diagnostic tool for HCF infection (Gabal *et al.*, 1985; OIE, 2008).It is rapid and used in case of isolation and detection of organism is un successful. Indirect and direct fluourescent antibody tests are conducted commonly. Enzyme Linked Immuno Sorbet Assay (ELISA) is used for the diagnosis of the disease. Minced preparation of four week growth of fungus in phosphate buffered saline can be used as antigen, and peroxidase labeled anti equine Immunoglobulin G (IgG) is used as the conjugated antibody (Gabal and Mohama, 1985; Carter and Changappa,1991; OIE 2008). The serum agglutination test is highly suitable for the large scale screen of sera. Agglutination is detected

when the red blood cell create a uniform mat/coagulation on the bottom of the tube (Gabal and Khailifa, 1983; OIE, 2008).

#### 2.8.4. Skin hypersensitivity test

It is a histofarcin test that is suitable for routine diagnosis of large number of animals screening. This consist of intradermal injection of 0.1ml of soluble antigen prepared from the mycelia form of HCF an increase the thickness of skin more than 4mm within 24 to 48 hr after njecting 0.2mg/ml of antigen can be regarded as positive result (Gabal and Khalifa,1993; Ameni *et al.*, 2006).

#### 2.8.5. Differential Diagnosis

Epizootic lymphangitis is clinically confusing with other disease but the final diagnosis is by laboratory confirmation. The diseases that create confusion with EL are Ulcerative lymphangitis caused by *Corynebacteria Pseudotubeclosis*, indolent ulcer (caused by *Rhodococcus equi*), strangles caused by *S.equi*, sporotrichosis caused by *S.schaki*, histoplasmosis caused by HCC, cryptococcosis, sarciod and cutaneouse form of glanders also called farcy, which caused by *Burkholderia mallei* (Gilbert,1998; OIE, 2008; Ali-Ani and Ruberson, 2007). Skin form of glanders (farcy) due to the involvement of the skin including ulceration, lymphadenitis and lymphangitis makes them similar but farcy is caused bacteria *Burkholderia mallei* and identified by mullein test and serology and also no yeast in pus. Ulcerative lymphangitis: caused by *corynebacteria pseudo tuberculoses* is differentiated by it more acute, greenish pus, lesion in lower limb below hock joint and heal as quickly as EL lesion and also respond to antibiotics only (OIE, 2008).

Strangles: Acute bacterial disease of horse caused by *streptococcus equi* and inflammation of URT and abscessation adjacent lymph node and respond penicillin therapy.

Sporotrichosis: is chronic subcutaneous mycosis occur only sporadically affected group of animals. It is caused by *sporotrichum schaki* with single walled spore of gram positive fungus. Only small amount of pus are discharged from lesion and there after no lymphatic involvement.

## 2.9. Treatment

There is no completely satisfactory treatment is for epizootic lymphangitis. In endemic areas it is treated by inorganic iodides, potassium iodide (KI) and sodium iodide (NaI). Intravenous injection of 100ml of NaI of 10% solution repeated weekly for four weeks or oral administration of KI at 0.096gm/kg body weight with topical application and infuse nodules after incision and drainage of pus with 4% tincture iodine solution showed good response in early stage of the cases in Ethiopia (SPANNA, 2006; Getachew *et al.*, 2007; Hadush *et al.*, 2007).

As a drug of choice the infected horses were treated with an intravenous injection of Amphotericin B at dose 0.2mg/kg body weight three times on alternate days and treating the lesion with 4% iodine solution for several days (Ali -Ani, 1999). Ketoconazole can also be given orally at a daily dose of 10mg/kg (Plumb, 1999). But outcome depends on stage of disease, dosage rate and length of treatment (Getachew and Hadush, 2007).

There is also a report of combination of treatment with sodium iodide and penicillin, streptomycin or crude dried ground of "Endode" (*Phytolacca dodecandra*) with penicillin-streptomycin show significance responses (Hadush *et al.*, 2007). Other related studies that was the effect "Endod" on case of epizootic lymphangitis has therapeutic effect (Ameni and Tilahun, 2005). Additionally related study reported that the effect of *P. dodecandra* or "Endod" is due to extract in the secondary metabolite N- butanol identified in berries are all active antifungal compounds (Abad *et al.*, 2006; Negesse *et al.*, 2012; Perkurst *et al.*, 1973).

## 2.10. Prevention

According to the world health organization for animal health (OIE) recommendation for the control of EL are as follows. Controlling of the disease is usually through elimination of the infection. This is achieved by culling of infected horses and application of strict hygiene practice to prevent the spread of organism. The long incubation period of the disease, high persistence of the agent and the presence of clinically health carrier make controlling the disease difficult in endemic areas

(Scantybury, 2009). So, control of the disease in endemic countries depends on the incidence of the disease, method of husbandry, attitude and economic capacity of the farming community. However culling of infected animals in an endemic area, particularly in developing countries is impracticable and practical control at present depends on basic hygiene, wound management, infection control and treatment when it is available. Contaminated inanimate objects should either be thoroughly disinfected or destroyed (Radostais *et al.*, 2007; Ali-Ani, 1994; Pal, 2007). The organism can be destroyed by 1% Hypochlorite, Gluteraldehyde, Formaldyde and Phenolics (Anzuino, 2008).

In Ethiopia, prevention of this disease mostly depend on educating horse owners in such a way that they present case early to veterinary clinics for treatment, advice on basic hygiene of harness and other equipment they use. In addition, avoiding common use of tacks between animals unless otherwise good cleaning of cart equipments is practiced, fly control by some fly repellent cream, promoting euthanasia in advanced cases with careful disposable of infected carcasses, prevent wounds punctually by repairing and maintaining of their harnesses and proper management of wounds and appropriate dressing.

Regarding immunization live attenuated vaccine produced at high temperature and 3ml injected SC tested in China was reported to protect 75% animals inoculated with immunity persisting for > 2 years (Zhang *et al.*, 1986 and Ali-Ani, 1999). A killed formalized vaccine prepared from the yeast form of the fungus and administered SC at dose of 5ml once a year has given good results (Ali-Ani *et al* 1998). Vaccinated animals may be serologically positive which may be difficult for control and eradication programs (Ali-Ani, 1999) but none of this vaccine are commercially available so far.

### **2.11. Bacterial contaminant isolated from EL lesion**

Bacterial contaminant found everywhere may infect and create complication with equine histoplasmosis lesion. This disease equine histoplasmosis is rarely responding to treatment. One of the reason in addition to the chronic nature of the disease and could also be due to the complication the lesion with different bacterial

(Hadush,2004; Hadush *et al.*,2008). The presence of biofilmin equine wounds partly explains the reluctance of many lower limb wounds to heal. Non healing limb wounds in horses are well documented welfare and economic concern. So these study can be shape future treatment in order to increase the healing rate and decrease the costs and suffering associated with equine wounds (Westgate *et al.*, 2011) So the bacteria involved in pathogenesis leading to leukocyte recruitment and lymphocytosis requiring an efficient anti biotherapy coupled to antifungal drugs.

Bacterial infection of wound generally clinically comprises two identifiable elements which include regional inflammation that is excessive for the type, size or age of wound and purulent exudate from or within the wound (James, 2014). Hence in order to provide effective treatment the identification of bacteria invaders from the lesion and then determination of their drug susceptibility pattern are of paramount importance. Report indicates that study was conducted and isolated bacteria invaders contaminating the lesion of EL and also drug sensitivity test on isolated bacteria. As the study conducted around Mekelle, sample collection done from 24 cart horses and at different anatomical sites of infection from different type of lesion closed, open, and mild sever lesions in sterile conditions (sterile syringe used).Sample collected from closed nodules were washed with water and soap, shaved, disinfect with alcohol and pus sample collected by sterile syringe and in similar case pus is collected from open lesion and directly inoculated to nutrient broth and transport and transfer to growth media. After culturing the pure colony sub cultured aerobically and anaerobically at 37°C for 24-48 hr for staining and morphological identification of organism was done by biological tests (Hadush *al et.*, 2008). The dominant bacteria isolates from confirmed cases of EL in closed and open lesions of equines observed in 24 cart horses at Mekele town are indicated in Table 2 below.

Table 2: Dominant bacterial isolates in closed and open equine histoplasmosis lesion observed in 24 carthorses from Mekelle town , Ethiopia, 2014

Dominant bacteria isolates	Total	Number of bacterial isolates according to severity stage of EL									
		In closed lesion					In open lesion				
		a	b	c	d	Total	a	b	c	d	Total
<i>Bacillus</i>	32(27.1%)	4	3	3	3	13(27.7%)	4	4	5	6	19(26.8%)
<i>Aeromonus</i>	29(24.6%)	3	4	4	4	15(31.9%)	3	3	4	4	14(19.7%)
<i>Klebsiela</i>	1(0.1%)	1	0	0	0	1(2.1%)	0	0	0	0	0%
<b>Subtotal</b>	62(52.5%)	8	7	7	7	29(61.7%)	7	7	9	10	33(46%)
<i>Staphylococcus</i>	19(16.1%)	1	0	1	1	3 (6.4%)	3	3	5	5	16(22.3%)
<i>Micrococcus</i>	20(16.9%)	1	2	3	2	8(17%)	1	1	6	4	12(16.9%)
<i>Rhodococcus</i>	17(14.4%)	1	3	2	1	7(14.9%)	2	3	1	4	10(14.52)
<b>Subtotal</b>	56(47.5%)	3	5	6	4	18(18.3%)	6	7	12	13	38(53.5%)
<b>TOTAL</b>	118(100%)	11	12	13	11	47(100%)	13	14	21	23	71(100%)

*Note: a= early, b=moderate, c= sever and d = highly sever*

Source: Hadush *et al.*, 2014

Six different bacteria genera (*Bacillus*, *Aeromonus*, *Klebsiella* for bacilli group and *Staphylococcus*, *Micrococcus* and *Rhodococcus* for cocci) were isolated from different stages and forms of EL lesions. Broadly the majority of the bacteria isolated from closed EL lesions were bacilli (27.7%) where as in open lesions cocci, mainly *Staphylococcus species* were predominant but bacilli species were also frequently identified in open lesions. Concerning the antibiotic sensitivity of dominant bacterial isolates, Gentamycine resistance was observed from Cefoxin, Streptomycin, Tetracycline and Amoxacillin. On the other hand, *Aeromonus* predominantly isolated from the closed lesion and frequency seen in open lesions of horse histoplasmosis, so it will require attention during treatment of the disease (Hadush *et al.*, 2014). Other study was also confirmed that the swelling is due to a restriction of lymphatic flow because of bacterial complication like *Staphylococcus Streptococcus*, *Pasturella*, *Pseudobacterium*, *Fusobacteria*, *Actino bacillus* and *Nocardia* (Sellnow, 2000).

Other study reported that the isolation of *Streptococcus* and *Coryne bacterium* as well as *pseudomonas* are also observed (Ameni and Fontaine, 2003; Amen and Tilahun 2003; Hadush, 2004).

As study indicated *Aeromonas* are non fastidious a gram negative rod bacilli widely distribute in fresh and salty water as well as sewage water (Le Chevallier *et al.*,1980). This organism are important wound pathogen and pus forming organisms of domestic animals including horse, pigs, sheep's and cows incase of polluted environment they are invade and pathogen of soft tissue infection ( Janda and Abbott , 2010 ). They are infect skin and form skin nodules as well as lesion (Young and Barr, 1981).

*Klebsiella* is a another gram negative bacteria that colonizes and cause for wound infection and ulcerogranulomatouse and characterized by beefy red ulcer and create necrosis (Shahab Quresh and Michael Stuart Bronze. 2016). *Proteus* is another gram negative bacteria widely distributed in nature. They have clinical significance in creating of wounds and urinary tract infection. They also cause abcesiation (pus forming) and being found in animal matters. (Rauprich *et al.*,1996). *Corneabacteria* a gram positive polymorphic bacteria that cause for ulcerative lymphangitis in horse. The bacteria enter to the horse through abrasion or wounds on the skin and transmitted to other via flies. These bacteria affects lymphatic vessels of hind limbs. It form according lymphatic and formation of nodule and abscess with greenish discharge (Pascoe, Knottebelt, 1999).

Some bacteria such as *Staphylococcus*, *Bacillus* and *Aeromonas* that are frequently found in the EH lesions can potentially contribute to the pathogenesis and to the severity of the disease leading sometimes to death in severely infected horses. In other study, the abscess is the hallmark of *Staphylococcal* infection , which consists of a fibrin wall surrounded by inflamed tissues enclosing a central core of pus containing organisms and leukocytes. From this focus of infection, the organisms may be disseminated hematogenously, even from the smallest abscess(Loir *et al.*, 2003; Smith, 2007). As study indicated in a total 340 bacterial isolates were identified from all the equine wound and skin samples. *Pseudomonas aeruginosa* and *Enterococcus faecium* were the most predominantly isolated

bacterial species from equine wound and skin samples respectively. *Staphylococcus* was the most commonly isolated genus in both environments. Bacteria cultured from chronic and acute wounds showed significantly higher biofilm forming potential than bacteria isolated from skin. This paper highlights preliminary evidence supporting the presence of biofilms and a high microbial diversity in equine chronic wounds. The presence of biofilms in equine wounds partly explains the reluctance of many lower limb wounds to heal. Non-healing limb wounds in horses are a well documented welfare and economic concern.

As another study indicated that 90% of horses wounds are colonize by *Staphylococcus species*, where it significant wound pathogen in animals as well as humans. So *S. aureus* and other species are heavily involved to difficulty in wound infection healing in equines ( Theoretic *et al.*, 2012; Carnwath *et al.*, 2014; Tobiasc *et al.*, 2016). So Wound management equine patient Can be very difficult due to bacterial infection. So using anti microbial agents is very important (James, 2014).

In other study indicated that the presence of gram negative bacteria in wounds is aggravated the severity of infection besides other criteria and cause for the delaying of wound healing. So severely infected wound would not heal easily because defective immune function that leads the bacterial to proliferate and contaminant Bacteria infect the wounds via exudates or by environmental contaminants. The identified wound pathogen were found in study before, *Staphylococcus*, *Stereptococcus*, *Actiobacter*, *E.coli*, *Proteus Vugaris* and *Pseudo-mona aeroginosa* (Nagoba *et a.l*, 2013).

Other study also indicated that the most implicated bacteria in lymphangitis and Cellulitis in horse are coagulase positive and negative *Staphylococcus species*, *Streptococcus* gram negative aerobic organism and aerobic bacteria's are involved (Wilso,2001).*Bacillus strains* were susceptible to all antibiotics except that sensitivity to *Streptomycin* is moderate.

According to Hadush (2004) report, the *bacillus species* were susceptible to aminoglycosides, particularly gentamycine. *Aeromonas* were susceptible to Gentamycine and Amoxicillin but resistance to tetracycline. *Micrococcus* was highly susceptible to all antibiotics except tetracycline. As other study indicated that the yeast form and mycelia form of *Histoplasma capsulatum* treated by the combination of and chloramphenicol was more effective against the yeast phase of *H. capsulatum* than the mycelial phase. In contrast, clotrimazole was more effective against the mycelial phase (Gabal and Mohamod, 1985)

### 3. MATERIALS AND METHODS

#### 3.1. Description of Study area

The study was conducted in Bishoftu and Akaki towns Bishftu is located in Adea district, Oromia regional state, Ethiopia. It is located at 45km away from the capital city, Addis Ababa. Bishoftu town is found at 1900 meter above sea level and receiving an annual rainfall of 1115mm with two rainy season: March to May (short rainy season) June to September (main rainy season). The annual average maximum and minimum temperature are 10°C and 8.5°C respectively with relative humidity of 61.3% (NMSA, 2003).

Akaki is one of the sub cities in Addis Ababa. It is located at an altitude of 2120 meter above sea level with annual rain fall of 1200mm and annual average maximum and minimum temperature of 20°C and 18°C respectively. The area experiences bimodal rainfall pattern with short rainy season from March to May and the long rainy season from June to September (NMSA, 2003). The report shows that 22,676 donkeys, 6,136 horses, and 2,015 mules are found in this town (Dessalegn *et al.*,2016)

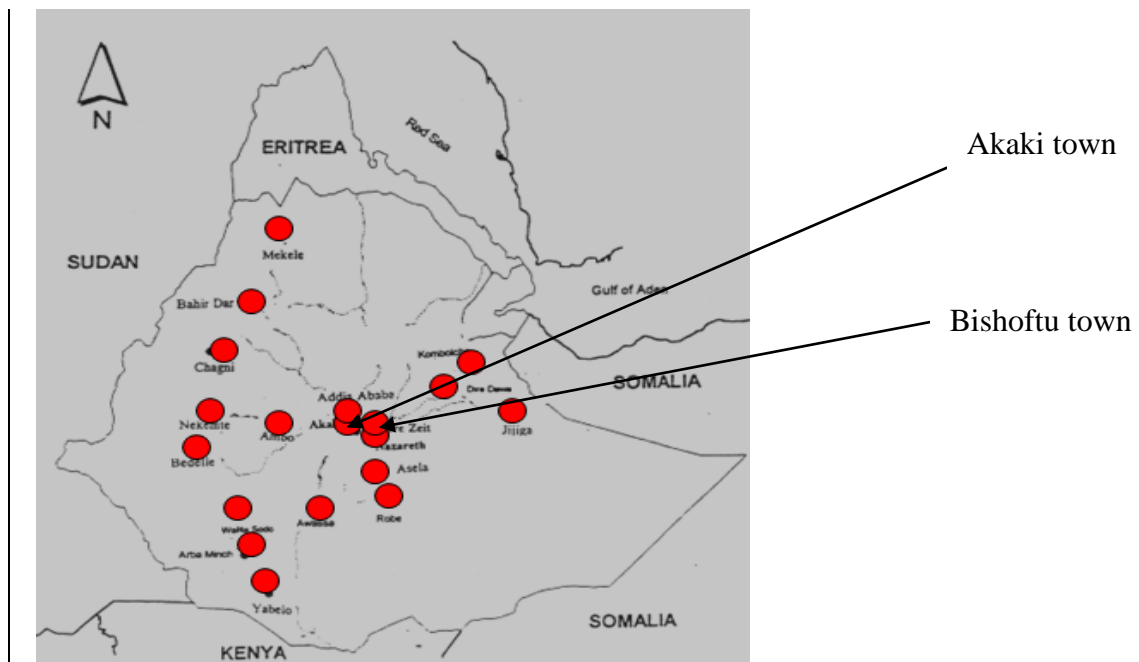


Figure 8: Map of the study area  
(Source: SPANA Ethiopia, 2006)

### **3.2. Study Animals**

Horses of local breed with characteristic EL lesion were included in this study. Fifty six from Bishoftu and sixteen from Akaki were included.

### **3.3. Study methods**

#### ***3.3.1. Clinical examination of the animals***

Physical and systematic clinical examination of horses was done to identify animals with a clinical signs of EL. During the examination, owners name and address, animal identification, observed clinical signs, body parts involved, number of topical nodules or ulcers of the selected horses were recorded.

The identified horses were categorized into three different groups based on the stages of disease. Stages of the disease were determined by level of cording, the number of sites and limbs involved and diameter of lesion and number of palpable nodules and lymph nodes. Criteria that were used to categorize the three stages are indicated in Table 3( Getachew, 2007).

Table 3: Criteria used for categorization of stages of Epizootic lymphangitis

<b>Stages of disease</b>	<b>No. of ulcers and palpable nodules</b>	<b>Radius of lesion in case circular in diameter</b>	<b>Distance between 1st and recent nodules if it is straight</b>	<b>No. of limbs involved</b>	<b>No. of sites involved</b>	<b>No. of lymph node involved</b>	<b>Level of "cording" activity"</b>
<b>Early</b>	1-5	≥10cm	≥40cm	1	1	Nil	Nil
<b>Moderate</b>	6-20	≥20cm	≥100cm	1-2	1-3	0-1	Moderate
<b>Severe</b>	Above 20	Above 20cm	≥100-150cm	1-3	1-5	1-3	Pronounced

Adapted from Getachew *et al.*, 2007

### **3.3.2 Handling animals during sampling**

Before sampling, animals were well restrained using nose twitch and in aggressive horses sedatives were used (Hulme, 2002).

### **3.4. Sample collection, processing and examining**

Pus samples were collected from un-ruptured palpable nodules using sterile syringe and needle after the nodules were washed with soap and water, shaved, and disinfected with alcohol. The aspirated content of the nodules were used for the preparation of smears for microscopic examination and cultured on different media (Getachew *et al.*, 2007). Media were prepared according to the rules prescribed on the bottle container (Annex 2). Media were weighed, dissolved using heat and shakers, autoclaved at 121°C for sterilizing and cool in water bath at 50°C and dispensed in to petridishes and wait to cool and for blood agar enriched with 7% defibrinated sheep blood as well as procain penicillin G  $6 \times 10^6$  IU for SAD agar preparation. Once the medium were prepared and ready to use aseptically collected pus sample was inoculated or stricken under laminar air flow on different plates to avoid contaminants on sterile media and incubated in incubator at 37°C in inverted position for yeast growth and at room temprature for mycelial growth. The samples were cultured on nutrient agar media for less fastidious organism growth and on blood agar (Oxoid, U) for fastidious bacteria isolate and to check heamolysis. Macconkey agar (Oxoid UK), was used for isolation of gram negative bacteria and the isolates were further sub cultured on Eosin Methylene blue (EMB) and Xylose Lysine Deoxycholate (XLD) agar. All agar plates were incubated aerobically at 37°C for 24to 48 hours and then bacterial colonies were identified. *Staphylococcus* and *Aeromas* were isolated from Manitol salt agar (Oxoid UK), *Streptococcus* isolated from Eduward media (Oxoid UK), *Escherchia coli* isolated from Eosin Methyl Blue (Oxoid UK), *Klebsiella* and *Proteus* isolated from XLD agar. The colony were examined macroscopically for morphology and by further stain. The aspirated pus samples were also cultured on two Sabouradus Dextrose Agar

(SDA) impregnated with Fortified procain penicillin G to identify the mycelia form incubated at room temperature and yeast form incubated at 37°C indicated in (annex 2). The inoculated media are kept at 25°C for 2-8 weeks as it has slow growth in case of fungal mycelial agent. The direct smears of same sample was fixed with heat, stained with gram stain for the identification of the yeast form of HCF. Examination were made using 40 x magnification followed by oil immersion at 100x magnification until the fungus and bacteria was demonstrated in the clinical specimens as described by Carter,(1991), Getechew *et al.*,(2007) and Asfaw *et al.*, (2012,). Annex 4. So isolation and identification of bacterial contaminants and the fungus causative agent was done by smear, colony characteristics and use of selective media.

### **3.5. Study design and sampling method**

The study design was cross- sectional type. Purposive sampling method was used to select 72 horses with typical EL lesions. Infected horses were grouped in to three categories (Early, Moderate and sever) based on the severity of the disease. Each of these categories were divided in to two sub groups based on whether they were taking treatment or not( new case join SPANA clinic and others follow treatment).

### **3.6. Questionnaire survey**

#### *3.6.1. Ethical clearance*

Ethical clearance certificate for this research was obtained from Addis Ababa University, College of Veterinary Medicine to conduct questionnaire survey and for sample collection from study horses and attached at end of this paper.

Structured semi closed questionnaire was developed and delivered to respondents to collect information related to the impacts of EL. Before the interview, the aim of the study were briefed for the respondents and were asked for their voluntariness.

Accordingly, 100 respondents of different groups of key stake holder including horse owners, community members/users of cart horse for transportation, traffic police man, and person from municipality working on town sanitation and hygiene were interviewed. The base line for selection of respondents were nearby to uses of horses in case of users and owner while disease predispose horses on main roads for the case of traffic police man and urban greener and hygiene keepers. Types of questions indicated under annex 1.

### **3.7. Data Management and Analysis**

The collected data related to the findings were coded and entered in to MS excel spread sheet. Statistical analysis was performed using SPSS version 20. Descriptive statistics including frequencies percentages, graph were used to summarise the results.

## 4. RESULTS

In this study, 72 horses with characteristic lesions of EL were sampled for identification of the causative agent of EL and associated co-infect bacteria involved. Direct gram stained smears of the contents of pyogranulomatous skin nodules revealed the presence of EL causing organism, HCF yeast form, in 71 cases from 72 samples and 10 bacterial genera were isolated based on gram stain of colonies from cultured samples and also colonies characteristics on selective media.

### 4.1. Microscopic examination of yeast under gram stain and macroscopic appearance of mycelia colony of HCF on SDA media

Out of 72 examined samples 71 (98.6%) of *Histoplasma capsulatum var farciminosum* yeast was identified by direct microscopic examination whereas 42 (58.9 %) of mycelia growth was observed by culturing on SDA enriched with 2.5% glycerol media. Unfortunately the yeast form negative to growth within 6 weeks .

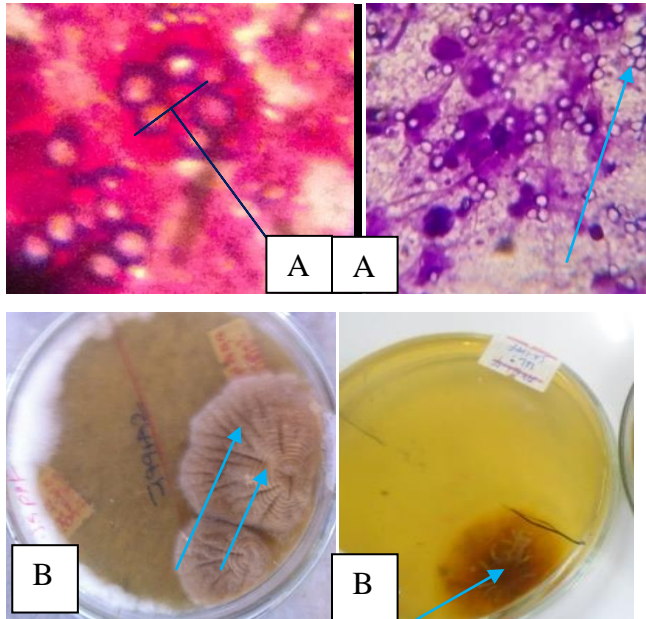


Figure 9: Gram staining with lemon shape, round to oval and holo unstained capsule Yeast of HCF (A) and Dry, grey, white, granular with wrinkled/lined, cerebriform, convoluted mycelia colonies of *HCF* on SDA media (B)

#### 4.2 Bacterial isolates from horses with EL nodules with pus

Different bacterial genera including gram positive *bacilli* and gram negative *bacilli* such as *Aeromonus*, *Klebsiella*, *proteus*, *pseudomonas* and *E coli* were isolated. Besides, gram positive cocci such as *Staphylococcus*, *Micrococcus*, *Streptococcus* and *Corynebacterim* were isolated from different stages of EL lesions. Mixed infection was common and at least one bacterial genera was identified from all samples examined. The common bacteria isolated from EL lesions were *Staphylococcus species* 64 (88.8%) and *Micrococcus* 54 (75%). Bacterial isolates identified in this study with their frequencies of occurrence is indicated in Table 4.

Table 4: Bacteria isolated from pus of horses with EL lesions (n=72)

<b>Bacterial isolates</b>	<b>Number (%)</b>
<i>Staphylococcus</i>	64 ( 88.8)
<i>Micrococcus</i>	54 (75)
<i>Streptococcus</i>	30 ( 41.1)
<i>Corynebacterium</i>	16 (22.2)
<i>Aeromonus</i>	25 (34.7)
<i>Klebsiella</i>	16 (22.2)
<i>Proteus</i>	15 (20.7)
<i>Pseudomonas</i>	15 (20.8)
<i>E coli</i>	5 (6.8)
Other gram positive <i>bacilli</i>	30 (41.7)

4.2.1. Microscopic examination of different bacteria under gram stain and its macroscopic appearance of colony on different media

i) *Staphylococcus isolates*

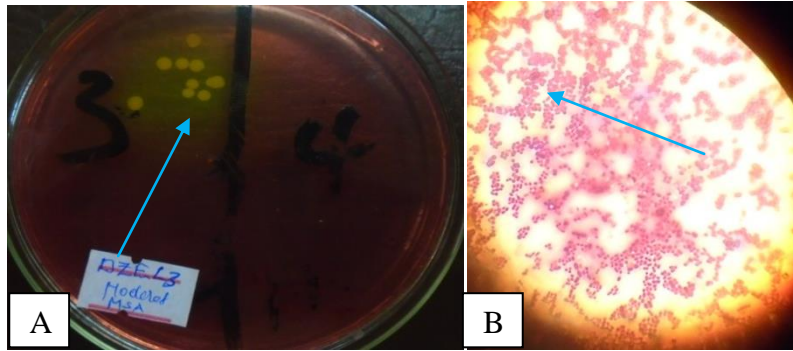


Figure 10: Golden yellow pigmented colony on mantoli salt agar (A) and Gram positive with bunch of cocci (B)

ii) *Streptococcus isolate*

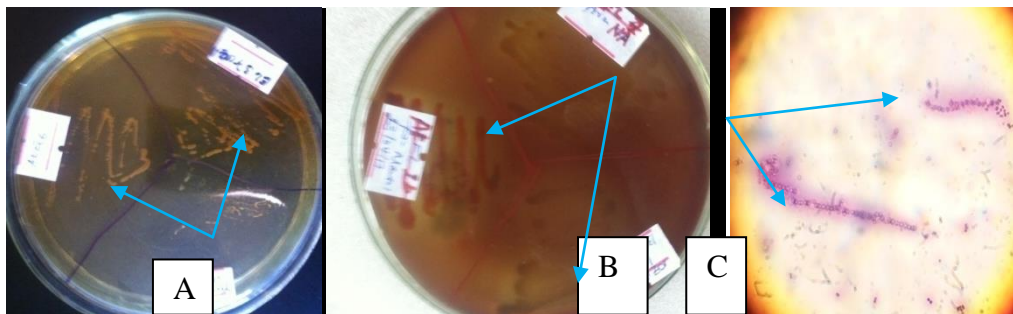


Figure 11: Muroid colony on Edward Media (A), Hemolysis on blood agar (B) and Gram positive, chain forming cocci (C)

iii) *Micrococcus isolates*

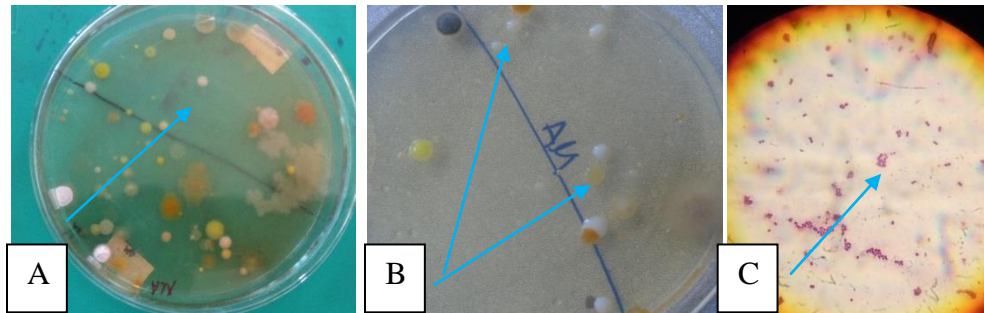


Figure 12: Shiny White pigmented colony of *Micrococcus* on nutrient agar media and subcultured (A&B), Microscopic examination of gram stained tetrad cocci (C)

iv) *Corynebacterium isolates*

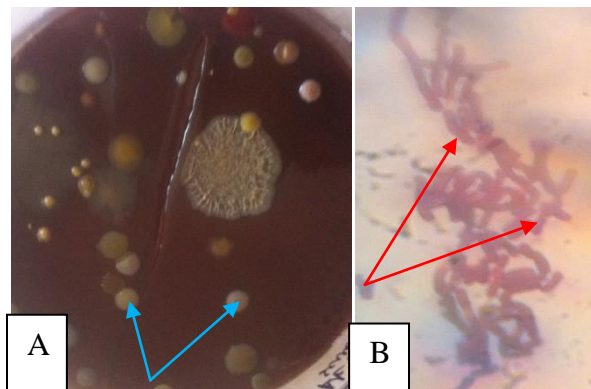


Figure 13: Colony of *Corynebacterium* grown on blood agar and showing no hemolysis (A) and Gram positive rod appearing with group of parallel cells or at sharp angle like 'Chinese' letter (B).

v) *Aeromonas isolates*

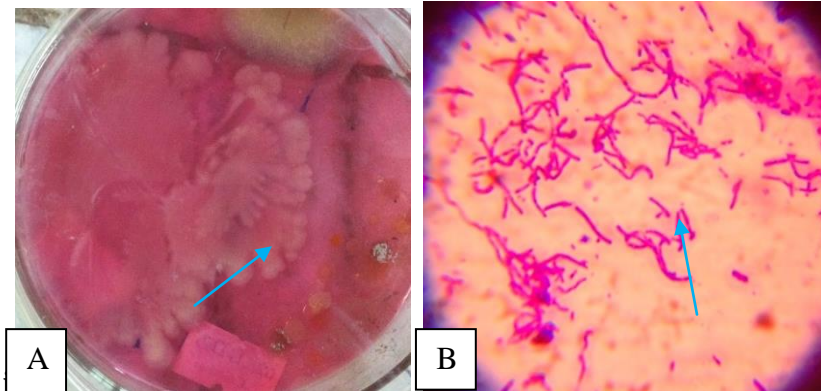


Figure 14: Smooth mucoid or buffy colored with irregular edge colony on MSA (A) and Gram negative rod (B)

vi) *Klasiella isolates*

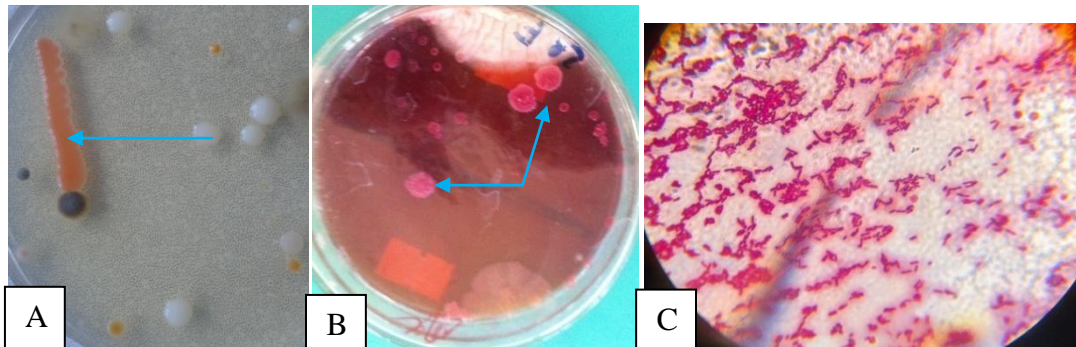


Figure 15: Gray Mucoid, pale to pink rough edge colony (seems mucouse membrane) on nutrient agar (A), Pink colony on MacConkey (B) and gram negative rod (C).

vii) *Proteus isolates*

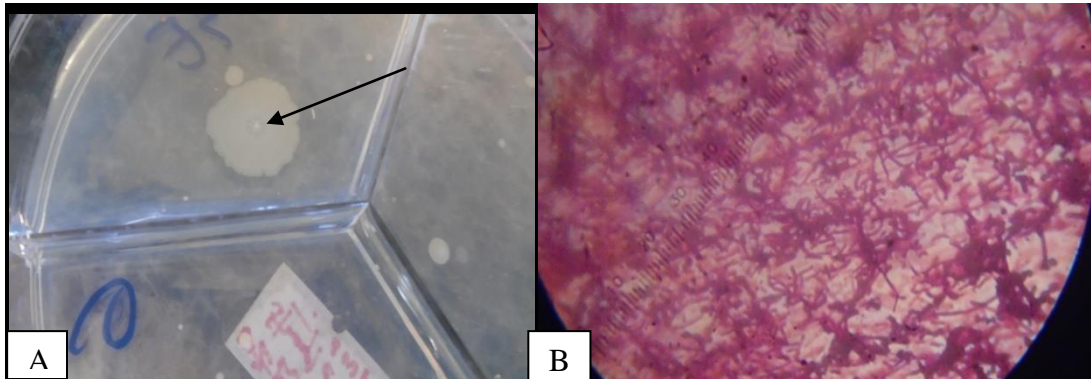


Figure 16: Gray, wavy swarming mucoid pink colony (A) and gram negative long rod (B).

Viii) *Pseudomonas isolates*

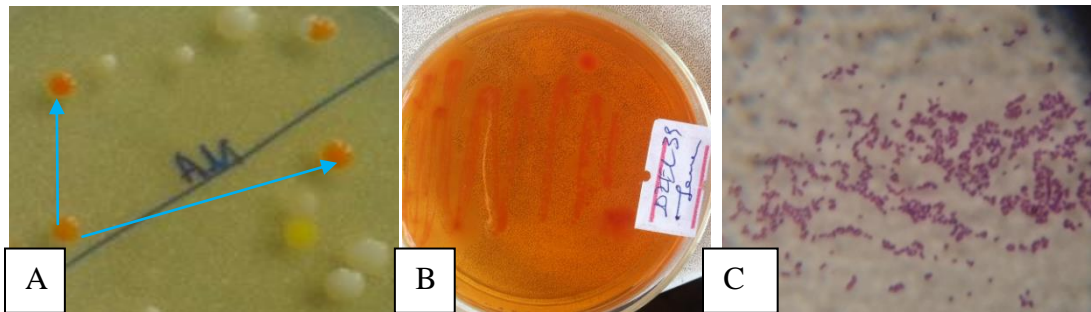


Figure 17: Blue green colony (A) *Pseudomonas* grown on XLD agar (B) and Gram negative rod (C)

xi) *Echerichia coli* isolates

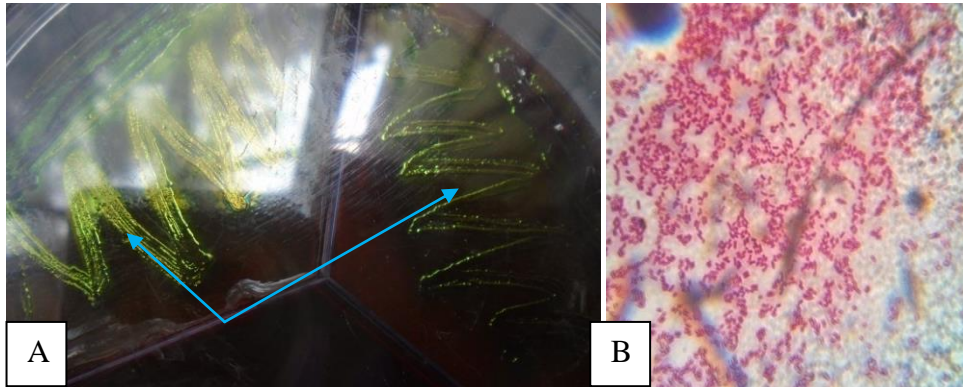


Figure 18: Distinctive green metallic sheen colony of *E.coli* on EMB agar (A) and gram negative small rod shape under microscope (B).

xii) Gram positive *Bacilli* isolates

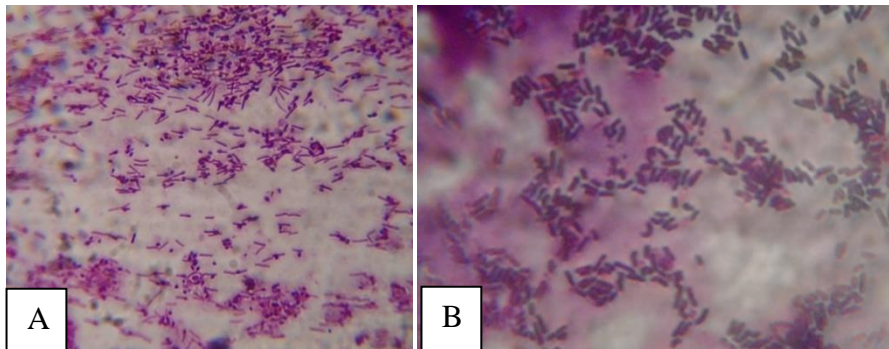


Figure 19: Gram positive rod shape *Bacilli* with spore at one end which was not bulge mother cell ( A) and other gram positive rod shape *bacilli* (B).

### 4.3. Bacterial isolates from horses under treatment with topical iodine and new EL cases without treatment

Pus samples were collected from 43 horses which were under treatment with topical 4% iodine tincture and 29 new cases. Different bacteria were identified both from horses under treatment and non treated horses. The occurrence of *Staphylococcus*, *Micrococcus*, *Klebsiella* and *E. coli* were relatively higher in horses without treatment while the occurrences of *Streptococcus* and *Proteus* were relatively higher in horses under treatment. The occurrences of other bacterial isolates were almost similar as shown in Table 5

Table 5: Bacterial isolation rate from horses under treatment and without treatment.

<b>Isolated bacterial contaminants</b>	<b>Frequency of isolates in horses under treatment in (%) (n=43)</b>	<b>Frequency of isolates in horses without treatment in (%) (n= 29)</b>
<i>Staphylococcus</i>	35 (81%)	27 ( 96.4 %)
<i>Micrococcus</i>	30 (69.7%)	24 ( 87.7 %)
<i>Streptococcus</i>	22 (51.1%)	8 ( 28.6 %)
<i>Corynebacterium</i>	10 (22.4 %)	6 ( 21.4 %)
<i>Aeromonus</i>	15 (36.3 %)	10 (35.7 %)
<i>Klebsiella</i>	7 (16.2 %)	8 (28.6 %)
<i>Proteus</i>	11(27.2 %)	3 ( 10.7 %)
<i>Pseudomonas</i>	10 (22.6 %)	5 (17.8 %)
<i>E. coli</i>	1 (2.3 %)	4 ( 13.8 %)
Other gram positive bacilli	15 (38 %)	13 (46.4 %)

#### 4.4. Bacterial isolates from horses with different stages of EL cases.

The study animals were categorized into early, moderate and severe cases of EL. Accordingly 32, 22 and 18 horses were categorized as early, moderate and severe cases respectively. It was found that high proportion of different bacterial isolates were frequently identified in severe cases as compared to moderate and early cases. The frequency in percentage of bacterial isolates in relation to the severity of EL cases are indicated on figure 20 and presented on graph using bars. The Pictures were supported for stages of EL disease on annex 7

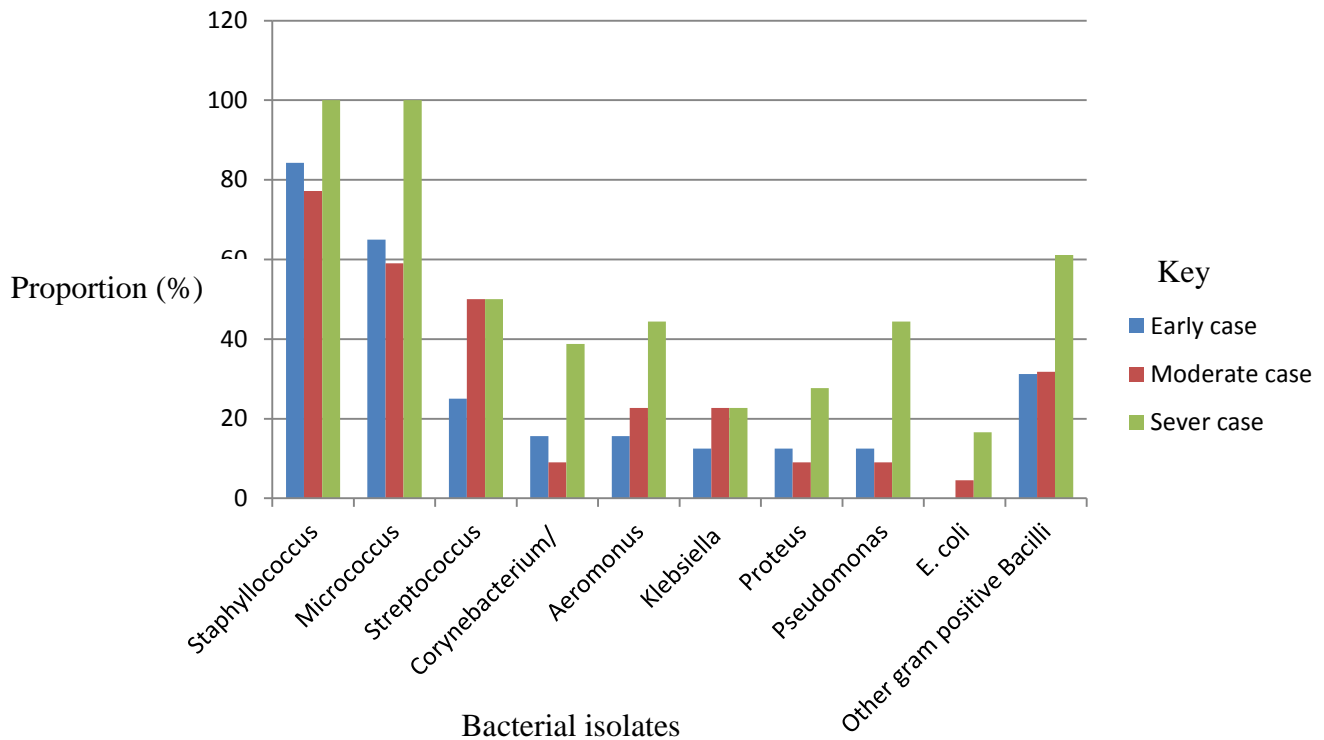


Figure 20: Bacterial isolated from pus samples of different stages of EL infected horses explained using bars in percentage.

#### 4.5. Area based occurrence of isolated bacterial contaminant from EL Lesion

From 16 samples collected and examined from Akaki, *Staphylococcus* was identified in 15 (93.7% ) samples. This bacteria was also isolated from 49 (87.5%) of samples collected from Bishoftu town and were most common pathogens. The result of this study indicated the existence of all bacterial isolates in the study areas indicated in Table 7.

Table 6: Area based occurrence of isolated bacterial contaminant from EL lesion.

Bacterial contaminants	proportion in different distinct	
	Bishoftu town (n=56)	Akaki town ( n=16)
<i>Staphylococcus</i>	49 ( 87.5 %)	15 ( 93.7%)
<i>Micrococcus</i>	43 (76.7 %)	11 (68.7 %)
<i>Streptococcus</i>	18 (32.1 %)	12 (75%)
<i>Corynebacterium</i>	11 (19.5 %)	5 (32.1%)
<i>Aeromonus</i>	18 (32.1%)	7 (16 %)
<i>Klebsiella</i>	11 (19.6 %)	5 (32.1%)
<i>Proteus</i>	10 (17.8 %)	5 (32.1%)
<i>pseudomonas</i>	11 (19.6 %)	4 (25 %)
<i>E coli</i>	4 (71.7 %)	1 (6.2 %)
<b>Other gram positive bacilli</b>	24 ( 42.8 %)	6 (37.5%)

#### 4.6. Questioner survey on the effect of epizootic lymphangitis among different groups of community

Different community groups (owners, users of cart horse for transportation, traffic polices and persons from municipality) were interviewed for their perception on the effect of the disease within the community. In this questionnaire survey, all the respondents indicated that the performance and income generated adversely affected due to EL. Except the owners, all respondents in other group replied that the welfare of horses is compromised in horses affected with EL because the owner perception about the welfare compromise of infected horses, it may be owners focused on income rather welfare of infected horse and they think that the horse get feed were enough. Incomes collected by those animals were reduced that is because user haven 't showed interest to use such animals due to smelling, flies, weak in walking and other reasons. Besides, almost all respondents agree that whenever infected animals are abounded they may cause environmental contamination, act as a source of infection for other horses and cause for traffic jam which may results in car accident. The observed cases of EL infected horse indicated the fact.




Figure 21: Severely infected and abounded horses in middle of road (A) and in field (B)

Table 7: Respondent reply result related to the effect of the disease within the community

Respondents	Respondents feeling and idea to the question raised about EL effect.								
	Effect of disease Reduced in (%)			Fate of severely infected horses abandoned to` (%)			The consequences of severely infected horse by EL abounded and cause for (%)		
	Welfare of animal	Income	Performance	Main road	River	Village	Car and human accident	Source of infection	Contaminating environment
Owner (n=40)	18 ( 45 )	40 (100)	40 (100 )	40 (100)	31 (77.6)	36 (90)	36 (90)	39 (97.5)	17 ( 42.5)
Users ( n=25)	25 (100)	25 (100)	25 (100)	25 (100)	22 (88)	24 (96)	25 (100)	25 (100 )	17 (68)
Traffic polices (n=20)	20 (100)	20 (100)	20 (100)	15 (75)	6 (30)	10 (50)	20 (100)	20 (100)	20 (100)
Person from municipality (n= 15)	15 (100)	15 (100)	15 (100)	15 (100)	9 (60)	14 (93)	15 (100)	15 (100)	14 ( 93)

## 5. DISCUSSION

Among 72 examined pus samples, 71 (98.6 %) were found to be positive for *Histoplasma capsulatum* var *farciminosum* yeast up on direct microscopic examination using gram stain techniques and 42 (58.9%) of the mycelia form of the fungus was grown on mycobiotic agar (SDA) enriched with 2.5% glycerol and addition of antibiotics. Mycelia form grown in suitable temperature and media (Ali Ani, 1999) penicillin G ( $6 \times 10^6$  unit/liter) were used instead of chloranphenicol to avoid the contaminant bacterial (Selim *et al.*, 1985; Radostis *et al.*, 1994). The growth of mycelia colony was slow and the Colonies appeared as dry, granular, wrinkled, cerebriform colonies, convoluted grey white and become yellow to dark brown similar to study before (Awad, 1960; Ali-Ani 1999; Ameni and Siyoum, 2002; OIE, 2008). The prevalence of this disease in this study is more than study conducted Before, 10.4% (Endebu and Rogeer, 2004) this indicated that there is infection of horses by this disease which support present study. However the difference in prevalence might be due to purposive sampling technique were used, only infected horses that clinically showed the using of EL were include that was suggestive for the disease.

The current study indicated that some different bacterial genera were isolated from all samples collected from lesions of EL. The bacterial genera isolated include: gram positive bacilli and gram negative bacilli including *Aeromonus*, *Klebsiella*, *proteus*, *pseudomonas*, *Corynebacterium* and *E. coli* from bacilli group and *Staphylococcus*, *Micrococcus*, *Streptococcus* and from cocci group from samples of different stages of EL lesions. This finding is closely comparable with (Hadush *et al.*, 2014) who reported majority of currently identified bacteria from EL lesions. The difference might be the difference in wound type which the samples were collected. Horse wounds have a high risk of becoming infected due to their environment. It is well documented that infected wounds harbor diverse populations of micro organisms that can be difficult to identify and fail to respond to antibiotic treatment, resulting in chronic non-healing wounds (Westgate *et al.*, 2011; Nagoba B. *et al*, 2013; Carnwath *et al.*, 2014).

The most commonly isolated bacteria from the EL lesions were *Staphylococcus species* (64, 88.8%) and *Micrococcus* (54, 75%) followed by *Streptococcus*, other gram positive *bacilli* (30, 41.7%) and *Aeromonas* (25, 37.7%). The remaining bacteria were relatively identified less frequently. *E. coli* being the least frequent. The dominance of *Staphylococcus*, *Micrococcus* and *Streptococcus* may be due to the fact that those bacteria are commonly found as skin flora of animals where easily to invade the infected skin tissues. But the rest of isolated bacterial found in environment and mud area or in aquarium (*Aeromonas*) where it may get probability of invading affected skin of animals. So, in severe cases more prominent due to the lesion or wounded skin part increased. In line with this, several reports indicated that *Staphylococcus* was the most commonly isolated genus in wounds and skin sample (Theoretic *et al.*, 2012; Carnwath *et al.*, 2014; Tobiasc *et al.*, 2016). Other study also supported that the most implicated bacteria in lymphangitis and cellulitis in horse are coagulase positive and negative *Saphylococcus species*, *Streptococcus*, gram negative aerobic or an aerobic bacteria. However it was common isolates with other study, its prevalence in this study was high, may be due to directly take from pus from nodule. The current finding agrees with the positivity with Wilson (2001) and Westgate *et al.*; 2011 finding in which *Pseudomonas* were the most predominantly isolated bacterial species from equine wound and skin samples respectively. The presence of gram negative bacteria including *E. coli*, *Proteus Vugaris* and *P. aeruginosa* in wounds aggravate the severity of infection besides to other criteria and cause for the delaying of wound healing (Bessa *et al.*, 2015; Nagoba *et al.*, 2013). So wound management in equine patient can be very difficult due to bacterial infection indicated that using anti microbial agents is also very important (James, 2014).

The proportion of bacterial contaminants increased with the severity of the stages of disease because it may be due to severity of disease, the chronic nature of disease and their availability in different environments. So bacteria have get chance to invade the lesion easily exposed wounds to co-infect Bacterial complicated infection and invaded

EL lesions caused for bad smelling. The study supported that in advanced cases, the nodules and ulcers may have unpleasant odor in advanced case (Ameni, 2007) and swelling of the lymphatic vessel is due to bacterial complication restrict lymph vessel. From this angle the organisms may be disseminated hematogenously, even from the smallest abscess could ability to aggravating the disease (Loir *et al.*, 2003; Smith, 2007). These indicated that the presence of bacterial contaminates in lesions of EL infected horses.

Questionnaire survey was also designed in order to find the perception of respondent the importance of epizootic lymphangitis due to the effects of the disease on the horse and its impact on human livelihoods. According to response of different groups of community, the negative effect of epizootic lymphangitis is multi-directional. Though the magnitude of the problem is difficult to precisely describe, EL is known to lower the daily income of household, critically decreases the working performance and welfare of horses. According to respondent replay in this study all respondents indicated that EL adversely affect the performance of horses and the income generated using infected horses. The reduction income might arise from the reduction in working ability and refusal of passengers the working cart horses with EL and due to the death of severely affected animals. This may have a direct impact upon the livelihoods of owners and heir dependent family members. In line with this all groups of respondent except the owners agree that EL compromises the welfare of animals. From the owner groups only 45% of them recognized the welfare problem in EL infected horses it may indicated that horse with EL to be work and in sever case abandoned. Study supported this horse ,with EL continued to worked and in advanced cases, horses were abandoned due to in effective or unavailable treatment (Stephanie, 2014; Scantlebery *et al.*, 2015). According to respondents view horses with severe case of EL, 100% said that stand on middle of main road, 48.2% abandoned to river area and 82.2% of respondents said that stayed in the village. Study also indicated that the horses become debilitated and develop secondary infection and quit often they are abounded and seen on the road (Stephanie, 2014). The consequence of the abandoned in

different place were also accessed and investigated in this study. Accordingly different respondents replied that in average 97.7% of respondents replied that potential causes of cars and human accident, 93.7% of respondents replied that resulted in source of infection and 76.2% of respondents replied that severely affected and abounded horses are contaminating the environments because of bad smelling. So early checking and follow up is important before come to advanced.

## 6. CONCLUSION AND RECOMANDATIONS

The result of the current study indicated that the causative agent of epizootic lymphangitis (EL) is highly positive to collected pus samples as well as they are various co-infect bacterial associated with EL lesions. The bacterial isolates includes *Staphylococcus*, *Micrococcus*, *Streptococcus*, gram positive *bacilli* and other gram negative *bacilli* including *Aeromonas*, *Corynebacterium*, *Pseudomonas*, *Klinsiella*, *Proteus* were frequently found in the EL lesions and *E. coli* were also found to be positive. The occurrences of co-infect bacterial increased along the advancement of the disease. This may indicate that co-infect bacterial have their own contribution in enhancing pathogenesis and severity of the disease, which may result in chronic non healing wounds. This would have impact on the performance and welfare of horses resulting in reduction of income and death in severe cases which may create the impact on the owners economy which may have contribution in manifesting to their families and country economy. In addition, this disease have indirect consequences in case of severely infected horse stands in the middle of the road cause for car and human accident as well as source of infection for other susceptible animals. This study also indicated that the use of topical iodine could not stop the development of new nodules and significantly not reduce bacterial contaminates from un open wounds.

### **In light of present study the following are recommended:**

- ❖ In treating EL consideration should be taken about the presence of bacterial and their subsequent potential complications.
- ❖ Comprehensive study using molecular techniques should be under taken for isolation and identification of bacterial contaminants of EL to species level
- ❖ Awareness should be created for owners related to the early checking of the disease for the treatment and appropriate culling of infected horses.
- ❖ The pathogenic impact of isolated bacteria were not established in this study, therefore further research is needed.

- ❖ Anaerobic bacteria were not investigated due to limited laboratory facility so it needs further study.
- ❖ Further investigation should be conducted on Epizootic lymphangitis in order to develop practical and sustainable control and prevention strategies so as to reduce the social and economic impact of the disease.
- ❖ Antibigram should be analyzed for the isolated bacteria for proper treatment.

## 7. REFERENCES

- Aillo, B.S and Mays, A. (1998): The Merck veterinary Manual 8<sup>th</sup> Edition, Merck and Co., Inc. white station, *N.J*, Pp467-478.
- Aillo, L. (1968): Comparative morphology and immunology of members of genus histoplasma; A review *mykosen* **11**:507-514.
- Addo, BP. (1980): A review of epizootic lymphangitis and ulcerative lymphangitis in Nigeria: misnomer or misdiagnosis. *Bull Anim Hlth Prod Afr*, **28**: 103-107.
- Ali-Ani, F.K (1999): Epizootic lymphangitis in horses: a review of the literature. *Rev.Sci.Tech*, **18**:691-699.
- Abad, M. J., Ansuategui, M., Bermejo, P. (2007): Active antifungal substances from natural sources. *ARKIVOC*, (*Vii*). 116-145.
- Abate, D. and Fesseha, S. (1994): *In vitro* and *in vivo* antifungal activity of endod (*Phytolacca dodecandra*) In: Proceedings of a preparatory workshop held in Nazareth, *Addis Ababa University Press*, Pp. 62-66.
- Ali-Ani, FK.and Ali-Delaimi, K.A.(1986): Epizootic Lymphangitis in horses: clinical epidemiology and hematological studies. *Pak.Vet. J*, **6**: 96-100.
- Ali-Ani, F.K., Ali, A.H. and Banna, H.B. (1998): Histoplasma farciminosum infection of horses in Iraq.*Veterinaski Arhiv*, **68**:101-107.
- Ameni, G. and Fontaine, N. (2003): Isolation of Bacteria from the lesions of Equine Histoplasmosis and their drug sensitivity tests. Unpublished paper, Aklilu Lemma Institute of Pathobiology, University of Addis Ababa, Ethiopia.
- Ameni, G. and Siyoum, F. (2002): Study on Epizootic lymphangitis in cart horses in Ethiopia *J.vet., Sci*, **3**:135-139.
- Ameni, G. (2007): Pathology and clinical Manifestation of epizootic lymphangitis in cart mules in Ethiopia. *J. Equine Sci*, **18**:1-4.
- Ameni, G. (2006a): Epidemiology of equine histoplasmosis in cart horses in Ethiopia. *Vet. J*, **172**: 160-165.
- Ameni, G.(2006b): Preliminary trial on reproducibility of epizootic lymphangitis through experimental infection of two horses. *Vet. J*, **172**:553-555.

- Ameni, G. and Terefe, W. (2004): A cross-sectional study of epizootic lymphangitis in cartmules in western Ethiopia. *Preventive Vet. Med.*, **66**: 93–99.
- Ameni, G. and Tilahun, G. (2003): Preliminary laboratory and field trials on the effect of Endod (*Phytolacca dodecandra*) on epizootic lymphangitis. *Bull. Anim. Hlth. Prod. Afr.*, **51**:153-160.
- Awad, FI.(1960): Studies on epizootic lymphangitis in the Sudan. *J. Comp. Path.*, **70**: 457-463.
- Ameni, G.,Terefe, W. and Hailu, A. (2006): Histofarcin test for the diagnosis of epizootic lymphangitis in Ethiopia: development, optimisation and validation in the field. *Veterinary J.*, **171**: 358–362.
- Aravena-Roman M, Harnett G B, Riley T V, Inglis T J, Chang B J (2011): *Aeromonas aquariorum* is widely distributed in clinical and environmental specimens and can be misidentified as *Aeromonas hydrophila*. *J Clin Microbiol*; **49**:3006-3008.
- Biruhtesfa, A.,Yilikal, A., Bojia, E., Ayele, G.and Getachew, M. (2007): Aerobic bacterial isolates in Equids and their antimicrobial susceptibility pattern. *Intern. J. Appl. Res. Vet. Med.*, **5**:107-112.
- Bessa L J, Fazii P, *et al* (2015): Bacterial isolates from infected wounds and their antibiotic susceptibility pattern: some remarks about wound infection. *International Wound Journal*; **12**: 47-52.
- Chandler, F.W., Kaplan, W. and Ajello, L. (1980): Histopathology of Mycotic Diseases. Year Book Medical Publishers, Chicago, USA, Pp. 70–72 and 216–217.
- Clark NM, Femino JE, Chenoweth CE (2001): *Aeromonas* infection after medicinal leech therapy:case reports and review of the literature. *Infect Dis Clin Pract*; **10**:211-218.
- Carter, GR. and Chengappa, MM. (1991): Essentials of Veterinary Bacteriology and Mycology. 4th Edition, Lea and Febiger, Philadelphia,;Pp. 261-271.
- Carnwath R, Graham EM, Reynoldsk, Pollock PJ (2014): The antimicrobial activity of honey against common equine wound isolates. *Vet. J.*, **199**: 110-114.
- CSFPH (2009): Central Food Safety and public health.
- Dessalegn Genzebu, Berhan Tamir and Gebreyohannes Berhane. (2016): Study of Reproductive and Production Performance of Cross Breed Dairy Cattle under Smallholders

- Management System in Bishoftu and Akaki Town. *Int. J. Adv.Res. Biol. Sci.* 3(2): 151-157.
- Endebu, B. and Roger, F. (2003): Comparative studies on the occurrence and distribution of epizootic lymphangitis and ulcerative lymphangitis in Ethiopia. *Intl J App Res Vet Med.* **3**: 1-5.
- EARO (1999): National Animal Health Research Program strategy Document; Bureau of Agricultural and National Resource Organization (BANRO), Addis Ababa, Ethiopia.
- Edward B. (2005): Black's veterinary dictionary. 21<sup>st</sup> Ed. A & C Black Publishers Limited. 38 Soho Square, London. Pp.: 430
- El-Gundy M., Shokeir A., Wasfey I., Ahmed K., Elbedeiwy A., Abou-Gabal M. & El-Rehewy M. (1975): Histoplasmosis of the eyes of donkeys. An electron microscopic study. *Assiut Vet. med. J.*, **2**, 235-239.
- Endebu B. (1996) : Epidemiology of epizootic lymphangitis in Ethiopia: Retrospective analysis and cross-sectional study and treatment trail at Debrezeit and Akaki. DVM thesis, Faculty of Veterinary Medicine, University of Addis Ababa, Ethiopia, Pp.: 1-30.
- Fawi, M.T. (1969): Fluorescent antibody test for the serodiagnosis of *Histoplasma farciminosum* infections in Equidae. *Br. Vet. J.*, 125, 231–234.
- Fereda B, Bersissa Kumsa, Abere Bsrat, Shawit Kelyou (2010): Tick of donkey in central Oromiya regional state Ethiopia.
- Femino JE, Chenoweth CE(2001): *Aeromonas* infection after medicinal leech therapy: case reports and review of the literature. *Infect Dis Clin Pract*; **10**:211-218.
- Feseha G. (1993). Use of Equines in Ethiopia. In: Proceedings of the Fourth National Livestock Improvement Conference. Addis Ababa, IAR, Ethiopia. pp 51–57.
- Fawi, MT. (1971): *Histoplasma farciminosum*, the etiological agent of equine cryptococcal pneumonia. *Sabouraudia*; **9**: 123-125.
- Gillespie, J.H., Timoney, J.F., Hagan and Bruner, S. (1981): Infectious diseases of domestic animals. 7<sup>th</sup> ed. Cornell University Press. London: Pp. 390-391.

- Gabal, M.A., Bana. A. and Gendi, M.E. (1983): The fluorescent antibody technique for diagnosis of equine histoplasmosis (epizootic lymphangitis). *Zentralbl.Veterinarmed.* **30**, PP. 283–287.
- Gabal, M.A. and Khalifa, K. (1983): Study on the immune response and serological diagnosis of equine histoplasmosis (epizootic lymphangitis). *Zentralbl. Veterinarmed*, **30**, Pp317–321.
- Gold WL, Salit IE(1993): *Aeromonas hydrophila* infections of skin and soft tissue: report of 11 cases and review. *Clin Infect Dis*;16:69-74
- Guerin C., Abebe, S. and Touati F. (1992): Epizootic lymphangitis in horses in Ethiopia. *J. Mycol. Med.*, **2**: 1–5.
- Gabal, M.A. (1984): The effect of Amphotericin B, 5-Fluorocytosine and nystatin on *Histoplasma farciminosum* in vitro. *Zentralbl Veterinarmed* **31**: PP. 46-50.
- Guetntzal M N and Barons (1996): *Echericha , klebsiella , enterobacter , seratia, citrobacter* and *Proteus* in Barron's medical microbiology ( 4th edition).
- Getachew, A., Endebu, B., Gebreab, F., Jones, K., Akililu, N., Zerfu, A. and Mideksa, K. (2007): Treatment of epizootic lymphangitis in cart horses through participatory method.
- Gilbert, R.O. (1998): Epizootic lymphangitis in Foreign Animal Diseases. Richmond,V. A., Animal Health Association, United States, Pp.201-206.
- Guedes, H.L., Guimaraes, A J. and Muniz, MM *et al.* (2003): PCR assay for identification of *Histoplasma capsulatum* based on the nucleotide sequence of the M Antigen. *J Clin Microbiol* .**41**: 535-539.
- Hadush B. (2004): Equine histoplasmosis: preliminary treatment trial, isolation of bacteria from lesions and drug sensitivity test, Central Ethiopia. DVM thesis, Faculty of Veterinary Medicine, University of Addis Ababa, Ethiopia, pp. 9-20.
- Hadush, B., Ameni. G, Medhin, G. (2008): Equine histoplasmosis: treatment trial in cart horses in Central Ethiopia. *Trop Anim Health Prod.* **40**:407–411.
- Hadush B., Biratu D., Taddele H., Tesfaye D., & Ameni G. (2014): Bacterial contaminants isolated from lesions of equine histoplasmosis in cart horses of Mekelle town, northern Ethiopia. *Revue Méd. Vet.*,**165**: 25-30

- Hulme J.(2002): SPANA guide to animal care part I pp 2-8
- IVIS (2006): Epizootic Lymphangitis: Proceedings of the 9th International Congress of World Equine Veterinary Association Jan. 22-26, 2006. Marrakech, Morocco. 419. Available on line at <http://www.ivis.org/>
- James A.(2014): Management of severely infected wounds in equine patient. Johnson, P., Howden, B. and Bennett, C. (2006): *Staphylococcus aureus*: a guide for the perplexed. *Medical Journal of Australia*, **184**: 374-375.
- Janda JM, Abbott SL(2010): The genus *Aeromonas*: taxonomy, pathogenicity, and infection. *Clin Microbiol Rev*; **23**:35-73.
- Jagama T.and Jarso D (2016): Study on Epidemiology and Socioeconomic Impact of Epizootic Lymphangitis in Carthorses in Southwestern Shoa.
- Jubb, K.V., Kennedy, PC. and Palmer, N. (1985): Epizootic lymphangitis. In Pathology of domestic animals. Vol. 3. 4<sup>th</sup> Ed. Academic Press. New York,: 82-84
- Jubb K., Kennedy P. & Palmer N. (Eds.) (2006): Epizootic lymphangitis. In Pathology of Domestic Animals, Vol. 3, 5th Ed, Grant M. & Wayne F. Eds. Academic Press, New York, USA. Pp: 98-102.
- Kasuga, T., Taylor, J.W. and White, T. J. (1990): Phylogenetic relationships of varieties and geographical groups of the human pathogenic fungus *Histoplasma capsulatum* darling. *J Clin Microbiol*; **37**: Pp. 653-663.
- Kuastros, M. (2007): Major animal health problems of market oriented life stock development in Alaba woreda,southern nation and nationalities and people region, Thesis paper for fulfillment of doctorate of vet. medicine AAU, Pp 13
- Lemma, A., Brody, G., Newell, G.W., Parkhurst, R. M. and Skinner W. A. (1972) : Studies on the molluscicidal properties of Endod (*Phytolacca dodecandra*) increased potency with butanol extraction. *J Parasitol*.**58**: Pp104–107.
- LeChevallier M.W, Seidler R.J, Evans T.M (1980): Enumeration and characterization of standard plate count bacteria in chlorinated and raw water supplies. *Appl Environ Microbiol*; **40**: 922-930.
- Mc Gavin & Zachary, (2010): Acute Inflammation. In Pathologic Basis of Veterinary Disease, 4th Ed, Mark R. Ed.:Mosby. Elsevier publisher. Pp.: 10-62.

- Meles, B. (2008): Study on prevalence and socioeconomic impact of Equine Histoplasmosis in carthorses in Mekelle town. DVM thesis, Faculty of Veterinary Medicine, University of Mekelle, Ethiopia, .
- NMSA, (2003) : National Meteorological Service Agency, Addis Ababa, Ethiopia.
- Negase, M., Iyasu, M., Nigatu, A. and Gobene, A. (2012): Evaluation of barriers of *Phytolaca dodecandra* for groth inhibition of *Histoplasma capsulatum var. farciminosum* and treatment case of epizootic lymphangitis in Ethiopian.
- Nagoba.B, Selkar,Selkar, Wadher B,Genshir (2013): Acetic acid treatment of pseudomonal wound infection. A review infection. Public health. **6**: 410 - 415.
- OIE (2008): Terrestrial manual for epizootic lymphangitis. Paris: *Office International des Epizootics*. Pp. 852–857.
- OIE (2008): Manual of Standards for Diagnostic Test and Vaccines. Office International Des Epizooties. Paris, France, Pp. 852-857.
- OIE (2009): Update for epizootic lymphangitis. USA: Center for Food Security and Public Health (CFSPH), and Institute for International Cooperation in Animal Biologics, an OIE Collaborating Centre. Pp1–4.
- Pal M. (2004): Histoplasmosis; A fungal zoonosis. *Veterinary World*; **2**: 13-15.
- Pal M. (2007):Veterinary and Medical Mycology. First Edition
- Pal, M. (2008): Veterinary and Medical Mycology. First Edition, Indian Council of Agricultural Research, Krishi, **2007**: 108-110, 142-147
- Pal M, Hasegawa A, Ono K, Lee CW.(1990): A new staining solution for the morphological studies of fungi and *Prototheca*. *Jap J Vet Res* 1990; **52**: 527-531
- Pearson, R.A and Ouassat, M., (2000): A guide to Live Weight Estimation and Body condition scoring of donkeys. Centre for Tropical veterinary Medicine, University of Edinburgh, Sotland. J.Thomson color printers Ltd., Glasgow, Great Britain.pp.16.
- Plumb, D.C. (1999): Veterinary Drug Hand book third edition, Iowa state University, Minnesota, Pp 111-119, 365-336.
- Plunkett, J.J.(1949): Epizootic lymphangitis. *J. Army vet corps*, **20**:94-99.
- P.J Quinn, M. E. Carter, G.R.Carter and B Markey(2002): Clinical veterinary microbiology pp.32

- Radostits OM, Gay CC, Hinchcliff KW, (2007): Constable PD. Veterinary Medicine. 10th Edition, Bailliere Tindall, London, :PP 1478-1479.
- Raupricho, Matsushita M, Weijer C. (1996) : "periodic Phenomena in proteus swarming colony development. *J. bacteria* **178(22)**: 6525-38)
- Pascoe RR, De Kottebelt. (1999): Manual Equine dermatology Elsevier health science pp 109
- Salandra, G., Goffredo, E., Pedarra, C., Nardella, M., Parisi, A., Dambrosio, A., Quaglia, N., Celano, G. and Normanno, G. (2008): Occurrence, characterization and antimicrobial resistance pattern of *Staphylococcus species* isolated from dairy products in southern Italy. *International Journal of Food Microbiology*, **9**: 327-360
- Scantlebury CE<sup>1</sup>, Zerfu A<sup>2</sup>, Pinchbeck GP<sup>3</sup>, Reed K<sup>4</sup>, Gebreab F<sup>5</sup>, Aklilu N<sup>6</sup>, Mideksa K<sup>5</sup>, Christley R<sup>7</sup> (2015): Participatory appraisal of the impact of epizootic lymphangitis in Ethiopia.
- Schahab Quresh and Michael Stuart Bronze (2016) : klebsiela infection.
- Scott, D.W (1998): Large animal dermatology 1st edition W.B Saunders co., Philadelphia 120-121 and 133-134.
- Selim, S.A, Soliman R, Osman K, Padhye A.A, and Ajello L. (1985): Studies on histoplasmosis farciminosi (epizootic lymphangitis) in Egypt. Isolation of *Histoplasma farciminosum* from cases of histoplasmosis farciminosi in horses and its morphological characteristics. *Eur J Epidemiol*; **1**: 84-89.
- Singh, T. (1965): Studies on epizootic lymphangitis. I. Modes of infection and transmission of equine histoplasmosis (epizootic lymphangitis). *Indian J. Vet. Sci.*, **35**, 102–110
- Solomon H. (1980): Animal Health Review in Ethiopia (1972–1979). Addis Ababa Department of Veterinary Service Division, Ministry of Agriculture.
- Soliman, R., Saad M.A. and Refai M. (1985): Studies on histoplasmosis farciminosii (epizootic lymphangitis) in Egypt. III. Application of a skin test ('histofarcin') in the diagnosis of epizootic lymphangitis in horses. *Mykosen*, **28**, 457–461.
- SPANA Ethiopia. Consultant Document. The Horse Health and Welfare Project in Ethiopia (2006): Joint Project between SPANA and Addis Ababa University, Debre Zeit, Ethiopia, 1-20 (Unpublished).
- Stephanie L. (2014): Epizootic lymphangitis a working equids disease.

- Tobianse, Olofesson, Eile Butler, Christina Hindlon, Alejdra Vasquez. (2016): Fighting off wound pathogen in horse with honey bee lactic acid bacteria.
- Theoret C, Wilmink J (2012): Aberrant Wound healing in the horses naturally occurring conditions reminiscent .wound repair regime. **21**:365-371.
- Ueda, Y., Sano, A., Tamura, M., Inomata, T., Kamei, K., Yokoyama, A.K., Kishi F., Ito J., Y., Miyajim. & Nishimura K. (2003): Diagnosis of histoplasmosis by detection of the internal transcribed spacer region of fungal rRNA gene from a paraffin-embedded skin sample from a dog in Japan. *Vet. Microbiol.* **94**, Pp. 219–224.
- Weeks, R.J., Padhye, A.A. And Ajello, L. (1985): *Histoplasma capsulatum* variety *farciminosum*: a new combination for *Histoplasma farciminosum*. *Mycologia*; **77**: 964-970.
- Westgate SJ<sup>1</sup>, Percival SL, Knottenbelt DC, Clegg PD, Cochrane CA (2011): Microbiology of equine wounds evidence of bacterial biofilm.
- White, So; (2005): Equine bacterial and fungal diseases A diagnostic and therapeutic update *Tech equine pract*, 302-310
- Wilson, W (2001): Rational selection of antimicrobial for use in horse proceeding of the 47th Annual convention of American association equine practitioner pp 75-93.
- Woldeamanuel, Y., Abate, G. and Chryssanthou, E. (2005): In vitro activity of *Phytolacca dodecandra* (Endod) against *dermatophytes*. *Ethiop Med J.*; **43** (1):31–34.
- Young DF, Barr RJ (1981): *Aeromonas hydrophila* infection of the skin. *Arch Dermatol*; **117**:244.
- Yirga, G. (2010): Ethnobotanical study of medicinal plants in and around Alamata, Southern Tigray, Northern Ethiopia. *Curr Res J Biol Sci.*; **2** (5):338–344
- Zhang, W.T., Wang, Z.R., Liu, Y.P., Zhang, D.L., Liang, P.Q., Fang, Y.Z., Huang Y.J. and Gao, S.D. (1986): Attenuated vaccine against epizootic lymphangitis in horses. *Chinese J. Vet. Sci. Tech.*, **7**, 3–5.

## 8. ANNEXES

### Annex 1. Questionnaire

December /2017

#### **Questioner formats used to interview key Stake holders on Epizootic lymphagitis /'Nidifit'/ 'Biche'**

Date ..... Name..... Address.....Role.....

No	Questions	Responses	Remark
1	What is the effect of this d/s in term of animal welfare, income, performance	- performance 1) no changed 2) reduced 3) increased - income 1) increased 2) reduced 3) no changed - welfare 1) lost 2) no changed	
2	Do you use a horse infected with EzL infected horse to pulled cart? what do feel?	1) yes 2) no If yes 1) worried but no choice 2) nothing	
3	Where do you see severely affected horses that are abounded due to EzL affected horse? what is the consequence?	1) in fields and around river 2) villages and main road 3) all 1) car and humane accident 2) source of infection 3) contamination of evt, water and health issue 4) all	
4	Do you feel any smelling of Ezl infected horse?	1) yes bad foul 2) no	
5	What is your feeling when you look EL infected horse?	1) sadness 2) nothing	
6	If you have given with a chance to use either a healthy horse or EZL infected horse; which one do you prefer? why?	1) healthy one 2) affected one Why 1) it has bad smelling and weak to walk 2) health issue due to fly 3) for the welfare of horse 4) all	

## Annex 2 Media used for isolation and identification of fungus and bacteria

### ***1 Composition of SDA***

Ingredients	In gm/L
Dextrose (Glucose)	40 gm
Peptone	10 gm
Agar	15 gm
Distilled Water	1000 ml

Final pH 5.6 +/- 0.2 at 25°C.

In addition,

Sabouraud Dextrose Broth is the same formulation as above, without agar added.

Final pH 5.6 +/- 0.2 at 25°C.

Sabouraud Dextrose Agar with Chloramphenicol contains 50.0 mg of chloramphenicol.

Final pH 5.6 +/- 0.3 at 25°C.

Sabouraud Dextrose Agar with fortified procain penicillin  $6 \times 10^6$  international unit.

Final pH of 5.6 +/- 0.3 at 25°C were used.

### **Principle of SDA**

Peptone (Enzymatic Digest of Casein and Enzymatic Digest of Animal Tissue) provide the nitrogen and vitamin source required for organism growth in SDA. Dextrose is added as the energy and carbon source. Agar is the solidifying agent.

Chloramphenicol and/or tetracycline may be added as broad spectrum antimicrobials to inhibit the growth of a wide range of gram-positive and gram-negative bacteria.

Gentamicin is added to further inhibit the growth of gram-negative bacteria.

The neutral pH of the Emmons modification seems to enhance the growth of some pathogenic fungi, such as dermatophytes

1. This medium is also employed to determine microbial contamination in food, cosmetics, and clinical specimens.

2. Blood agar base (BBL<sup>®</sup>, Becton Dickinson, USA) Composition (g/l): Heart muscle, infusion from (solids) 2.0; pancreatic digest of casein 13.0; yeast extract 5.0; Sodium chloride 5.0; Agar 15.0.

Preparation: Suspend 40.0 gram of the powder in 1 liter of distilled water. Mix thoroughly. Heat with frequent agitation and boil for 1 minute to completely dissolve the powder. Autoclave at 121<sup>0</sup>C for 15 minutes. Cool the base to 45-50<sup>0</sup>C and add 5% sterile defibrinated blood.

3. MacConkey agar (Oxoid, Hampshire, England)

Composition (g/l): peptone 20.0; lactose 10.0; bile salts No. 3 1.5; Sodium chloride 5.0; neutral red 0.03; crystal violet 0.001; agar 15.0

Preparation: suspend 51.5g in 1 liter of distilled water. Bring to boil completely. Sterilize by autoclaving at 121<sup>0</sup>C for 15 minutes.

4. Mannitol salt agar (Difco, Detroit, USA)

Composition (g/l): proteose peptone No. 3 10.0; Bacto-beef extract 1.0; D- mannitol 10.0; Sodium chloride 75.0; Bacto-agar 15.0; phenol red 0.025.

Preparation: suspend 111 gram in 1 liter distilled water and heat to boiling to dissolve completely. Sterilize in the autoclave for 15 minutes at 15 pounds pressure (121<sup>0</sup>C). Cool to 45 – 45<sup>0</sup> C and dispense in to Petri dishes.

5. Nutrient agar (Oxoid, Hampshire, England)

Composition (g/l): “lab-lemco” powder 1.0; yeast extracts 2.0; peptone 5.0; sodium chloride 5.0; agar 15.0.

Preparation: Suspend 28 gram in 1 liter of distilled water. Bring to boil to dissolve completely. Sterilize by autoclaving at 121<sup>0</sup>C for 15 minutes

6. Edwards medium (modified)

A selective medium for the rapid isolation of Streptococcus

Typical Formula*	gm/litre
‘Lab-Lemco’ powder	10.0
Peptone	10.0
Aesculin	1.0

Sodium chloride	5.0
Crystal violet	0.0013
Thallos sulphate	0.33
Agar	15.0
pH 7.4 ± 0.2	

\* Adjusted as required to meet performance standards

POISON - Contains Thallium Salt

Directions

Suspend 41g in 1 litre of distilled water. Bring to the boil to dissolve completely. Sterilise by autoclaving at 115°C for 20 minutes. Cool to 50°C, add 5-7% of sterile bovine or sheep blood, mix well and pour plates.

Description

A selective medium for the rapid isolation of *Streptococcus*.

Crystal violet or gentian violet and thallium salts have long been used in selective media for streptococci

## 7. EOSIN METHYLENE BLUE AGAR (MODIFIED) LEVINE ( EMBA)

An isolation medium for the differentiation of the Ecloi

Typical Formula*	gm/litre
Peptone	10.0
Lactose	10.0
Dipotassium hydrogen phosphate	2.0
Eosin Y	0.4
Methylene blue	0.065
Agar	15.0
pH 6.8 ± 0.2	

\* Adjusted as required to meet performance standards

#### Directions

Suspend 37.5g in 1 litre of distilled water. Bring to the boil to dissolve completely. Sterilise by autoclaving at 121°C for 15 minutes. Cool to 60°C and shake the medium in order to oxidise the methylene blue (i.e. restore its blue colour) and to suspend the precipitate which is an essential part of the medium.

### 8. MACCONKEY AGAR

Isolation gram negative bacteria

Typical Formula*	gm/litre
Peptone	20.0
Lactose	10.0
Bile salts	5.0
Sodium chloride	5.0
Neutral red	0.075
Agar	12.0
pH 7.4 ± 0.2	

\*Adjusted as required to meet performance standards

#### Directions

Suspend 52g in 1 litre of distilled water. Bring to the boil to dissolve completely. Sterilise by autoclaving at 121°C for 15 minutes. Dry the surface of the gel before inoculation.

### 9. Uses of XLD Agar

XLD Agar is a selective differential medium for the isolation of Gram-negative enteric pathogens from fecal specimens and other clinical material.

Composition of XLD Agar

Lactose	7.5 gm
Sucrose	7.5 gm

Sodium Thiosulfate	6.8 gm
L-Lysine	5.0 gm
Sodium Chloride	5.0 gm
Xylose	3.75 gm
Yeast Extract	3.0 gm
Sodium Deoxycholate	2.5 gm
Ferric Ammonium Citrate	0.8 gm
Phenol Red	0.08 gm
Agar	15.0 gm

Final pH 7.4 +/- 0.2 at 25 degrees C.

#### Preparation of XLD Agar

1. Suspend 55 grams of dehydrated medium in 1000 ml purified or distilled water.
2. Heat with frequent agitation until the medium boils.
3. Transfer immediately to a water bath at 50°C.
4. After cooling, pour into sterile Petri plates.

*Note: It is advisable not to prepare large volumes, which will require prolonged heating and may produce precipitate.*

- Degradation of xylose, lactose and sucrose generates acid products, causing a color change in the medium from red to yellow.
- Lysine decarboxylation in the absence of lactose and sucrose fermentation causes reversion to an alkaline condition and the color of the medium changes back to red.

- Typical colonial morphology on XLD Agar are as follows:
  - Salmonella Typhi* – Red Colonies, Black Centers
  - Salmonella choleraesuis* – Red Colonies
  - Shigella sonnei* – Red Colonies
  - Shigella flexneri* – Red Colonies
  - Escherichia coli* – Large, Flat, Yellow Colonies; some strains may be inhibited
  - Proteus vulgaris* – Yellow Colonies
  - Enterobacter/ Klebsiella* – Mucoid, Yellow Colonies
  - Pseudomonas aeruginosa* – Pink, Flat, Rough Colonies
  - Gram-positive bacteria – No growth to slight growth



## Annex 4 Primary identification tests

### Gram's stain

(Carter, 1991)

1. Gram's reagent
  - Crystal violet
  - Gram's iodine (mordant)
  - Ethanol 95%
  - Counter – stain ( carbon fuchsine / safranin )

### **Procedure:**

From a fresh colony take a loop full of bacteria and emulsify it in a small drop of water or saline on the slide. This should be a thin, not milky, suspension or it will not stain properly.

Air dries the slide.

1. Fix the smear by passing on Bunsen burner
2. Pour crystal violet for 1 minute
3. Flood with tap water
4. Pour Gram's iodine (Mordant) for 1 minute
5. Flood with Tap water
6. Decolorize with 95% Ethanol alcohol for 5-10 seconds
7. Rinse with tap water
8. Pour safranin (counter stain) for 1 minute
9. Rinse with Tap water
10. Examine the slide under 100x oil immersion microscope

### **Interpretation**

Gram positive bacteria appear blue/ violet

Gram negative bacteria appear red/ pink

Annex 5 Types of medias and type of microbial

NO	Selected media were been used	Pyogenic and fungus agent
1	Sabouradus Dextrose Agar	For fungus
2	Nutrient Agar media	Less fastidious
3	MacConkey	Gram negative
4	Manitol salt agar	<i>Staphylococcus</i> <i>Aeromona isolates</i>
5	Blood agar	For fastidious and to check hemolysis
6	Edwards media agar	<i>Streptococcus isolates</i>
7	Eosin and ethylene blue (EMB) agar	<i>E coli</i>
8	Xylose, lactose H <sub>2</sub> S (XLD) Agar	<i>Klebssiella and Proteus</i>

( Quinn, 2002)

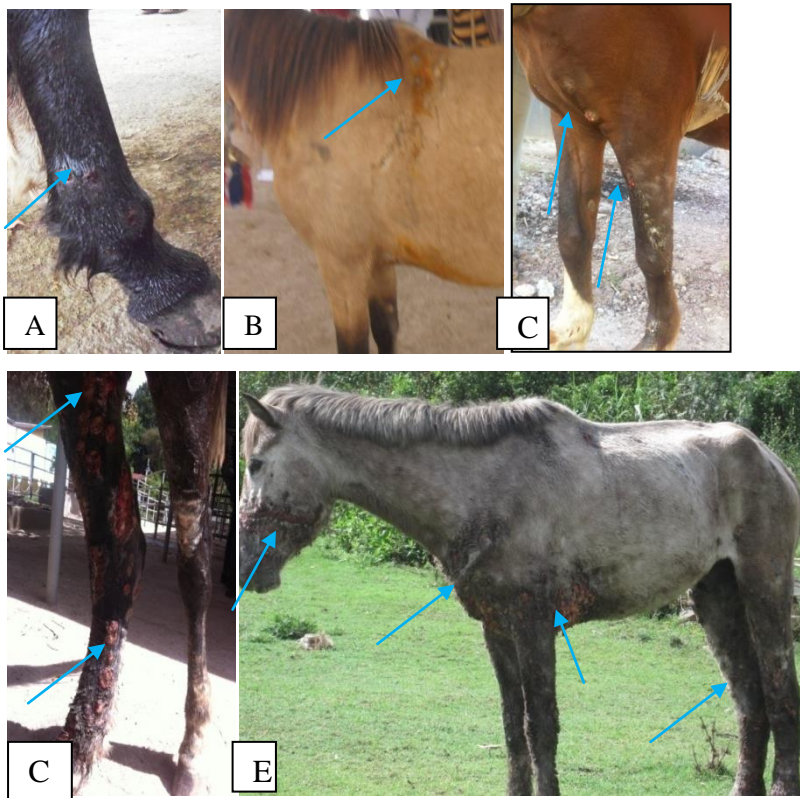
Annex 6 : colony characteristics of bacterial contaminants and HCF

Contaminants of EL lesion	Colony Characteristics of each contaminants on their selective media
<i>Staphylococcus</i>	Yellowish golden round smooth , glistening on MSA
<i>Streptococcus</i>	Translucent, mucoid colony on Eduward agar
<i>Micrococcus</i>	Shiny and white convex colony but often pigmented on nutrient agar
<i>Crynebacteria</i>	Small White dry non heamoltic colony on sheep blood agar
<i>Klebsiella</i>	Gray mucoid (pale to pink like mucous membrane on XLD
<i>Proteus</i>	Gray wavy swarming growth over agar ( due to cell growth), on blood agar brown colony and have foul smell but on MacConkey pale colony with irregular edge on blood agar.
Pseudomonas	Yellowish green, flat or gray, yellowish is due to pigment called pyoverdin on blood agar
Aeromonas	On agar plate their colony Smooth convex, rounded have Buffy colored and not disintegrated in fridge on MSA.
<i>E. coli</i>	Distinctive metallic sheen on EMB
HCF (fungus the causative agent of EL )	Dry , granular wrinkled/lined , cerebriform, convoluted grey-white colony and, dark brown( up on aging)

(Quinn, 2002)

Annex 7: Pictures of stages of EL cases

Early case with one ulcer and nodule on different body parts(A&B) , Moderate case with some nodules and ulcers and started cording (C), Sever case with many ulcers and nodules on leg (D) and Ulcers and nodules distributed and affect different body parts (E)





Animal Research Ethical Review Committee

*Ethical clearance certificate*

Certificate Ref. No: VM/ERC/02/01/09/2017

**Name of Applicant:** Kefyalew Mideksa (Animal Health Assistant, BSc in Applied biology, MSc fellow)

**Address:** SPANA, College of Veterinary Medicine and Agriculture, Addis Ababa University

**Title of the project:** Isolation and Identification of *Histoplasma capsulatum* var. *farinosum* and bacterial contaminants from infected horses and assessment of the effects of the disease in the community of Bishoftu and Akaki towns

Date of application: **30/12//2016**  
Nature of the project: **Non-invasive, with questionnaire survey**  
Target animal species: **Horses**  
Number of animals involved: **72**  
Study area: **Bishoftu and Akaki, Ethiopia**

Minutes No. and date of review: **VM/ERC/01/09/017, 03/03/2017**

The above indicated research project is acceptable from ethical perspective, relevance, originality and technical competence points of view. Hence the project is allowed to be executed provided that:

1. All procedures and conditions stipulated in the proposal are respected and any deviation or changes be reported to the committee
2. The project activities be open for occasional supervision by the committee whenever this is deemed necessary

Dr Getachew Terefe  
Chairman

Dr. Dinka A  
Dean  
College of Veterinary Medicine  
and Agriculture



መልሱን በግጽፋልን ጊዜ ባክዎን የ ኛን ደብዳቤ ቁጥር ያስጠብቁ  
Please quote Our Ref. No. When replying

ፋክስ }  
Fax 251-11-4339933

ስልክ }  
Tel. +251 114338450

ፖ.ሣ.ቁ }  
P.o.x. Box}34

ቢሾፍቱ/ደብረዘይት፣ ኢትዮጵያ  
Bishoftu/Debre Zeit, Ethiopia