

**ADDIS ABABA UNIVERSITY**  
**COLLEGE OF VETERINARY MEDICINE AND AGRICULTURE**  
**DEPARTEMENT OF CLINICAL STUDIES**



**CLINICAL CASE STUDIES ON MAJOR DISEASES OF VETERINARY IMPORTANCE**  
**IN BISHOFTU TOWN, ETHIOPIA**  
**MVSc THESIS**

**By**  
**ABDI FEYISA**

**JUNE 2018**  
**BISHOFTU, ETHIOPIA**

## TABLE OF CONTENTS

CONTENTS	PAGES
ACKNOWLEDGMENTS .....	IV
LISTS OF TABLES .....	V
LISTS OF FIGURES .....	VI
LISTS OF ANNEXES.....	VIII
LISTS OF ABBRIVIATIONS.....	IX
ABSTRACT.....	X
1. INTRODUCTION .....	1
2. MATERIALS AND METHODS.....	3
2.1. Study area and study animals.....	3
2.2. Study Design and case handling protocols .....	3
3. REFERENCES.....	5
4. COMPILED CASES.....	7
4.1. Case reports on bovine .....	8
4.1.1. Cutaneous bovine papillomatosis (warts) treatment with ivermectin: A case of crossbred heifer and calf .....	8
4.1.2. Lumpy skin disease treatment outcome in a bull.....	15
4.1.3. Colibacillosis in a calf.....	22
4.1.4. Laryngeal necrobacillosis and its treatment in calf and cow .....	29
4.1.5. <i>Escherichia coli</i> caused clinical mastitis in a late pregnant cow .....	34
4.1.6. Hemorrhagic septicemia and its treatment outcome in a bull.....	42
4.1.7. Black leg in a bull: Symptomatic therapy.....	50
4.1.8. Unidentified hemoglobinuria in a bull.....	56
4.2. Case reports on ovine .....	62
4.2.1. Coccidiosis in a lamb.....	62
4.2.2. Dysentery in a ram caused by <i>Escherichia coli</i> .....	67
4.2.3. Mannheimiosis (pneumonic pasteurolosis) in a ewe .....	75
4.2.4. Clinical hypocalcaemia/milk fever in a late pregnant ewe and a lactating Cow ...	80
4.2.5. Hemonchosis: A case of four sheep.....	88

4.2.6. Urolithiasis with hematuria in a ram.....	95
<b>4.3. Case reports on caprine.....</b>	<b>100</b>
4.3.1. Treatment outcome of goat pox: A case of four goats.....	100
4.3.2. Listeriosis in a kid/young goat.....	106
<b>4.4. Case reports on canine .....</b>	<b>112</b>
4.4.1. Parvovirus infection in a puppy .....	112
4.4.2. Management of aural hematoma in a dog.....	118
<b>4.5. Case report on equine.....</b>	<b>124</b>
4.5.1. Therapeutic management of tetanus in a cart horse.....	124
<b>5. CONCLUSIONS AND RECOMMENDATIONS .....</b>	<b>132</b>
<b>ANNEXES .....</b>	<b>133</b>

## **ACKNOWLEDGMENTS**

Firstly, I praise and thank my almighty and most high God for his every time protections that enable me to accomplish this paper without any troubles.

My special and sincere gratitude goes to my advisor Prof. Fekadu Regassa for his supervision, advice, and guidance and devotion of his time to comment this thesis. In addition, I would like to extend my deepest gratitude to Dr. Fufa Abunna for his guidance during this work. Finally, I am grateful to others who are involved directly or indirectly in this work.

## **LISTS OF TABLES**

<b>Table 1:</b> Total number of animals examined and treatment outcome.....	7
<b>Table 2:</b> Diseases encountered during the study in percentage .....	7

## LISTS OF FIGURES

<b>Figure 1:</b> Bovine cutaneous papillomatosis covering the faces of heifer (A-C) and calf (D) .....	10
<b>Figure 2:</b> Recovered from cutaneous papillomatosis two months post-administration of ivermectin .....	11
<b>Figure 3:</b> First day visit at VTH with lumpy skin nodular lesions .....	17
<b>Figure 4:</b> Indicates the bull recovered (three months later) .....	18
<b>Figure 5:</b> A calf with bloody diarrhea (the arrow).....	24
<b>Figure 6:</b> Status of the calf on the 5 <sup>th</sup> day of therapy.....	25
<b>Figure 7</b> Cow with salivation and lacrimation (A, arrows) and the calf with open mouth breathing (B).....	31
<b>Figure 8:</b> Cow's recovering post treatment A (after the 3 <sup>rd</sup> therapy) and B (after the 6th day therapy).....	32
<b>Figure 9:</b> Indicates affected quarters (A&B) and clotty milk(C) from the affected teat .....	36
<b>Figure 10:</b> Picture representing clinical case of HS with edema at different area of the neck (a, b& c, arrows) and unilateral nasal discharge (d, arrow).....	44
<b>Figure 11:</b> Comparative picture specifying the bull during 1 <sup>st</sup> day visit (A, arrows) and 5 <sup>th</sup> day visit (B, arrows) .....	45
<b>Figure 12:</b> Congestion and lacrimation.....	52
<b>Figure 13:</b> The status of the bull on the 5th day .....	53
<b>Figure 14:</b> indicating bloody urine .....	58
<b>Figure 15:</b> representing bloody urine (A, before centrifuged), after centrifuged (B) and Giemsa stained blood smear(C) .....	59
<b>Figure 16:</b> Emericia oocytes under microscope: magnified: X 40 .....	64
<b>Figure 17:</b> Represents first day clinic visit; lethargic (A) and with dysentery (B).....	69
<b>Figure 18:</b> IV Lactated Ringer's solution institution .....	70
<b>Figure 19:</b> Comparative picture indicating the ram during the 1 <sup>st</sup> (B arrow), the 3 <sup>rd</sup> (A, arrow) and 5 <sup>th</sup> day visit (recovered, C).....	71
<b>Figure 20:</b> Indicating clinical picture of Pasteurellosis .....	77
<b>Figure 21:</b> A recumbent cow with hypocalcaemia and mammary-vein calcium-boroglucoante institution (the arrow) .....	82

<b>Figure 22:</b> Pregnant ewe with hypocalcaemia during presentation .....	83
<b>Figure 23:</b> After calcium borogluconate administration, ewe (A) and cow (B).....	84
<b>Figure 24:</b> Representing sheep with edema under the jaw .....	90
<b>Figure 25:</b> Thin shelled, embroynated and oval shaped eggs of strongyle observed under microscope: magnified: X 40.....	91
<b>Figure 26:</b> Congested mucus membrane of the ram (A) and urine by cystocentesis (B) and sediment upon centrifugation (C) .....	97
<b>Figure 27:</b> Stream of bloody urine following urethral process amputation (the arrow).....	98
<b>Figure 28:</b> Status of the ram 48 hour's post-treatment and normal urine output (the arrow).....	98
<b>Figure29:</b> Designating pox lesion on different body of goats .....	102
<b>Figure 30:</b> Two months post-treatment recovery from goat pox .....	103
<b>Figure 31:</b> Indicating circling movement in kid .....	108
<b>Figure 32:</b> Indicating a puppy with bloody diarrhea .....	114
<b>Figure 33:</b> Indicating intravenous rehydration .....	115
<b>Figure 34:</b> A dog with aural hematoma on the left ear (the arrow) .....	119
<b>Figure 35:</b> Longitudinal incision on the concave side of pinna and drainage of hemorrhage....	120
<b>Figure 36:</b> Flushing of the cavity with saline solution .....	120
<b>Figure 37:</b> Interrupted suture made parallel to the major vessels.....	121
<b>Figure 38:</b> The incised ear bandaged .....	121
<b>Figure 39:</b> A month after treatment the affected ear was healed without recurrence (the arrow) .....	122
<b>Figure:40</b> A tetanus case of horse with drooling of saliva (A); stiffen neck and locked jaw(C), and stiffen tail (B). .....	127
<b>Figure 41:</b> The condition of the horse on 14 <sup>th</sup> day visit (post-treatment).....	128

## **LISTS OF ANNEXES**

<b>Annex 1:</b> Clinical Case Handling Protocol .....	133
<b>Annex 2:</b> Clinical Examination Protocols.....	134
<b>Annex 3:</b> Clinical Case Recording Form .....	137
<b>Annex 4:</b> Positive PCR Result of the Lumpy Skin Disease Suspected Bull.....	138
<b>Annex 5:</b> Laboratory works (bacteriology).....	139

## LISTS OF ABBRIVIATIONS

AAU	Addis Ababa University
ACP	Acepromazine
AH	Aural Hematoma
BPV	Bovine Papilloma Virus
CPV	Canine Parvovirus
CVMA	College of Veterinary Medicine and Agriculture
GABA	Gamma Aminobutyric Acid
GTPV	<i>Goatpox virus</i>
HS	Hemorrhagic Septicemia
IVF	Intravenous Fluid
IVM	Ivermectin
LSD	Lumpy Skin Disease
LSDV	Lumpy Skin Disease Virus
PBS	Phosphate Buffer Saline
PCR	Polymerase Chain Reaction
PCV	Packed Cell Volume
TAT	Tetanus Antitoxin
VTH	Veterinary Teaching Hospital

## **ABSTRACT**

Livestock is the pillar of the livelihood of the majority of Ethiopians, however, profitability of the sector is hindered by multifaceted constraints, of which livestock diseases are the major contributing factors. The current case studies described clinical cases of various diseases and their management in different species of animals brought to Veterinary Teaching Hospital and SPANA, Ethiopia animal health facilities of Addis Ababa University, College of Veterinary Medicine from Bishoftu and its vicinity. Young and adult animals of different species, physiological stages and sexes were examined from November 2017 to June 2018. The examination method involves owner complaint and detail clinical examinations. Animals were treated vigorously based on tentative diagnosis using broad-spectrum antimicrobials and supportive drugs based on the manufacturer instructions. Simultaneously, samples from the individual animals examined tentatively were collected and processed following appropriate laboratory procedures to reach on definitive diagnosis. The cases were then followed until the animal recovered either in the clinic during the successive therapies or at home for the diseases with prolonged recovery. A total of 28 animals were examined of which 89.3% (25/28) were ruminants while 10.7% (3/28) were equine and canine. Among these, 35.7 % (10/28), 28.6 % (8/28), 17.9 % (5/28), 10.7% (3/28), 7.1% (2/28), of the diseases were caused by bacteria, virus, parasites, miscellaneous, and metabolic, respectively based on clinical pictures and laboratory results. Among the treated animals 82.1 % (23/28) were recovered, 14.3 % (4/28) (two goats, one sheep, and one calf) died and one bull was refractory. Therefore, this study showed bacteria's and viruses were the most common disease causing agents followed by parasites. In general, highest proportions of animal diseases could be cured if appropriate management and rational drug use applied on time and appropriately. Based on this finding, training of animal health workers, construction of inpatient facility and installing advanced diagnostic tools were recommended to facilitate the routine animal health care works and reduce the losses of diseases.

**Keywords:** *Case description; Case management; Treatment outcome*

## **1. INTRODUCTION**

Livestock sector supports the livelihoods of a large proportion of rural households in most African countries and it is believed to play a paramount role in rural poverty reduction strategies (Gelan et al., 2012). Ethiopia has the largest livestock population in Africa with approximately 58 million cattle, 54 million goats and sheep, plus a collection of horses, donkeys, camels and chickens (CSA, 2016). Livestock is the pillar of the livelihood of the majority of Ethiopians; providing draught power for crop production, source of meat and milk, and source of cash income for farmers. Furthermore, livestock provides foreign currency to the national and considerably contributes to national GDP (Megersa et al., 2009; Gelan et al., 2012; Ayele et al., 2015). However, profitability of the sub-sector is hindered by multifaceted constraints, of which livestock diseases are the major contributing factors (Ayele et al., 2015). The widespread prevalence of a wide range of diseases and parasites in all agro ecological zones of the country causes direct economic losses through high mortality of animals and contributes to the poor productive and reproductive performance of the animals. The annual mortality of livestock is estimated at 8-10%, 14-16% and 11-13%, for cattle, sheep and goats respectively (Asresie and Zemedu, 2015). Various bacterial, viral, protozoal, endoparasites and ectoparasites are frequently encountered livestock diseases all over the country and accounts for the momentous economic losses (UNDP, 1994; Abdeta et al., 2015). Consequences are also devastating at national level since the presence of the diseases has triggered strict trade embargo amounting to be hundreds of millions of birr losses annually.

Diseases can be infectious or non-infectious; pathogens like Viruses, Protozoa, Parasites, Bacteria, and Fungi are principal agents among infectious while non-agent caused diseases are non-infectious (Jana and Ghosh, 2013). A retrospective study conducted at university of Gondar veterinary clinic determine that among 1966 (during 2007 to 2009) farm animals admitted to the clinic, more than 75% were affected by bacterial, parasitic and viral diseases while metabolic diseases account only 4.2% (Alemu and Zegeye, 2011). Among viral diseases affecting the livestock sector of the country, Foot-and-mouth disease, Capri pox virus diseases (Sheep pox, goat pox and Lumpy skin disease), PPR (Peste de petits ruminants), Contagious Ecthyma, AHS (African Horse Sickness) and rabies are more frequent while Anthrax, blackleg, CBPP

(Contagious bovine pleuropneumonia), CCPP (contagious caprine pleuropneumonia) pastuerellosis, IBK (Infectious Bovine Keratitis), Brucellosis, clinical mastitis, dermatophilosis, actinobacillosis, actinomycosis, foot rot and abscess are among consistently reportable bacterial diseases (UNDP, 1994). Asmare et al, (2016) report strengthen evidence of the occurrence of numerous gastro-intestinal tract (GIT) parasites in livestock and the resulting impact on production and productivity in Ethiopia. Though erratic, tick born hemoparasitic diseases such as Babesiosis, Theileriosis, Anaplasmosis and cowdriosis (heart water) existence has been reported in different regions of the country (Nejash, 2016).

Despite a number of diseases affecting productivity of the livestock sector, 40% of the national economy are still tuned on livestock agriculture; however potential and productivity of the sector stays disproportional (Asresie and Zemedu, 2015). Although most of these diseases are curable and manageable, the proceeding interventions are not in line with the standard protocols. Besides, knowing the type and extent of common animal diseases are very crucial to veterinarians in the development of herd health strategies and the selection of possible treatments.

Therefore, the objective of this case study was to study major veterinary importance diseases brought to animal health care facilities of Addis Ababa University, College of Veterinary Medicine and Agriculture from Bishoftu and its vicinity. In addition, each case were treated and followed to investigate the treatment outcome.

## **2. MATERIALS AND METHODS**

### **2.1. Study area and study animals**

This case study was conducted at VTH and SPANA animal health facilities of Addis Ababa University College of Veterinary Medicine, Bishoftu from November 2017 to June 2018. Animals brought from Bishoftu town and its surrounding peasant associations were targeted in this study. Bishoftu town is located in East shewa zone of the Oromia region, 47.9 km to south east of Addis Ababa. It is located at latitude and longitude of 10° 35' 0" N and 35° 48' 0" E respectively. The area lies at an altitude of 1850 meter above sea level and experiences the mean annual rainfall, maximum and monthly temperatures ranges between 801.3mm, 25.5 0 C, 23.7 in July & 27.70 C in May, respectively. Moreover Bishoftu and its surrounding have variable and yet representative agro-ecologies of the country. These agro-climatic zones are inhabited with different plant (flora) and animal species (fauna). Cattle, small ruminant, poultry and equines are the major livestock species reared in Bishoftu. Most of the animals in the town are kept intensively while the animals in the rural areas were kept semi-intensively. In this area, 'Frushka', house hold remnants and straw are regular feed of the animals kept intensively while semi-intensively kept animals grazes on communal grazing land in addition.

### **2.2. Study Design and case handling protocols**

Descriptive type of case study designs were executed with the purpose of identifying and organizing case reports of animals admitted to AAU CVMA animal handling facilities. These were attained through implementation of thorough clinical case handling protocols (Annex 1). The examinations of individuals or groups of animals admitted to the facilities were begin with owner complaint and followed by performing a complete clinical examination which includes a broad search for abnormalities starting from head to tail (Annex 2). In addition, the organs or systems involved, location and type of lesion present, and the severity of the diseases were identified thoroughly (Jackson and Cockcroft, 2002; Jana and Ghosh, 2013). Based on the information obtained during the clinical examination and owner complaint, tentative diagnoses of the cases were asserted. In certain cases illustrative samples from the affected individuals were

collected and appropriate laboratory procedures were done (each laboratory procedures were discussed under the respective cases). The cases were then treated and thoroughly monitored until recovered either in the clinic during the successive therapies or at home for the diseases with prolonged recovery. The information for all the cases was first obtained using standard case recording format (Annex 3). Finally, each case was compiled using case report compilation format. This encompasses summary, introduction, case description, laboratory investigations and findings, case management and treatment outcome and discussion for each cases. Each case was supported with picture of the animals during presentation and after recovery.

### 3. REFERENCES

- Abdeta D., Zenebe T., Fikirte L., Negessu D., Hirpha E. (2015): Retrospective Survey on Major Cattle Diseases in Guto Gida woreda, Eastern Wollega, Nekemte, Ethiopia. *Science, Technology and Arts Research Journal*, **4**: 120-123.
- Alemu S., Zegeye B. (2011): Occurrence and Associated Risk Factors of Clinical Diseases of Farm Animals Presented to Gondar University Veterinary Clinic. *American-Eurasian Journal of Agriculture & Environmental Science* **11** : 237-241.
- Asmare K., Sheferaw D., Aragaw K., Abera M., Sibhat B., Haile A., Kiara H., Szonyi B., Skjerve E., Wieland B. (2016): Gastrointestinal nematode infection in small ruminants in Ethiopia: A systematic review and meta-analysis. *Acta Tropica*, **160**: 68-77.
- Asresie A., Zemedu C. (2015): Contribution of Livestock sector in Ethiopian Economy:A Review. *Advanced Life Science and Technology*, **29**.
- Ayele B., Tigre W., Deresa B. (2015): Investigation of major cattle production constraints in Kembata Tambaro zone of Southern Ethiopia using participatory epidemiology methods. *Tropical Animal Health and Production* .
- Constable P., Hinchcliff K., Done S., Grundberg W. (2017): *Veterinary Medicine: A Textbook of the Diseases of Cattle, Horses, Sheep, Pigs, and Goats*. UK: Elsevier . 1591 p.
- CSA (2016): Central Statistical Agency. Federal Democratic Republic of Ethiopia, Agricultural Sample Survey. Addis Ababa, Ethiopia.
- Gelan A., Engida E., Caria A., Karugia J. (2012): The Role of Livestock In the Ethiopian Economy: Policy Analysis Using A Dynamic Computable General Equilibrium Model for Ethiopia.
- Jackson P. G. Cockcroft, P. D. (2002): *Clinical Examination of Farm Animals*. UK: Blackwell Science. 322 p.
- Jana D. Ghosh N. (2013): *Essentials of Veterinary Practice*. Delhi: Daya Publishing House; A Division Of Astral International (P) Ltd. 508 p.
- Megersa B., Beyene B., Abunna F., Regassa A., Amenu K., Rufael T. (2009): Risk factors for foot and mouth disease seroprevalence in indigenous cattle in Southern Ethiopia: the effect of production system. *Tropical Animal Health and Production*, **41**: 891-898.

Nejash A. (2016): Review of Important Cattle Tick and Its Control in Ethiopia. *Open access library journal*, **3**: e2456.

UNDP (1994): United Nation Development Program. Technical report: Rough guide to animal disease in Ethiopia.

#### 4. COMPILED CASES

A total of 19 cases comprised of 28 total animals were compiled in these case reports (table 1)

**Table1:** Total number of animals examined and treatment outcome

<b>Animals</b>	<b>Total</b>	<b>Recovered</b>	<b>Died</b>	<b>Refractory</b>
Ruminants	25	20	4	1
Equine	1	1	0	0
Canine	2	2	0	0
Total (in percentage)	28	23(82.1%)	4 (14.3%)	1(3.6%)

**Table 2:** Diseases encountered during the study in percentage

<b>Diseases</b>	<b>Number of affected animals</b>	<b>Percentages (%)</b>
Bacteria	10	35.7
Virus	8	28.6
Parasites	5	17.9
Metabolic	2	7.1
Surgical cases	3	10.7

## 4.1. Case reports on bovine

### 4.1.1. Cutaneous bovine papillomatosis (warts) treatment with ivermectin: A case of crossbred heifer and calf

#### Abstract

Cutaneous bovine papillomatosis is a contagious neoplastic viral disease of animals characterized by the presence of multiple skin tumors or growths particularly, on head and neck areas. Although it regresses spontaneously, some cases may take a prolonged period and/or extended to malignant form. This case report summarizes the treatment of cutaneous bovine papillomatosis using ivermectin. A crossbred heifer of around one year and calf of around 4-month old were examined with abundant and various sizes of warts principally on their faces. Based on the history and clinical pictures, the cases were diagnosed as bovine cutaneous papillomatosis. The animals were treated with double shot ivermectin (with two week interval) at a dose of 0.2mg/kg bodyweight, subcutaneously. Warts regression and sloughing with prompt healing was observed following two months follow-up. Therefore, ivermectin can be used as a treatment of choice for bovine papillomatosis.

**Keywords:** *Ivermectin; Cutaneous papillomatosis*

#### Introduction

Bovine papillomatosis is an infectious, contagious and neoplastic disease, characterized by the presence of multiple benign tumors (papillomas) that can regress spontaneously or progress to malignant neoplasms (Araldi *et al.*, 2016). It is instigated by oncogenic Bovine papillomaviruses (BPV) which are non-enveloped, icosahedral viruses, 50–55 nm in diameter, with a circular, double-stranded DNA genome, ranging from 7.4 to 8.6 kb. The viruses have a tropism to both cutaneous and mucosal epithelia of cattle and water buffalo. There are 13 types of BPV reported so far (Erdelyi *et al.*, 2009; Batista *et al.*, 2013; Araldi *et al.*, 2015); they are strictly species-specific except the infection of horses and other equids by BPV type 1 (BPV-1) or BPV type-2 (BPV-2) (Borzachiello and Roperto, 2008). BPV can be found worldwide, and its dispersion can

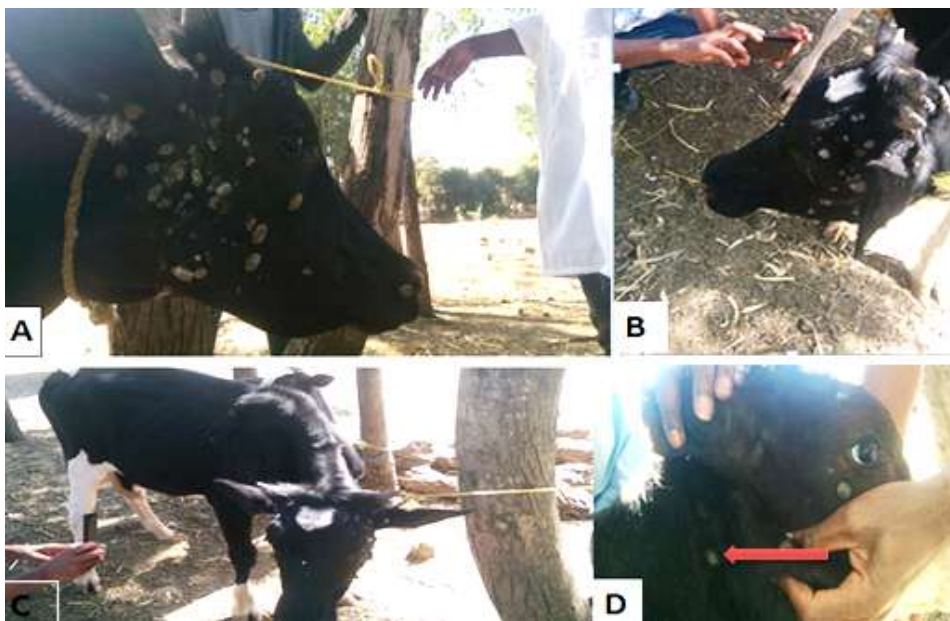
occur via direct or indirect contact between infected animals or through contact with contaminated areas, such as milking machines, water dispensers, feeders, ropes or fences, or transmitted by insects (Araldi *et al.*, 2015). It can be exhibited as benign nodular lesions, finger-like projections or cauliflower-like small growths on the skin arising from stratified squamous epithelium that may appear solitary or in multiples. The common sites for the development of cutaneous warts are head, eyelids, ears, neck, dewlap, brisket, shoulders and legs, occasionally on the back, para-genital region and along the lower line of the abdomen (Jana and Mukherjee, 2013). Although the papillomas regress as a result of a cell-mediated immune response, in some animals they may succumb to widespread cutaneous or mucosal involvement and further, it results in cancers which are problematic and of economic significance (Nasir and Campo, 2013).

Different treatment options were tried in clinically affirmative cases of cutaneous warts (Jana, 2015). Autohemotherapy or self-blood therapy alone and along with Levamisole brought about 90% and 100% recovery after fourth administration, respectively. Levamisole at a dose of 2.5 mg/kg/day on days 1, 3, 5, 7, 9 and 16, by oral and parenteral route obtained 82% and 88% recovery, respectively. A Single shot subcutaneous administration of Ivermectin resulted in complete recovery in 70% cases and 86.67% was achieved in double shot. Similarly, the current case report describes successful treatment of cutaneous bovine papillomatosis using ivermectin in two cattle.

#### Case description

A crossbred heifer of around one year and calf of around 4-months old were examined at Gerbicha peasant association, Ada'a in one of smallholder dairy farm on November 11, 2017. The major complaint of the owner was the appearance of growths on the face and other body parts of the heifer which has been elapsed four months. The heifer was brought to Addis Ababa College Veterinary Medicine, Veterinary Teaching Hospital, Bishoftu, and treated with an unknown drug but not responded. After few months the same condition was started to erode on the body of the calf. The animals were managed intensively. Upon physical examinations; the temperature, heart rate, and respiratory rate were within the normal range. There were wart like multiple nodular lesions on the faces of the heifer (figure 1A & 1B) and calf (figure 1D); in

addition, a few but similar lesions were also seen on the neck and other body parts of the patients (Figure 1D). The lesions were small to large in size and active lesions started to explode. Based on the history and typical clinical findings it has been concluded tentatively as Bovine cutaneous papillomatosis or wart.



**Figure 1:** Bovine cutaneous papillomatosis covering the faces of heifer (A-C) and calf (D)

#### Case management and treatment outcome

Both patients were treated with double shot ivermectin (with two weeks interval) at a dose of 0.2mg/kg (Sheyang Sunvictotor Pharmaceutical Co., Ltd. /China) body weight subcutaneously. Two months post-treatment, both cases were fully recovered (Figure 2).



**Figure 2:** Recovered from cutaneous papillomatosis two months post-administration of ivermectin

## Discussions

The present cases of a heifer and calf was diagnosed as cutaneous bovine papillomatosis based on the typical clinical picture and the contagiousness nature of the disease. Most types of bovine papillomavirus cause cutaneous form of papillomatosis (BPV1-3 and BPV5-10), whereas BPV4 causes tumors of the upper gastrointestinal tract in animals feeding bracken fern (Nasir and Campo, 2008). BPV1 and BPV2 (genus delta) predominantly infect the fibroblasts of the underlying dermis and cause fibropapillomas of the skin, teats and udders and urinary bladder cancer in the cattle fed bracken fern (Nasir and Campo, 2013). The benign lesions generally regress as a result of a cellular immune response, which appears to protect against re-infection with that type but may also occasionally persist, leading to a high risk of evolving into cancer or even widely spread, particularly in the presence of environmental carcinogenic co-factors. In addition, BPV may persist as latent infection and become reactivated by immunosuppression and/or physical trauma. Accordingly the furtherance may necessitate culling or slaughtering of the animal which is problematic and of economic significance (through interfering with animal sales) (Salib and Farghali, 2011). Similarly, the animals in the present study had multiple wart lesions without any sign of regression for months and spread to other animals (calf). Hence, it necessitates intervention.

Ivermectin is a macrolide family antiparasitic drug isolated in 1979 from a filamentous bacterium called *Streptomyces avermitilis* which selectively kills nematodes at a very low dose (0.2 mg/kg) by inhibiting their gamma-aminobutyric acid (GABA) receptor, but not mammalian counterpart. Although anti-cancer mechanism of ivermectin is yet not clear, reports has been indicated its effectiveness against cancer both in animals and humans (Borku *et al.*, 2007; Hashimoto *et al.*, 2009; Jana, 2015; Jana and Mukherjee, 2013). According to the reports regression or healing of warts could have occurred due to immune modulatory and antitumor effect of Ivermectin.

Previously, autogenous vaccine, wart enucleation, burning with hot iron or eraser, ligation and surgical removal of wart (excision) with a surgical knife, application of salicyclic acid ointment, and other treatment options has been used for bovine papillomatosis remedial but this cannot bring favorable results alone. Autohemotherapy of the affected calves was also tried (Pattanayak, 2004). Although it needs prolonged therapy, Levamisole has also promising therapeutic effect (Jana, 2015). In the current study however, both the cases were treated successfully with double shot ivermectin subcutaneously (at 1ml/50 kg body weight with two-week interval) with remarkable recovery two months post-treatment; which is in accordance with Borku *et al.* (2007), Jana (2015) and Puvarajan *et al.* (2016) reports in which complete recovery without reemission was indicated. Therefore, the current finding advocates that ivermectin is effective drug, easily available and shows recovery relatively within short periods.

In conclusion, cutaneous papillomatosis is a contagious disease of bovine characterized by wart lesion on the skin of the animals, in particular. Although it appears regress spontaneously, some cases may take a prolonged period and/or extended to malignant form. Hence, immediate intervention with effective and available ivermectin can reduce the economic loss due to culling or slaughtering.

#### Acknowledgement

I am grateful to Mr. Dereje Gudeta for his contribution and the owner of the animal for his valuable information during the follow up.

## References

- Araldi R., Assaf S., Carvalho R., Caldas M., Carvalho R., Souza J., Magnelli R., Grando D., Roperto F., Stocco R., Becak W. (2016): Papillomaviruses: a systematic review. *Genetics and Molecular Biology* 1-22.
- Araldi R., Melo T., Neves A., Spadacci-Morena D., Mngnelli D., Modolo D., Junior P., Souza J., Carvalho R., Becak W., Stocco R. (2015): Hyperproliferative action of bovine papillomavirus: genetic and histopathological aspects. *Genetics and Molecular Research*, **14**: 12942-12954.
- Batista M., Silva M., Pontes N., Reis M., Corteggio A., Castro R., Borzacchiello G., Balbino V., Freitas A.(2013): Molecular epidemiology of bovine papillomatosis and the identification of a putative new virus type in Brazilian cattle. *The Veterinary Journal*, **197**: 368-373.
- Borku M., Atalay O., Kibar M., Cam Y., Atasever A. (2007): Ivermectin is an effective treatment for bovine cutaneous papillomatosis. *Research in Veterinary Science*, **83**: 360-363.
- Borzachiello G., Roperto F. (2008): *Bovine papillomaviruses*, papillomas and cancer in cattle. *Veterinary Research*, **39**: 45.
- Erdelyi, K., Gal, J., Sugar , L., Ursu, K., Forgrach, P., Szeredi, L., and teineck, T. (7-1-2009): Papillomavirus-associated fibropapillomas of red deer (*Cervus Elaphus*). 344 p.
- Hashimoto H., Messerli S., Sudo T., Maruta H. (2009): Ivermectin inactivates the kinase PAK1 and blocks the PAK1-dependent growth of human ovarian cancer and NF2 tumor cell lines. *Drugs and Discovery Theriogeniology*, **3**: 243-246.
- Jana, D. (2015): Studies on bovine and bubaline papillomatosis with special reference to its epidemiology, clinicopathology and therapeutics [dissertation]. University of Kalayani. 9 p.
- Jana D., Mukherjee S. (2013): Therapeutic Management of Bovine Cutaneous Papillomatosis With Ivermectin in Farm Bredcalf Crops of West Bengal, India. *Explore Animal Medicine Research*, **3**: 123-130.
- Nasir L., Campo S. (2013): Bovine papillomaviruses: their role in the aetiology of cutaneous tumours of bovids and equids. *Explore Animal Reaserch and Medicine* **3**: 123-130.

- Pattanayak S. (2004): Autohaemotherapy in Bovine Papillomatosis. *Intas polivet*, **5**: 16-17.
- Puvarajan B., Umarani R., Kathiresan D. (2016): Evaluating Therapeutic Use of Ivermectin for Management of Bovine Cutaneous Papillomatosis-A Clinical Study in 35 Crossbred cattle.
- Salib F., Farghali H. (2011): Clinical, epidemiological and therapeutic studies on Bovine Papillomatosis in Northern Oases, Egypt in 2008. *Veterinary World*, **4**: 53-59.

#### 4.1.2. Lumpy skin disease treatment outcome in a bull

##### Abstract

Lumpy skin disease (LSD) is a disease responsible for huge economic losses in the cattle producing industries, particularly in Africa. A local breed bull with nodular eruptions on different body parts was examined at Addis Ababa University College of Veterinary Medicine, Veterinary Teaching Hospital, Bishoftu, on November 29, 2017. The bull was febrile with a rectal body temperature of 40.4 °C and had a flare-up of small to large sized circumscribed nodules on different body parts and the neck area in particular. Besides, there was lameness, swelling of both prescapular and prefemoral lymph nodes. Based on the history, clinical findings and PCR result the case was confirmed as lumpy skin disease caused by lumpy skin diseases virus (LSDV). The case was managed vigorously with short-acting oxytetracycline (10mg/kg/day, IM) for five consecutive days and dexamethasone (0.2mg/kg/day, IM) for three successive days. The bull was fully recovered three months post-treatment and sold. Hence, opportune treatment of LSD with anti-biotic and anti-inflammatory drugs is indispensable in reducing the losses.

**Keywords:** *Bull; Lumpy skin disease; Treatment*

##### Introduction

Lumpy skin disease is an infectious and occasionally fatal disease of cattle (Hamid, 2016). It is among the major health problems affecting the livestock industry of most developing countries like Ethiopia (Abera *et al.*, 2015; Gari *et al.*, 2010; Gari *et al.*, 2011). The disease is caused by lumpy skin disease virus for which Neethling strain is the prototype and transmitted mechanically by arthropod vectors (Lubinga *et al.*, 2014; Tuppuraine *et al.*, 2013; Tuppurainen and Oura, 2012). Temporally LSD is shown to be aggregated during the warm and humid months of the year (Gari *et al.*, 2010), which is directly associated with vector abundance. These authors also revealed the role of husbandry practices such as commingling of animals at communal grazing and watering points in the transmission of LSDV.

Lumpy skin disease lesions may explode from 7 to 14 days post infection under experimental conditions whereas in natural cases it takes 2 to 5 weeks (Tuppuraine *et al.*, 2005). The disease is

manifested by distinguishing firm, circumscribed, few (mild forms) to multiple (severe forms) skin nodules, which sometimes involve mucous membranes of the respiratory system, urogenital system and other internal organs (AU-IBAR, 2013; Tageldin *et al.*, 2014). In severe cases continuous high pyrexia (40–41.5°C), depression and anorexia may ensue (Constable *et al.*, 2017). Subsequently, milk production lessens, abortion, temporary or permanent sterility, damage to hide and deaths will occur which further contribute to a momentous economic loss (OIE, 2010; Tuppuraine *et al.*, 2017).

The clinical cases of LSD can be confirmed using conventional or real-time PCR methods using tissue or blood samples (Tuppuraine *et al.*, 2005). Although prevention with available vaccine plays significant role in controlling the occurrence of LSD in endemic areas, treatment of clinical cases as early as possible might reduce the complications and economic losses of the disease. These could be achieved through treatment of secondary bacterial complications using a combination of antimicrobial and anti-inflammatory drugs (Abutarbush *et al.*, 2013; Salib and Osman, 2011). Therefore, the current case report describes the treatment outcome of lumpy skin disease in bull.

#### Case description

A local breed bull was examined at Addis Ababa University College of Veterinary Medicine, Veterinary Teaching Hospital on November 29, 2017, with complaint of nodular eruptions on different body parts. According to the complaints, the feed intake and performance of the animal was also reduced. The animals were kept in communal grazing land with other herds and they were not vaccinated for more than a year. Upon physical examinations, the bull was lethargic and febrile with the rectal body temperature of 40.4 °C and 64beats/min and 36 breaths/min heart and respiratory rates, respectively. There was a flare-up of small to large sized circumscribed nodules on different body parts and the neck area in particular (Figure 3). The nodules were also seen on the scrotum and hind legs. Some nodules coalesced and form larger nodules (Figure 3, arrow). Besides, there was lameness, swelling of both prescapular and prefemoral lymph nodes. The tentative diagnosis was established as lumpy skin disease (LSD) based on the history, clinical findings and eruption of similar cases in other areas.



**Figure 3:** First day visit at VTH with lumpy skin nodular lesions

#### Laboratory investigation and findings

For further confirmation of the case, excisional biopsy of cutaneous nodule was collected for PCR. During biopsy sampling, the bull held in chute, the selected nodule (on the left hind limb) was prepared aseptically and anaesthetized locally using 2% Lidocaine. The entire nodular biopsy (excisional biopsy) was taken aseptically and the incisions were sutured with Ethicon Vicryl (Tuppurainen, 2005). Sample was placed in phosphate buffered saline (PBS) containing universal sterile bottle and submitted with cold chain to NVI (National Veterinary Association, Ethiopia) for PCR protocol. The NVI report confirmed that the bull was suffering from lumpy skin disease caused by lumpy skin disease virus (LSDV) (Annex4).

#### Case management and treatment outcome

The treatment of the bull was aimed at reducing pain to the animal and losses of the disease. Hence, therapy of 10% Oxytetracycline (Shanghai Thongren Pharmaceutical Co., Ltd, China) at 10mg/kg/day for five successive days and Dexamethasone (Sokar Healthcare Pvt.Ltd. Gujarat India) 0.2mg/kg/day for three consecutive days were managed I.M. The owner was also advised to segregate and nurse the animal at home until fully recovered. Feed intake has been recommencing gradually (reported by owner) and also rectal body temperature was dropped to 39.7°C and 38.5°C after 24 and 48 hours post-treatment, respectively (at clinic), however the

nodules were present during the courses of therapy. Three months later the bull was fully recovered and nodules were also disappeared but with scars on the skin (Figure 4). A week after recovery, the owner reported that he sold his bull.



**Figure 4:** Indicates the bull recovered (three months later)

#### Discussion

Lumpy skin disease is enzootic in Africa, mainly a disease of cattle with 20% morbidity and 2% case fatality (Hamid, 2016). Based on the clinical signs, history and laboratory result, the current incident was confirmed as LSD which is in agreement with Al-Salihi (2014), Mauldin and Peters-Kennedy (2016) reports. According to these authors, infected animals may show fever commonly rises to 40-41.5°, lacrimation, nasal discharge, anorexia, dysgalactia, general depression and a disinclination to move. The usual manifestations of LSD are multiple firm circumscribed nodules developed in the skin of the animals in which head, neck, the perineum, the genitalia, udder, and the limbs are principally involved. The regional lymph nodes are easily palpable and enlarged 3-5 times their normal size. Most cases may complicate or extend to other underlying tissues or internal organs and may sequel in economically significant disorders (Constable *et al.*, 2017). LSD is not associated with high mortalities (1-3%); however, the economic losses accompanying LSD eruption is higher. The losses are significant due to decreased feed intake, milk production, weight conversion, abortion and infertility, and damaged hides (Abutarbush *et al.*, 2013; Babiuk *et al.*, 2008; EFSA, 2015; Hamid, 2016; Mauldin and Peters-Kennedy, 2016). Therefore, systemic antibiotic and anti-inflammatory drugs are obligatory for skin infections,

cellulitis or pneumonia, and considerably to avoid further complications and economic losses (Abutarbush *et al.*, 2013; Hamid, 2016).

In the present study, 10% Oxytetracycline and Dexamethasone were managed; consequently, fever, anorexia, nodular lesions and other deviations were remarkably improved but the skin healed with scar. Similarly, a treatment trial conducted by Salib and Osman (2011) with the aim of preventing LSD complications and saving the life has been successful using a combination of antimicrobials, anti-inflammatory, supportive therapy and antiseptic solutions. According to these authors, the complications encountered during the trial have been recovered within 3 days to 2 weeks. However, the treatments do not guarantee full recovery as the skin nodular restoration prolonged and healed with scar.

In conclusion, lumpy skin disease (LSD) is an economically devastating viral disease of cattle characterized by distinctive nodular lesions principally on the skin, hence reduces hide quality. Although it doesn't guarantee full recovery, management of LSD with antibiotics and anti-inflammatory can lead to recovery and prevent LSD complications and reduce economic losses. However, prevention with available vaccine plays significant role in controlling the occurrence of LSD in endemic areas.

#### Acknowledgement

I am grateful to Addis Ababa University college of Veterinary medicine, Veterinary Teaching Hospital staff, in particular Dr. Cheru Talila and Mr. Dereje Gudeta for their contribution. And also, the owner of the animal for his valuable information during the follow up.

## References

- Abera Z., Degefu H., Gari G., Kidane M. (2015): Sero-prevalence of lumpy skin disease in selected districts of West Wollega zone, Ethiopia. *Biomedical Center Veterinary Research*, **11**: 135.
- Abutarbush S. M., Ababneh M. M., Al Zoubil I. G., Al Sheyab O. M., Al Zoubi M. G., Alekish M. O., AL Gharabat R. J. (2013): Lumpy Skin Disease in Jordan: Disease Emergence, Clinical Signs, Complications and Preliminary-associated Economic Losses. *Transboundary and Emerging Diseases* **62**, : 549-554.
- Al-Salihi K. A. (2014): Lumpy Skin disease: Review of literature. *Mirror of Research in Veterinary Sciences and Animals* **3**, : 6-23.
- AU-IBAR (2013): African Union - Interafrican Bureau for Animal Resources: lumpy skin disease. Selected content from the Animal Health and Production Compendium (© CAB International 2013). <http://www.au-ibar.org/lumpy-skin-disease>, accessed on August, 2017.
- Babiuk S., Bowden T. R., Dalman B., Parkyn G., Copps J. (2008): Quantification of lumpy skin disease virus following experimental infection in cattle. *Transboundary Emerging Disease*, **55**.
- Constable, P. D., Hinchcliff, K. W., Done, S. H., and Grundberg, W. (2017): *Veterinary Medicine: A Textbook of the Diseases of Cattle, Horses, Sheep, Pigs, and Goats*. UK: Elsevier . 1591 p.
- EFSA (2015): European Food Safety Authority. Scientific Opinion on Lumpy Skin Disease. EFSA Panel on Animal Health and Welfare (AHAW). *EFSA Journal* **13**: 3986.
- Gari G., Bonnet P., Roger F., Waret-Szkuta A. (2011): Epidemiological aspects and financial impact of lumpy skin disease in Ethiopia. *Preventive Veterinary Medicine*, **102**.
- Gari G., Waret-Szkuta A., Grosbois V., Jacquiet P., Roger F. (2010): Risk factors associated with observed clinical lumpy skin disease in Ethiopia. *Epidemiology and Infectious*, **138**.
- Hamid M. E. (2016): Clinical Quiz No. 10. In: *Skin Diseases of Cattle in the Tropics*. Academic Press. pp. 45-48.
- Lubinga J. C., Tuppuraine E. S., Coetzer J. A., Stoltsz W. H., Venter E. H. (2014): Evidence of lumpy skin disease virus over-wintering by transstadial persistence in *Amblyomma*

- hebraeum and transovarial persistence in *Rhipicephalus decoloratus* ticks. *Experimental and Applied Acarology*, **61**.
- Mauldin E. A., Peters-Kennedy J. (2016): Chapter 6 - Integumentary System. In: Jubb, Kennedy & Palmer's Pathology of Domestic Animals: Volume 1 (Sixth Edition). W.B. Saunders. pp. 509-736.
- OIE (2010): World Organization for Animal Health. Lumpy Skin Disease. OIE terrestrial manual. [https://web.oie.int/eng/normes/MANUAL/2008/pdf/2\\_04\\_14\\_LSD.pdf](https://web.oie.int/eng/normes/MANUAL/2008/pdf/2_04_14_LSD.pdf) accessed on March 14, 2018.
- Salib F. A., Osman A. H. (2011): Incidence of lumpy skin disease among Egyptian cattle in Giza Governorate, Egypt. *Veterinary World*, **4**: 162-167.
- Tageldin M. H., Wallace D. B., Gertdes G. H., Putterill J. F., Greyling R. R., Phosiwa M. N., Albusaidy R. M., Al Islmaaily S. I. (2014): Lumpy skin disease of cattle: an emerging problem in the Sultanate of Oman. *Tropical Animal Health and Production*, **46**: 241-246.
- Tuppuraine E. S., Alexandrov T., Beltran-Alcrudo D. (2017): Lumpy skin disease field manual - A manual for veterinarians. FAO Animal Production and Health Manual. 20: 1-60.
- Tuppuraine E. S., Stoltsz W. H., Lubinga J. C., Carpenter M. S., Coetzer J. A., Venter E. H., Oura C. A. (2013): Mechanical transmission of lumpy skin disease virus by *Rhipicephalus appendiculatus* male ticks. *Epidemiology and Infection*, **141**: 425-430.
- Tuppurainen E., Oura C. (2012): Review: Lumpy Skin Disease: An Emerging Threat to Europe, the Middle East and Asia. *Transboundary and Emerging Diseases*, **59**: 40-48.
- Tuppurainen E., Venter E., Coetzer J. (2005): The detection of lumpy skin disease virus in samples of experimentally infected cattle using different diagnostic techniques. *Onderstepoort Journal of Veterinary Research*, **72**: 153-164.

#### 4.1.3. Colibacillosis in a calf

##### Abstract

Colibacillosis is one of the most significant diseases in calves, causing enormous economic losses in cattle producing industries worldwide. A crossbred calf of around two-month old was examined in Addis Ababa University College of veterinary medicine, Veterinary Teaching Hospital, Bishoftu on January, 1/2018, with the history of runny and blood containing fecal output. Other abnormalities and deviation from normal body parameters were also appreciated. Bacteriological cultures of fresh fecal samples show that the dysentery was due to *E. coli* infection whilst bacteriological culture for Salmonella and parasitological examinations for *Eimeria* oocytes were negative. Sulfadimidine sodium with 1.5ml/2.5kg/day as initial dose and 0.75ml/2.5kg/day for the other four subsequent days were administered IM, for a total of five days. The calf was successfully recovered at the end of treatment course. Hence early and appropriate intervention could be cured colibacillosis.

**Keywords:** *Calf; Colibacillosis; Dysentery; Sulfadimidine*

##### Introduction

Calf diarrhea is one of the most common diseases in young animals, causing enormous economic and production losses to bovine based businesses worldwide (Cho and Yoon, 2014). Manifold pathogens are claimed to cause or contribute to calf diarrhea (Jessie *et al.*, 2016). Amongst them, *Bovine rotavirus* (BRV), *Bovine coronavirus* (BCoV), *Bovine viral diarrhea virus* (BVDV), *Salmonella enterica*, *Escherichia coli*, *Clostridium perfringens*, and *Cryptosporidium parvum* are principal and newly emerging enteric pathogens such as *Bovine torovirus* and *caliciviruses* (*Bovine norovirus* and *Nebovirus*) are also donating. Other factors including both the environment and management practices influence disease severity or outcomes. *Escherichia coli* are amongst common bacterial causes of diarrhea and septicemia in cattle producing industries of the world. There are six major diarrheagenic *E.coli* pathotypes (Croxen *et al.*, 2013) which include enterotoxigenic *E.coli* (ETEC), Shiga toxin-producing *E. coli*, enteropathogenic *E. coli*, enteroinvasive *E. coli*, enteroaggregative *E. coli*, and enterohaemorrhagic *E. coli*. Among them,

Enterotoxigenic *E.coli* (ETEC) is confirmed as the main causative agent of neonatal calf diarrhea. Enteropathogenic *E.coli* (EPEC), Shiga toxin-producing *E.coli* (STEC including enterohemorrhagic *E.coli*/EHEC) are also often isolated from diarrheic and healthy calves, but their role in calf disease remains controversial (Dubreuil *et al.*, 2016; Kolenda *et al.*, 2015)

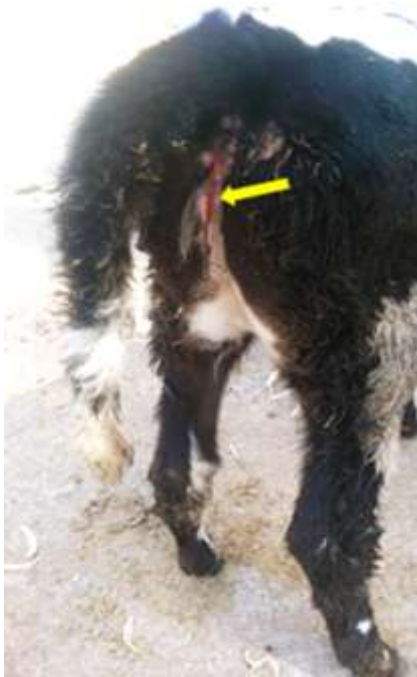The pathogenic strains of *E.coli* are the cause of enteritis manifested by diarrhea, dysentery, abdominal pain, dehydration as well as electrolyte loss and imbalance. In severe cases, mucus, shreds or sheets of exfoliated mucosa might be present in the feces (Constable *et al.*, 2017). Transmission is most often through oral-fecal route by ingestion of contaminated feed and water, however infection through umbilical vein and nasopharyngeal routes were believed to occur in certain serotypes of *E.coli* (Constable *et al.*, 2017). New born are more susceptible due to deficiency of immunoglobulin (Jessie *et al.*, 2016).

Definitive diagnosis of the condition requires examination of fecal sample by microscopy (for *C. parvum* and Coccidian), bacterial culturing (for *Salmonella* spp., *E. coli*, and *C. perfringens*), and PCR (for BRV and BCoV). More recently, antigen-capturing enzyme-linked immunosorbent assay (Ag-ELISA) have been more commonly used for the rapid detection of various bacterial and viral pathogens in clinical specimens from diarrheic calves (Cho and Yoon, 2014). The intervention requires vigorous antibiotic treatment together with intravenous fluid (IVF) and non-steroidal anti-inflammatory agents (NSAID) immediately as the disease cannot give time until confirmation (Jessie *et al.*, 2016). Therefore, this case report describes the clinical case of colibacillosis in calf and its treatment outcome.

### Case description

A two-month old crossbred calf was presented to AAU-CVMA-VTH, Bishoftu on January, 1/2018 with the history of runny, blood containing fecal output and reduced feed intake. The calf was kept intensively separated from her dam and fed milk. The clinical examination of the calf revealed high temperature (40.8<sup>0</sup>C) and increased heart rate (94/min) while the respiratory rate was within the normal range. The calf was slightly dehydrated. There was congestion of conjunctival mucus membranes, dysentery and soiled perineum with fleck of blood (Figure 5

arrow). Based on history and clinical pictures *coccidiosis* was diagnosed tentatively although *Salmonellosis* and *colibacillosis* were doubted.



**Figure 5:** A calf with bloody diarrhea (the arrow)

#### Laboratory investigations and findings

For further confirmation of the case, fecal samples were collected directly from the rectum of the calf into specimen container and labeled accordingly. The samples were submitted and processed at Microbiology and Parasitology laboratory of Addis Ababa University College of Veterinary Medicine, Bishoftu. The first day a fecal floatation technique was performed for the detection of *Eimeria/Coccidian* oocytes and the result was negative. The same day 1gm of fecal sample was cultured on the liquid enrichment media (9ml) and incubated at 37 °C for 24hrs. On the following day the enriched fecal samples were cultured on sorbitol macConkey agar and Rappaport broth selective medium for the isolation of *E.coli* and *Salmonella*, respectively. After incubation at optimum temperature, growth was observed on the sorbitol macConkey agar medium but not on the Rappaport broth. The growths from the sorbitol macConkey agar selective medium for *E.coli* were harvested and sub cultured on nutrient agar medium and EMB (Annex 4). The next day the gram's staining was performed from the pure culture on the nutrient agar. Finally it was

concluded based on the growth patterns and Gram's stain results the bacterium responsible for the disease was *E.coli*.

Therefore, based on the clinical pictures and laboratory findings it was confirmed that the calf was suffering from colibacillosis caused by *Escherichia coli* and the treatment regimen that has been started based on the tentative diagnosis was continued with thorough follow up.

#### Case management and treatment outcome

Sulfadimidine sodium 33.3% (Hebei Yuanheng Pharmaceutical Co., Ltd, China) with 1.5ml/2.5kg/day as initial dose and 0.75ml/2.5kg/day for the other four subsequent days were administered IM, for a total of five days. The calf was followed until recovered and on the second day of therapy the calf started taking feed but evacuation of runny feces mixed with blood was continued with slight change. However, on the fifth day of therapy (Figure 6), the calf was fully revived and recommenced to normal state.



**Figure 6:** Status of the calf on the 5<sup>th</sup> day of therapy

## Discussions

Colibacillosis is a major economic concern in bovine industries all over the world and able to cause various forms of calf diarrhea which ranges from severe diarrhea to mild less significant diarrhea (Shahrani *et al.*, 2014). Although *E.coli* is a part of normal flora in the GIT of animals, there are pathogenic forms which able to cause severe diseases most commonly following stress and immunosuppression. The current case was confirmed as colibacillosis caused by *E.coli* based on the integrated results of clinical pictures, age of the animal and laboratory results.

Enterotoxigenic *Escherichia coli* (ETEC) are amongst common diarrhegenic types of *E. coli* characterized by adhesions, which are expressed in the context of fimbriae (commonly F5 (K99) and F 41 fimbriae in calves) and enterotoxins production, which is responsible for fluid secretion and watery diarrhea (Dubreuil *et al.*, 2016). These ETEC induce diarrhea in calves in the first four days of life, older calves or adult cattle being more resistant. Albeit both healthy and diarrheic calves harbor STEC (shiga toxin producing *E.coli* including EHEC (enterohemorrhagic *E.coli*)) in their intestine, natural outbreaks and experimental infections have been documented in association with diarrhea and dysentery in young calves. The strains are capable of attaching, eroding and producing toxin which is responsible for diarrhea and dysentery to 1- to 5-week-old nursing calves that have been attributed to serogroups including O157, O26, O103, O111, O145, O45, O91, O113, O121 and O128 (Sandhu and Gyles, 2002; Shahrani *et al.*, 2014).

In the current instance, a two-month old calf had shown dysentery and bacteriological culture results were also indicated the presence of *E.coli* in the fecal sample which was negative for salmonella and *Eimeria* tests. Although a further investigation for other serogroups of STEC/EHEC was not performed in this case, the incidents of dysentery due to EHEC serogroups were reported by some authors. Sandhu & Gyles (2002) and Shahrani *et al.* (2014) reported the endowed ability of EHEC to attach, erode and produce toxin and cause dysentery in young calves. Besides, Moxley *et al.* (2015) reported the first case of EHEC O165: H25 in one-year-old heifer with clinical manifestation of bloody diarrhea and nervous sign. Besides, EPEC can also be able to cause hemorrhagic diarrhea in young animals due to its effacing and attaching life style. Hence, the present case of dysentery may be associated with either EHEC serogroups or EPEC

rather than Enterotoxigenic *Escherichia coli* (ETEC) which lack effacing nature and usually responsible for watery diarrhea.

According to Constable (2004), Amoxicillin, chlortetracycline, neomycin, oxytetracycline, streptomycin, sulfachloropyridazine, sulfamethazine, and tetracycline are recommended drugs for the treatment of colibacillosis. In contrast Shahrani *et al.*, (2014) report was elucidated as most serogroups of EHEC are highly resistant to penicillin, streptomycin and tetracycline antibiotics. In agreement with current instance, Shahrani *et al.*, (2014) also reported that most serogroups of EHEC are highly susceptible to sulfonamide antibiotics.

In conclusion, *Escherichia coli* are a major economic concern in cattle producing industries worldwide and able to cause severe bloody diarrhea in calf. However, early detection and intervention with appropriate antibiotics will overcome the losses due to the incident. For the prevention of the occurrences, colostrum feeding to newborn and hygienic management of the premises play integral role.

#### Limitations

During this work the agglutination kits used to identify the *E.coli* serogroups were not available and hence the study was concluded based on bacterial culture and clinical pictures only.

#### Acknowledgement

I am grateful to Addis Ababa University college of Veterinary medicine, Veterinary Teaching Hospital staff, in particular Ms. Tsedale.

#### References

- Cho Y., Yoon K. (2014): An overview of calf diarrhea - infectious etiology, diagnosis, and intervention. *Journal of Veterinary Science*, **15**: 1-17.
- Constable P. (2004): Antimicrobial use in the treatment of calf diarrhea. *Journal of veterinary internal medicine*, **18**: 8-17.

- Constable P., Hinchcliff K., Done S., Grundberg W. (2017): *Veterinary Medicine: A Textbook of the Diseases of Cattle, Horses, Sheep, Pigs, and Goats*. UK: Elsevier . 1879 p.
- Croxen M., Law R., Scholz R., Keeney K., Wlodarska M., Finlay B. (2013): Recent Advances in Understanding Enteric Pathogenic *Escherichia coli*. *Clinical Microbiology Review*, **26**: 822-880.
- Dubreuil J. D., Isaacson R. E., Schifferli D. M. (2016): Animal Enterotoxigenic *Escherichia coli*. *EcoSal Plus* **7**: 10.
- Jessie F., Saharee A., Yussuf A., Chung E., Adamu L., Bitrus A., Hambali I., Lila M., Haron A., Saharee A., Salleh A., Gabriel a. (2016): Clinico-Pathological Findings of Septicaemic Colibacillosis in a Calf Submit Manuscript. *Journal of Dairy, Veterinary & Animal Research*, **4**: 00124.
- Kolenda R., Burdukiewicz M., Schierack P. (2015): A systematic review and meta-analysis of the epidemiology of pathogenic *Escherichia coli* of calves and the role of calves as reservoirs for human pathogenic E. coli. *Front Cell Infection Microbiology*, **5**: 23.
- Moxley R., Stromberg Z., Lewis G., Loy J., Brodersen B., Patel I. (2015): Haemorrhagic colitis associated with enterohaemorrhagic *Escherichia coli* O165 : H25 infection in a yearling feedlot heifer. *Journal of Medical Microbiology*, **2**:1-4
- Shahrani M., Dehkordi F. S., Momtaz H. (2014): Characterization of *Escherichia coli* virulence genes, pathotypes and antibiotic resistance properties in diarrheic calves in Iran. *Biology Research*, **47**: 28.
- Sandhu K., Gyles C. (2002): Pathogenic Shiga toxin-producing *Escherichia coli* in the intestine of calves. *Canadian Journal of Veterinary Research*, **66**: 65-72.

#### 4.1.4. Laryngeal necrobacillosis and its treatment in calf and cow

##### Abstract

Laryngeal necrobacillosis is an inflammatory disease of the larynx particularly of the mucous membrane which lines its interior. It is a major disease confined to younger calves. This case report describes a laryngeal necrobacillosis and its treatment in calf and cow. The cases were similar in clinical presentations but with different endings. The calf was treated with penstrip for seven successive days at 1ml/20kg/day and Dexamethasone sodium phosphate at 0.2mg/kg/day for three days both I.M. but not responded. Then, 10% Oxytetracycline at 1ml/10kg/day for the other five days and dexamethasone sodium phosphate for the other three days were managed but calf died while under medication. However, the cow was successfully responded to oxytetracycline and Dexamethasone. Therefore, the prognosis of laryngeal necrobacillosis is good for early cases that are treated aggressively with antibiotic and anti-inflammatory but refractory if delayed.

**Keywords:** *Calf; Cow; Laryngeal necrobacillosis; Treatment*

##### Introduction

Laryngeal necrobacillosis or laryngitis is an inflammatory disease of the larynx particularly of the mucous membrane which lines its interior. It is a major disease of confined younger calves but can occasionally encounter adult cattle for up to 18 months. The condition is usually associated with injuries to the mucosa of laryngeal areas or adjacent tissues (abrasive feedstuffs, oral dosing) allowing anaerobic conditions to *Fusebacterium necroforum*, which unable to penetrate intact mucous membrane (Blowey and Weaver, 2011; Cockcroft, 2015). Concurrent diseases (persistently viraemic BVDV in calves) and nutritional deficiency may also predispose to such bacterial infection and in adult cattle, the lesions are generally located in the oro-pharynx and are often secondary to trauma from thorny feeds or faulty oral medications (Larde *et al.*, 2014). Following the exposure, edema and inflammation of the mucosa of the larynx will result; further varying degrees of closure of the rima glottidis which is manifested by inspiratory dyspnea and stridor will ensue. Discomforts, painful swallowing, and toxemia may occur as well and if left

untreated or delayed, the incidents will progress to laryngeal chondritis due to the arytenoid cartilages involvement and consequently healing process will be complicated or fail completely (Constable *et al.*, 2017). Therefore, this case report describes laryngeal necrobacillosis and their management in calf and cow.

## Case descriptions


### Case 1

A three-month old cross breed calf was presented to AAU-CVMA-VTH in February, 6/2018 with the history of difficulty breathing and unable to suckle. The calf was managed at home with her dam and has been treated for the case but not responded. Upon physical examination, the rectal body temperature of the calf was 40.4 °C while respiratory rate and heart rates were 56 breaths/min and 72 beats/min, respectively. The calf had typical inspiratory stridor (roaring, honking) audible from distant and dyspnea and stands with extended neck and head held in lowered position, tongue protruded and breathes through the mouth (figure 7B). In addition, palpable laryngeal swelling from external and congested mucous membranes was appreciated. The remainders of the clinical examination were unremarkable.

### Case 2

A local breed cow of around four years old with the history of difficulty breathing, reduced feed and water intake was examined in March, 21/2018 at AAU-CVMA-VTH. According to the owner the condition was started four days before admission. During physical examination there was swelling of the laryngeal area (firm, painful and non-productive up on aspiration), inspiratory dyspnea, Stridor, moist cough, excessive salivation, lacrimation (Figure 7A), congestion of the mucous membranes and foul smell from the mouth were appreciated.

Based on the history and typical clinical findings, both cases were diagnosed tentatively as Laryngitis or laryngeal necrobacillosis amongst mechanical obstruction and other respiratory problems and treatment regimen was arranged.

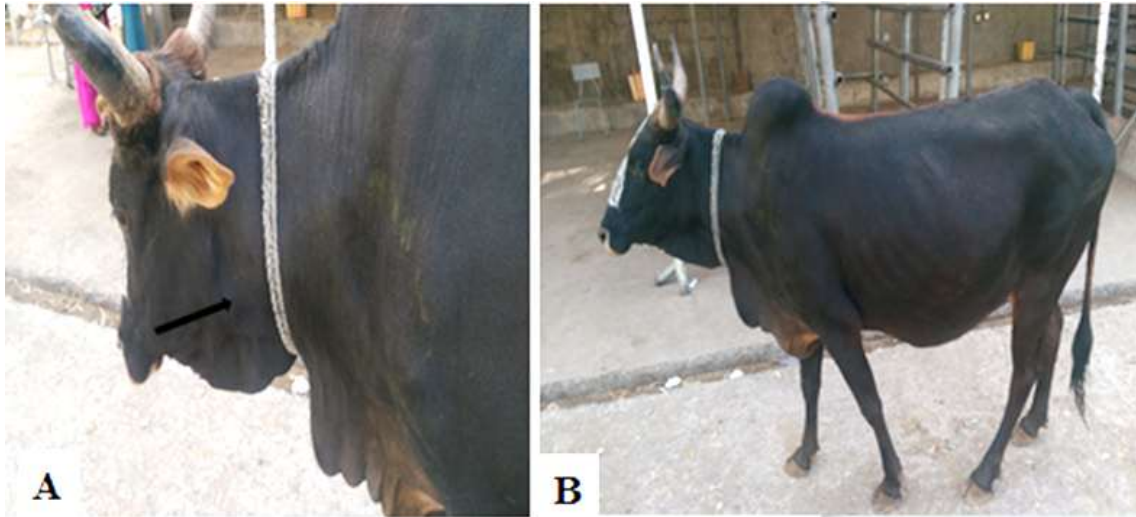

**Figure 7** Cow with salivation and lacrimation (A, arrows) and the calf with open mouth breathing (B).

#### Case management and treatment outcome

Treatment for both cases was arranged accordingly: the calf was treated with penstrip (Chongqing Fantong Animal Pharmaceutical Co.Ltd, China) for seven successive days at 1ml/20kg/day and Dexamethasone sodium phosphate (Sokar Healthcare Pvt.Ltd. Gujarat India) 0.2mg/kg/day for three days both I.M. but not responded. Then, 10% Oxytetracycline (Shanghai Thongren Pharmaceutical Co., Ltd, China) at 1ml/10kg/day for the other five days and dexamethasone sodium phosphate 0.2 mg/kg/day for the other three days were arranged again; but the calf died while under medication. Conversely, the cow was successfully responded to 10% Oxytetracycline at 1ml/10kg/day for seven successive days and Dexamethasone sodium phosphate 0.2 mg/kg/day for three days both I.M.

Post-treatment (from day one to day three therapy), the cow's feed intake has been improved (owner reported) whilst inhalation and the swelling under the jaw were not fully recovered (Figure 8A). On the seventh day therapy (from day four to day six post-treatment), salivation, lacrimation, and inspiratory dyspnea were disappeared while the swelling was reduced but not completely disappeared (Figure 8B). Two week later, the owner responded that the cow was fully recovered.



**Figure 8:** Cow's recovering post treatment A (after the 3<sup>rd</sup> therapy) and B (after the 6<sup>th</sup> day therapy).

#### Discussion

The current cases of laryngeal necrobacillosis in young and adult cattle have similar clinical presentations with those indicated in (Constable *et al.*, 2017). In present incidents, the cow was responded efficaciously to 10% Oxytetracycline for seven days coupled with Dexamethasone for three days which was due to early intervention with due follow up. In contrast, the calf was failed to respond to two weeks follow up with the same protocol and died which may be due to late hospital visit and subsequently progression or complication of the case. The present protocols are in agreement with Scott (2010) which elucidates the effectiveness of parenteral potentiated sulphonamides and oxytetracycline for at least 7–10 consecutive days for laryngeal necrobacillosis. These authors also indicated coupling of the antibiotics with anti-inflammatory drugs is helpful in the acute stage of the case and reduce laryngeal edema and aid breathing. Tracheotomy was not performed in the present case of the calf because of poor prognosis related to suppurative chondritis and destruction of laryngeal architecture.

In conclusion, laryngeal necrobacillosis is an important disease in both young and adult cattle with the abilities to causing significant losses due to mortalities associated with the furtherance and complication of the condition. However, the prognosis is good for early cases that are treated aggressively with antibiotic and anti-inflammatory. Avoiding thorny feeds could reduce the occurrence of the conditions.

### Limitations

During this work, diagnostic imaging tools such as ultrasound and/or x-rays were not available which may aid in identifying the site and extent of the lesion.

### Acknowledgement

I am grateful to Mr. Dereje Gudeta and also, the owner of the animal for his valuable information during the follow up.

### References

- Blowey, R. and Weaver, A. (2011): Color Atlas of Diseases and disorders of Cattle. China: Elsevier. 26 p.
- Cockcroft, P. (2015): Bovine Medicine. UK: Wiley Blackwell. 574 p.
- Constable P., Hinchcliff K., Done S., Grundberg W. (2017): Veterinary Medicine: A Textbook of the Diseases of Cattle, Horses, Sheep, Pigs, and Goats. UK: Elsevier . 534 p.
- Larde H., Nichols S., Babkine M., Chenier S. (2014): Laryngeal obstruction caused by lymphoma in an adult dairy cow. *Canadian Veterinary Journal*, **55**: 136-140.
- Scott, P. R. (2010): Self assessment colour Review: Cattle and Sheep medicine. UK: Manson publishing Ltd.

#### 4.1.5. *Escherichia coli* caused clinical mastitis in a late pregnant cow

##### Abstract

*Escherichia coli* mastitis is an environmental form of clinical mastitis having a substantial impact on dairying worldwide. This case report describes a clinical mastitis caused by *Escherichia coli* in a pregnant cow. A pregnant at last trimester cow was examined with the complaint of swelling of the udder, reduced appetite and leakage from the teat in November, 21/2017 in one of privately owned smallholder dairy farm, Bishoftu. Upon physical examination, the cow was febrile with a rectal body temperature of 40.4° C while other parameters were normal. The left hind quarter of a cow was severely affected and appeared swollen, firm, reddened, painful, and warm. The left forequarter was also slightly affected while the other two superficially healthy. There was greyish and clotted seepage from the affected quarter. Bacteriological culture of milk sample revealed bacterium *Escherichia coli* as the etiology. The case was thoroughly treated intravenously with oxytetracycline at a dose of 1ml/10kg/day for five days and dexamethasone at a dose of 0.2mg/kg/day intramuscularly for three days. After a month the cow was fully recovered.

**Keywords:** *Clinical mastitis; Escherichia coli; Late pregnant cow*

##### Introduction

Mastitis is the disease of greatest economic importance for the dairy cattle industries worldwide. About 140 microbial species, subspecies, and serovars have been isolated from the bovine mammary gland (Constable *et al.*, 2017). Based on their epidemiology and pathophysiology, these pathogens have been further classified as causes of contagious, teat skin opportunistic or environmental mastitis. However, *Staphylococcus aureus*, *Streptococcus agalactiae* and other spp., *Corynebacterium bovis* (summer mastitis of heifers, dry cows, and beef breeds), coliform agents (*Escherichia coli* and *Klebsiella pneumoniae*), and Mycoplasma spp. including *Mycobacterium bovis* (California mastitis) is the principal cause of mastitis in bovine (Bradley, 2002; Pieterse and Todorov, 2010; Plummer and Plummer, 2012; Quinn *et al.*, 2016). *Staphylococcus* species, *Streptococcus* species, and *E. coli* are the most reported and leading infectious causes in Ethiopia (Belayneh *et al.*, 2013). They are responsible for both subclinical

and clinical forms of the diseases with a prevalence range of 2.7-21.0% for clinical mastitis and 33.3-68.1% for subclinical mastitis cases in small and large-scale dairy farms of Ethiopia (Adane *et al.*, 2012). In general, clinical forms of mastitis are manifested by inflammatory responses including swelling, redness, alterations in milk composition, and decreased milk production of the infected quarter whereas the subclinical forms are by elevated somatic cells and an obviously decreased milk production (Brankol *et al.*, 2012).

*Escherichia coli* is amongst clinical form of mastitis characterized by inflammation of the mammary gland in dairy cows around parturition and during early lactation with striking local and sometimes severe systemic clinical symptoms (Burvenich *et al.*, 2003). The ability to infect the non-lactating gland is directly related to the ability of the bacteria to acquire iron from the mammary secretion. It is well known that bacterial, cow and environmental factors are interdependent and influence mastitis susceptibility. *Escherichia coli* is thought to dwell in bedding materials, soil, manure and other organic matter in the environment of cows. Ensuring entry using teat canal, they exploit available substrates in the mammary secretion and hence replicate and evade host defenses. Therefore, mastitis caused by this agent is commonly known as environmental mastitis or coliform mastitis (Hogan and Smith, 2003).

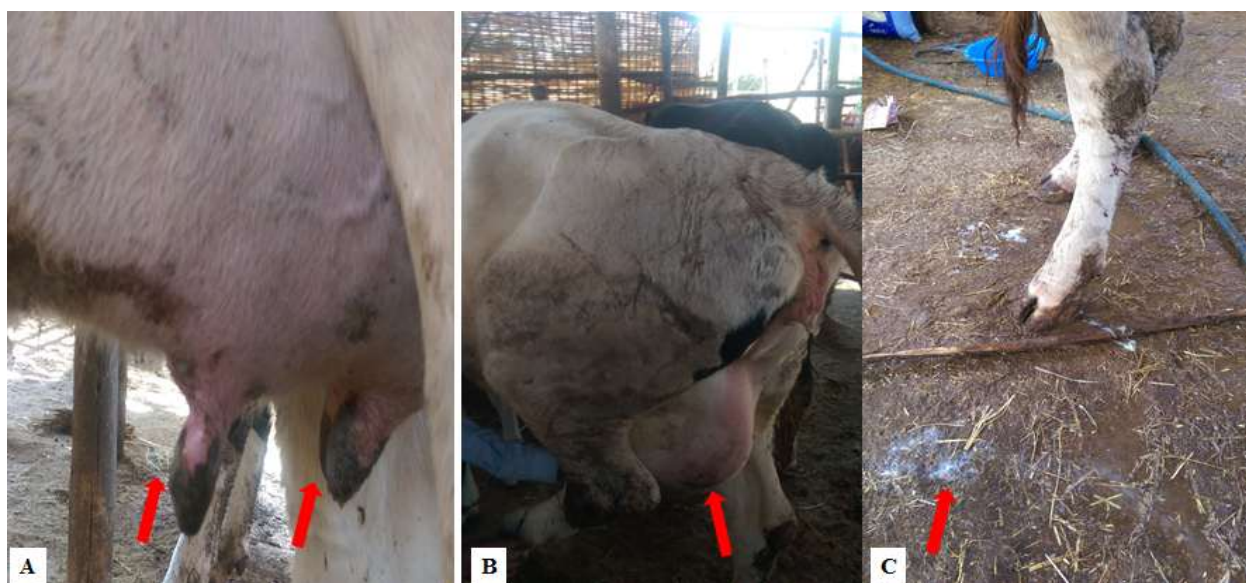
Many of the clinical signs of coliform mastitis are associated with the release of lipopolysaccharides and the systemic response to these endotoxins (Plummer and Plummer, 2012). The clinical characteristics and outcome of *E. coli* mastitis vary from mild mastitis, where cows have only local signs in the udder and the duration of the infection is short, to very severe or even fatal forms (Erskine *et al.*, 2002; Burvenich *et al.*, 2003). *E. coli* mastitis typically has a sudden onset, which leads to changes in milk appearance, first to serious and yellow, and later to clotty and thick. Milk somatic cell count (SCC) increases to very high numbers. The udder becomes hard, swollen and tender. The cow also has systemic signs, generally including high fever, increased pulse frequency, reduced rumen contractions, lack of appetite, depression and decreased milk production (Wenz *et al.*, 2001).

The treatment of clinical bacterial mastitis are based on the considerations of the spectrum of activity, an effective therapeutic concentration at the site of infection, duration of treatment and

adverse local and /or systemic effects and violate residues (Constable and Morin, 2003; MacDiarmid, 2011). In cases of severe *E. coli* mastitis, parenteral administration of fluoroquinolones and cephalosporins are thought to be effective, however, has been limited to use in food animals. In *E. coli* mastitis with mild to moderate clinical signs, a non-antimicrobial approach (anti-inflammatory treatment, frequent milking, and fluid therapy) should be the first option. Evidence for the efficacy of intramammary-administered antimicrobial treatment for *E. coli* mastitis is so limited that it cannot be recommended (Roberson, 2012; Suojala *et al.*, 2013).

### Case descriptions

A late pregnant cow was examined at Bishoftu in one of privately owned smallholder dairy farm in November, 21/2017. The major complaint of the attendant was the swelling of the udder, reduced appetite, and leakage from the teat. Upon physical examination, the rectal body temperature was raised (40.4°C) while other parameters were normal. The left hind quarter of the cow was affected and appeared swollen, firm, reddened, painful (figure 9A&B), and warm. The left forequarter was also affected (moderate) while the other two superficially healthy. There was greyish and clotted seepage from the affected quarter (figure 9C). The cows were kept together at a stall with close proximity and the manure removal from the stable was poor. Based on the history and clinical findings, mastitis affirmed tentatively.



**Figure 9:** Indicates affected quarters (A&B) and clotty milk(C) from the affected teat

## Laboratory investigations and findings

A milk sample from the severely affected teat was collected and submitted for bacteriological culture accordingly. The bacteriological culture was made on sorbitol macConkey and blood agar medium for identification of the causative agents. Following incubation at optimum temperature (37° C for 24hrs), there was growth on the sorbitol macConkey agar but not on blood agar. Colonies were randomly picked and sub cultured again on nutrient agar (at 37° C for 24hrs) to obtain a pure culture. A gram stain was done from the growths pure culture on Nutrient agar and Gram-negative short rod bacteria were appreciated under microscope X100 objective lens. Finally, it was concluded based on the history, clinical findings, stages of production, management and laboratory findings as *Escherichia coli* caused clinical mastitis.

## Case management and treatment outcome

10% oxytetracycline (Shanghai Thongren Pharmaceutical Co., Ltd, China) at a dose of 10mg/kg for five successive days, IV and dexamethasone (Sokar Healthcare Pvt.Ltd. Gujarat India) at a dose of 0.2mg/kg/day for three days I.M. were arranged based on the tentative diagnosis. Luckily the cow calved on the second-day visit during which the treatment was started. Besides, the drug treatment, the attendant was advised to strip the teat and wash the udder with warm water and discard the dirty cautiously. The attendant was also advised to scrap the stall (especially where the udder rests) on regular basis for all the cows. Post-treatment, fever and local heat on the udder were disappeared whilst the swelling and the seepage were not. Two weeks later, the clotty milk from the affected teat was reduced but not fully disappeared. Besides, the attendant reported that the pain and swelling reduced, the appetite of the animal was resumed to normal. A month later the cow was fully recovered.

## Discussion

Clinical mastitis incurs significant costs to owner related to the costs of diagnosis, treatment (drug costs, milk discard), ongoing production losses from damaged quarters, increased probability of cow death, and increased risk of antibiotic residues in milk. Mastitis caused by *Escherichia coli* is the most common among clinical mastitis in high-producing dairy cows. In

the present case, a late pregnant cow was examined with a clinical case of mastitis. Further, the case was diagnosed as *E.coli* caused mastitis based on the integration of history, clinical signs, stage of production, immediate environment of the cow, and laboratory findings.

The current case of *E.coli* caused mastitis was believed to be associated with the stage of production (physiological) and the poor management system especially the poorly installed sewage system of the farm. In experimentally induced coliform mastitis by Burvenich *et al.* (2004) the dual role of the PMN leukocyte (defense and tissue damage), especially around parturition and during early lactation was highlighted. In addition, Burvenich *et al.* (2003), Lehtolainen (2004), and Vangroenweghe (2004) indicated that the stage of production and the age of the animal greatly influence the clinical response and outcome of *E. coli* mastitis. The severe clinical form of *E. coli* mastitis is evident in older cows, during early lactation and at late pregnancy which is primarily due to diminished numbers of circulating PMN (Polymorphonuclear leukocytes) and compromised immune mechanisms of the cows during the periparturient period. These authors also showed during the periparturient period, the hormonal and metabolic profile of the high-yielding dairy cow undergoes some tremendous changes which are mainly related to the process of calving. Besides, high concentrations of estrogen and to a lesser extent progesterone and cortisol peaks on the day of calving have been shown to decrease blood PMN. Further, the organism (*E. coli*) is ubiquitous in the immediate environment of the animals (Peeler *et al.*, 2000; Hogan and Smith, 2003; Ericsson *et al.*, 2009; Constable *et al.*, 2017) hence contribute to the incidence. Furthermore, the failure of lactoferrin within mammary secretions to prevent new infections and mastitis near and after parturition may be caused by a decrease in lactoferrin before parturition. Lactoferrin normally binds the iron needed by iron dependent organisms such as *E. coli*; the absence may allow the agent to multiply excessively (Constable *et al.*, 2017).

There is no standard treatment for mastitis, but it is advocated that the clinical forms should be treated according to the severity of the udder inflammation (Du Preez, 2000). Treatment of clinical mastitis commonly involves antibiotics and supportive therapy, such as fluids and anti-inflammatory medications. In acute coliform mastitis with fever, a swollen and painful quarter, corticosteroid drug dexamethasone is recommended systemically or directly into the mammary

gland. Systemic effects of the drugs and potential consequences in pregnant animals (dexamethasone) must be considered before administration (NYSCHAP, 2013).

In the current study intramuscular dexamethasone was administered after the cow calved (on the second-day visit). Further, an intravenous therapy with oxytetracycline was managed for five successive days with a remarkable outcome. In accordance, Du Preez, (2000) and MacDiarmid, (2011) indicated the therapeutic effect of intravenous high doses of oxytetracycline (10 mg/kg) and therapeutic levels in milk which is likely to be maintained over a 24-hour period. Although there are controversies in the systemic treatment of clinical mastitis, Erskine (2003) report suggests systemic therapy to be more efficient than IMM route. Theoretically, antimicrobials have better penetration of the udder tissue by systemic route thus it reduces uneven distribution throughout the udder. Besides, in severe coliform mastitis, parenteral administration of antimicrobials has been suggested to combat both bacteremia and heavy *Escherichia coli* bacterial growth in the udder (Wenz *et al.* 2001; Suojala *et al.*, 2013).

In conclusion, *E.coli* mastitis is an environmental form of clinical mastitis having a substantial impact on dairying worldwide. Although prevention aimed at maintaining a clean and dry environment for dairying is of utmost importance, vigorous treatment of affected animals with appropriate drugs is also essential.

#### Limitation

Drug sensitivity tests were not performed for this case due to scarcity of disks.

#### Acknowledgement

I am grateful to Addis Ababa University college of Veterinary medicine, Veterinary Teaching Hospital staff, in particular Dr. Cheru Talila.

## References

- Adane B., Guyo K., Tekle Y., Taddele H., Bogale A., Biffa D. (2012): Study on Prevalence and Risk Factors of Bovine Mastitis in Borana Pastoral and Agro-Pastoral Settings of Yabello District, Borana Zone, Southern Ethiopia. *American-Eurasian Journal of Agriculture & Environmental Science*, **12**: 1274-1281.
- Belayneh R., Belihu K., Wubete A. (2013): Dairy cows mastitis survey in Adama Town, Ethiopia. *Journal of Veterinary Medicine and Animal Health*, **5**: 281-287.
- Bradley A. (2002): Bovine Mastitis: An Evolving Disease. *The Veterinary Journal*, **164**: 116-128.
- Brankol A., Ljupcol M., Ljupcol A., Martin N., Marija R., Dean J., Kiro P., Toni D. (2012): Implementation of Strategies for Mastitis Control in Dairy Herds in Macedonia: A Case Report. *Macedonia Veterinary Review*, **35**: 87-90.
- Burvenich C., Monfarini E., Mehrzad J., Capuco A., Paape M. (2004): Role of neutrophil polymorphonuclear leukocytes during bovine coliform mastitis: physiology or pathology. *Veterinary acadamia Geneeskd Belgium*, **66**: 97-150.
- Burvenich C., Van Merris V., Mehrzad J., Diez-Fraile A., Duchateau L. (2003): Severity of *E.coli* mastitis is mainly determined by cow factors. *Veterinary Research*, **34**: 564.
- Constable P., Morin D. (2003): Treatment of clinical mastitis Using antimicrobial susceptibility profiles for treatment decisions. *Veterinary Clinical and Food Animal*, **19**: 139-155.
- Constable P., Hinchcliff K., Done S., Grundberg W. (2017): *Veterinary Medicine: A Textbook of the Diseases of Cattle, Horses, Sheep, Pigs, and Goats*. UK: Elsevier . 1943 p.
- Du Preez J. (2000): Bovine mastitis therapy and why it fails: Continuing education. *Journal of the South African Veterinary Association*, **71**: 201-208.
- Ericsson U., Lindberg A., Persson W., kman T., Artursson K., Nilsson M., Bengtsson B. (2009): Microbial aetiology of acute clinical mastitis and agent-specific risk factors. *Veterinary Microbiology*, **137**: 90-97.
- Erskine R., Bartlett P., VanLente J., Phipps C. (2002): Efficacy of systemic ceftiofur as a therapy for severe clinical mastitis in dairy cattle. *Journal of Dairy Science*, **85**: 2571-2575.
- Goodman, G. (2001): Goodman and Gilman's the pharmacological basis of therapeutics. Macmillan, cop. 1985, New York *et al*.

- Hogan J., Smith K. (2003): Coliform mastitis. *Veterinary Research*, **34**: 519.
- Lehtolainen, T. (2004): *Escherichia coli* mastitis. Bacterial factors and host response [dissertation]. Helsinki.
- MacDiarmid S. (2011): Antibacterial drugs used against mastitis in cattle by the systemic route. *New Zealand Veterinary Journal*, **26**: 290-295.
- NYSCHAP (2013): New York State Cattle Health Assurance Program; Mastitis Module. Veterinary Resource. Mastitis Therapy: A Systematic Approach.
- Peeler E., Green M., Fitzpatrick J., Morgan K., Green L. (2000): Risk Factors Associated with Clinical Mastitis in Low Somatic Cell Count British Dairy Herds. *Journal of Dairy Science*, **83**: 2464-2472.
- Pieterse R., Todorov S. (2010): Bacteriocins: exploring alternatives to antibiotics in mastitis treatment. *Brazilian Journal of Microbiology*, **41**: 542-562.
- Plummer P., Plummer C. (2012): Chapter 15 - Diseases of the Mammary Gland. In: Baird AN, editors. *Sheep and Goat Medicine (Second Edition)*. Saint Louis: W.B. Saunders. pp. 442-465.
- Quinn P., Markey, B., Leonard, F., Fitzpatrick, F., Fanning, S. (2016): *Concise Review of Veterinary Microbiology*. The Atrium, Southern Gate, Chichester, West Sussex, PO19 8SQ, UK: John Wiley & Sons Ltd. 142 p.
- Roberson J. (2012): Treatment of clinical mastitis. *Veterinary Clinician in North America and Food Animal Practice*, **28**: 271-288.
- Suojala L., Pyorala S., Kaartinen L. (2013): Treatment for bovine *Escherichia coli* mastitis - an evidence-based approach. *Journal of Peterinary Pharmacology and Therapeutics*, **36**: 521-531.
- Vangroenweghe, F. (2004): Experimentally induced *Escherichia coli* mastitis in lactating primiparous cows [dissertation]. Gent University.
- Wenz J., Garry F., McSweeney K., Dinsmore R., oodell G., Callan R. (2001): Bacteremia associated with naturally occurring acute coliform mastitis in dairy cows. *Journal of Animal science and Veterinary Medicine Association*, **219**: 977-981.

#### 4.1.6. Hemorrhagic septicemia and its treatment outcome in a bull

##### Abstract

Hemorrhagic septicemia occurrence in cattle is endemic in most tropical areas and incurred severe economic losses to smallholder farmers. A bull with edema under the jaw, dewlap and brisket region, and serous unilateral nasal discharge was examined at Addis Ababa University College of veterinary medicine, Veterinary Teaching Hospital, Bishoftu on January 13/2018. A nasal swab submitted for bacteriological culture revealed that the bull was suffering from Hemorrhagic septicemia (HS) caused by *Pasteurella multocida*. Rigorous therapy with Penstrip at a dose of 1ml/20kg/day for five days coupled with Dexamethasone 0.2mg/kg/day for three days both IM were successfully cured the bull. Therefore, immediate interventions with appropriate drugs are significant in reducing the losses due to Hemorrhagic septicemia.

**Keywords:** *Bull; Hemorrhagic septicemia; Pasteurella multocida; Treatment*

##### Introduction


Hemorrhagic septicemia (HS) is an acute, highly fatal form of pasteurellosis that affects mainly cattle and buffaloes and caused by a Gram-negative coccobacillus bacterium *Pasteurella multocida* residing mostly as a commensal in the nasopharynx of animals. It is primarily associated with *Pasteurella multocida* serotypes B: 2 and E: 2 in Asia and Africa, respectively (Moustafa *et al.*, 2017; OIE, 2013; Shivachandra *et al.*, 2011). HS is the most economically imperative disease of cattle in tropical areas, particularly it is overwhelming to smallholder farmers where husbandry and preventive practices are poor and free-range management is common. Radical changes in weather, debility caused by a seasonal level of low nutrition, close confinement, and work pressure are some of the predisposing factors which ignite the occurrence of the HS disease (Brenda and Mengfei, 2013; Farooq *et al.*, 2011).

*Pasteurella multocida* possesses a number of virulence factors which is responsible for the clinical cases including: capsule, fimbriae, and adhesions; outer membrane proteins (OMPs); endotoxin (lipopolysaccharide [LPS]); siderophores; and a number of extracellular enzymes.

Among these Endotoxin appears to be the most important virulence factor responsible for clinical disease. LPS of serogroups B and E were found to be identical (Constable *et al.*, 2017). The disease is characterized by the sudden upsurge in body temperature, anorexia, depression, edematous swelling on throat, brisket and dewlap region, dyspnea, nasal discharge, salivation and reluctance to move (Biswas *et al.*, 2004; Constable *et al.*, 2017; Farooq *et al.*, 2011). Cattle can only survive if immediate interference ensues as soon the condition is appreciated, however in most instances animals may die because early detection and effective treatment needs regular follow up. Although recent reports are indicating the presence of multiple drug resistance, different works of literature stated antibiotics such as streptomycin, oxytetracycline, penicillin, sulfonamides, tetracycline, chloramphenicol, and ampicillin are effective against *Pasteurella multocida* if managed promptly with high dose (Karunasree, 2016; Kehrenberg *et al.*, 2001; Yami Bote *et al.*, 2017). Therefore, the current work describes clinical case of HS and its treatment outcome.

#### Case description

A crossbred bull from Filtino peasant association, Ada'a was examined at AAU-CVMA-VTH, Bishoftu on January 13/2018 with the history of reduced feed intake, swelling under the jaw, shivering, and straining in an attempt to defecate. The owner reported that two of his cattle died previously with similar symptoms after they had been treated with unknown drugs at home. The animals were managed semi-intensively and kept for agricultural works. Upon physical examination; the bull was slightly febrile with a rectal body temperature of 39.8 °C, and has 64 beats/min and 36 breaths/min heart rates and respiratory rates, respectively. The bull has got edema under the jaw (Figure 10c), dewlap and brisket region (Figure 10a&b) which was clear and water like up on aspiration. There were serous unilateral nasal discharge (Figure 10d), congestion of conjunctival mucus membrane, muscle tremor, tenesmus in attempt to defecate and diarrhea. Based on the history, clinical findings and similar cases previously visited the clinic; it has been diagnosed tentatively as Hemorrhagic septicemia.



**Figure 10:** Picture representing clinical case of HS with edema at different area of the neck (a, b& c, arrows) and unilateral nasal discharge (d, arrow).

#### Laboratory investigation and findings

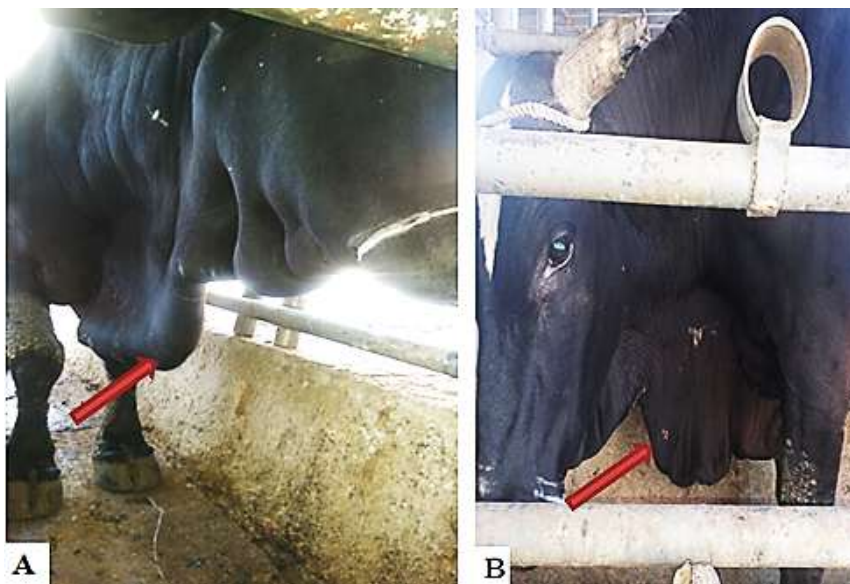The nasal swab was collected after external part of the nose disinfected. A sterile cotton-tipped swab inserted into the nostril and rotated against the wall of the nasal cavity. The swab then placed in the labeled sterile test tube that contains 3 ml of tryptose Soya broth and immediately submitted to Addis Ababa University College of Veterinary Medicine Microbiology laboratory and incubated at 37°C for 24hrs. The next day a loop full of the broth cultures were taken and streaked over macConkey agar and blood agar medium with 7ml of sheep blood. After 24hrs of incubation at 37° C, there was growth on blood agar medium but not on the macConkey agar medium (annex 4). A round, greyish and non-haemolytic colonies were appreciated. A smear was prepared for gram's staining and short rod gram negative bacteria were appreciated under X100 microscope. Biochemical tests were also performed. The bacterium produces indole. It was concluded that the bacterium was *Pasteurella multocida* based growth pattern (no growth on the

macConkey agar medium and no hemolysis on blood agar medium).and biochemical test results (indole production).

Finally, based on the summative result of history, clinical and laboratory findings the case was confirmed as hemorrhagic septicemia caused by *Pasteurella multocida*.

#### Case management and treatment outcome

The treatment regimen was arranged with the aim of deterring further effect of the agent and reducing inflammatory effects. Therefore, penstrip (combination of procaine penicillin and Dihydrostreptomycin) (Chongqing Fantong Animal Pharmaceutical Co.Ltd, China) at a dose of 1ml/20kg/day for five successive days coupled with Dexamethasone (Sokar Healthcare Pvt.Ltd. Gujarat India) 0.2mg/kg/day for three days were administered IM. On the 5<sup>th</sup> day visit, the bull recommenced to its normal state and the edema was disappeared (Figure 11B). Three weeks later the owner reported that the bull was fully recovered and started working.



**Figure 11:** Comparative picture specifying the bull during 1<sup>st</sup> day visit (A, arrows) and 5<sup>th</sup> day visit (B, arrows)

## Discussion

Hemorrhagic septicemia occurrence in cattle is endemic in most parts of Ethiopia which have incurred a severe economic loss to poor livestock farmers where cattle are abundant and vital for draught power and milk production (Gemeda *et al.*, 2016). *Pasteurella multocida* remains a commensal in different parts of the lungs but the pathogen cannot cause disease without stressors due to the defense mechanism. The Organisms are capable of destructing bovine blood mononuclear leukocytes and lung macrophages. Pharmacologically active substances like histamine, prostaglandins, hyaluronidase, chondroitinase (inflammatory substances) as well as fibro-elastic elements are released with the death of the macrophages. In addition, the organism is capable to cause septicemia once the immunity suppressed which has the most severe effect on the respiratory tract, heart and gastrointestinal tract (Constable *et al.*, 2017). An acute inflammatory reaction takes place in the trachea following the release of active substances leads to the development of submandibular edema in addition to severe changes in the lungs. Besides, *Pasteurella multocida* produces endotoxins which are responsible for all the manifestations (Jibachha, 2011).

The present case of HS was supposed to have correlation with exhaustion from work overload and relatively cold weather condition of the season during the case was examined which is in line with the findings of Brenda and Mengfei (2013), Farooq *et al.* (2011), Jibachha (2011) and Mitra *et al.* (2013) which indicates exhaustion from workload, transport, successive change in nutrition, management and temperature changes of seasons and mode of husbandry plays persuasive role in the occurrence of HS. Similar to the present instance, the disease is manifested by depression, pyrexia, abdominal pain, edema in different regions of the body (submandibular, dewlap and brisket) and dyspnea (Khan, 2012; Mitra *et al.*, 2013; Naz *et al.*, 2012; Odugbo *et al.*, 2005), unlike current case, the ailment may sequel in severe pneumonic changes to lungs, recumbency and death within few days unless instantly intervened.

Mitra *et al.* (2013) and Gemeda *et al.* (2016) reports indicate recovery from the clinical disease of HS occurs only if the animals are treated in the very early stages, which are often impossible under field conditions. Besides, the agents are evolving resistance to multiple antibiotic drugs to

which they are previously susceptible which can also significantly influence recovery. In addition, the agent (*Pasteurella multocida*) is endowed with capsule and LPS which shelter them from phagocytosis and allow bacterial survival in the animal (Karunasree, 2016; Yami Bote *et al.*, 2017). However, in the present instance, the owner present the bull soon following the death of two of his cattle with similar conditions thus immediate intervention made with penstrip intramuscularly for five successive days and dexamethasone for three days were produced successful recovery.

In conclusion, Hemorrhagic septicemia is a significant disease of cattle in most tropical countries of the world with enormous economic loss particularly to smallholder farmers. In most cases of the condition, stressors plays paramount role. Unless opportune therapy of antibiotic and anti-inflammatory is directed, most cases of HS end up with death. Therefore, reducing workload and ensuring good management practice may reduce the incidence of the case.

#### Limitations

Drugs sensitivity tests were not performed for this case due to scarcity of disks which is helpful in selecting the most effective drug than the one used currently.

#### Acknowledgements

I am grateful to Addis Ababa University College of Veterinary medicine, Veterinary Teaching Hospital and Microbiology staffs; in particular, Dr. Cheru Talila, Mr. Dereje Gudeta, Ms. Tsedale and Mr. Abebe for their contribution. And also, the owner of the animal for his valuable information during the follow up.

## References

- Brenda A., Mengfei H. (2013): *Pasteurella multocida*: from Zoonosis to Cellular Microbiology. *American Society for Microbiology*, **26**: 631-655.
- Biswas A., Shivachandra S., Saxena M., Kumer A., Singh V., Srivastava S. (2004): Molecular Variability of among Strains of *Pasteurella multocida* Isolated from an Outbreak of Hemorrhagic Septicemia in India. *Veterinary Research Communication*, **28**: 287-298.
- Constable P., Hinchcliff K, Done S., Grundberg W. (2017): *Veterinary Medicine: A Textbook of the Diseases of Cattle, Horses, Sheep, Pigs, and Goats*. UK: Elsevier . 2040 p.
- Farooq U., Saeed Z., Khan M., Ali I., Qamar M. (2011): Sero-Surveillance of Hemorrhagic Septicemia in Buffaloes and Cattle in Southern Punjab, Pakistan. *Pakistan veterinary Journal*, **31**: 254-256.
- Gemeda F., Taddese D., Shumi E. (2016): Creation of Public Awareness in Hemorrhagic Septicemia, in and around Jimmaa areas, South Western part of Ethiopia. *Journal of Harmonized Research*, **3**: 38-43.
- Jibachha S. (2011): Hemorrhagic Septicemia (HS). [https://www researchgate net/publication/308322100](https://www.researchgate.net/publication/308322100) .
- Karunasree P. (2016): A Brief Study on Hemorrhagic Septicemia. *Research and Reviews: Journal of Veterinary Sciences*, **2**: 30-37.
- Kehrenberg C., Salmon S., Watts J., Schwarz S. (2001): Tetracycline resistance genes in isolates of *Pasteurella multocida*, *Mannheimia haemolytica*, *Mannheimia glucosida* and *Mannheimia varigena* from bovine and swine respiratory disease: intergeneric spread of the tet(H) plasmid pMHT1. *Journal of Antimicrobial Chemotherapy*, **48**: 640.
- Khan F. (2012): Field epidemiology of an outbreak of hemorrhagic septicemia in dromedary population of greater Cholistan desert (Pakistan). *Pakistan veterinary Journal*, **3**: 31-34.
- Mitra J., Chowdhury M., Bhattacharya C. (2013): Outbreak of Hemorrhagic Septicemia in Free Range Buffalo and Cattle Grazing at Riverside Grassland in Murshidabad District, West Bengal, India. *Explore Animal Medicine Research*, **3**: 178-182.
- Moustafa A., Ali S., Bennet M., Hyndman T., Robertson I., Edwards J. (2017): A Case-control Study of Haemorrhagic Septicaemia in Buffaloes and Cattle in Karachi, Pakistan, in 2012. *Transboundary and Emerging diseases*, **64**: 527.

- Naz S., Hanif A., Maqbool A., Ahmad S., Muhammand K. (2012): Isolation, Characterization and Monitoring of Antibiotic Resistance in *Pasteurella Multocida* Isolates from Buffalo (*Bubalus Bubalis*) Herds around Lahore. *The Journal of Animal and Plant Sciences*, **22**: 242-245
- OIE (2013): World Organization for Animal Health. Haemorrhagic Septicemia: Aetiology Epidemiology Diagnosis Prevention and Control References. [http://www oie int/fileadmin/Home/eng/Animal\\_Health\\_in\\_the\\_World/docs/pdf/Disease\\_cards/Accessed](http://www.oie.int/fileadmin/Home/eng/Animal_Health_in_the_World/docs/pdf/Disease_cards/Accessed) February 14, 2018 .
- Odugbo M. O., Turaki U. A., Itodo A. E., Okwori A. E. J., Yakubu R. A. (2005): Experimental Hemorrhagic Septicemia of Calves with *Pasteurella multocida* Serotype E:2: Clinical, Pathologic and Microbiologic Studies. *Veterinary Tropical Medicine Review*, **58**: 133-137.
- Shivachandra S. B., Viswas K. N., Kumar A. A. (2011): A review of hemorrhagic septicemia in cattle and buffalo. 67-82.
- Yami Bote, Legesse K., Tassew A. (2017): Isolation, identification and antimicrobial susceptibility of *Pasteurella multocida* from cattle with hemorrhagic septicemia in Assosa and Bambasi districts, Benishangul Gumuz Regional State, Ethiopia. *International Journal of Animal Research*, **4**.

#### 4.1.7. Black leg in a bull: Symptomatic therapy

##### Abstract

Black leg is an acute bacterial disease of ruminants which is characterized by swollen, hot and painful wound affecting mostly the hind limb. The present study reports, the case of black leg in bull and its treatment outcome. A local breed bull with the history of reduced feed intake, shivering and unable to walk was examined. According to the owner the condition happened at the morning before presentation. Up on physical examination the rectal body temperature (40.8°C) and heart rate (100beats/min) were higher. There was lacrimation (bilateral), lameness, muscle tremor and congested conjunctival mucus membrane. The case was managed with procaine penicillin G (20,000 IU/kg/day) for five consecutive days and dexamethasone (0.2mg/kg/day) for three days both intramuscularly. The bull was successfully cured at the end of the therapy. Although early intervention with appropriate drug could cure the animal, the better option to control the disease would be getting the animals vaccinated against black leg.

**Keywords:** *Bull; Black leg; Symptomatic*

##### Introduction

Blackleg is a fatal form of myonecrosis caused by anaerobic, highly pathogenic, endospore-forming, gram-positive bacterium *Clostridium chauvoei*. It is usually observed in young ruminants and responsible for significant loss in livestock production globally (Useh *et al.*, 2006; Frey and Falquet, 2015; Quinn *et al.*, 2016). Although blackleg vaccination has been carried out in endemic countries, sporadic outbreaks are still recorded annually worldwide. The disease is commonly affects young flourishing cattle from three months to two years of age. Latent spore of *Clostridium chauvoei* is thought to be activated through traumatic injury but more localized clostridial myositis can be iatrogenic. *C. chauvoei* is assumed to be soil borne, but likely does not grow in soil. The bacteria grow readily in the intestinal tract of cattle, and may be recycled through fecal contamination of the soil. Most cases of blackleg occur during the warm months, or after soil excavation, or during very high annual rainfall that can expose and activate latent

spores. In addition, the disease is enzootic in areas with a history of flooding (Useh *et al.*, 2006; Huang *et al.*, 2013).

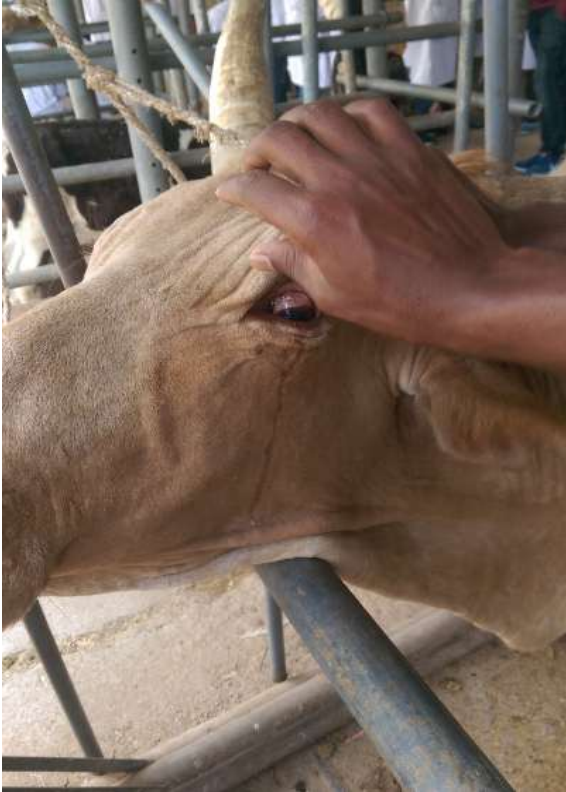The severity of blackleg is ignited by the toxin produced by the bacterium including an oxygen-stable haemolysin, an oxygen-labile haemolysin, a DNase ( $\beta$ -toxin), a hyaluronidase (previously called  $\gamma$ -toxin), and a neuraminidase (Uzal, 2012; Quinn *et al.*, 2016). The incubation period of the disease is between 1–5 days (Useh *et al.*, 2006). The clinical forms are per acute, which is so short-lived and usually not observed because of sudden death (Singh *et al.*, 1993). Acute form is commonly manifested by edema of the heavy muscles and crepitation, lameness and fever ( $41^{\circ}$  C)(Useh *et al.*, 2006); (Constable *et al.*, 2017). Other unusual findings such as fibrinous pleuritis, pericarditis, epicarditis (Daly *et al.*, 2009), and severe acute necrotizing enteritis (Harwood *et al.*, 2007) as well as the highly uncommon meningoencephalitis (Malone *et al.*, 1986; Ziech *et al.*, 2018) are also reported.

Diagnosis of these infections can be made based on clinical picture and postmortem findings. *C. chauvoei* is facultative, anaerobic gram-positive cocci. Anaerobic culture of sections of affected muscle or fluid from the lesion may be employed to identify the causative organism. The bacterium, however, is quite fastidious in its growth requirements. Also, affected tissue is often rapidly overgrown with other clostridial contaminants from the gastrointestinal tract further complicating culture of the causative organism (Constable *et al.*, 2017). The use of direct polymerase chain reaction (PCR) was proposed by (Farias *et al.*, 2012) using common filter paper as an alternative to collecting, storing, and shipping material to the laboratory for the diagnosis of blackleg. Penicillin are a drug of choice in the clinical management of blackleg (Constable *et al.*, 2017). Annual vaccination of cattle between 6 months and 2 years of age is advocated in areas where the disease is enzootic, just prior to the anticipated danger period.

#### Case description

A local breed bull from Bekejo was brought to AAU-CVMA-VTH in February 19/2018 with the history of reduced feed intake and shivering. According to the owner the condition happened at the morning before presentation during which the bull was refused to eat and unable to walk. Physical examination revealed higher rectal body temperature ( $40.8^{\circ}$  C) and heart rate (100

beats/min). There was lacrimation (bilateral,), lameness, muscle tremor and congested conjunctival mucus membrane (figure 1). The bull has got good body condition and other abnormalities were unremarkable. Therefore, based on the history and clinical findings black leg was established tentatively although other acute cases were doubted.



**Figure 12:** Congestion and lacrimation

#### Case management and treatment outcome

The bull was managed with procaine penicillin G (EPHARM, Addis Ababa, Ethiopia) at a dose of 20,000 IU for five consecutive days and dexamethasone at a dose of 0.2mg/kg/day for three consecutive days both intramuscularly. On the 2<sup>nd</sup> day visit both the rectal body temperature and heart rates were reduced to 39.2° C and 80beats/ min, respectively whilst appetite were not improved (the owner reported). However on the 3<sup>rd</sup> day of therapy, rectal body temperature and heart rates were returned to normal (38.2<sup>o</sup>C and 72beats/min, respectively). At the end of therapy the bull was fully recovered (figure 13).



**Figure 13:** The status of the bull on the 5th day

## Discussion

Black leg is endemic in Ethiopia and cause overwhelming economic loss in small holder farmers which is associated with death, losses in production and reduction in working capacity of farm animals. The current case was asserted as black leg tentatively based on the history and clinical findings (symptomatic) which is similar with symptoms specified in literatures (Useh et al., 2006), (Daly et al., 2009) and (Malone et al., 1986; Ziech et al., 2018). Accordingly, marked lameness with pronounced swelling of the affected limbs, marked depression, anorexia, ruminal stasis, high pulse rate (100–120/min), high temperature (41° C), marked respiratory distress, emphysema and crepitation of affected heavy muscles are usual in acute form of black leg. DNase ( $\beta$ -toxin) and hyaluronidase (called  $\gamma$ -toxin) toxins are greatly responsible for the pathogenesis of the disease. DNase ( $\beta$ -toxin) is an enzyme of the deoxyribonuclease and responsible for the nuclear degradation of muscle cells and actively participates in clostridial myonecrosis. While, hyaluronidase toxin is assumed to be responsible for the destruction of the loose connective tissue that surrounds the muscles, thus favoring the spread of *C. chauvoei* in the tissues of the infected and the end products of hyaluronate degradation are disaccharides, which might be a source of nutrients for the pathogen (Ziech *et al.*, 2018).

The present case was treated successfully with procaine penicillin G at 20,000 IU for five successive days coupled with dexamethasone (0.2mg/kg/day) to reduce pain and fever. The improvement was noted forty eight hours post treatment which is in agreement with a case reported by Nazir Zahid et al. (2012) and Datta and Karmakar (2017).

Black leg is a cause of considerable losses in cattle production industries in terms of production loss and death of the animal. Although early intervention with appropriate drug could cure the animal, the better option to control the disease would be getting the animals vaccinated against black leg.

#### Limitation

No laboratory confirmation was made for this disease due to lack of facilities and hence treatment was done based on clinical picture only (symptomatic therapy).

#### Acknowledgement

I am grateful to Addis Ababa University college of Veterinary medicine, Veterinary Teaching Hospital staffs.

#### References

- Constable P., Hinchcliff K., Done S., Grundberg W. (2017): Veterinary Medicine: A Textbook of the Diseases of Cattle, Horses, Sheep, Pigs, and Goats. UK: Elsevier . 1591 p.
- Daly R., Miskimins D., Good R., Stenberg T. (2009): Blackleg (Clostridium chauvoei Infection) in Beef Calves: A Review and Presentation of Two Cases with Uncommon Pathologic Presentations. *Bovine Practitioner*, **43**: 153.
- Datta S., Karmakar U. (2017): Black Quarter in a Cow: A Case Report. *Exploratory Animal and Medical Research* **7**: 113-115.
- Farias L., Avila S., Costa M., Vargas A. (2012): Molecular identification of Clostridium chauvoei from common filter paper. *Acta Scientiae Veterinariae*, **40**: 01-05.
- Frey J., Falquet L. (2015): Patho-genetics of Clostridium chauvoei. *Research in microbiology* **166**: 384-392.

- Harwood D., Higgins R., Aggett D. (2007): Outbreak of intestinal and lingual *Clostridium chauvoei* infection in two-year-old Friesian heifers. *Journal of veterinary record*, **161** (9):307-8.
- Huang S., Chan J., Shia W., Shyu C., Tung K., Wang C. (2013): The utilization of a commercial soil nucleic acid extraction kit and PCR for the detection of *Clostridium tetanus* and *Clostridium chauvoei* on farms after flooding in Taiwan. *Journal of Veterinary Medical Science* **75**: 489-495.
- Malone F., McParland P., O'hagan J. (1986): Pathological changes in the pericardium and meninges of cattle associated with *Clostridium chauvoei*. *The Veterinary Record*, **118**: 151-152.
- Nazir Zahid U., Kumar S., Randhawa S., Randhawa S., Hassan N. (2012): Black Quarter in crossbred dairy cattle-A Case Report. *Veterinary World*, **5**.
- Quinn, P. J., Markey, B. K., Leonard, F. C., Fitzpatrick, F. S., and Fanning, S. (2016): Concise Review of Veterinary Microbiology. The Atrium, Southern Gate, Chichester, West Sussex, PO19 8SQ, UK: John Wiley & Sons Ltd. 142 p.
- Singh K., Parihar N., Charan K., Tripathi B. (1993): Haematological and biochemical alterations in hill bulls infected with *Clostridium chauvoei*. *Acta Veterinaria Brno*, **62**: 89-94.
- Useh N., Ibrahim N., Nok A., Esievo K., Schnabl B., Bettenay S., Dow K., Mueller R., Xu J., Hofhuis H. (2006): 1195901. Relationship between outbreaks of blackleg in cattle and annual rainfall in Zaria, Nigeria. *The Veterinary Record*, **158**: 100-101.
- Uzal F. (2012): Evidence-based medicine concerning efficacy of vaccination against *Clostridium chauvoei* infection in cattle. *Veterinary Clinics: Food Animal Practice*, **28**: 71-77.
- Ziech R., Gressler L., Frey J., Vargas A. (2018): Blackleg in cattle: current understanding and future research needs. *Clinicia Rural*, **48**.

#### 4.1.8. Unidentified hemoglobinuria in a bull

##### Abstract

A local breed bull was presented to Veterinary Teaching Hospital of Addis Ababa University College of Veterinary Medicine and Agriculture, Bishoftu from Filtinno peasant association, Ada'a woreda on February, 19/2018. According to the owner, one day prior to presentation, the bull starts urinating blood. The bull was kept semi-intensively with other animals and fed household remnants and "frushka". Sometimes they were grazing around water bodies to which sewage from jeans factory was released. Upon physical examination, the bull had rectal body temperature of 38.9°C, pronounced pulsation, dark purple or red "port wine like" urine and pale conjunctival mucus membrane. Straining in attempt to defecation was also appreciated. Based on the history and clinical findings, lists of differential diagnosis were made including babesiosis, anaplasmosis, bacillary hemoglobinuria, brakenfern poisoning and cystitis. Blood and urine samples were examined, hematuria and intravascular hemolysis caused by hemoparasites were excluded but the cause of hemoglobinuria was not identified. The bull was treated with anti-protozoan, antibiotic and supportive therapy with no satisfactory outcome during the three successive treatments rather the condition worsening. The 4<sup>th</sup> and 5<sup>th</sup> treatment regimens missed because the bull was slaughtered. Based on the findings (laboratory and treatment outcome), the case was supposed to be a non-infectious caused hemoglobinuria rather than infectious. However, further laboratory diagnosis was not performed.

**Keywords:** *Bull; Hemorrhage*

##### Introduction

Hemoglobinuria is the presence of hemoglobin in the urine (Sara, 2012). A variety of conditions are responsible for urine discoloration to a red/black or brown color. This may be an indication of other systemic disease and where hemoglobin or myoglobin is present; unless treated promptly, it may sequel to acute renal failure (Archer, 2013). In hemoglobinuria the urine appear deep red to brown coloration and gives a positive reaction to biochemical tests for hemoglobin and there is no erythrocyte debris in the sediment. This is principally associated with marked intravascular

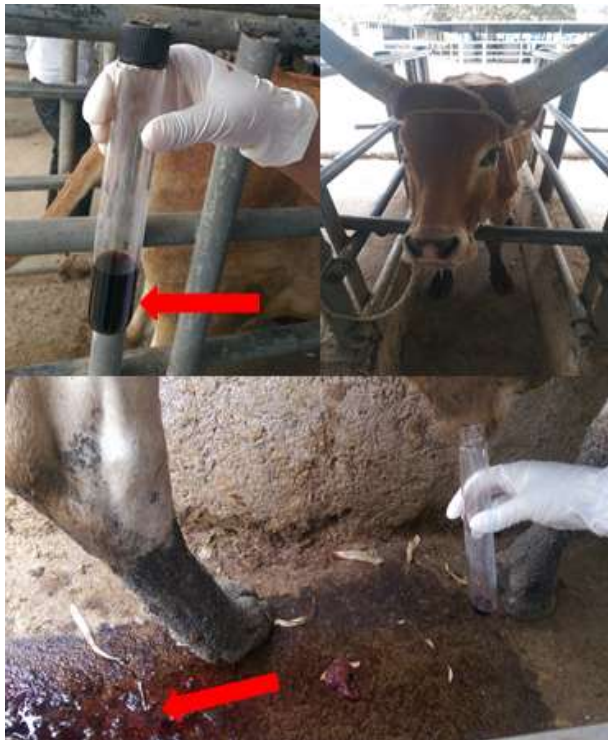hemolysis subsequently exceeded the renal threshold for hemoglobin. The causes are multifold and includes water intoxication (common in calves), hypotonic IV fluids, Bacillary hemoglobinuria caused by *Clostridium hemolyticum*, leptospirosis in calves, babesiosis, and postparturient hemoglobinuria; Plants and heavy metal toxicities as well (Divers, 2008; Constable *et al.*,2017). Bacillary hemoglobinuria is characterized clinically by intravascular hemolysis with anemia and hemoglobinuria. It is caused by *Clostridium haemolyticum* and common in cattle and sheep. The disease is mostly associated with a focus of hepatic injury due to *Fasciola hepatica* within which latent spores can germinate (Cullen and Stalker, 2016). It is rare on dry, open range country but does occur in range country where cattle have access to swales with areas naturally irrigated by springs or streams. The disease can be spread by flooding, natural drainage, contaminated hay from infected areas, or carrier animals (Constable *et al.*, 2017). Babesiosis is also significant tick-borne infectious disease of cattle characterized by febrile hemoglobinuria and anemia which is caused by intra-erythrocytic protozoan parasites of the genus *Babesia* (Vannier and Krause, 2013). The diagnosis of babesiosis can be made with a peripheral blood smear. Once the peripheral smear is obtained, the intra-erythrocytic organism may be seen. The direct method of identifying the parasite in Giemsa-stained blood smears is gold standard test for diagnosis of babesiosis however, low in sensitivity in subclinical and chronic phase of the infection (Bal *et al.*, 2016).

Generally, to differentiate hemoglobinuria from myoglobinuria and hematuria, which all have a positive blood test on a urine dipstick, evaluate the color of the supernatant after centrifugation of the urine; hematuria will have a clear supernatant, whereas hemoglobinuria and myoglobinuria will not. To differentiate hemoglobinuria from myoglobinuria, evaluate the plasma color; hemoglobinuria will have a pink to red plasma color, whereas myoglobinuria will not (Sara, 2012).

### Case description

A local breed bull was presented to AAU-CVMA-VTH from Filtinno peasant association, Ada'a woreda in February, 19/2018. One day prior to presentation, the bull starts urinating blood and was brought to the hospital. The bull was kept semi-intensively with other animals and fed house

hold remnants and “frushka”. Sometimes they were grazing around water bodies to which sewage from jeans factory was released. Upon physical examination, the bull had rectal body temperature of 38.9°C, pronounced pulsation, dark purple or red “port wine like” urine (figure 14) and pale conjunctiva mucus membrane. Straining in attempt to defecation was also appreciated. Based on the history and clinical findings, lists of differential diagnosis were made including babesiosis, anaplasmosis, bacillary hemoglobinuria, brakenfern poisoning and cystitis. Among them babesiosis was tentatively diagnosed.

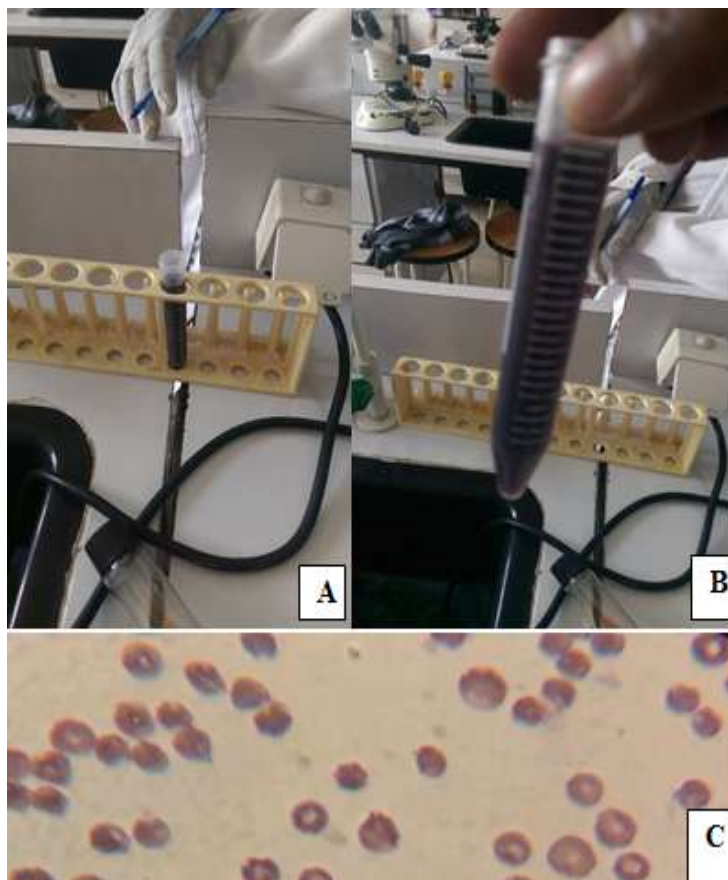


**Figure 14:** indicating bloody urine

#### Laboratory investigation and findings

Blood and urine samples were collected and different laboratory procedures followed. The urine sample was centrifuged (at 5000 rpm for five min) but sedimentation wasn't witnessed (failure of the urine to clear with centrifugation) (figure 15C). The direct method of identifying the parasite in Giemsa-stained blood smears was also performed (according to the protocol) but parasites were not detected (figure 15D). PCV and hemoglobin concentrations were assessed and indicated hypochromic anemia due to severe decrease in PCV (18%) and Hgb concentration (7g/dl). Based

on the results (failure of the urine to sediment and absence of blood parasite) hematuria and intravascular hemolysis caused by hemoparasites were excluded from the lists of differential diagnosis but the cause of hemoglobinuria (increased erythrocyte destruction) was not identified.



**Figure 15:** representing bloody urine (A, before centrifuged), after centrifuged (B) and Giemsa stained blood smear(C)

#### Case management and treatment outcome

The bull was treated on the basis of tentative diagnosis with antibiotic, antiprotozoal and supportive therapy. The treatment protocol was managed as follows: 10% oxytetracycline (Shanghai Thongren Pharmaceutical Co., Ltd, China) was administered at a dose of 10mg/kg (1ml/10kg/day) for five successive days IV (the first two days) and IM, while diminazine acetate (Diminol, Korea) was administered at 5ml/100kg/day once IM. Multivitamins were also given at a dose of 15ml per animal once IM. Until the third day therapy no satisfactory outcome

was seen rather the condition worsening. The 4<sup>th</sup> and 5<sup>th</sup> day's therapy were missed because the bull was slaughtered.

## Discussion

There are several cause of hemoglobinuria including babesiosis, bacillary hemoglobinuria and leptospirosis. Physiologically, hemoglobin liberated from circulating erythrocytes is converted to bile pigments in the cells of the reticuloendothelial system. If hemolysis exceeds the capacity of this system to remove the hemoglobin, it accumulates in the blood until it exceeds a certain renal threshold and then passes into the urine. Some hemoglobin is reabsorbed from the glomerular filtrate by the tubular epithelium but probably not in sufficient amounts to appreciably affect the hemoglobin content of the urine (Constable *et al.*, 2017). In the current condition the bull with bloody urine was examined and urine centrifugation, blood Hgb concentration and PCV were indicated the presence of hemoglobinuria. In addition, convectional Giemsa staining technique for hemoparasites was negative and hence hematuria and hemoparsites were omitted from the lists of differential diagnosis. Besides, treatment with diminazine aceturate and oxytetracycline were unsatisfactory. However, further laboratory diagnoses were not performed for the suspected bacterial causes particularly leptospirosis and bacillary hemoglobinuria. Bacillary hemoglobinuria (BH) is usually fatal disease in cattle however, early stage treatment with oxytetracycline provide successful recovery (Takagi *et al.*, 2009; Navarro *et al.*, 2017). Therefore, based on the findings (laboratory and treatment outcome), the case was supposed to be a non-infectious caused hemoglobinuria rather than infectious.

## Limitation

Further laboratory diagnoses for the identification of other possible causative agents were not performed due to lack of facilities.

## Acknowledgement

I am grateful to Addis Ababa University college of Veterinary medicine, Veterinary Teaching Hospital staff, and pathology laboratory staff.

## References

- Archer D. (2013): Chapter 9 - Urinary tract emergencies. In: Handbook of Equine Emergencies. W.B. Saunders. pp. 176-184.
- Bal S., Mahajan V., Filia G., Kaur P., Singh A. (2016): Diagnosis and management of bovine babesiosis outbreaks in cattle in Punjab state. *Veterinary World*, **9**: 1370-1374.
- Constable P., Hinchcliff K., Done S., Grundberg, W. (2017): *Veterinary Medicine: A Textbook of the Diseases of Cattle, Horses, Sheep, Pigs, and Goats*. UK: Elsevier . 1591 p.
- Cullen J. M., Stalker M. J. (2016): Chapter 2 - Liver and Biliary System. In: Pathology of Domestic Animals: Volume 2 (Sixth Edition). W.B. Saunders. pp. 258-352.
- Divers T. J. (2008): Chapter 10 - Urinary Tract Diseases. In: Rebhun's Diseases of Dairy Cattle (Second Edition). Saint Louis: W.B. Saunders. pp. 447-466.
- Navarro M., Dutra F., Briano C., Romero A., Persiani M., Freedman J., Morrell E., Beingesser J., Uzal F. (2017): Pathology of Naturally Occurring Bacillary Hemoglobinuria in Cattle. *Veterinary pathology* **54**: 457-466.
- Sara H. (2012): Hemoglobinuria. In: Clinical Veterinary Advisor. Saint Louis: W.B. Saunders. pp. 938-939.
- Takagi M., Yamato O., Sasaki Y., Mukai S., Fushimi Y., Yoshida T., Mizukami K., Shoubudani T., Amimoto K., Chuma T. (2009): Successful treatment of bacillary hemoglobinuria in Japanese Black cows. *Journal of Veterinary Medical Science* **71**: 1105-1108.
- Vannier E., Krause P. (2013): 100 - Babesiosis. In: Hill DR, Solomon T, Ryan ET, editors. Hunter's Tropical Medicine and Emerging Infectious Disease (Ninth Edition). London: W.B. Saunders. pp. 761-763.

## **4.2. Case reports on ovine**

### 4.2.1. Coccidiosis in a lamb

#### Abstract

Coccidiosis is an intestinal protozoan parasitic disease and it is one of the major constraints to sheep producing countries worldwide. This case report describes the clinical case of ovine coccidiosis. A 6-month-old lamb was examined on December 13, 2017, at Veterinary Teaching Hospital of Addis Ababa University College of veterinary medicine, Bishoftu. The lamb displayed fever (40.9°C), straining with eversion of the rectum and painful vocalization. The perineum of the lamb was stained with blood-tinged feces. The mucus membrane was also slightly congested. A floatation technique for fecal sample examination revealed typical coccidian/*Eimeria* oocytes under a microscope with X40 objective lens. The lamb was treated successfully with sulfadimidine sodium at a dose of 1.5 ml/2.5 kg /day as initial dose and 0.75 ml/2.5kg/day as a maintenance dose intramuscularly, for three successive days and 2.5 mg/kg diclofenac sodium as a single intramuscular injection. Therefore, thorough diagnosis and opportune treatment is indispensable in reducing economic losses due to coccidiosis.

**Keywords:** *Coccidiosis; Lamb*

#### Introduction

Coccidiosis is an intestinal protozoan parasitic disease and it is one of the major constraints to livestock productivity worldwide (Scott, 2007). It is a contagious enteritis caused by protozoans of genus *Eimeria* that develop in small intestine and large intestine and it affects 4-6-month old kids and lambs in particular (Engidaw *et al.*, 2015; Khodakaram-Tafti and Hashemina, 2017). So far 15 species of *Eimeria* are known to occur in sheep, *Eimeria ovinoidealis* and *Eimeria crandallii* are the most pathogenic and widespread (Odden *et al.*, 2017; Khodakaram-Tafti and Hashemina, 2017). The principal source of clinical coccidiosis for lambs is contamination of bedding, drinkers and feeders by fecal matter from adult sheep which contains large numbers of oocytes.

Stressors such as weaning, harsh weather, dietary changes, traveling and regrouping are significantly influence incidences of coccidiosis in small ruminant (Constable *et al.*, 2017).

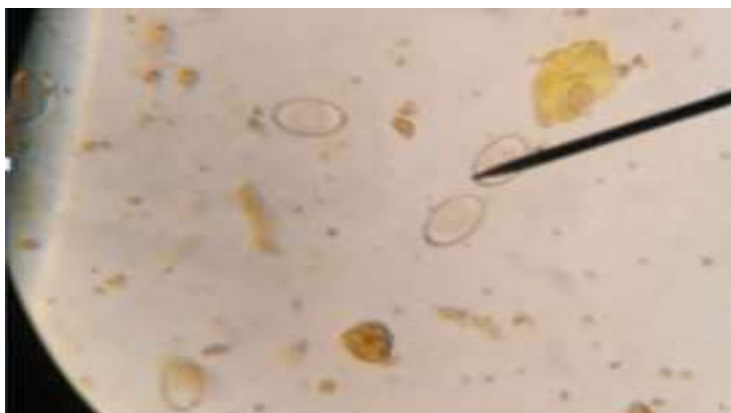
Coccidian can invade and destroy intestinal cells of their host and causing anemia, electrolyte loss and poor absorption of nutrients. The clinical coccidiosis can be manifested by diarrhea (fetid and contains mucus and flecks of fresh blood in severe cases), fever, abdominal pain (manifested by straining accompanied by painful vocalization and tenesmus), anorexia and reduced weight gain (Scott, 2007; Oyewusi *et al.*, 2015; Odden *et al.*, 2017). The subclinical form is commonly manifested by unthriftiness (Chartier and Paraud, 2012). Diagnosis of coccidiosis should be based on clinical signs, oocyst counts in faecal samples, pathological findings and, finally, clinical response to treatment(Andrews, 2013). Anti-coccidian such as Decoquinate and diclazuril are considerably more expensive and not available ubiquitously thus sulfa-drugs such as sulphamethoxypyridazine and sulfadimidine accompanied with hygienic protocols are found to be effective and reasonable (Scott, 2007).

#### Case description

A 6 month-old lamb was brought to AAU-CVMA-VTH, Bishoftu on December 13, 2017 from Filtinno peasant association, Ada'a woreda with a major complaint of straining in attempt to pass feces and contain blood. The feed intake of the lamb was also reduced which started three days before admission. The lamb was managed intensively with her dam and other flock of sheep. On clinical examination the lamb was febrile with rectal body temperature of 40.9° C; the respiratory, and heart rates were within the normal limits. There was straining, eversion of the rectum and painful vocalization in attempts to defecate. A fleck of fresh blood with staining of perineum and tail has been appreciated. The evacuated fecal matter was semi-solid and blood tinged. The conjunctiva mucus membrane was slightly congested and the lamb was depressed. Based on the history and clinical findings, lists of differential diagnosis were made including coccidiosis, salmonellosis and colibacillosis from which coccidiosis was diagnosed tentatively.

## Laboratory investigation and findings

For further investigation of the case, fecal samples were collected directly from rectum and immediately processed before the lamb dispatched at Addis Ababa University College of Veterinary Medicine, Veterinary Teaching Hospital multi-laboratory, Bishoftu. Fecal examination for *coccidian* oocysts was carried out using floatation method as described by Hansen and Perry (1994). Three grams of feces was added to 42 ml of saturated salt solution in a graduated cylinder. The contents were then mixed thoroughly using a glass rod, and were poured through a tea strainer into another beaker. The filtrate was then filled to 10ml test tube until convex meniscus formed and the cover-slip was putted on the top thoroughly and kept for 20 min in the test tube rack. Finally, the cover-slip was carefully lifted and placed on glass-slide and viewed under a compound microscope X40 objective lens. Fortunately, the floatation technique was found helpful and no further investigations were performed. Accordingly, typical coccidian/*Eimeria* oocysts were appreciated under microscope with X40 objective lens (figure 16). Therefore, based on the history, clinical findings and laboratory results, a definitive diagnosis of coccidiosis was made and treatment regimen was arranged.



**Figure 16:** Eimeria oocysts under microscope: magnified: X 40

## Case management and treatment outcome

Prompt and vigorous treatment regimen was continued with thorough follow up. Accordingly, broad-spectrum antibiotic Sulfadimidine sodium 33.3% (Hebei Yuanheng Pharmaceutical Co.,

Ltd, China) with 1.5 ml/2.5 kg /day as initial dose and 0.75 ml/2.5kg/day as maintenance dose, for three successive days, IM and 2.5 mg/kg diclofenac sodium (Jiangsu Pengyao Pharma .China) as a single intramuscular injection were administered. Forty eight hours post treatment, the lamb was presented with rectal body temperature of 38.9<sup>o</sup> C. The appetite of the lamb was also returned to normal (owner report). Generally, considerable change was appreciated at the end of the therapy (72 hours post-treatment).

## Discussion

The present incident in lamb was diagnosed as ovine coccidiosis based on the history, clinical findings and laboratory results. Coccidiosis is one of the most economically significant diseases of sheep worldwide and caused by protozoans of genus *Eimeria* of which *Eimeria crandallis* and *Eimeria ovinoidalis* are the most pathogenic species in lambs (usually 1–6 month old). The agents parasitize the epithelium lining of the alimentary tract and cause loss of epithelial cells and villous atrophy (Scott, 2007). Alike current case, coccidiosis in lambs is exhibited by unthriftiness, diarrhea (blood stained soft feces in rectum), perineum smudged with feces, abdominal pain, weakness, inappetence, fleece damage, mild fever, recumbency and emaciation; death may proceed if the case left untreated promptly (Oyewusi *et al*, 2015; Odden *et al*, 2017; Constable *et al* 2017).

The present case was treated successfully with sulfadimidine and Diclofenac administration. The improvement was noted forty eight hours post treatment which is in agreement with a case reported by Reddy *et al*. (2015). Mancebo *et al*. (2002), Oyewusi *et al*. (2015) and Gopalakrishnan *et al*. (2017) also reported the therapeutic efficacy of Sulfadimidine (sulfamezathine) against *Emeria* in goat kids, ram and calf, respectively with improvement 48hrs post treatment in goats and ram while it takes five days in calf.

In conclusion, coccidiosis is an intestinal protozoan parasitic disease and it is one of the major constraints to sheep producing countries worldwide. Hence, thorough diagnosis and opportune treatment of coccidiosis with sulfadimidine drugs plays a paramount role in combating economic losses of the disease. Maintaining the hygiene of the premises and feeding trough and separating young's from adults plays significant role in reducing the incidence.

## References

- Andrews A. (2013): Some aspects of coccidiosis in sheep and goats. *Small Ruminant Research* **110**: 93-95.
- Chartier C., Paraud C. (2012): Coccidiosis due to *Eimeria* in sheep and goats, a review. *Small Ruminant Research*, **103**: 84-92.
- Constable P., Hinchcliff K., Done S., Grundberg W. (2017): *Veterinary Medicine: A Textbook of the Diseases of Cattle, Horses, Sheep, Pigs, and Goats*. UK: Elsevier . 1879 p.
- Engidaw S., Anteneh M., Demis C. (2015): Coccidiosis in Small Ruminants. *African Journal of Basic & Applied Sciences*, **7** : 311-319.
- Gopalakrishnan A., Dimri U., Joshi V., Kundave V., Ajith Y., Yattoo M. (2017): A clinically rare occurrence of rectal mucosal prolapse associated with tenesmus in a calf caused by *Eimeria* sp. *Journal of Parasitic Diseases*, **41**: 723-725.
- Hansen J., Perry B. (1994): The epidemiology, diagnosis and control of helminth parasites of ruminants. A handbook. Khodakaram-Tafti A., Hashemina M. (2017): An overview of intestinal coccidiosis in sheep and goats. *Review Veterinary Medicine*, **167**: 9-20.
- Khodakaram-Tafti A., Hashemina M. (2017): An overview of intestinal coccidiosis in sheep and goats. *Review Veterinary Medicine*, **167**: 9-20.
- Mancebo O., Acevedo C., Rossiter A., Suarez M., Guardia N., Russo A., Monzon C., Bulman G. (2002): Coccidiosis in goat kids in the province of Formosa (Argentina). *Veterinaria Argentina*, **19**: 342-348.
- Odden A., Enemark H., Robertson L., Ruiz A., Hektoen L., Stuen S. (2017): Treatment against coccidiosis in Norwegian lambs and potential risk factors for development of anticoccidial resistance-a questionnaire-based study. *Journal of Parasitological Research*, **116**: 1237-1245.
- Oyewusi J., Oyewusi I., Takeet O., Muastapha O., Awoyomi O., Olurode S. (2015): Ovine Coccidiosis: A Case Report. *Journal of Veterinary Advance* **5**: 1023-1028.
- Reddy B., Sivajothi S., Rayulu V. (2015): Clinical coccidiosis in adult cattle. *Journal of Parasitic Disease*, **39**: 557-559.
- Scott, P. (2007): *Sheep Medicine*. Manson Publishing Ltd. 99 p.

#### 4.2.2. Dysentery in a ram caused by *Escherichia coli*

##### Abstract

Colibacillosis is an infection with *Escherichia coli* and responsible for considerable losses in young animals and occasionally affect adult animals. A clinical case of dysentery due to *Escherichia coli* in ram and its management was described in this case report. The ram was presented with bloody diarrhea with mucous, foul smell, severe dehydration, depression, anorexia and congested mucus membrane. Bacteriological culture of fresh fecal samples from ram revealed that the dysentery was due to *E. coli* infection whilst bacteriological culture for salmonellosis and parasitological examinations of *Eimeria* oocytes were negative. The ram was treated vigorously based on the tentative diagnosis with sulfadimidine sodium at a dose of 1ml/10kg/day as initial dose and 0.5ml/10kg/day as maintenance dose, IV, for five successive days and IV Lactated Ringer's solution was instituted. The disease could be cured if treated promptly and vigorously with appropriate antibiotic accompanied by supportive therapy.

**Keywords:** *Colibacillosis; Dysentery; E.coli; Ram*

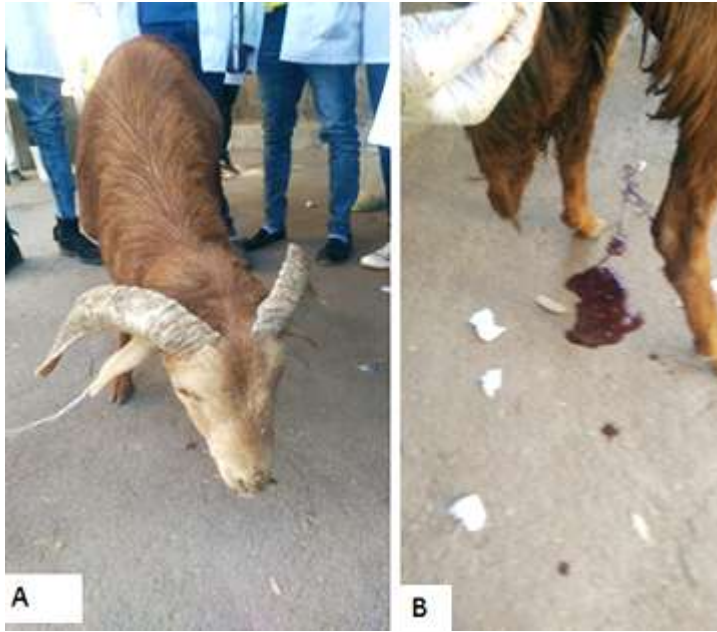##### Introduction

Colibacillosis, an infection with *Escherichia coli* (*E. coli*) is a major cause of mortality among young animals (Sharma *et al.*, 2006) and sometimes adult (Wani *et al.*, 2013). *E.coli* is a gram negative, rod, facultative anaerobic bacteria that is commonly found in the intestine of humans and animals; however there are certain strains of this organism that are pathogenic (Jessie *et al.*, 2016b; Quinn *et al.*, 2016). These pathogenic strains of *E.coli* are the cause of enteritis manifested by diarrhea, dysentery, abdominal pain, dehydration as well as electrolyte loss and imbalance. In severe case, mucus might be present in the feces while in worst case there might be shreds or sheets of exfoliated mucosa (Constable *et al.*, 2017). Transmission is most often through oral-fecal route by ingestion of contaminated feed and water, however infection through umbilical vein and nasopharyngeal routes were believed to occur in certain serotypes of *E.coli* (Constable *et al.*, 2017). New born are more susceptible due to deficiency of immunoglobulin. On the other hand multiple stresses such as transportation, deprivation of food and water or

weaning may also cause immunosuppression thus leading to enteritis (Jessie *et al.*, 2016). Diagnosis can be made based on history, clinical findings and isolation and characterization of the *E.coli* from representative samples (Berchtold and Constable, 2008; Gruenberg, 2017). Treatment of colibacillosis requires vigorous antibiotic treatment together with intravenous fluid (IVF) and anti-inflammatory agents (AID) (Berchtold and Constable, 2008). Parenteral antimicrobial such as oxytetracycline and sulfa drugs were reported to be effective in treatment of enteric colibacillosis ( Constable, 2004; Berchtold and Constable, 2008).Therefore, this paper describes dysentery in ram caused by *E.coli* and its treatment outcome.

### Case description

A Local breed ram was examined at AAU-CVMA-VTH on January 01/2018, Bishoftu. According to the owner, three days before admission, the ram started passing runny feces mixed with blood; feed intake was reducing gradually and later refused to eat and take water. The ram was bought from ‘Arsi Negelle’ with other flock of sheep and kept for commercial purpose. The ram and other flock were managed intensively and fed “frushka” and house hold remnants. The physical examinations were revealed slight increase in rectal body temperature (39.5<sup>o</sup>C), depression with head tilted down (figure 17 A), severe dehydration and rough hair coat. There was dysentery with mucous (figure 17 B) and pungent odor. The mucus membrane of the ram was congested and the perineum area was soiled with blood tinged feces. Based on the history and clinical findings, it was assumed tentatively as salmonellosis amongst colibacillosis, coccidiosis and enterotoxaemia.



**Figure 17:** Represents first day clinic visit; lethargic (A) and with dysentery (B)

#### Laboratory investigation and findings

For further confirmation of the case, fecal samples were collected directly from the rectum of the ram into specimen container and labeled accordingly. The samples were submitted and processed at Microbiology and Parasitology laboratory of Addis Ababa University College of Veterinary Medicine, Bishoftu. The first day a fecal floatation technique was performed for the detection of *Eimeria/Coccidian* oocytes and the result was negative. The same day the fecal sample was added to a test tube that contains 9 ml (1:9) of tryptose Soya broth and incubated at 37 °C for 24hrs. The next day a loop full of the broth cultures were taken and streaked over sorbitol macConkey and Rappaport broth medium for identification of *E.coli* and salmonella, respectively. Following incubation at optimum temperature, there were growths on the sorbitol macConkey agar whereas no growths were seen on Rappaport broth medium. Gram negative short rod bacteria were appreciated under microscope X100 objective lens following gram's staining procedure from pure culture on nutrient agar. Colonies were randomly picked and sub cultured on eosin methylene blue agar (EMB) to observe the characteristic metallic sheen of the *E.coli* (Annex 4). Further serotyping was not performed for the case due to scarcity of kits. Finally it was concluded that the ram was suffering from colibacillosis caused by pathogenic *E.coli*.


### Case management and treatment outcome

The ram was treated promptly and vigorously based on the tentative diagnosis with broad-spectrum antibiotic sulfadimidine sodium 33.3 % (Shandong Jinyang Biological Pharmaceutical Co.Ltd. China) at a dose of 1ml/10kg/ day as initial dose and 0.5ml/10kg/day as maintenance dose, IV, for five successive days and the fluid resuscitation was made by intravenous infusion of Lactated Ringer's solution (Addis Pharmaceutical factory PLC) (figure 18).



**Figure 18:** IV Lactated Ringer's solution institution

The ram was followed for five successive days during which daily checkup were done at VTH with administration of prescribed drugs. On the third day of therapy the bloody diarrhea disappeared and was changed to light green color but still runny in consistency (figure 19A). On the fifth day visit the ram was recovered (figure 19C) and feed intake recommenced (owner report). Three weeks later the owner responded that his ram was fully recovered and sold.



**Figure 19:** Comparative picture indicating the ram during the 1<sup>st</sup> (B arrow), the 3<sup>rd</sup> (A, arrow) and 5<sup>th</sup> day visit (recovered, C)

## Discussion

The present case report was confirmed *Escherichia coli* as responsible cause of dysentery in ram by incorporating the history (management), clinical and laboratory findings. So far six pathotypes of diarrhoeagenic *E. coli* strains were identified; including enterotoxigenic (ETEC), enteropathogenic (EPEC), entero-invasive, Shiga toxin-producing/enterohemorrhagic (EHEC), enteroaggregative (EAEC) and diffusely adherent *E.coli* (DAEC). Among the pathotypes, ETEC is most commonly associated with diarrhea in calves and lamb without causing significant morphologic damage to the intestinal lining whereas EHEC is capable of attaching, eroding and producing toxin which is responsible to hemorrhagic colitis in humans commonly (Croxen *et al.*, 2013; CFSPH, 2016) and animals occasionally (Moxley *et al.*, 2015; CFSPH, 2016)

Although colibacillosis is a major cause of diarrhea in lambs, the present case report was isolated *E. coli* as a cause of colibacillosis in ram. Wani *et al.*, 2013 report also indicated enteropathogenic *E. coli* (EPEC) which is adhering and effacing *E. coli* as causative agent for

severe diarrhea in both kids and adult sheep and goats. Although typing was not performed in the current report, the clinical and laboratory findings were indicated *Escherichia coli* which were negative for *Salmonella* and *Eimeria*. Moxley *et al.* (2015) and Constable *et al.*, (2017) also indicated that the diarrhoeagenic strains of *E. coli* are responsible for diarrhea (containing mucus or shreds mucosa), dysentery, abdominal pain and severe dehydration.

In current case report, sulfadimidne antibiotic augmented with Lactated Ringer's solution was found effective in preserving the ram which is in agreement with Shahrani *et al.* (2014) report which elucidated most serogroups of EHEC are highly susceptible to sulfadimidine antibiotics. In addition, Constable (2004) also indicated amoxicillin, chlortetracycline, neomycin, oxytetracycline, streptomycin, sulfachloropyridazine, sulfamethazine, and tetracycline as recommended drugs for the treatment of colibacillosis. Conversely, Shahrani *et al.* (2014) report was shown most serogroups of EHEC are highly resistant to penicillin, streptomycin and tetracycline antibiotics.

Colibacillosis can affect animals of any age albeit the prevalence is very high in young animals. The disease could be cured if treated aggressively with the appropriate antibiotic and supportive therapy. However, maintaining a clean and dry environment and reducing stressors plays paramount role in preventing the occurrences.

#### Limitations

During this work, the agglutination kits used to identify the *E.coli* serogroups were not available and hence the study was concluded based on bacterial culture and clinical pictures only. The drug selections for the treatment of the case was not based on sensitivity tests due to a scarcity of disks

#### Acknowledgment

I am grateful to Addis Ababa University College of Veterinary medicine, Veterinary Teaching Hospital, and Microbiology staffs; in particular, Dr. Cheru Talila, Mr. Dereje Gudeta, and Ms. Tsedale for their contribution. And also, the owner of the animal for his valuable information during the follow up.

## References

- CFSPH (2016): Center for Food Security and Public Health, Iowa State University: Enterohemorrhagic *Escherichia coli* and Other *E.coli* Causing Hemolytic Uremic Syndrome.
- Constable P., Hinchcliff K., Done S., Grundberg W. (2017): Veterinary Medicine: A Textbook of the Diseases of Cattle, Horses, Sheep, Pigs, and Goats. UK: Elsevier . 1879 p.
- Constable P. (2004): Antimicrobial use in the treatment of calf diarrhea. *Journal of veterinary internal medicine*, **18**: 8-17.
- Croxen M., Law R., Scholz R., Keeney K., Wlodarska M., Finlay B. (2013): Recent Advances in Understanding Enteric Pathogenic *Escherichia coli*. *Clinical Microbiology Review* **26**: 822-880.
- Gruenberg, W. (2017): Overview of Colisepticemia (Septicemic colibacillosis, Septicemic disease). In: Kahn C. SL (Eds), The Merck veterinary manual [online], Merck and Co, Whitehouse Station, NJ, USA.
- Jessie F., Chungl E., Latif S., Yussuf A., Tijjani A., Sadiq M., Mohammed K., Adamu L., Hambali I., Bitrus A., Salleh A., Lila M., Haron A., Saharee A. (2016): A Clinical Case of Severe Enteric Colibacillosis in a Doe and its Pathological Findings: A Case Report. *Research Journal for Veterinary Practitioners*, **4**: 34-38.
- Moxley R., Stromberg Z., Lewis G., Loy J., Brodersen B., Patel I. (2015): Haemorrhagic colitis associated with enterohaemorrhagic *Escherichia coli* O165 : H25 infection in a yearling feedlot heifer. *Journal of Medical Microbiology* **2**.
- Quinn P., Markey B., Leonard F., Fitzpatrick F., Fanning S. (2016): Concise Review of Veterinary Microbiology. The Atrium, Southern Gate, Chichester, West Sussex, PO19 8SQ, UK: John Wiley & Sons Ltd. 142 p.
- Shahrani M., Dehkordi F., Momtaz H. (2014): Characterization of *Escherichia coli* virulence genes, pathotypes and antibiotic resistance properties in diarrheic calves in Iran. *Biology Research*, **47**: 28.
- Sharma V., Katch M., Katoch R., Dhar V. (2006): Recovery of some important serotypes of *E.coli* from diarrhoeic and apparently healthy calves in palam valley of himachal pradesh. *International Journal of Cow Science*, **2**: 34-36.

Wani S., Hussain I., Beg S., Rather M., Kabli Z., Mir M., Nishikawa Y. (2013): Diarrhoeagenic *Escherichia coli* and salmonellae in calves and lambs in Kashmir: absence, prevalence and antibiogram. *Review of Science and Technology*, **32** : 833-840.

#### 4.2.3. Mannheimiosis (pneumonic pasteurellosis) in a ewe

##### Abstract

Mannheimiosis/pneumonic pasteurellosis is the most significant respiratory disease in sheep rearing industries worldwide. In this case report a ewe with clinical manifestations of fever (41.2°C), profuse muco-purulent bilateral nasal discharges, congested mucus membrane, dull hair coat and lethargic was described. Bacteriological culture of a nasal swab and biochemical test results pointed out that the ewe suffered from pneumonic pasteurellosis or mannheimiosis caused by *Mannheimia hemolytica*. Penistip at a dose of 1ml/20kg/day intramuscularly for 5 consecutive days arranged. However, forty-eight hours post-treatment, the ewe died. The death of the ewe was supposed to be associated with the complication of the case due to a late hospital visit.

**Keywords:** *Ewe; Mannheimiosis*

##### Introduction

Pneumonic pasteurellosis is one of the most economically important infectious diseases of ruminants with a higher prevalence universally. It is caused by small, non-motile, Gram-negative rods or coccobacilli *pasteurella* and *Mannheimia* species (Quinn *et al.*, 2016). *Mannheimia* is responsible for septicemia in young lambs, pneumonia in older sheep and mastitis in ewes (Scott, 2007).

*Mannheimia haemolytica* is well established to be the major etiological agent of pneumonic pasteurellosis, although *Pasteurella multocida* has been incriminated in many acute outbreaks (Mohamed and Abdelsalam, 2008); in a report from Ethiopia 79.5% of *pasteurella* isolates from sheep were found to be *Mannheimia haemolytica* (Alemneh and Tewodros, 2016). Both *Mannheimia* and *Pasteurella* species are commensally resident in the respiratory tract of healthy ruminants however, the disease is principally triggered by physical or physiological stress created by adverse environmental and climatic conditions such as extremely bad weather, poor management, overcrowding, transportation or previous infection with respiratory viruses, mycoplasma or some other pathogenic organisms (Winter and Clarkson, 2012; Alemneh and

Tewodros, 2016). Infections due to *Mannheimia haemolytica*, generally, are observed all year round, even if, they are often observed at the end of spring and at the beginning of summer (this form is also known as 'summer pneumonia'), or during colder seasons in some African countries (AU-IBAR, 2013).

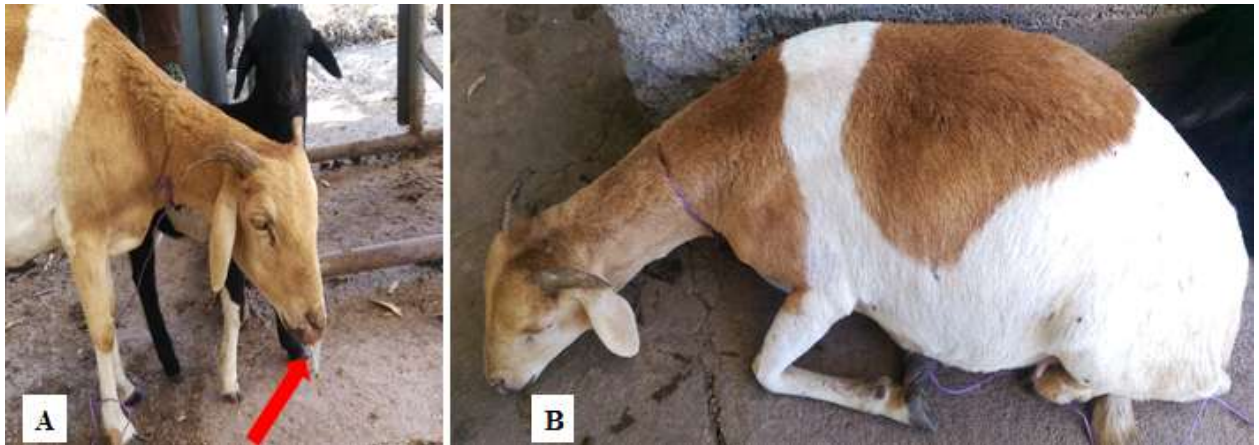
The disease is characterized by severe fibrinous or fibrinopurulent bronchopneumonia, fibrinous pleurisy and septicemia. Observable clinical signs of acute respiratory distress usually develop within 10 to 14 days in adult animals after being exposed to stress but a much earlier onset is more typical. However, infected animals in severe cases may die as a result of toxemia even before the development of significant pulmonary lesions. In this case sudden death may be the first sign of acute outbreaks particularly in young animals. After the onset of respiratory disturbances, infected animals appear extremely dull with reduced appetite and remarkable depression. They soon develop high fever, anorexia and rapid shallow respiration accompanied with profuse mucopurulent nasal and ocular discharges. Infected animals may die within a few days of the onset of clinical signs, but those which survive the acute attack may become chronically infected (Winter and Clarkson, 2012; Constable *et al.*, 2017).

It is unrealistic to depend on a vaccine, an antimicrobial, or a single management technique to control the disease. Successful control begins with the adoption of effective management techniques, the judicious use of efficacious vaccines, and care in handling and transportation of cattle (Constable *et al.*, 2017). Therefore, this case report describes the clinical case of manheimiosis and its consequence in ewe

#### Case description

A ewe with her lamb was brought to AAU-CVMA-VTH, Bishoftu on November, 14/2017. According to the complaint the ewe had breathing problem, discharges from the nose, reduced feed intake and ceases suckling her lamb. The case has elapsed three days. The ewe was managed intensively with new arrivals and previous collect reared for the purpose of marketing and fed “frushka” and household leftovers. Detailed physical and clinical examinations revealed the ewe was febrile with body temperature of 41.2° C, and had 38 breaths/mean and 92 beats/mean respiratory and heart rates, respectively. The ewe had profuse, muco-purulent bilateral nasal

discharges (figure 20A) and congested conjunctival mucus membrane. Generally, the ewe was dull and lethargic (figure 20B) with head tilted down. Based on the history, clinical findings and weather condition of the season (cold weather), it has been asserted tentatively as pneumonic pasteurellosis and treated accordingly.



**Figure 20:** Indicating clinical picture of Pasteurellosis

#### Laboratory diagnosis and findings

The nasal swab was collected after external part of the nose disinfected. A sterile cotton-tipped swab inserted into the nostril and rotated against the wall of the nasal cavity. The swab placed in the labeled sterile test tube that contains 3 ml of tryptose Soya broth and immediately submitted to Addis Ababa University College of Veterinary Medicine Microbiology laboratory and incubated at 37° C for 24hrs. The next day a loop full of the broth cultures were taken and streaked over macConkey agar and blood agar medium with 7ml sheep blood. After 24hrs of incubation at 37° C, there was growth both on the blood agar and macConkey agar medium (Annex 4). A smear was performed for gram's staining and short rod gram negative bacteria were appreciated under microscope (fig 14). Besides, biochemical tests including oxidase, catalase, motility, glucose, sucrose, maltose, lactose and indole tests were also performed. Except motility and indole tests all tests were positive. Therefore, it was concluded that bacterium was *Mannhiemia hemolytica* based on growth pattern (growth on macConkey and blood agar with visible zone of hemolysis) and biochemical test results (no indole production).

Finally, based on the integrated results of laboratory findings, clinical findings and history, the case was confirmed as pneumonic pasteurellosis caused by *Mannheimia hemolytica*

#### Case management and treatment outcome

For the treatment of the case a broad-spectrum antibiotic, penistip (combination of procaine penicillin and Dihydrostreptomycin) (Chongqing Fantong Animal Pharmaceutical Co.Ltd, China) 1ml/20kg/day intramuscularly for 5 consecutive days was arranged. The ewe was presented twenty four hours post therapy with body temperature reduced to 39.2°C; however forty eight hours post treatment, the owner reported that the ewe died.

#### Discussion

The present case of ewe confirmed as mannheimiosis based on the history, clinical findings, laboratory findings and the weather conditions of the season. The cold weather conditions during the incident and new arrivals assembly to the previous flock were believed to ignite the incident. Similar situations reported by Ekong *et al.* (2014) specified mannheimiosis outbreak in a flock of sheep and goats in Nigeria inclined by stressors including, the intensive management and high number of goats and sheep confined together; commingling of new and previous flocks of sheep and goats; area where the outbreak occurred had sub-tropical climate with a temperature averaging 20° C. Various literature and reports also emphasize that most cases of pneumonic pasteurellosis/mannheimiosis are elicited by stressors (Winter and Clarkson, 2012; AU-IBAR, 2013; Alemneh and Tewodros, 2016; Constable *et al.*, 2017). Similar to the current condition, most cases of acute pasteurellosis/mannheimiosis will terminate with death albeit few cases may progress to chronic infection and/or recover (Winter and Clarkson, 2012). The death of the ewe in this study could be associated with respiratory distresses including severe fibrinous or fibrinopurulent bronchopneumonia, fibrinous pleurisy and septicemia (Winter and Clarkson, 2012). Late hospital visit has a contribution to the complication of the case and management afterward may also promote the death of the animal.

Mannheimiosis/pneumonic pasteurellosis is one of the most significant respiratory diseases in sheep rearing industries and elicited by stressors. It is commonly characterized by acute

respiratory distress and death within a few days of the onset of the clinical signs. Hence, early hospital visit as soon the condition noticed can ease complication and death. Besides, reducing stressors and adoption of good management practices has paramount role in lessening the occurrences. The better option to control the disease could be getting the animals vaccinated against Pasteurellosis.

#### Acknowledgement

I am grateful to Addis Ababa University College of Veterinary medicine, Veterinary Teaching Hospital, and Microbiology staffs; in particular, Ms. Tsedale and Mr. Abebe W. for their contribution.

#### References

- Alemneh T., Tewodros A. (2016): Sheep and goats pasteurellosis: Isolation, identification, biochemical characterization and prevalence determination in Fogera Woreda, Ethiopia. *Journal of Cell and Animal Biology*, **10**: 22-29.
- AUIBAR (2013): African Union for Interafrican Bureau for Animal Resources: Pasteurellosis.
- Constable P., Hinchcliff K., Done S., Grundberg, W. (2017): *Veterinary Medicine: A Textbook of the Diseases of Cattle, Horses, Sheep, Pigs, and Goats*. UK: Elsevier . 2042 p.
- Ekong P., Akanbi B., Odugbo M. (2014): A Case Report of Respiratory Mannheimiosis in Sheep and Goat Complicated by Bordetella Parapertussis. *Nigerian Veterinary Journal*, **35**.
- Mohamed R., Abdelselam E. (2008): A Review on Pneumonic Pasteurellosis (Respiratory Mannheimiosis) with Emphasis on Pathogenesis, Virulence Mechanisms and Predisposing Factors. *Bulgarian Journal of Veterinary Medicine*, **11**: 139-160.
- Quinn P., Markey B., Leonard F., Fitzpatrick F., Fanning S. (2016): *Concise Review of Veterinary Microbiology*. The Atrium, Southern Gate, Chichester, West Sussex, PO19 8SQ, UK: John Wiley & Sons Ltd. 142 p.
- Scott, P. (2007): *Sheep Medicine*. Manson Publishing Ltd. 99 p.
- Winter, A. and Clarkson, M. (2012): *A Handbook for the Sheep Clinician*. UK: CAB International.

#### 4.2.4. Clinical hypocalcaemia/milk fever in a late pregnant ewe and a lactating Cow

##### Abstract

Metabolic diseases pose a considerable risk to animal production enterprises. The clinical case of hypocalcaemia (milk fever) in late pregnant ewe and a lactating cow was described. The cow was at sternal recumbency and unable to stand and hence, examined at home while the ewe was presented with a cart to the veterinary teaching hospital of Addis Ababa University, Bishoftu. The case history indicated that the cow had calved before a month and had similar condition a week after calving and treated. Physical examinations showed vital parameters were within the normal range in a cow while the respiratory (36 breaths/min) and heart rates increased (100 beats/min) in the ewe. Both the animals were treated successfully with calcium borogluconate composed of calcium borogluconate 400mg/ml and Magnesium hypophosphate hexahydrate 80mg/ml intravenously. After completion of therapy, both animals were successfully responded. Therefore, opportune IV calcium borogluconate institution has reduced the likelihood of complication and death due to hypocalcaemia.

**Keywords:** *Cow; Calcium borogluconate; Ewe; Hypocalcaemia*

##### Introduction

Milk fever or hypocalcemia is an acute metabolic disorder that occurs predominantly in late pregnant and lactating animals and occasionally in weaned lambs. Usually, when the total serum calcium concentration is less than 9.7 mg/dL in cattle and 11.5 mg/dL in sheep and the ionized calcium is less than 4.0 mg/dL in cattle and 4.0 mg/dL in sheep. It has a considerable importance for the dairy cow and sheep producing industries worldwide (Thilsing-Hansen *et al.*, 2002; El-Khodery *et al.*, 2008; Brozos *et al.*, 2011; Giadinis *et al.*, 2016; Constable *et al.*, 2017). There is an increased incidence in mature, heavy milk producers and multiparous dairy cows and ewes (Lorenz *et al.*, 2011). Clinical hypocalcemia in ewes is frequently sporadic but occasionally it can occur as an outbreak especially when sheep are managed intensively (Bulgin, 2007; Giadinis *et al.*, 2016). Most cases of hypocalcemia are related to errors in formulating rations, incorrect mineral supplementation and stress-related events (Bulgin, 2007).

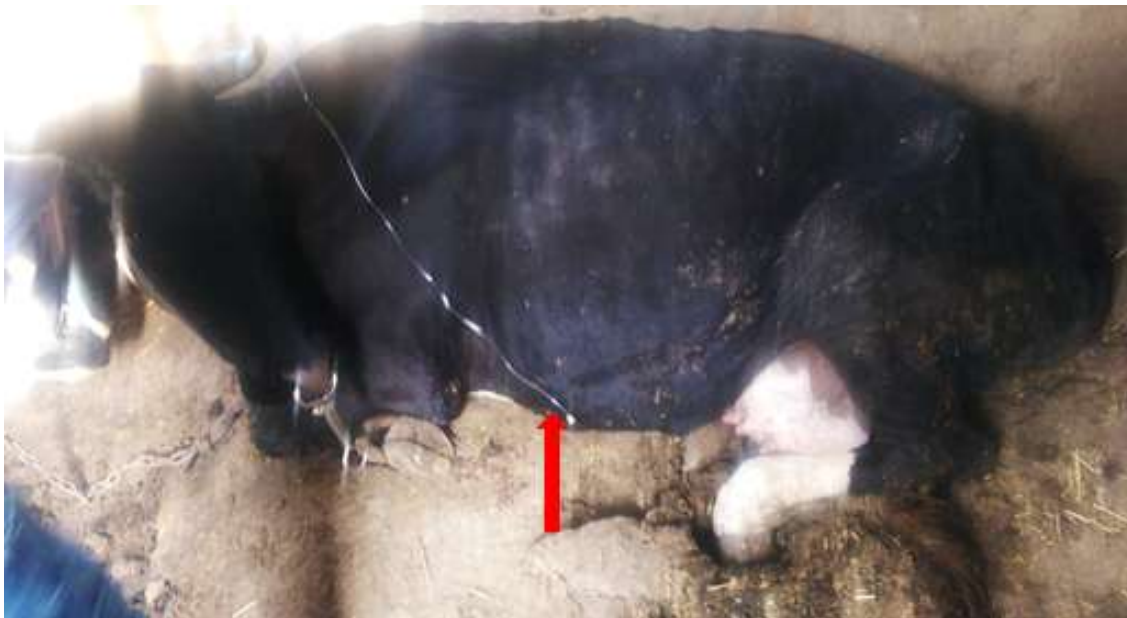Hypocalcemia is initially manifested by restlessness, excitability, and anorexia. The ability to regulate core temperature is gradually lost. Therefore, the rectal temperature will be either high or low and cutaneous circulation is depressed depending on ambient temperature. Rumen contractions will progress from weak to absent. Skeletal muscle weakness develops over several hours. Cows may stagger or fall but more commonly are found down and unable to rise. Heart rate increases; later cardiac output decreases as a result of reduced venous return and weaker cardiac muscle. Bloat occurs because of failure to eructate. Death may occur within 12 hours of the onset of signs caused by suffocation secondary to bloat or cardiovascular collapse. Generally, hypocalcemia has three stages, with stage 1 characterized by the animal being able to stand, stage 2 by recumbency, and stage 3 by coma and unresponsiveness (Peek and Divers, 2008; Oetzel and Goff, 2009; Brozos *et al.*, 2011; Constable *et al.*, 2017). The early stages of hypocalcemia in affected ewes can be manifested by isolation from the flock, unable to raise themselves from their knees and assume sternal recumbency again within 10–30 seconds. Over the next 2–6 hours the ewe becomes depressed, weak and unable to stand even when supported. Later the rumen distended and contents expelled with green fluid on the external nares and around the lower jaw, which is the indication of advancement (Bulgin, 2007; Brozos *et al.*, 2011).

Although, the case usually responds well to prompt IV calcium borogluconate treatment, in some animals it relapses and/or predisposes them to other metabolic and infectious diseases (Lorenz *et al.*, 2011) hence, prevention of hypocalcaemia is given a high priority (Thilsing-Hansen *et al.*, 2002). According to Brozos *et al.*, (2011) good nutritional management during the fourth and fifth months of pregnancy should prevent the occurrence of hypocalcaemia in ewes whereas feeding rations low in calcium is highly efficient during the last week pregnancy in cows (Thilsing-Hansen *et al.*, 2002). Therefore, this case report presented the clinical case of hypocalcaemia and its intervention in late pregnant ewe and lactating cow.

## Case descriptions

### Case 1

A crossbred cow weighing around 450kg was examined in one of privately owned smallholder dairy farm in February, 21/2018 with the chief complaint of inability to stand. The cow had calved a month ago for the 4th time and the same condition happened a week after delivery for which the cow had treatment and recovered. The cow was managed intensively and fed “frushka” and straw, however, cow’s daily milk production has been reduced while feed intake was as usual. A physical examination has revealed that the rectal body temperature of the cow was 37.8°C while heart rate and respiratory rates were 64 beats/ min and 32 breaths/ min, respectively. The cow was recumbent on her right side with the neck curved towards the left flank (figure 21).



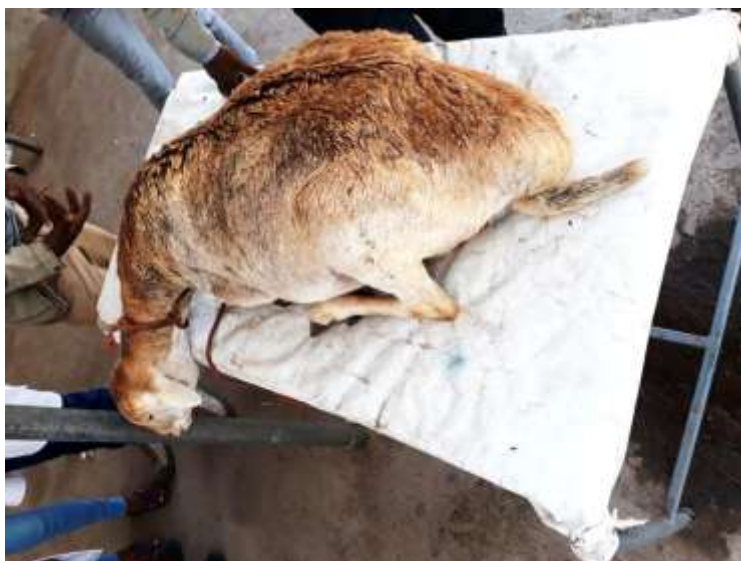**Figure 21:** A recumbent cow with hypocalcaemia and mammary-vein calcium-boroglucoante institution (the arrow)

### Case 2

A late pregnant local breed ewe with the history of inability to stand and distended abdomen was brought with a cart to AAU-CVMA-VTH on March 01, 2018. According to the owner, on the morning some hours prior to presentation to the hospital, the ewe was laid down and unable to stand even with support. The ewe was managed intensively with other sheep kept for marketing

and fed “frushka” and household leftovers. A physical examination was revealed that the rectal body temperature of the ewe was 37.7°C while the respiratory rates (36 breaths/min) and heart rates increased (100 beats/min). The ewe was depressed, recumbent and unable to stand and also had distended abdomen and protruded tongue (figure, 22).

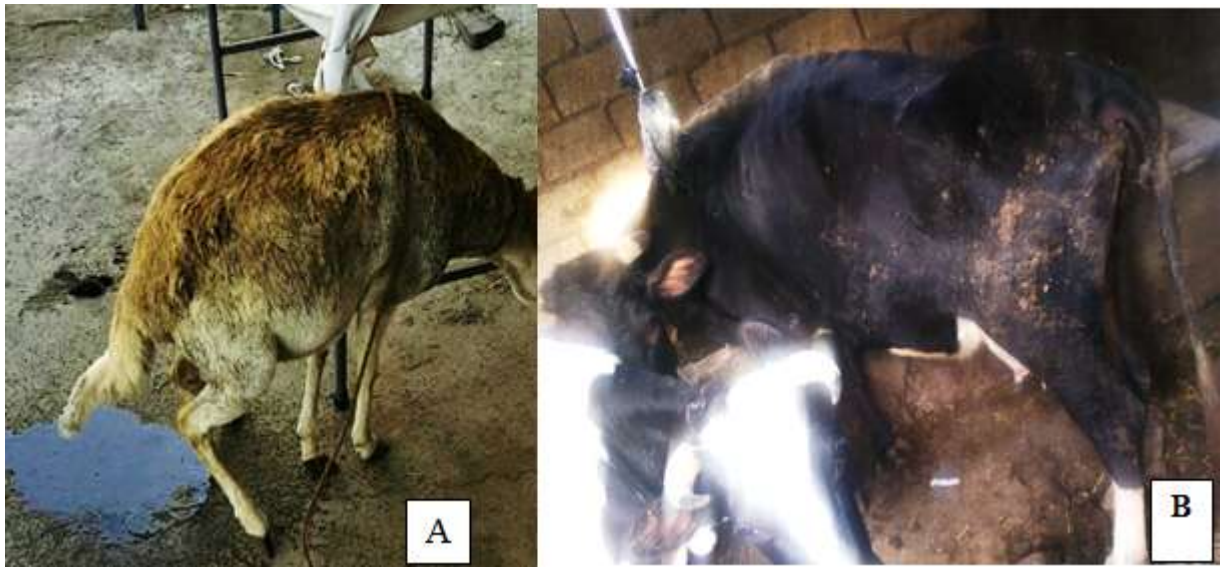Based on the stage of production and clinical findings, both cases were asserted tentatively as hypocalcaemia even though pregnancy toxemia also doubted in the ewe.



**Figure 22:** Pregnant ewe with hypocalcaemia during presentation

#### Case management and treatment outcome

A therapy of 40% calcium borogluconate composed of calcium borogluconate 400mg/ml and Magnesium hypophosphate hexahydrate 80mg/ml (Norbrook, UK.) at a dose of 1ml/kg body weight was managed slowly via I.V. and S.C route. The cow was treated with slow IV administration of 500 mL of calcium borogluconate into the mammary vein over a period of 30 minutes and recovered after treatment (figure 20B). For the ewe, 20 ml of the same preparation was given intravenously into the jugular vein whilst 10ml was administered subcutaneously and responded excellently. Eructation was observed in ewe following IV institution. Then five minutes later the ewe was able to stand, defecate, urinates (figure, 23A) and start walking. Muscle tremor, particularly of the flanks and later extends to the whole body was appreciated and heart rate was decreased. Therefore, based on the treatment outcome and exhibited signs it was confirmed that the animals were suffered from hypocalcaemia.



**Figure 23:** After calcium borogluconate administration, ewe (A) and cow (B)

#### Discussion

Hypocalcaemia was diagnosed in the present case report based on the stages of production, clinical findings and rapid response to calcium borogluconate therapy. Hypocalcaemia is an acute metabolic disease particularly in adult sheep and lactating cow, which is instigated by an inadequate supply of metabolizable calcium during the peak demand. For instance, from 6 weeks before to 10 weeks after lambing in ewes (Giadinis *et al.*, 2016) and the first two weeks before and after parturition in cow (Constable *et al.*, 2017). Calcium homeostasis is mediated primarily by parathyroid hormone, which stimulates bone calcium resorption and renal calcium reabsorption. Parathyroid hormone stimulates the production of 1, 25-dihydroxyvitamin D to enhance diet calcium absorption. Calcium is endowed with various capacities, including directing skeletal, heart, and smooth muscle constriction, facilitation of nerve stimuli transmission, triggering chemicals that support vital body compound responses, adding to the coagulation framework, impacting cardiovascular automaticity and contractility (Wassan and Manar, 2015). However, reproductive events (gestation and lactation), high dietary cation-anion difference, vitamin D deficiency and hypomagnesaemia challenge tissue sensitivity to a parathyroid hormone which results in deficiency and further interruptions of the activities (Goff, 2008; Goff, 2014).

In the late gestation and in lactating animals, demand for calcium become maximum particularly 3–4 weeks prior to parturition and two weeks after parturition, because during this time the demand of calcium for the fetal bone development particularly in ewes is higher. Similarly in lactating animal plasma calcium levels can significantly drop due to calcium excretion into the milk. Furthermore, these two events challenge the plasma calcium concentration (Hoenderop *et al.*, 2005). Mobilization of calcium from bone stores takes more than 24 hours; therefore, periods of transient hypocalcaemia (inevitable delay in Calcium metabolism adaptation) may result but sometimes this transient hypocalcaemia may advance to persistent hypocalcaemia due to a deficient compensatory mechanism (Martin-Tereso and Martens, 2014). These situations can be exhibited typically by tetany, incoordination, and loss of motion, extreme lethargies, and coma which is coherent with the present cases. Alike current reports, early detection and appropriate treatment with calcium borogluconate reduces the likelihood of progression of the case and death. As indicated in present cases following successful therapy, animals with milk fever exhibit a typical pattern of response to calcium borogluconate administration including, belching, muscle tremor, the decrease of the heart rate, increase in the intensity of the heart sounds, sweating of the muzzle, defecation, and urination (Constable *et al.*, 2017).

In conclusion, hypocalcaemia is a common metabolic disease in late pregnant ewe and in early lactating cow due to increased demand for calcium in this period. Therefore, early and adequate therapy with calcium borogluconate will ease the likelihood of complication and death due to hypocalcaemia. Adjustment of feeding especially at the time of peak calcium demand is important in reducing the occurrences.

#### Acknowledgments

I am grateful to Addis Ababa University College of Veterinary medicine, Veterinary Teaching Hospital, in particular, Dr. Cheru Talila and Mr. Dereje Gudeta.

## References

- Brozos C., Mavrogianni V., Fthenakis G. (2011): Treatment and Control of Peri-Parturient Metabolic Diseases: Pregnancy Toxemia, Hypocalcemia, Hypomagnesemia. *Veterinary Clinics of North America: Food Animal Practice*, **27**: 105-113.
- Bulgin M. (2007): Chapter 92 - Diseases of the Periparturient Ewe. *Current Therapy in Large Animal Theriogenology (Second Edition)*. Saint Louis: W.B. Saunders. pp. 695-700.
- Constable P., Hinchcliff K., Done S., Grundberg, W. (2017): *Veterinary Medicine: A Textbook of the Diseases of Cattle, Horses, Sheep, Pigs, and Goats*. UK: Elsevier . 121 p.
- El-Khodery S., El-Boshy M., Gaafar K., Elmashad A. (2008): Hypocalcaemia in Ossimi Sheep Associated with Feeding on Beet Tops (*Beta vulgaris*). *Turkey Journal of Veterinary and Animal Science*, **32**: 199-205.
- Giadinis N., Abd El-Tawab M., Polizopoulou Z., Argiroudis S., Karatzias H. (2016): Hypocalcemic tetany in a pet lamb fed with cow milk. *Journal of Hellenic Veterinary Medicine Society*, **67**.
- Goff J. (2008): The monitoring, prevention, and treatment of milk fever and subclinical hypocalcemia in dairy cows. *The Veterinary Journal*, **176**: 50-57.
- Goff J. (2014): Calcium and Magnesium Disorders. *Veterinary Clinics: Food Animal Practice* **30**: 359-381.
- Hoenderop J., Nilius B., Bindels R. (2005): Calcium Absorption Across Epithelia. *Physiology Review* **85**: 373-422.
- Lorenz M., Coates J., Kent M. (2011): Chapter 15 - Systemic or Multifocal Signs. In: *Handbook of Veterinary Neurology (Fifth Edition)*. Saint Louis: W.B. Saunders. pp. 432-487.
- Martin-Tereso J., Martens H. (2014): Calcium and Magnesium Physiology and Nutrition in Relation to the Prevention of Milk Fever and Tetany (Dietary Management of Macrominerals in Preventing Disease). *Veterinary Clinics: Food Animal Practice*, **30**: 643-670.
- Oetzel G., Goff J. (2009): Chapter 33 - Milk Fever (Parturient Paresis) in Cows, Ewes, and Doe Goats. In: *Food Animal Practice (Fifth Edition)*. Saint Louis: W.B. Saunders. pp. 130-134.

- Peek F., Divers T. (2008): Chapter 14 - Metabolic Diseases. In: Rebhun's Diseases of Dairy Cattle (Second Edition). Saint Louis: W.B. Saunders. pp. 590-605.
- Thilsing-Hansen T., Jorgensen R., Ostergaard S. (2002): Milk Fever Control Principles: A Review. *Acta veterinaria scandinavica*, **43**: 1-19.
- Wassan A., Mannar H. (2015): Effect of Experimental Induced Hypocalcemia on Physical Parameters and Calcium Levels in Awassi Sheep. *International Journal of Research and Development in Pharmacy and Life Sciences*, **4**: 1808-1812.

#### 4.2.5. Hemonchosis: A case of four sheep

##### Abstract

Hemonchosis is economically limiting factor in sheep production system particularly in developing countries. This case report describes the clinical case of chronic hemonchosis in sheep. Four sheep with edema under the jaw, poor body condition, and pale conjunctival mucous membrane examined at Addis Ababa University College of Veterinary Medicine, Veterinary Teaching Hospital, Bishoftu on March 15/2018. According to the owner, previously one sheep died with similar case after treated with oral unknown medicament. Based on the history, clinical findings and detection of eggs in the fecal samples, diagnosis of Hemonchosis reached and the animals were treated rigorously. Ivermectin at a dose of 0.2mg/kg administered subcutaneously and the sheep successfully revived. Therefore, early diagnosis and treatment with the appropriate drug have a substantial outcome and reduce losses.

**Keywords:** *Hemonchosis; Sheep*

##### Introduction

In the tropics, gastrointestinal nematodes are a major problem in small ruminants, and they cause disease, death, and economic loss (Puspitasari *et al.*, 2016). *Haemonchus*, *Trichostrongylus*, *Teladorsagia/Ostertagia*, *Strongyloides*, *Bunostomum*, *Nematodirus*, *Chabertia*, *Trichuris*, *Cooperia*, *Skrjabinema* and *Oesophagostomum* are elucidated by parasitological investigations as the most prevalent nematode parasites of small ruminants in Ethiopia (Asmare *et al.*, 2016). All grazing sheep and goats are infected with most of these nematodes which is clinically known as parasitic gastroenteritis (PGE) (Sissay, 2007; Zajac, 2006). *Haemonchus contortus* is the most common amongst superfamily of *Trichostrongyloidea* parasitizing small ruminants (sheep and goats) particularly in tropical and subtropical areas (Gilleard and Redman, 2016; Irma and Richard, 2010; Nisbet *et al.*, 2016) including Ethiopia (Sissay *et al.*, 2007). *Haemonchus* is highly pathogenic, avid bloodsucker nematode primarily occurring in the abomasum notably of sheep and goats. Although, warm and moist conditions favor the free-living stages of *Hemonchus*, periodic outbreaks occur commonly during periods of transient environmental

favorability (Besier *et al.*, 2016). It undergoes hypobiosis during the winter or prolonged drought (Craig, 2009).

Hemonchosis is imperative veterinary disease and the cause of significant economic loss in small ruminant industries worldwide. It is also the most prevalent and substantial small ruminant disease in Ethiopia representing more than 60% of the total worm burdens recorded in the sheep and goats (Sissay, 2007). The life cycle of *Haemonchus* are direct (requiring no intermediate hosts), which other economically important nematode parasites of small ruminants shares. The first and second stages of larvae are free-living organisms and the host ingests the third stage larvae (the infective stage). The L3 pass to the abomasum where they ex-sheathe and penetrate the mucosal lining of the stomach. The L3 moult within 2–3 days to become L4, which remain in the mucous membrane or in the gastric glands for a further 10 to 14 days. Both the larvae (L4) and the adults of *Haemonchus* species suck blood. Each worm suck 0.05 milliliter of blood per day, hence major impacts on small ruminants health and economy (Urquhart *et al.*, 2003).

Hemonchosis causes heavy losses because of animal deaths and reduced production. In sheep, the acute form is most common in lambs and cause mortality, especially those recently weaned, but yearlings and mature sheep may also be affected. In chronic cases, lethargy, muscular weakness, and pale conjunctival mucus membrane are indicative of heavy blood loss. Anemia with packed cell volumes (PCVs) occasionally in the single digits and hypoproteinemia as seen by intermandibular edema (bottle jaw) are the primary signs of the disease. Most affected sheep show constipation rather than diarrhea. There is a loss of body weight and a detrimental effect on wool growth and quality (Constable *et al.*, 2017; Craig, 2009). The clinical diagnosis of haemonchosis is based mostly on the detection of anemia in association with a characteristic epidemiological picture, fecal egg count, and confirmed at postmortem by the finding of large numbers of *H. contortus* in the abomasum (Besier *et al.*, 2016). Although resistance is evolving issue all the broad-spectrum ruminant anthelmintics are thought to be effective against *Haemonchus* (Constable *et al.*, 2017). Therefore, the current case report describes the clinical case of chronic hemonchosis in sheep.

## Case description

Four sheep were presented to Addis Ababa University College of Veterinary Medicine, Veterinary Teaching Hospital from Babogaya, Bishoftu in March 15/2018 with a complaint of decreased feed intake and swelling under the jaw. According to the owner, a flock of sheep was purchased from Dalota peasant association, Ada'a before a month. One sheep with similar symptom died after treated with oral unknown drug. The sheep were nursed at home with “frushka” and household leftovers and kept primarily for commercial. Upon physical examinations, the vital body parameters were within the normal range. The sheep had edema under the jaw, poor body condition (figure 24), and pale conjunctival mucous membrane. The fecal output was normal and no other remarkable signs were noticed. Based on history and clinical findings a tentative diagnosis of Hemonchosis was made although other parasitic gastro-enteritis (PGE) doubted.

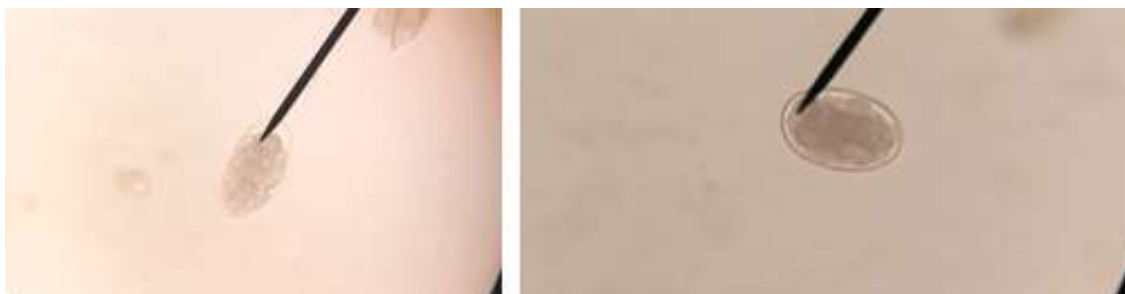

**Figure 24:** Representing sheep with edema under the jaw

## Laboratory investigation and findings

For further investigation of the case, fecal samples collected directly from rectum and immediately processed at Addis Ababa University College of Veterinary Medicine, Veterinary Teaching Hospital multi-laboratory, Bishoftu. Fecal examination for eggs was carried out using floatation method as described by (Hansen and Perry, 1994). Three grams of feces was added to 42 ml of saturated salt solution in a graduated cylinder. The contents were then mixed thoroughly using a glass rod, and were poured through a tea strainer into another beaker. The filtrate was

then filled to 10ml test tube until convex meniscus formed and the cover-slip was putted on the top thoroughly and kept for 20 min in the test tube rack. Finally, the cover-slip was carefully lifted and placed on glass-slide and viewed under a compound microscope X40 objective lens. Thin shelled, embroynated and oval shaped eggs were detected (figure 25). Based on the history, clinical signs and laboratory findings the case was concluded as Hemonchosis and treatment with anti-helminthic was directed.



**Figure 25:** Thin shelled, embroynated and oval shaped eggs of strongyle observed under microscope: magnified: X 40

#### Case managements and treatment outcome

Ivermectin (Sheyang Sunvictotor Pharmaceutical Co., Ltd. /China) at a dose of 0.2mg/kg was prescribed for all of the animals with thorough follow up. Three weeks later communication with the owner revealed that all the animals were successfully revived and resumed to their normal state.

#### Discussion

Hemonchosis is economically limiting factor in sheep production system worldwide and in developing countries in particular. Recent reports elucidated the prevalence of hemonchosis in sheep as 67.57 % Mengist *et al.* (2014), 67.2% Badaso and Addis (2015), 40.9% Gebresilassie and Tadele (2015), 69.6 % Abdo *et al.* (2017), and 56.25% Sewalem *et al.* (2017) in different parts of Ethiopia. Presently, a chronic form of hemonchosis were established in a group of sheep based on clinical picture of anemia, poor body condition and fecal examination of eggs (floatation) which is in line with various works of literature. Accordingly, the chronic forms of hemonchosis are manifested by poor body condition, pale mucus membrane, anemia and

submandibular edema (Constable *et al.*, 2017; Sissay, 2007). Essentially, adult and fourth stage larvae of *Hemonchus* causes hemorrhagic anemia due to their vein puncture lifestyle on the abomasal wall. *Hemonchus* is thought to inject an anticoagulant into the wound so that the host actually loses more blood or the worm ingest. Each worm removes about 0.05 ml of blood per day by ingestion and seepage from the lesion (Urquhart *et al.*, 2003). However, small ruminants suffered from these blood-sucking parasites may be able to maintain their hemoglobin levels as long as their iron and protein intakes are adequate. Nevertheless, if the animals' iron reserves and protein intake are reduced their haemopoietic systems become exhausted and the condition worsens. This integrated loss of albumin protein and blood gives rise anemia, edema and eventually the animal may die.

In the present instances, the animals were treated with ivermectin at a dose of 0.2mg/kg and were successfully revived. A full dose of Ivermectin (IVM) is very effective against gastrointestinal nematodes that are resistant to Albendazole, including *H. contortus*. Ivermectin binds with high affinity to glutamate-gated chloride channels which occur in invertebrate nerve and muscle cells, causing an increase in the permeability of the cell membrane to chloride ions with hyperpolarization of the nerve or muscle cell. Hyperpolarization results in paralysis and death of the parasite either directly or by causing the worms to starve. Paralysis of the pharynx reduces the energy reserves of the parasites and inhibits feeding by blocking pharyngeal pumping. Paralysis of the uterine muscles in female worms can suppress egg production and the release of eggs that are already present in the uterus. In addition, IVM can sterilize female nematodes in several hosts without killing them(Coles, 2005).

In conclusion, Hemonchosis is the first amongst parasitic gastro-enteritis causing diseases of sheep and characterized by edema under the jaw, poor body conditions and anemia due to a blood-sucking lifestyle of the parasite. Hence, early detection and treating of affected animals with appropriate drugs has substantial input in reducing death and economic loss of the disease.

## Acknowledgments

I am grateful to Addis Ababa University College of Veterinary medicine, Veterinary Teaching Hospital in particular Ms. Frehiwot and also, the owner of the animal for his valuable information during the follow up.

## Reference

- Abdo B., Tesfaye W., Agaro A., Eshetu B., Mekuria K. (2017): Prevalence and associated risk factors of small ruminants haemonchosis in Debra-Zeit Elfora export Abattor, Beshoftu town, Ethiopia. *International Journal of Advanced Multidisciplinary Research*, **4**: 30-42.
- Asmare K., Sheferaw D., Aragaw K., Abera M., Sibhat B., Haile A., Kiara H., Szonyi B., Skjerve E., Wieland B. (2016): Gastrointestinal nematode infection in small ruminants in Ethiopia: A systematic review and meta-analysis. *Acta Tropica*, **160**: 68-77.
- Badaso T., Addis M. (2015): Small ruminants haemonchosis: prevalence and associated risk factors in Arsi Negelle municipal abattoir, Ethiopia. *Global Veterinaria*, **15**: 315-320.
- Besier R., Kahn L., Sargison N., Van Wyk J. (2016): Chapter Six - Diagnosis, Treatment and Management of *Haemonchus contortus* in Small Ruminants. In: Gasser RB, Samson-Himmelstjerna GV, editors. *Advances in Parasitology and Haemonchosis Past, Present and Future Trends*. Academic Press. pp. 181-238.
- Coles G. (2005): Anthelmintic resistance looking to the future: a UK perspective. *Research in Veterinary Science*, **78**: 99-108.
- Constable P., Hinchcliff K., Done S., Grundberg W. (2017): *Veterinary Medicine: A Textbook of the Diseases of Cattle, Horses, Sheep, Pigs, and Goats*. UK: Elsevier . 610 p.
- Craig T. (2009): CHAPTER 22 - Helminth Parasites of the Ruminant Gastrointestinal Tract. In: Rings DM, editors. *Food Animal Practice (Fifth Edition)*. Saint Louis: W.B. Saunders. pp. 78-91.
- Gebresilassie L., Tadele B. (2015): Prevalence of ovine haemonchosis in Wukro, Ethiopia. *Journal of parasitology research*, **6**: 34-42.
- George N., Persad K., Sagam R., Offiah V., Adesiyun A., Harewood W., Lambie N., Basu A. (2011): Efficacy of commonly used anthelmintics: First report of multiple drug resistance in gastrointestinal nematodes of sheep in Trinidad. *Veterinary Parasitology* **183**: 194-197.

- Gilleard J., Redman E. (2016): Chapter Two - Genetic Diversity and Population Structure of *Haemonchus contortus*. In: Gasser RB, Samson-Himmelstjerna GV, editors. *Advances in Parasitology and Haemonchosis Past, Present and Future Trends*. Academic Press. pp. 31-68.
- Irma V., Richard C. (2010): Chapter 15 - Glycomics in Unraveling Glycan-Driven Immune Responses by Parasitic Helminths. In: *Handbook of Glycomics*. San Diego: Academic Press. pp. 367-396.
- Hansen J., Perry B. (1994): *The epidemiology, diagnosis and control of helminth parasites of ruminants. A handbook*.
- Mengist Z., Abebe N., Gugsu G., Kumar N. (2014): Assessment of small ruminant Haemonchosis and its associated risk factors in and around Finoteselam, Ethiopia. *Journal of Agriculture and Veterinary Science* **7**: 36-41.
- Nisbet A., Meeusen E., González J., Piedrafita D. (2016): Chapter Eight - Immunity to *Haemonchus contortus* and Vaccine Development. In: Gasser RB, Samson-Himmelstjerna GV, editors. *Advances in Parasitology and Haemonchosis Past, Present and Future Trends*. Academic Press. pp. 353-396.
- Puspitasari S., Farajallah A., Sulistiawati E., Muladno (2016): Effectiveness of Ivermectin and Albendazole against *Haemonchus contortus* in Sheep in West Java, Indonesia. *Tropical Life Science Research*, **27**: 135-144.
- Sewalem M., Kiros H., Bassazin G., Temesgen M., Tarekegn S. (2017): Prevalence of *Haemonchus contortus* of Sheep Slaughtered at Bahir Dar Municipal Abattoir, Bahir City, Ethiopia. *Global Veterinaria*, **18**: 269-276.
- Sissay, M. (2007): Helminth parasites of sheep and goats in Eastern Ethiopia [dissertation].
- Sissay M., Uggla A., Waller P. (2007): Epidemiology and seasonal dynamics of gastrointestinal nematode infections of sheep in a semi-arid region of eastern Ethiopia. *Veterinary Parasitology*, **143**: 311-321.
- Urquhart G., Armour J., Duncan J., Dunn A., Jennings F. (2003): Arrested Larval Development. In *Veterinary Parasitology*. In: Blackwell Services Ltd. Garesington Road Oxford UK.
- Zajac A. (2006): Gastro-intestinal nematodes of small ruminants: life cycle, anthelmintics, and diagnosis. 541. *Veterinary Clinics, Food Animal Practice*, **22**: 541.

#### 4.2.6. Urolithiasis with hematuria in a ram

##### Abstract

A castrated ram with a chief complaint of failure to void urine and reduced feed intake was examined at Addis Ababa University College of Veterinary Medicine teaching hospital on March 12, 2018. The ram was febrile (40.8° C) with increased heart rates (100 beats/min) and congested mucus membrane. There were signs of abdominal pain such as grunting, restlessness and abnormal vocalization in attempts to urinate. The bladder was distended and full; the urethral process of the ram was inflamed. Urine sample was collected by cystocentesis and revealed the presence of blood in the bladder and sediment upon centrifugation. Hence, hematuria was realized. The intervention was made by urethral process excision technique and intravenous oxytetracycline administration (1ml/10kg/day) for three successive days. Immediately following excision, clotted blood and stream of bloody urine was passed. 48-Hour post-treatment the ram was recommenced to its normal state with a good appetite and normal urine output.

**Keywords:** *Hematuria; Ram; Urolithiasis*

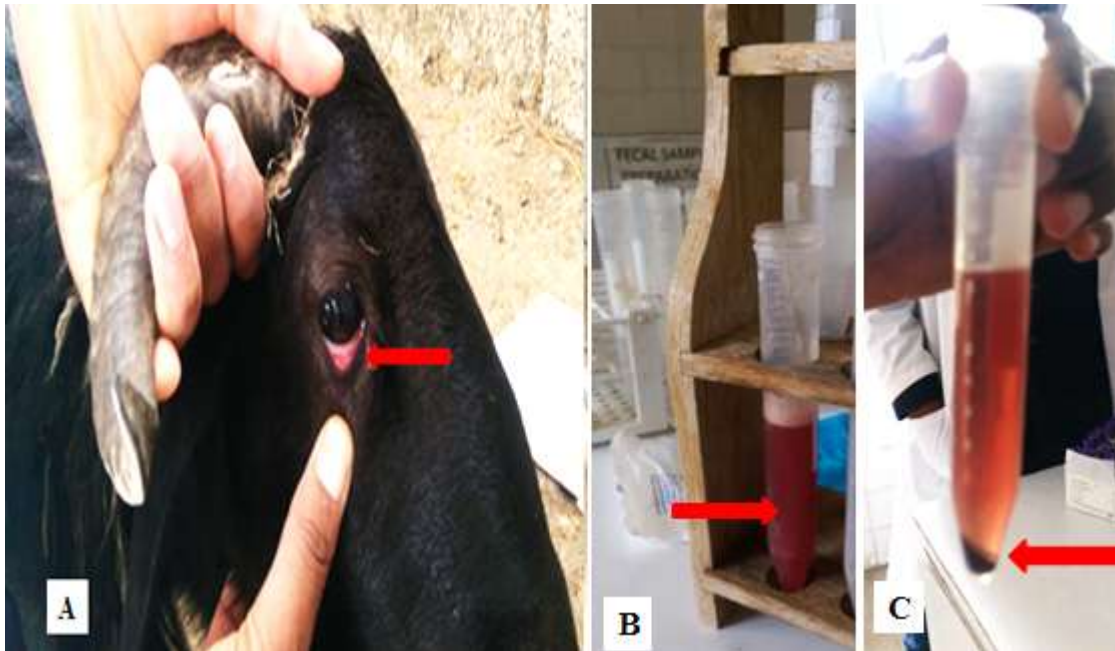
##### Introduction

Hematuria is a condition in which blood or red blood cells are present in the urine and appear red to reddish brown and sediment at the bottom on centrifugation (Sara, 2012). Based on their cause hematuria can be glomerular (medical) or nonglomerular (urologic). Non glomerular causes of hematuria can include lesions in either the kidney or upper urinary tract such as neoplasm, trauma, hemorrhage, urolithiasis, inflammation, infection, toxemia, exercise, cystic disease, and papillary necrosis. Metabolic defects (hypercalciuria or hyperuricosuria) are also associated with hematuria (Harold, 2015; Wachtel, 2007). Postrenal hematuria occurs particularly in urolithiasis and cystitis. Typically, lesions of the kidney, bladder, and proximal urethra cause hemorrhage throughout or toward the end of urination, whereas lesions of the middle and distal urethra are responsible for bleeding at the beginning of urination (Constable *et al.*, 2017).

Urolithiasis is a metabolic disease of ruminant animals characterized by the formation of bladder and urethral crystals, urethral blockage and anuria predisposed by anatomical structure and management factors (Ewoldt *et al.*, 2008). Uroliths in male ruminants most frequently lodge in the distal sigmoid flexure, near the insertion of the retractor penis muscle, or in the vermiform appendage (urethral process) of small ruminants. Additionally, the removal of testosterone by early castration is thought to result in hypoplasia of the urethra and penis. The disease is rare in female ruminants (Underwood *et al.*, 2015). The condition is clinically characterized by syndrome of abdominal pain with restlessness, treading with the hind feet, and swishing of the tail. Abdominal distention ensues as well. The animal may make strenuous efforts to urinate, accompanied by straining, grunting, and grating of the teeth, but these result in the passage of only a few drops of bloodstained urine or anuria (Constable *et al.*, 2017).

#### Case description

A castrated ram with a chief complaint of failure to void urine and reduced feed intake was examined at Addis Ababa University College of Veterinary Medicine teaching hospital on March 12, 2018. The ram was managed intensively and fed 'frushka' and household leftovers. Physical examinations were revealed fever with a rectal body temperature of 40.8°C, tachycardia with a heart rate of 100 beats/min and the respiratory rates was normal (36 breath/min). The ram was depressed and had congested mucus membrane (figure 26A). The ram had signs of abdominal pain including frequent straining accompanied by grunting and abnormal vocalization in attempts to urinate but non-productive (no urine passage). The bladder was distended and full; the urethral process of the ram was inflamed. Urine collected by cystocentesis revealed the presence of blood in the bladder (figure 26B) and upon centrifugation at 5000 rpm for five min; sedimentation was witnessed (figure 26C). Hence, hematuria was realized. Based on the history and clinical findings urolithiasis was suspected and minor excision of the urethral process was suggested with broad-spectrum antibiotic.



**Figure 26:** Congested mucus membrane of the ram (A) and urine by cystocentesis (B) and sediment upon centrifugation (C)

#### Case management and treatment outcome

The case was managed by urethral process excision technique and broad-spectrum antibiotic administration postoperative. Accordingly, the ram was rested on its left side, glans penis exteriorized and the urethral process amputated using a scissor. Following excision, clotted blood was passed first and then stream of bloody urine (figure 27). The ram was treated with broad-spectrum 10% oxytetracycline (Shanghai Thongren Pharmaceutical Co., Ltd, China) intravenously at 1ml/10kg/day for three days. 24-Hour post-therapy the bloody urine was slightly changed but the fever has gone. 48-Hour post-treatment however, the ram was recommenced to its normal state with a good appetite and normal urine output (figure 28). Communication with the owner after a week revealed that the ram was fully recovered.



**Figure 27:** Stream of bloody urine following urethral process amputation (the arrow)



**Figure 28:** Status of the ram 48 hour's post-treatment and normal urine output (the arrow)

## Discussion

Based on the history, clinical findings, urine centrifugation, and treatment outcome, the present case of the ram was concluded as urolithiasis accompanied by hematuria. Uroliths are concretions of solid mineral and organic compounds that cause disease through direct trauma to the urinary tract and obstruction of urinary outflow (Underwood *et al.*, 2015). The clinical signs manifested in the present case mainly sign of abdominal pain and hematuria were suggestive of urolithiasis. Most literature recommends various treatment options based on the degree and site of obstruction

including exteriorizing and amputation of the urethral process that had been done for the present case management (Ewoldt *et al.*, 2008; Constable *et al.*, 2017). This protocol was prioritized based on examination of the inflammation of the exteriorized urethral process (dark-brown) and anatomical positions where urolithiasis most commonly encountered in rams (Ewoldt *et al.*, 2008). Antibiotic oxytetracycline was used in the current case with the suspect of generalization and urinary tract infection as secondary infection based on the suggestive signs including congested mucus membrane, depression, and fever.

#### Acknowledgments

I am thankful to Dr. Cheru Talila and Mr. Hymanot for their contribution.

#### References

- Constable P., Hinchcliff K., Done S., Grundberg W. (2017): *Veterinary Medicine: A Textbook of the Diseases of Cattle, Horses, Sheep, Pigs, and Goats*. UK: Elsevier . 1101 p.
- Ewoldt J., Jones M., Miesner M. (2008): Surgery of Obstructive Urolithiasis in Ruminants. *Veterinary Clinics: Food Animal Practice*, **24**: 455-465.
- Harold C. (2015): Chapter 109 - Hematuria A2 - Sprayberry, Kim A. In: Robinson NE, editors. *Robinson's Current Therapy in Equine Medicine (Seventh Edition)*. St. Louis: W.B. Saunders. pp. 456-459.
- Sara H. (2012): Hemoglobinuria. In: *Clinical Veterinary Advisor*. Saint Louis: W.B. Saunders. pp. 938-939.
- Underwood W., Blauwiel R., Delano M., Gillesby R., Mischler S., Schoell A. (2015): Chapter 15 - Biology and Diseases of Ruminants (Sheep, Goats, and Cattle) A2 - Fox, James G. In: Anderson LC, Otto GM, Pritchett-Corning KR, Whary MT, editors. *Laboratory Animal Medicine (Third Edition)*. Boston: Academic Press. pp. 623-694.
- Wachtel T. (2007): Heart failure, congestive. In: *Geriatric Clinical Advisor*. Philadelphia: Mosby. pp. 90-108.

### 4.3. Case reports on caprine

#### 4.3.1. Treatment outcome of goat pox: A case of four goats

##### Abstract

Goat pox is recognized as the most imperative viral disease responsible for a considerable loss in small ruminant producing enterprises of the world. A treatment outcome of four goats with pox lesions was described in this case report. The goats were febrile and had typical pox lesions which range from few to entire body involvement. Besides, lameness and lacrimation displayed due to lesions in the limbs and conjunctiva, respectively. Based on the history, typical pox lesions and PCR result the cases were confirmed as Goat pox caused by *Goatpox virus*. The cases were managed vigorously with short-acting oxytetracycline at a dose of 10mg/kg/day for five successive days, IM and Flunixin meglumine at a dose of 1.1 mg/kg/day IV, for 3 days. The goats were followed for two months during which two goats were fully recovered while two goats (buck and doe) were died. Therefore, opportune and thorough treatment is essential in reducing mortality and economic loss of the disease. However, prevention through vaccination and isolation of infected and new arrivals is indispensable.

**Keywords:** *Goats; Goat pox; Treatment*

##### Introduction

Goat pox (GTP) is a significant disease in the small ruminant producing industries worldwide and results in a considerable loss in the production and productivity of this sector. Goat pox is enzootic in Africa, particularly in the Northern and Western Sahara, in Middle East and Far East and in Indian subcontinent (Madhavan *et al.*, 2016). The disease is found in all regions of Ethiopia; however, more serious in lowland arid areas than in midland and highland agro ecologies. They are highly prevalent and may reach up 22% and 18% in sheep and goats, respectively (ESGPIP, 2009; Sileshi, 2009). The disease is caused by *Goatpox virus* (GTPV), which is enveloped, double-stranded DNA viruses, classified in the genus Capripoxviruses of the family Poxviridae (Barrett and McFadden, 2008; Quinn *et al.*, 2016; Tulman *et al.*, 2002). GTPV

primarily affect goats, but some isolates can cause mild to serious disease in sheep (CFSPH, 2017).

Goat pox can affect all age groups, both sexes and all breeds, but are more common and more severe in young and old animals and in lactating females. In a susceptible flock, morbidity and mortality may reach 75-100% and 50-100%, respectively depending on the virulence of the agent (Madhavan *et al.*, 2016). Goatpox is highly contagious. The virus is present in nasal and oral secretions for several weeks after infection and can live in scabs that have fallen off the animal for several months. Principally, the virus enters the susceptible animal via the respiratory tract, thus aerosol infection is the usual means of transmission associated with close contact with infected animals. The spread can also be possible via contact with contaminated materials and through skin abrasions produced iatrogenically or by insects (*Stomoxys calcitrans* and other flies) (Constable *et al.*, 2017; James, 2017). The virus is present in the vesicular fluid, scab, milk and blood of infected goats and sheep which are infective for other animals. Clinically the diseases are characterized by pyrexia, generalized skin and internal pox lesions, and lymphadenopathy. There is no specific treatment for sheep pox or goat pox, but supportive treatment may reduce morbidity and complications (CFSPH, 2017). Therefore, this case report describes the treatment outcome of four goats presented with pox lesions.

#### Case description

Four goats were examined at Addis Ababa University College of Veterinary Medicine, Veterinary Teaching Hospital, Bishoftu on March, 14/2018 with the history of reduced feed intake, coughing (the doe, figure 29C), and nasal discharge. According to the owner, a flock of sheep and goats were purchased from Arsi Negelle for marketing before a month and kept together intensively. Previously, one sheep brought with flock displayed similar condition and sold. Upon physical examinations, the goats were depressed and febrile with rectal body temperature reaching (40.5°C- 41.1 °C). Respiratory and heart rates were within the normal range. There were typical pox lesions under the tail (figure 29A& F), between the hind legs (which is sore and responsible for the lameness), on the mammary gland of the doe (figure 29B), in the buccal cavities and eyelids (figure 29E). A doe (figure 29C) and buck (figure 29F) had

lesions covering the entire body. In addition, there was lacrimation (figure 29E) and dried crusts on the nares which block air flow. Based on the history and typical pox lesions, goat pox (GP) was diagnosed tentatively.



**Figure29:** Designating pox lesion on different body of goats

#### Laboratory investigation and findings

The goat with typical lesion was selected for taking tissue sample. A lesion on the left hind limb was selected and the hair over the papule was clipped off. With waterproof marker the area of the papule was marked and with 25 gauge needle 2% lidocaine was infiltrated around the lesion. Using scalped blade No. 24 and thumb forceps, the marked papule was surgically removed and the tissue sample was kept in sterile universal bottle that contain Phosphate-buffered saline (PBS). The area where the sample was taken was cleaned with 1% iodine and covered with gauze for three days. The sample was then transported with cold chain to NVI for molecular identification of antigen.

### Case management and treatment outcome

The treatments of the animals were aimed at reducing further complication, pain and pyrexia. Thus, all patients were treated with Flunixin meglumine (1.1 mg/kg/day IV) for 3 days as antipyretic and anti-pain. Oxytetracycline 10% at a dose of 10mg/kg/day was administered to all for five successive days, IM. And the owner was advised to nurse and separate them from other flocks. The animals were thoroughly monitored during the treatment courses and the rectal body temperatures and appetite were recommencing to normal state gradually but not the lesions. On the 5<sup>th</sup> and 10<sup>th</sup> days the owner was reported that the doe and buck died, respectively. However, the other two goats were in good condition. On the 60<sup>th</sup> day visit the two goats were completely revived from the pox lesions (figure 30).



**Figure 30:** Two months post-treatment recovery from goat pox

### Discussions

*Goatpox virus* (GTPV) is considered the most important poxvirus disease of sheep and goat as it cause significant economic losses due to reduced milk production, increased abortion rates, decreased weight gain, increased susceptibility to secondary bacterial infections, high mortality, and tread embargo (Constable *et al.*, 2017; James, 2017). The current cases were established as goatpox caused by *Goatpox virus* based on history, clinical findings and PCR results. The cases were exhibited relatively similar symptoms indicated in previous works (OIE, 2014; Mirzaei *et*

*al.*, 2015; Constable *et al.*, 2017; CFSPH, 2017; Yune and Abdela, 2017; James, 2017). Accordingly, the most common clinical manifestation of the disease includes fever (41 to 42°C) and skin lesions frequently on hairless areas but in more severe cases, they may cover the entire body (similar with the case of the doe and kid in the current report). These lesions eventually become necrotic and slough and heal by leaving scars in mild cases (similar with the two recovered goats in the current instance). A severe form of the case that may involve internal organs (such as lungs) may terminate with death.

In the current study, the goats were treated with antibiotic coupled with supportive therapy with the aim of preventing further complications and pain. In consistent, Hamid, 2016 indicates early and rigorous therapy is essential to prevent further complications and mortality due to goat pox. However, two goats were died whilst the rest two survived in the current instance. The deaths may be the integrated effect of age of the goats, severity of the case (which involves entire body including internal organs), stress and/or immunosuppression as the goats were new arrivals. Similarly, Madhavan *et al.* (2016) and James (2017) asserted that morbidity and mortality can be influenced by immunity to capripoxviruses, breed of animals, severity, strain of the virus, the age of the animal, stressors and concurrent infections. The authors also elucidated that in imported or newly assembled, immunosuppressed and very old or young animals' morbidity and mortality may reach 75-100% and 50-100%, respectively.

In conclusion, Goatpox cause substantial loss in small ruminant producing enterprises accompanied by higher morbidity and mortality rate. Therefore, to lessen mortality and economic loss once the disease explodes, opportune and thorough management plays enormous role. However, prevention through vaccination and isolation of new arrivals at least for three weeks is indispensable.

#### Acknowledgement

My grateful appreciation goes to Mr. Shelemew, for his valuable information during the follow up.

## References

- Barrett J. W., McFadden G. (2008): CHAPTER 19 - Origin and Evolution of Poxviruses. In: Parrish C, Holland J, editors. *Origin and Evolution of Viruses (Second Edition)*. London: Academic Press. pp. 431-446.
- CFSPH (2017): Center for Food Security and Public Health, Iowa State University. Sheep and Goats pox: *Capripoxvirus* Infections, Capripox . Technical fact sheet. [http://www.cfsph.iastate.edu/Factsheets/pdfs/sheep and goat pox pdf](http://www.cfsph.iastate.edu/Factsheets/pdfs/sheep%20and%20goat%20pox.pdf) accessed on April 27, 2018 .
- Constable, P. D., Hinchcliff, K. W., Done, S. H., and Grundberg, W. (2017): *Veterinary Medicine: A Textbook of the Diseases of Cattle, Horses, Sheep, Pigs, and Goats*. UK: Elsevier . 1591 p.
- ESGPIP (2009): Ethiopian Sheep and Goats Productivity Improvement Program "Common defects of sheep and goats skin in Ethiopia and their causes". Technical Bulletin.
- James M. N. (2017): Chapter 7 - Poxviridae. In: Dubovi EJ, editors. *Fenner's Veterinary Virology (Fifth Edition)*. Boston: Academic Press. pp. 157-174.
- Madhavan A., Venkatesan G., Kumar A. (2016): Capripoxviruses of Small Ruminants: Current Updates and Future Perspectives. *Asian Journal of Animal and Veterinary Advances* **11**: 757-770.
- Quinn P., Markey B., Leonard F., Fitzpatrick F., Fanning S. (2016): *Concise Review of Veterinary Microbiology*. The Atrium, Southern Gate, Chichester, West Sussex, PO19 8SQ, UK: John Wiley & Sons Ltd. 142 p.
- Sileshi Z. (2009): Sheep and goat pox: causes, prevention and treatment. In: Technical bulletin no.29 sheep and goat pox: causes, prevention and treatment.
- Tulman C., Afonso Z., Zsak L., Kutish G., Rock D. (2002): The genomes of sheeppox and goatpox viruses. *Journal of virology*, **76**: 6054-6061.

#### 4.3.2. Listeriosis in a kid/young goat

##### Abstract

Listeriosis is significant bacterial zoonotic diseases worldwide. This case report describes a clinical case of listeriosis in young goat and its treatment outcome. A male kid of around 4-months was examined with the complaint of circling movement and reduced feed intake. The kid was managed semi-intensively with other goats and kept for the commercial purpose. The goats fed household leftover and vegetables from the market. Physical examination revealed that the kid was febrile with a rectal body temperature of 40.8°C while other parameters were within the normal range. There was pedaling movement with head turned to the left. Listeriosis was diagnosed tentatively based on the history and clinical findings. Therefore, the kid was successfully responded to procaine penicillin G at a dose of 20,000 IU/kg/day for five successive days coupled dexamethasone at a dose of 0.2 mg/kg/day for two days treatment. Hence early and aggressive treatment with appropriate antibiotic could be cured the animals.

**Keywords:** *Kid; Listeriosis; Treatment*

##### Introduction

Listeriosis is an infectious disease affecting a wide range of mammals, including ruminants, monogastric animals and humans. The disease is caused by a facultative intracellular Gram positive aerobic non-spore forming coccobacillus bacterial pathogen of genus *Listeria* (Colville and Berryhill, 2007; Ismaela *et al.*, 2009; Dortet *et al.*, 2009; Gebretsadik *et al.*, 2011). The genus is composed of 10 species, two of which are pathogenic. *Listeria monocytogenes*, the most important of these two pathogens, has been implicated worldwide in diseases of many animal species and humans. *Listeria ivanovii* occasionally causes abortions in cattle and sheep. *L. monocytogenes* is considered a ubiquitous organism, which can be isolated from many different environmental sources (surface water, soil, sewage, plant material etc.). The organism can grow over a wide temperature range, from 4 to 45°C, and can tolerate pH values between 5.5 and 9.5 and up to 10% sodium chloride. Based on cell wall and flagellar antigens, 16 serotypes are recognized with serotypes 4b and 1/2 responsible for most cases of disease in animals and

humans (Pezzanite *et al.*, 2009; Dortet *et al.*, 2009; Lorber, 2012; Quinn *et al.*, 2016; Constable *et al.*, 2017).

Listeriosis affects sheep and goats of all ages and both sexes but animals less than three years of age are more commonly prone to clinical disease than older animals (Pezzanite *et al.*, 2009). *Listeria* is an intracellular pathogen with unique potential to spread from cell to cell, thereby crossing blood–brain, intestinal and placental barriers (Actor, 2012; Dhama *et al.*, 2015). Hence, three recognized syndromes of listeriosis are described in domestic animals: 1) septicemic disease of young animals, with involvement of the liver, spleen, and other organs; 2) reproductive disease, associated with metritis, placentitis, and abortion occurring predominantly in sheep and cattle; and 3) meningoencephalitis, more frequently diagnosed in adult sheep, goats, and cattle (Scott, 2007; Garcia *et al.*, 2016). Less common symptoms associated with *L. monocytogenes* infections are mastitis, iritis and keratoconjunctivitis. Dullness, circling and tilting of the head are common clinical signs associated with meningoencephalitis. Unilateral facial paralysis results in drooling of saliva and drooping of the eyelid and ear. Abortion with evidence of systemic illness may occur up to 12 days after infection (Headley *et al.*, 2013; Quinn *et al.*, 2016). Because *L. monocytogenes* multiplies intracellularly, it is largely protected against circulating immune factors (AMI) such as antibodies and complement-mediated lysis. The effective host response is cell-mediated immunity (CMI), involving both lymphokines (especially interferon) produced by CD4+ (TH1) cells and direct lysis of infected cells by CD8+ (Tc) cells (Todar, 2015).

Listeriosis is often a rapidly progressing disease; in encephalitic cases death usually occurs within 2 days to 2 weeks of the first onset of clinical signs. Therefore, rapid diagnosis and timely treatment immediately after onset of clinical signs are necessary (Todar, 2015). Although it is facultative intracellular pathogen, some antibiotics that do not penetrate intracellularly is still effective for treatment of listeriosis. Ampicillin and amoxicillin are often recommended as effective antibiotics for the treatment of listeriosis. Higher doses oxytetracycline at 10mg/kg/day for at least five days and Penicillin G at 44,000U/kg/day for 1-2 weeks are thought to be effective for treatment of listeriosis. In addition to antibiotic therapy, supportive therapy may be necessary. This may include fluid and electrolyte replacement for animals having difficulty eating and

drinking as a result of neurological damage (Wiedmann, 2008; Pezzanite *et al.*, 2009). Therefore, this case report describes the clinical cases of listeriosis and its treatment outcome in young goat.

#### Case description

A male kid of around 4-months was admitted to Veterinary Teaching Hospital (VTH) of Addis Ababa University, college of Veterinary Medicine, Bishoftu in February 01, 2018 with history of circling movement and reduced feed intake. The kid was managed semi-intensively with other goats. The goats were primarily kept for commercial and fed household leftover and vegetables from market. Physical examination revealed that the kid was febrile with rectal body temperature of 40.8°C and 36 breaths/min and 72 beats/min respiratory and heart rate, respectively. There was pedaling movement with head turned to the left (figure 31). Listeriosis was diagnosed tentatively based on the history and clinical findings.



**Figure 31:** Indicating circling movement in kid

#### Case management and treatment

The kid was treated with procaine penicillin G (EPHARM, Addis Ababa, Ethiopia) at a dose of 20,000IU/kg/day for five successive days and dexamethasone (Sokar Healthcare Pvt.Ltd. Gujarat India) at a dose of 0.2 mg/kg/day for two days both intramuscularly. 48-HRs post-treatment, the owner was reported that his goat started eating very well. At the end of the medication (the 5<sup>th</sup>

day) the rectal body temperature was within the normal range (38.7°C) and the kid was recovered.

## Discussion

*Listeria monocytogenes* is known to cause listeriosis in humans and animals with low incidence but high case fatality rate (Gebretsadik *et al.*, 2011). In the present case, a kid (young goat) with a history of circling movement was examined and tentatively diagnosed as listeriosis based on the clinical findings. Scott (2007) indicated that the encephalitis form of listeriosis is readily recognized form and initially affected animals are anorectic, depressed and disoriented. This form is the most common form of the disease in all age groups and usually occurs sporadically, affecting a single animal in a herd or flock or a few individuals over several weeks. The infectious agent *L. monocytogenes* gain access to the brain by invading the sensory nerve endings in the oral mucosa (associated with abrasions of the buccal mucosa from coarse feed or from infection) and migrating over these nerves to the pons, where the trigeminal nerve enters the brainstem. Various combinations of facial paralysis and vestibular ataxia with a head tilt are the most common cranial nerve signs observed in this form of listeriosis (Lahunta and Glass, 2009; Constable *et al.*, 2017).

The current case of listeriosis may be associated with consumption of contaminated vegetables based on the information obtained from the owner. As stated by Lorber (2012), Pezzanite *et al.* (2009), Bortolussi and Mailman (2010) and Constable *et al.* (2017) *L. monocytogenes* is ubiquitous in the immediate environments of the animals including animal feces, human feces, farm slurry, sewerage sludge, soil, farm water troughs, surface water, vegetables, animal feeds, and the walls, floors, drains, and other agricultural and animal products.

Recovery from listeriosis depends on the stage and severity of the condition; early and less severe cases commonly responds to higher dose of antibiotic therapy. If signs of encephalitis are severe, death usually occurs despite treatment. *L. monocytogenes* is susceptible to penicillin, ceftiofur, erythromycin, and trimethoprim/sulfonamide. High doses are required because of the difficulty in achieving minimum bactericidal concentrations in the brain (Wiedmann, 2008;

Pezzanite *et al.*, 2009; Scott and Phil, 2016). The current case report was less severe and managed early hence the kid was successfully responded to procaine penicillin G (20,000 IU/kg/day) and dexamethasone (0.2 mg/kg/day) treatment.

In conclusion, listeriosis is a significant disease both in animal and human with worldwide occurrence. Because of its ubiquitous nature and growth in wide range of temperatures, most cases are related with ingestion of contaminated feeds from the immediate environment of the animals. Although most severe cases end up with death, early and aggressive treatment with appropriate antibiotic could be cured the animals.

#### Limitations

No laboratory confirmation was made for this disease due to lack of facilities and hence treatment was done based on clinical picture only (symptomatic therapy).

#### Acknowledgement

My grateful appreciation goes to Dr. Cheru and the owner of the animal.

#### References

- Actor J. (2012): 12 - Clinical Bacteriology. In: Elsevier's Integrated Review Immunology and Microbiology (Second Edition). Philadelphia: W.B. Saunders. pp. 105-120.
- Bortolussi R., Mailman T. (2010): Chapter 13 - Listeriosis. In: Klein JO, Wilson CB, Nizet V, Maldonado YA, editors. Infectious Diseases of the Fetus and Newborn (Seventh Edition). Philadelphia: W.B. Saunders. pp. 470-488.
- Colville J., Berryhill D. (2007): Listeriosis. In: Handbook of Zoonoses. Saint Louis: Mosby. pp. 108-113.
- Constable P., Hinchcliff K., Done, S., Grundberg W. (2017): Veterinary Medicine: A Textbook of the Diseases of Cattle, Horses, Sheep, Pigs, and Goats. UK: Elsevier . 1591 p.
- Dhama K., Karthik K., Tiwari R., Shabbir M., Barbuddhe S., Malik S., Singh R. (2015): Listeriosis in animals, its public health significance (food-borne zoonosis) and advances in diagnosis and control: a comprehensive review. *Veterinary Quarterly*, **35**: 211-235.

- Dortet L., Veiga-Chacon E., Cossart P. (2009): *Listeria Monocytogenes*. In: Encyclopedia of Microbiology (Third Edition). Oxford: Academic Press. pp. 182-198.
- Garcia J., icheloud J., ampero C., orrell E., driozola E., oreira A. (2016): Enteric listeriosis in grazing steers supplemented with spoiled silage. *Journal of Veterinary Diagnostic Investigation*, **28**: 65-69.
- Gebretsadik S., Kassa T., Alemayehu H., Huruy K., Kebede N. (2011): Isolation and characterization of *Listeria monocytogenes* and other *Listeria* species in foods of animal origin in Addis Ababa, Ethiopia. *Journal of Infection and Public Health*, **4**: 22-29.
- Headley S., Bodnar L., Fritzen J., Bronkhorst D., Alfieri A., Okano W., Alfieri A. (2013): Histopathological and molecular characterization of encephalitic listeriosis in small ruminants from northern Paraná, Brazil. *Brazilian Journal of Microbiology*, **44**: 889-896.
- Ismaela A., Masoud E., El-Nabtityc S. (2009): Potential clinical role of propolis in treatment of clinical ovine and caprine listeriosis. *Veterinary Medical Journal Giza*, **57**: 723-736.
- Lorber B. (2012): 301 - Listeriosis. In: Schafer AI, editors. Goldman's Cecil Medicine (Twenty-Fourth Edition). Philadelphia: W.B. Saunders. pp. 1835-1836.
- Pezzanite L., Neary M., Hutchens T., Scharko P. (2009): Common diseases and health problems in sheep and goats. Kentucky: University of Kentucky.
- Quinn P., Markey, B., Leonard, F., Fitzpatrick F., Fanning S. (2016): Concise Review of Veterinary Microbiology. The Atrium, Southern Gate, Chichester, West Sussex, PO19 8SQ, UK: John Wiley & Sons Ltd. 142 p.
- Scott P., Phil S. (2016): Overview of Listeriosis (Listerellosis, Circling disease). In merck Veterinary Manual.  
<https://www.msdvetmanual.com/generalized-conditions/listeriosis/overview-of-listeriosis>  
 accessed June, 11/2018 .
- Scott, P. (2007): Sheep Medicine. Manson Publishing Ltd. 99 p.
- Todar K. (2015): Listeriosis: In Textbook of bacteriology. <http://textbookofbacteriology.net/Listeria.html> .
- Wiedmann M. (2008): *Listeria monocytogenes*: Transmission and Disease in Ruminants ACVIM 2008. <https://www.vin.com/apputil/content/defaultadv1.aspx?id=3865527&pid=11262>  
 accessed on March 20, 2018 .

## 4.4. Case reports on canine

### 4.4.1. Parvovirus infection in a puppy

#### Abstract

Canine parvovirus disease is a pandemic fatal disease commonly affecting growing pups between 6 weeks and 6 months of age and caused by canine parvovirus (CPV-2). A puppy of around two months of age was examined with a chief complaint of reduced feed intake, runny feces and vomiting. Two days prior to presentation the puppy had treatment at home with unknown drug but not recovered. The physical examination revealed that the vital body parameters were within the normal range. The puppy had pungent odor bloody diarrhea. Besides, the puppy was weak, dehydrated and had poor body conditions. The case was tentatively established as canine parvovirus disease based on history, age and observed clinical pictures. Therefore, the puppy was successfully recovered following antibiotics, fluid and antiemetic therapy. Hence, the case could be cured if treated promptly and vigorously with appropriate drug accompanied by supportive therapy.

**Keywords:** *Canine parvovirus; Puppy*

#### Introduction

Canine parvovirus disease is a pandemic fatal disease of pups caused by canine parvovirus strain-2 (CPV-2) of the family Parvoviridae, genus Protoparvovirus, and species Carnivore protoparvovirus-1 which is characterized by bloody diarrhea and vomiting. Currently, there are three antigenic variants of CPV-2 including 2a, 2b, and 2c. Parvoviruses are non-enveloped, single-stranded DNA viruses (Decaro and Buonavoglia, 2012; James, 2017; Nemzek *et al.*, 2015; Parker and Parrish, 2000; Parrish and Kawaoka, 2005).

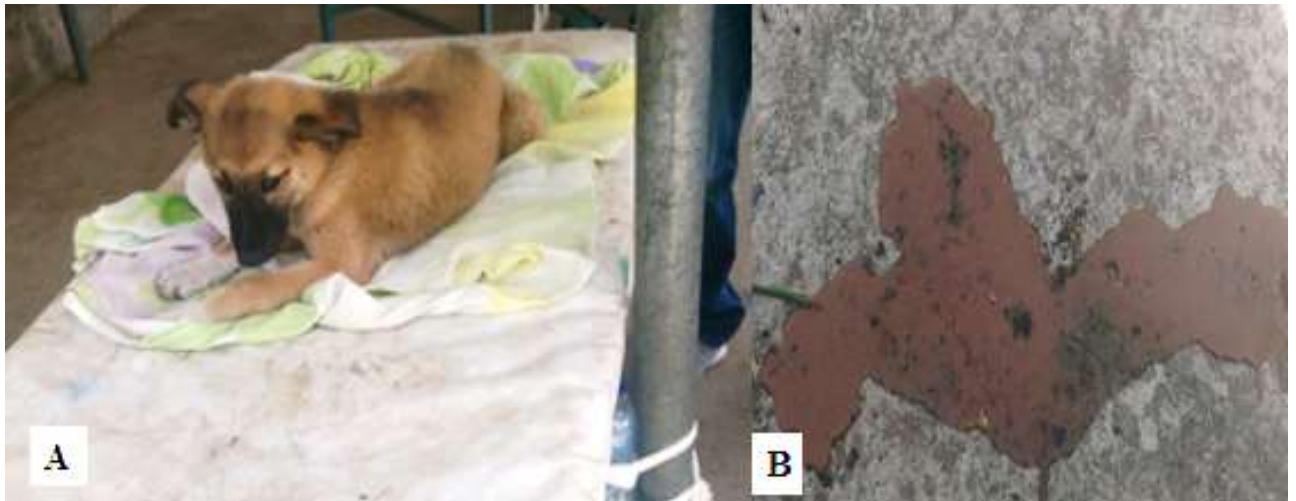All members of the family *Canidae* (dogs, wolves, coyotes) are susceptible to the natural infection with CPV-2 and *Felidae* family specifically cats, mink, and ferrets (James, 2017). The virus is highly contagious and very stable in the environment, so most infections result from the exposure of susceptible dogs to virus-contaminated feces. Severe disease is most common in

rapidly growing pups between 6 weeks and 6 months of age; though, others exhibit mild or subclinical diseases (James, 2017). The viruses have tropism to the gastrointestinal tract and occasionally they can infect bone marrow, myocardium, and nervous tissues thus typically manifested by acute enteritis as a result of infection of crypts and Payer's patches. Clinical signs usually appear 5 days after fecal–oral inoculation and anorexia, fever, depression, vomiting, and profuse hemorrhagic diarrhea are usual. This will accompany by excessive fluid and protein losses through the gastrointestinal tract result in rapid and severe dehydration. At the end affected dogs may develop hypothermia, icterus, or disseminated intravascular coagulation due to endotoxemia (Nemzek *et al.*, 2015). The disease is most severe in puppies and can be fatal (Lawrence *et al.*, 2013).

Although mortality has been reported as high as 91%, prompt and aggressive in-hospital supportive therapy of severely affected puppies survival rates may approach 80–95% (Prittie, 2004). Antimicrobial therapy is also recommended due to intestinal compromise and risk of sepsis (Nemzek *et al.*, 2015). Therefore this report describes canine parvovirus in puppy and its treatment outcome based on tentative diagnosis

#### Case description

A puppy of around two months of age from 05 kebele was examined at AAU-CVMA-VTH, Bishoftu, with a chief complaint of reduced feed intake, runny feces and vomiting. Two days before presentation the puppy had treatment at home with unknown drug but not responded. The physical examination revealed that the rectal body temperature of the puppy was 38.6° C while the respiratory rate and heart rate were 28 breaths/min and 92 beats/min, respectively. The puppy had pungent odor bloody diarrhea (Figure 32B). Besides the puppy was weak, dehydrated and had poor body conditions (figure 32A). It was tentatively spotted as Canine parvovirus disease (CPV) based on the age, history and clinical findings.



**Figure 32:** Indicating a puppy with bloody diarrhea

#### Case management and treatment outcome

The puppy was treated promptly and vigorously based on the tentative diagnosis with broad-spectrum antibiotic Sulfadimidine sodium 33.3% (Hebei Yuanheng Pharmaceutical Co., Ltd, China) at a dose of 1.5 ml/2.5kg body weight as initial dose the first day and 0.75ml/ 2.5kg / day as maintenance dose for the other two days, IM and the fluid resuscitation was made by intravenous infusion of Lactated Ringer's solution (Addis Pharmaceutical factory PLC) (Figure 33). Antiemetic metoclopramide was also administered intramuscularly. The puppy was followed for three successive days during which daily checkup were done at VTH with administration of prescribed drugs. On the second day therapy vomiting was stopped while the diarrhea still there. On the third day visit the puppy was recovered and feed intake recommenced according to the owner.



**Figure 33:** Indicating intravenous rehydration

#### Discussion

Although, CPV mostly diagnosed based on clinical signs such as vomiting, profuse foul-smelling bloody diarrhea and dehydration, documented information concerning the disease are scarce in Africa including Ethiopia (Folitse *et al.*, 2017). Based on the history and clinical findings, the current case of puppy was diagnosed tentatively as canine parvovirus disease. In addition, the age of the dog and the abundance of similar cases were also considered. James (2017) stated that the virus is stable in the immediate environment of animals and severe disease is most common in rapidly growing pups between 6 weeks and 6 months of age. The puppy in the present study shown similar clinical manifestations indicated in various literature including anorexia, depression, vomiting, and profuse pungent hemorrhagic diarrhea (Nemzek *et al.*, 2015; Lawrence *et al.*, 2013).

The treatment protocol followed in the current case was aimed at curing the puppy via resuscitation of fluid deficit due to vomiting and diarrhea, avoiding of further effacing of the intestine by secondary bacteria and ceasing of vomiting. Hence, an intravenous lactated ringer, sulfadimidine sodium for secondary bacterial prevention and antiemetic for vomiting were administered. This is in line with the protocols stated in the literatures indicating rehydration and antimicrobial as integral therapy for puppy with parvovirus (Prittie, 2004; Nemzek *et al.*, 2015; Mitchell, 2017). Unlike current case, these authors also indicated without treatment, canine parvovirus (CPV) infection is often a fatal disease ending in severe dehydration, endotoxin or septic shock, and multiple organ failures. However, aggressive therapy and supportive care will heighten the survival rate up to 85-95%.

In conclusion, canine parvovirus is a common disease of pups characterized by bloody diarrhea, vomiting and severe dehydration. Hence, treatment of the puppies with this disease should be with the aim of reducing continuous loss and prevention of further effacing of the intestine.

#### Limitations

Further laboratory confirmation was not performed for this case because of lack of specific kits for the virus hence the pup was treated based on clinical pictures and other indications.

#### Acknowledgement

I am grateful to Mr. Dereje and Mr. Hymanot

#### References

- Decaro N., Buonavoglia C. (2012): Canine parvovirus: A review of epidemiological and diagnostic aspects, with emphasis on type 2c. *Veterinary Microbiology*, **155**: 1-12.
- Folitse R., Kodie D., Amemor e., Dei D., Tasiame W., Burimuah V., Emikpe B. (2017): Detection of Canine Parvovirus Antigen in Dogs in Kumasi, Ghana. *Journal of Infectious Diseases*, **12**: 28-32.
- James M. (2017): Chapter 12 - Parvoviridae. In: Dubovi EJ, editors. *Fenner's Veterinary Virology (Fifth Edition)*. Boston: Academic Press. pp. 245-257.

- Lawrence J., Andersen P., Leathers V., Workman E. (2013): Chapter 8.1 - Immunoassay Applications in Veterinary Diagnostics. In: The Immunoassay Handbook (Fourth Edition). Oxford: Elsevier. pp. 623-645.
- Mitchell K. (2017): Canine Parvovirus. In: Merck Veterinary Manual. Kenilworth, NJ, USA: Merck Sharp and Dohme corp.
- Nemzek J., Lester P., Wolfe A., Dysko R., Myers J. (2015): Chapter 12 - Biology and Diseases of Dogs A2 - Fox, James G. In: Anderson LC, Otto GM, Pritchett-Corning KR, Whary MT, editors. Laboratory Animal Medicine (Third Edition). Boston: Academic Press. pp. 511-554.
- Parker J., Parrish C. (2000): Cellular Uptake and Infection by Canine Parvovirus Involves Rapid Dynamin-Regulated Clathrin-Mediated Endocytosis, Followed by Slower Intracellular Trafficking. *Journal of virology*, **74**: 1919-1930.
- Parrish C., Kawaoka Y. (2005): The Origins of New Pandemic Viruses: The Acquisition of New Host Ranges by Canine Parvovirus and Influenza A Viruses. *Annual Review Microbiology*, **59**: 553-586.
- Prittie j. (2004): Canine parvoviral enteritis: a review of diagnosis, management, and prevention. *Journal of Veterinary Emergency and Critical Care*, **14**: 167-176.

#### 4.4.2. Management of aural hematoma in a dog

##### Abstract

A one-year-old male dog was presented to Addis Ababa University, College of Veterinary Medicine, Teaching hospital, Bishoftu, with the history of a swollen left ear. Upon physical examination soft fluctuating swelling noticed at the concave surface of the pinnae. On aspiration, hemorrhagic fluid detected and it was diagnosed as aural hematoma and decided for surgical drainage. The case was managed with an incisional technique of intervention followed by loose interrupted vertical mattress suture. Post-operation, a bandage placed after the cavity was flushed with saline solution and penstrip was prescribed at a dose of 1ml/20kg/day for a week. After a month, the case was successfully recovered without repeated drainage and with good cosmetic results.

**Keywords:** *Aural hematoma; Dog*

##### Introduction

Aural or auricular hematoma is a fluctuant swelling filled with hemorrhage fluid affecting the concave surface of the pinna in both dogs and cats. This condition most commonly result of shear forces created by violent head shaking or ear scratching secondary to otitis externa, ectoparasitism, otorrhoea, foreign bodies, hyper sensitivity and allergic dermatitis which leads to rupture of the pinna blood vessel resulting in hematoma formation (Manjunatha *et al.*, 2014). A bloody fluid accumulates under the skin the inner pinna after vascular trauma and separation from the underlying cartilage. The exact location of the source of the hemorrhage is not known but is thought to come from branches of the great auricular arteries and veins within, under or between the cartilage layers. These vessels penetrate the scapha to supply the concave surface of the ear (Brown, 2010; MacPhail, 2016). Various management protocols employed for AH disorder based on the severity and the effectiveness of the procedures. AH fluid aspiration, AH fluid aspiration and dexamethasone infusion and surgical incisions are among the management protocols (Hassan *et al.*, 2002). Surgical intervention is the most commonly used treatment for this case as it effectively prevent recurrence of the hematomas and maintain natural and aesthetic appearance of the ear pinna (Beteg *et al.*, 2011; Hall *et al.*, 2016). Delay intervention may leads to hematoma maturation and fibrin formation. Furthermore, the chronicity drives to fibrosis and

deform the ear (cauliflower contraction) (Eyarefe *et al.*, 2013). Therefore, the current case report describes the surgical intervention treatment of AH in dog.

#### Case description

A one-year-old dog was presented to Addis Ababa University, College of Veterinary Medicine, Teaching hospital, Bishoftu, with a history of swollen left ear since one week (Figure 34). On physical examination the rectal body temperature of the dog was 38.7°C with 32 breaths/min respiratory rate and 88 beats/min heart rate. Soft fluctuating swelling was noticed at medial side (concave surface) of the left ear pinnae. On aspiration hemorrhagic fluid was observed. Flea's infestations were abundant on the body of the dog. Based on the findings it was diagnosed tentatively as aural hematoma and decided for surgical drainage.

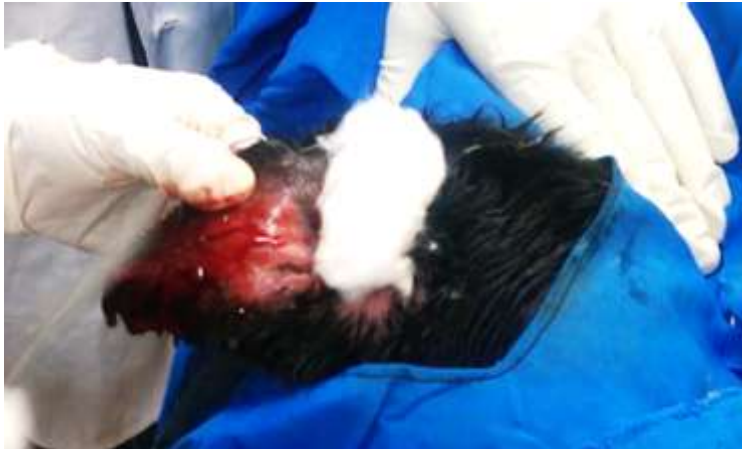

**Figure 34:** A dog with aural hematoma on the left ear (the arrow)

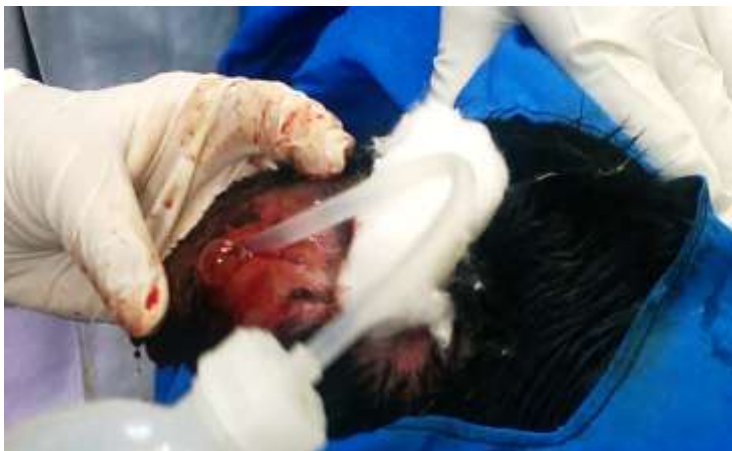#### Case management and outcome

The incisional technique was used during the procedure under general anesthesia. The dog was placed in the right lateral recumbency with the affected ear on the top and aseptically prepared; tramadol 2mg/kg and xylazine 1mg/kg were administered as pre-anesthetic and anesthetized with ketamine 5mg/kg and diazepam 0.5mg/kg intravenously. The longitudinal incision over the length of the hematoma on the pinna's concave surface was made (Figure 35). The incision was made from hematoma's distal edge to its proximal edge, running parallel to the margins of the pinna. Following the incision, the blood was drained using gauze with mosquito forceps. The cavity was flushed with sterile saline solution (figure 36) and povidone iodine. Then loose

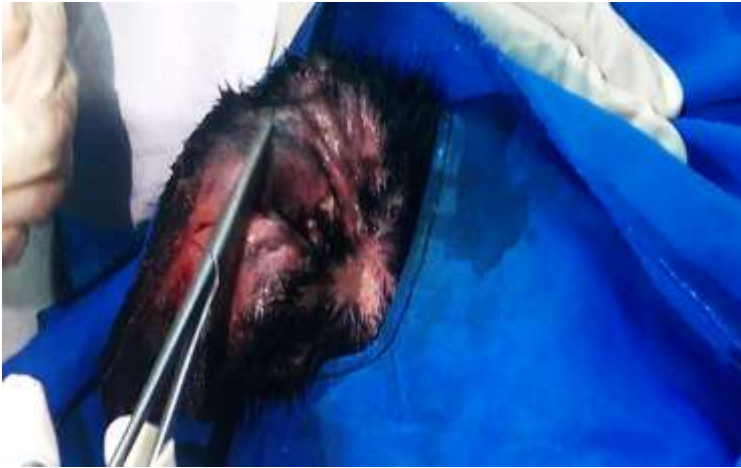interrupted vertical mattresses with non-absorbable sutures were placed through the skin on the concave surface of the pinna (figure 37). Postoperative bandage was placed (figure 38). Finally, broad-spectrum antibiotic penstrip (Chongqing Fantong Animal Pharmaceutical Co.Ltd, China) 1ml/25kg/day, IM was prescribed for a week. After a month, the dog recovered completely (figure 39); the fleas were also successfully treated and no relapse of the hematoma was seen.



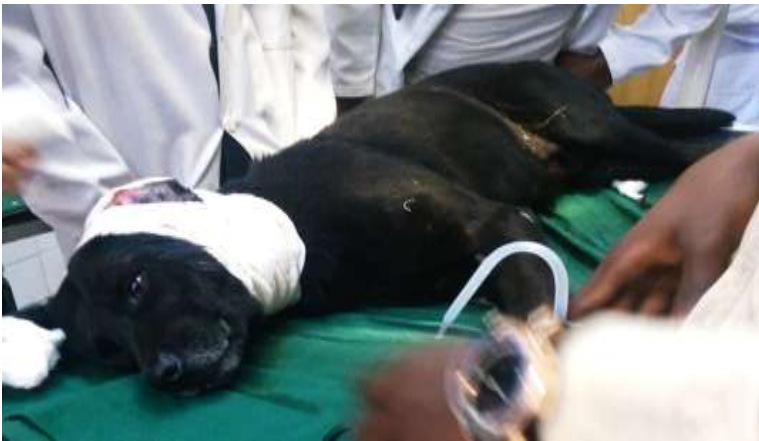**Figure 35:** Longitudinal incision on the concave side of pinna and drainage of hemorrhage



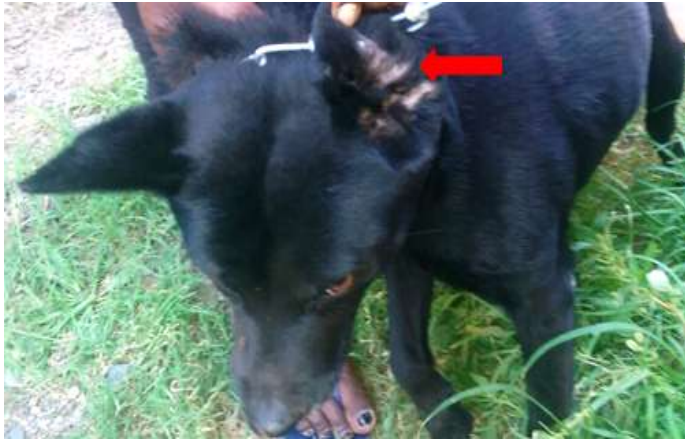**Figure 36:** Flushing of the cavity with saline solution



**Figure 37:** Interrupted suture made parallel to the major vessels



**Figure 38:** The incised ear bandaged



**Figure 39:** A month after treatment the affected ear was healed without recurrence (the arrow)

### Discussion

The dog with swelling of the left ear reported in the current case was diagnosed as aural hematoma based on the clinical findings and removal of hemorrhagic fluid during the incision. A report by Hassan *et al.* (2002) and Beteg *et al.* (2011) concludes that most cases of aural hematoma are associated with traumatic injury and irritation to the ear which leads to head shaking or pawing. In the current instance, flea infestations were observed on the body of the dog and established that the fleas were responsible for the disorder as they can be able to cause irritation (Rodrigues *et al.*, 2016). Presently, surgical intervention technique was done with the aim of removing the hematoma, establish drainage, and prevent recurrence and to retain the pinna's normal appearance by minimizing scar formation. Accordingly the operation was successful, no recurrence observed and the healing was with minimal scar which is in agreement with Beteg *et al.* (2011), Manjunatha *et al.* (2014) and Saibaba *et al.* (2016).

Although not common aural hematoma may occur in dogs associated with traumatic injury and irritation to the ear which leads to head shaking and hence hemorrhage fluid accumulation in the concave part of the ear. Thus, intervention with surgical operation has advantageous over other means of treatment in that it guarantee healing without recurrence and minimal scar and hence less defect.

## Acknowledgement

I am grateful to Addis Ababa University college of Veterinary medicine, Veterinary Teaching Hospital staff in particular Dr. Abebe F and Mr. Dereje Gudeta and also, the owner of the animal for their contribution.

## References

- Beteg F., Muste A., Krupaci A., Scurtu L. (2011): Surgical Treatment in Dog Auricular Hematoma(othematoma). *Bulletin UASVM, Veterinary Medicine*, **68**.
- Brown C. (2010): Surgical management of canine aural hematoma. *Journal of Laboratory Animal*, **39**: 104.
- Eyarefe O., Oguntoye C., Emikpe B. (2013): A Preliminary Report on Aural Hematoma Management with Auricular Pillow Method. *Global Veterinaria*, **11**: 44-48.
- Hall J., Weir S., Ladlow J. (2016): Treatment of canine aural haematoma by UK veterinarians. *Journal of Small Animal Practice*, **57**: 360-364.
- Hassan A., Yila A., Adeyanju J., Hassan F., Adawa D., Jahun B. (2002): Aural haematoma in dogs: a review of 55 cases. *Nigerian Journal of Surgical Research*, **4**: 50-56.
- MacPhail C. (2016): Current Treatment Options for Auricular Hematomas. *Veterinary Clinics of North America: Small Animal Practice*, **46**: 635-641.
- Manjunatha D., Mahesh V., Ranganath L. (2014): Surgical Managmen of Aural Hematoma in Russian Grey Giant Rabbit a Case Raeport. *International Journal of Agricultural Sciences and Veterinary Medicine*, **2**: 37-30.
- Rodrigues N., Quessada A., Silva F., arvalho S., sta N., ima W. (2016): Epidemiology and anesthetic risk in dogs with aural hematoma. ID - 20173094143. *Acta Scientiae Veterinariae*, **44**: 1354.
- Saibaba M., Vani G., Veena R., Suresh V. (2016): Aural Hematoma in Domestic Rabbit (Oryctologos Cunicuulus) - A Case Report. *International Journal of Scientific and Technical Advancements*, **2**: 73-74.

## 4.5. Case report on equine

### 4.5.1. Therapeutic management of tetanus in a cart horse

#### Abstract

Tetanus or lockjaw is fatal disease principally characterized by spastic paralysis caused by a toxin produced by *Clostridium tetani*, a ubiquitous organism, and commensal of a gastrointestinal tract. A cart horse with the complaint of shivering, failure to take in feed and water and unable to walk was examined on February 26, 2018, at SPANA, Ethiopia, Addis Ababa University College of Veterinary Medicine, Bishoftu. The physical examination revealed that the rectal body temperature of the horse was 37.7° C with 32 breaths/min and 64 beats/min respiratory and heart rates, respectively. The third eyelid of the horse was prolapsed (right side) and had stiffened gait and locked jaws (unable to take water and feed). Saliva was drooling from the mouth. There were wounds on body parts and one deep puncture due to nail was seen on the sole of the left forelimb. Based on the history and characteristic clinical features, tetanus was tentatively diagnosed. The horse was treated with ACP (Acepromazine) at a dose of 0.03-0.125/kg body weight, Procaine penicillin G at a dose of 20,000 IU/kg/day for seven successive days and Tetanus antitoxin or TAT with 100 IU/kg therapeutic dose were managed IM. In addition the horse was kept in dark and quiet place. The horse was successfully revived two weeks post treatment. Hence, tetanus could be cured if treated early with appropriate drugs.

**Keywords:** *Cart horse; Tetanus; Treatment outcome*

#### Introduction

Tetanus or lockjaw is an often fatal disease caused by gram-positive, spore-forming obligate anaerobe bacillus *Clostridium tetani* whose spores survive in soil and cause infection by contaminating wounds. It is a ubiquitous organism and a commensal of the gastrointestinal tract of domestic animals and humans (Hassel, 2013; Upadhyay *et al.*, 2013; Constable *et al.*, 2017). Horses and humans are highly susceptible to tetanus toxin, ruminants and pigs are moderately susceptible while poultry is resistant (Quinn *et al.*, 2016). Tetanus continues to be associated with

a high mortality rate, ranging from 58 % to 80 % in equidae (Graener *et al.*, 2015). It is an acute, spastic paralytic illness caused by tetanospasmin, a neurotoxin produced by the vegetative form of *Clostridium tetani* and it is one of the very few diseases where the clinical manifestations are very characteristic (Ismoedijanto *et al.*, 2004). The incubation period is approximately 8 days (range 3 to 21 days).

The most common source of environmental exposure to *C. tetani* bacilli and spores is soil, where the organism is widely but variably distributed. The spores are more common in soils with an alkaline pH and in nutrient-rich soils in warm, moist climates that could more easily support multiplication of the bacillus. Both herbivores and omnivores are reservoirs (harbor tetanus bacilli and spores in their intestines) of *C. tetani* and contaminate the soil by disseminating the organism in their feces. Fecal carriage has been reported in 10% to 20% of horses and 25% to 30% of dogs and guinea pigs; fecal specimens from several other species, including sheep, cattle, and small mammals, also were found to contain *C. tetani* (Fishman, 2009; Roper *et al.*, 2013; Thwaites and Yen, 2014; Underwood *et al.*, 2015).

The organism gains entry to the body via wounds. Although deep, penetrating wounds, such as punctures with sharp materials like snail, are more liable to permit proliferation of *Clostridium tetani*, even superficial wounds can provide suitable anaerobic conditions required for their transition to the vegetative form and replication at the site of infection and to produce toxin (Graener *et al.*, 2015). Accordingly, tetanospasmin toxin is taken up from the site of production into terminals of lower motor neurons and transported axonally to the spinal cord and/or brainstem. Here the toxin moves trans-synaptically into inhibitory nerve terminals, where a vesicular release of inhibitory neurotransmitters becomes blocked, leading to disinhibition of lower motor neurons. Muscle rigidity and spasms ensue, often manifesting as trismus/lockjaw, dysphagia, opisthotonus, or rigidity and spasms of respiratory, laryngeal, and abdominal muscles, which may cause respiratory failure and death (Hassel, 2013).

Although, *Clostridium tetani* grows in anaerobic condition at 37°C on a variety of media (including blood agar), diagnostic and therapeutic decisions should not be made based on the culture, since cultures are frequently negative in patients with clinical tetanus, and routine

bacteriologic studies do not indicate whether a strain of *C. tetani* carries the toxin plasmid (Nathan and Bleck, 2011).

Antibiotics to which the bacilli of *C. tetani* are susceptible include penicillin, erythromycin, clindamycin, tetracycline, chloramphenicol and metronidazole (Thwaites and Yen, 2014). Therefore, the present case report describes the management protocol of tetanus in cart horse.

#### Case description

A stallion with the history of shivering, failure to eat and drink and unable to walk was examined at SPANA, Ethiopia, Addis Ababa University College of Veterinary Medicine, Bishoftu in February 26, 2018. According to the compliant, the condition was seen one day before presentation. The stallion was a cart horse and has shoes on the sole, kept at home after work and fed “frushka”. The physical examination revealed that the rectal body temperature of the stallion was 37.7°C with 32 breaths/min and 64 beats/min respiratory and heart rates, respectively. The third eyelid of the stallion was prolapsed (right side), the hind legs and tail were stiffened (Figure 40 B), had stiff gait and locked jaws (unable to take water and feed) (figure 40C). Saliva was drooling from the mouth (Figure 40A). The stallion had also wounds on his body and one deep puncture due to nail was seen on the sole of the left forelimb (figure 40D). Generally the stallion was poorly managed and had lesions alike epizootic lymphangitis (EZL). Therefore, Tetanus was tentatively diagnosed based on the history and characteristic clinical features noticed.



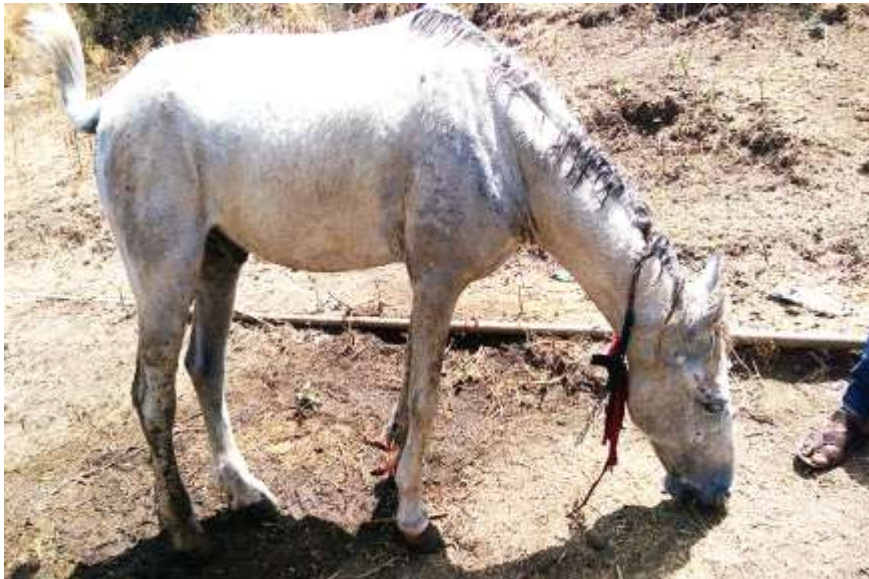**Figure:40** A tetanus case of horse with drooling of saliva (A); stiffen neck and locked jaw(C), and stiffen tail (B).

#### Case management and treatment outcome

The stallion was treated following tetanus management protocols indicated in Constable *et al.*, 2017, i.e. to halt further propagation of the agent, neutralize the circulating toxins, control of muscle spasm. Accordingly, ACP (Acepromazine, Elanco Europe Ltd, UK.) 2mg/ml at a dose of 0.03-0.125/kg body weight, as muscle relaxant was administered IM. Procaine penicillin G (EPHARM, Addis Ababa, Ethiopia) at a dose of 20,000 IU/ kg/day for seven successive days was managed, IM. In addition, Tetanus antitoxin or TAT (serum institute of India Pvt. Ltd, Hadapsar, India) with 100 IU/kg therapeutic dose was managed IM. Besides, the deep puncture due to nail was opened after the shoe removed and irrigated with antiseptic in order to expose the agent to oxygen. Other local wounds on the body of the stallion were also managed with povidone iodine.

Finally, the owner was advised to keep his stallion in quiet (the ear stuck down with cotton) and dark room in order to reduce further spasm and contraction in response to light.

During the successive therapy and visit at home, the jaw movement was gradually improving and started to take in feed and water. On the 14<sup>th</sup> day visit the stallion was fully recovered; walking and jaw movements were resumed to normal (figure 41). Communication with the owner a week later revealed that the stallion was getting back to work.



**Figure 41:** The condition of the horse on 14<sup>th</sup> day visit (post-treatment)

## Discussion

In present instance, a clinical case of tetanus was diagnosed tentatively based on presence of wound and characteristic clinical manifestations. The case may be associated with deep puncture due to nail on the left fore limb of the horse which acquire the agent favorable environment for the transition to vegetative form, multiply and produce toxin; which is in line with various literatures (Fishman, 2009; Roper *et al.*, 2013; Thwaites and Yen, 2014; Underwood *et al.*, 2015c). *Clostridium tetani* produce exotoxins, such as tetanolysin and tetanospasmin. Tetanolysin's function is not clear; however, it is believed to damage healthy tissues around the wound and to reduce oxidation-reduction potential, thereby promoting the growth of anaerobic organisms whereas tetanospasmin is a neurotoxin and is commonly known as tetanus toxin. All recognized tetanus manifestations result from tetanospasmin's ability to inhibit neurotransmitter

release from the presynaptic membrane for several weeks and causing important neurological disorders, which requires a quick medical action and intensive patient care because of the risk of poor prognosis and complications (Fecteau and Sweeney, 2009; Lisboa *et al.*, 2011; Nathan and Bleck, 2011; Simmons and Gibson, 2012; Ferreira *et al.*, 2016).

Similar with the current case management protocol, various works commend manifold tetanus management protocols which includes use of tetanus anti-toxin (TAT) as early as possible, and as soon as the clinical diagnosis is done, in order to neutralize the circulating toxin. Antimicrobial medication against *Clostridium tetani* becomes critical, with the purpose of eradicating the focus of the infection inoculation and propagation. The maintenance of a quiet environment with no light stimuli ensures the reduction of spasms and muscle contractions that worsen the course of the disease (Ferreira *et al.*, 2016; Constable *et al.*, 2017). Most cases of tetanus results in death due to the respiratory failure and dysphagia (due to lockjaw) which is a direct effect of tetanospasmin hence drugs which should decrease spasticity effectively are found imperative (Ismoedijanto *et al.* , 2004). In the present case, drugs such as ACP (Acepromazine), tetanus antitoxin or TAT and Procaine penicillin G which were believed to achieve the above preconditions were used with paramount outcome. The stallion fully recovered after two weeks rigorous therapy.

In conclusion, tetanus or lock jaw is a disease most commonly affecting horses and characterized by spastic paralysis caused by toxin produced by *Clostridium tetani*, a ubiquitous organism and commensal of gastrointestinal tract. Though horses are highly susceptible and most cases terminate with death, instant treatments accompanied by appropriate tetanus management protocols have considerable effect.

#### Acknowledgement

I am grateful to SPANA, Ethiopia staff and the owner of the animal for his valuable information during the follow up.

## References

- Constable P., Hinchcliff K., Done S., Grundberg W. (2017): *Veterinary Medicine: A Textbook of the Diseases of Cattle, Horses, Sheep, Pigs, and Goats*. UK: Elsevier . 1360 p.
- Fecteau M., Sweeney R. (2009): Chapter 63 - Muscular Tone and Gait Abnormalities. In: Rings D, editors. *Food Animal Practice (Fifth Edition)*. Saint Louis: W.B. Saunders. pp. 283-299.
- Ferreira F., Silva F., Campos M., Urno M. (2016): Case Report: Accidental Tetanus. *Journal of Infectious Diseases and Treatment*, **2**: 20.
- Fishman P. (2009): Chapter 34 - Tetanus Toxin. In: Albanese A, Atassi MZ, Dolly JO, Hallett M, Mayer NH, editors. *Botulinum Toxin*. Philadelphia: W.B. Saunders. pp. 406-425.
- Graener D., Barbiae L., Bijader I., Eolig P., Graener G., Selanec J., Zobel R., Stevanoviae V., Samardzija M. (2015): A twenty-year retrospective study of tetanus in horses: 42 cases. *Veterinary Archive*, **85**: 141-149.
- Hassel B. (2013): Tetanus: Pathophysiology, Treatment, and the Possibility of Using Botulinum Toxin against Tetanus-Induced Rigidity and Spasms. *Toxins*, **5**: 83.
- Ismoedijanto D., Nassiruddin M., Prajitno W. (2004): Case report: Diazepam in Severe Tetanus Treatment. *South Asian Journal of Tropical Medicine and Public Health*, **35**: 175-181.
- Lisboa T., Ho Y., Filho G., Brauner J., Valiatti J., Verdeal J., Machado F. (2011): Guidelines for the management of accidental tetanus in adult patients . *Rev Bras Ter Intensiva* **23**: 394-409.
- Nathan B., Bleck T. (2011): Chapter 42 - Tetanus. In: Walker DH, Weller PF, editors. *Tropical Infectious Diseases: Principles, Pathogens and Practice (Third Edition)*. Edinburgh: W.B. Saunders. pp. 284-288.
- Roper M., Wassilak S., Tiwari T., Orenstein W. (2013): 33 - Tetanus toxoid. In: *Vaccines (Sixth Edition)*. London: W.B. Saunders. pp. 746-772.
- Quinn, P. J., Markey, B. K., Leonard, F. C., Fitzpatrick, F. S., and Fanning, S. (2016): *Concise Review of Veterinary Microbiology*. The Atrium, Southern Gate, Chichester, West Sussex, PO19 8SQ, UK: John Wiley & Sons Ltd. 142 p.

- Thwaites C., Yen L. (2014): 32 - Tetanus. In: Hotez PJ, Junghanss T, Kang G, Lalloo D, White NJ, editors. *Manson's Tropical Infectious Diseases (Twenty-Third Edition)*. London: W.B. Saunders. pp. 399-403.
- Underwood W., Blauwiel R., Delano M., Gillesby R., Mischler S., Schoell A. (2015): Chapter 15 - Biology and Diseases of Ruminants (Sheep, Goats, and Cattle) A2 - Fox, James G. In: Anderson LC, Otto GM, Pritchett-Corning KR, Whary MT, editors. *Laboratory Animal Medicine (Third Edition)*. Boston: Academic Press. pp. 623-694.
- Upadhyay S., Hussain K., Singh R. (2013): Bovine Neonatal Tetanus: A Case Report. *Buffalo Bulletin*, **32**: 18-20.

## 5. CONCLUSIONS AND RECOMMENDATIONS

This case study illustrated different diseases including bacteria, virus, metabolic and parasitic from animals examined in VTH and SPANA, Ethiopia of AAU, CVMA. The study also showed that application of thorough clinical case handling protocols, rigorous and prompt treatment with rational drugs and thorough follow-up has a paramount role in reducing the impact of diseases on the animals, the owner and the country in general. Besides, antimicrobial therapy coupled with supportive therapy could minimize the animal suffering and hence facilitate recovery. However, drugs used in this study were not supported with sensitivity tests which may help to select the most effective drugs. Some diseases require due follow-up as inpatient and some require imaging facilities, for better care and diagnosis, respectively.

Based on the above conclusions the following recommendations are forwarded;

- ⊕ Clinicians' or animal health workers must gain training on how to handle clinical cases and follow-up routinely;
- ⊕ Drug sensitivity tests need to be performed particularly for economically significant diseases;
- ⊕ Inpatient animal care facilities need to be constructed in VTH;
- ⊕ Diagnostic imaging tools need to be installed and applied in routine diagnoses
- ⊕ Farmers and farm attendants must get training on handling and management of diseases.

## **ANNEXES**

### **Annex 1: Clinical Case Handling Protocol**

---

Owner's complaint

Signalment of the patient

History of the patient(s)

History of the farm

Observation of the environment

Observation of the animal at a distance

Detailed Examination of the animal (head to tail)

Further investigations (laboratory diagnosis and post mortem examination)

---

Sources:(Jackson and Cockcroft, 2002)

## **Annex 2:** Clinical Examination Protocols, adapted from Jana and Ghosh (2013)

### Recording of Rectal Temperature

Recording of body temperature of animal is most important in clinical diagnosis. Temperature should be recorded while the animal is at rest. Generally rectal temperature is recorded in animals by inserting the bulb of a clinical thermometer in the rectum, placed in contact of the rectal mucosae and keeping it for one to two minutes.

### Recording of Pulse Rate

Usually the pulse rate is equal to the rhythmic contraction and expansion of heart. Increased pulse rate is common and occurs in most cases of septicaemia, toxemia, circulatory failure, excitement and in pain stricken condition. Marked slowing of heart beat (bradycardia) is common in traumatic reticuloperitonitis in cattle.

### *Site for Recording Pulse*

- *Cattle:* Middle coccygeal artery, ventral coccygeal artery under the tail, facial artery, maxillary and median artery; femoral arteries (in case of calf).
- *Dog:* Femoral artery on the inner side of thigh.

### Recording of Respiration Rate

In cattle average respiration rate per minute is 12-16. Variation occurs due to high ambient temperature, after exercise and it is normal. Respiratory rate is accelerated during fever and respiratory distress due to disease. Respiration rate should be noted when the animal is at rest. The type of respiration like costal, intercostal, abdominal, jerkey *etc.* are also to be noted. There is a ratio of 1:3 between respiration rate and pulse rate in healthy animals. Examination of respiration rate of animals is indicated for primary respiratory disease as well as secondary respiratory disease due to cardiac involvement, allergy and anaphylaxis.

### Examination of Visible Mucous Membrane

This includes the examination of conjunctiva, buccal, nasal, vulval, vaginal and rectal mucosae. In normal and healthy condition of animals, the mucous membrane is moist and rosy in colouration. The following changes of mucous membrane are seen in unusual conditions of animals.

- *Congestion:* Signs of fever and inflammation, systemic diseases and allergic sensitization.

- *Paleness*: Revealing anaemia, internal haemorrhage, hypoproteinaemia, excessive blood loss and shock.
- *Yellow discolouration*: Signs of ecterus and hepatic disorder, jaundice.
- *Pin point/Petecheal haemorrhages*: Indicates septicaemia, surra, phosphorus and arsenic poisoning.
- *Cyanotic changes*: Bluish discolouration owing to dyspnoea, hypoxia, venous stasis, congestive cardiac failure, pleurisy, HCN and nitrate poisoning.
- *Ulcerations*: Typical ulcers on oral mucous membrane seen in FMD, PPR and RP.
- *Pinkish*: Equine infectious anaemia.

### Examination of Eyes

Ophthalmic examination gives some clues in diagnosing some diseases.

- *Sunken appearance*: Indicates chronic wasting disease and dehydration.
- *Pupillary reflex*: Loss of pupillary reflex and pupillary response to light are seen in toxemia and shock, poisoning and CNS disease.
- *Dilatation of pupil*: Seen in poisoning and shock.
- *Corneal opacity, ulcers*: Commonly occurs in mechanical injury or trauma. In canine it could also be due to canine distemper.

### Normal Colour of Conjunctiva of Various Animals

*Cattle and Buffalo – Pale pink*

*Horse - Pale roseate*

*Sheep and Goat - Pale pink*

*Pig - Reddish tinged*

*Dog - Roseate*

*Cat - Pale.*

### Palpation

Consistency of an organ or tissues or a part of the body can be felt by lying hand with gentle pressure. Tips of fingers and flat of the hand are mostly used for handling the tissues or organs. When tissue appears firm, hard, solid like muscle, that could be a neoplasm (tumour). When structure appears bone like consistency - it could be the exostosis or ossification of cartilage. Hot

and painful swelling, hard or soft could be the abscess (hard in initial stage, soft in maturity/ripened abscess).

- *Doughy* - Where soft tissues retain finger points, or causes pits on pressure - oedema and impaction of rumen.
- *Cold and painless (fluctuating)* - could be the cyst distended with gas (bloat), distended with food (impaction), distended with fluid (ascites), crepitating sound (Black Quarter or Subcutaneous emphysema). Abnormalities of abdominal and urogenital organs can be felt by rectal palpation.

### Percussion

Striking of any part of the body with a short, sharp blow that enables underlying organs to vibrate and generate an audible sound is called percussion. Drum like sound audible from rumen indicates tympanitis, dull resonance in impaction. Hyper resonant sound is observed while the lungs are filled with excessive air. Increased amount of gases will emit tympanic sound in abdomen. This method is useful in small animals than the large animals.

### Auscultation

It means listening of various functional sounds produced by some thoracic and abdominal organs by use of stethoscope for ascertaining the pathological condition of lungs, pleura, heart and certain parts of alimentary tract. It is useful for hearing peristaltic sounds during ruminal and intestinal contractions, listening sounds produced in course of normal functioning of trachea and lungs (dry rales in congestion and moist rales in exudation), cardiac sounds like cardiac murmurs in valvular disease, splashing sounds in pericarditis and hydro pericardium.

**Annex 3: Clinical Case Recording Form**

ADDIS ABABA UNIVERSITY  
COLLEGE OF VETERINARY MEDICINE AND AGRICULTURE  
Daily Clinical Activity Recording Form

Date: -----

Site/Name of the clinic \_\_\_\_\_ Address \_\_\_\_\_

Owner's name \_\_\_\_\_ Address \_\_\_\_\_ Phone number \_\_\_\_\_

Patient identification:

Species \_\_\_\_\_, Breed \_\_\_\_\_, Sex \_\_\_\_\_, age \_\_\_\_\_, Color \_\_\_\_\_

Markings (Ear tag no) \_\_\_\_\_

History: past immediate, environment, management, feeding and no affected, no at risk, place of origin etc. \_\_\_\_\_

General physical examination: temperature, heart rate, respiratory rate, rumen motility, visible mucous membrane etc...

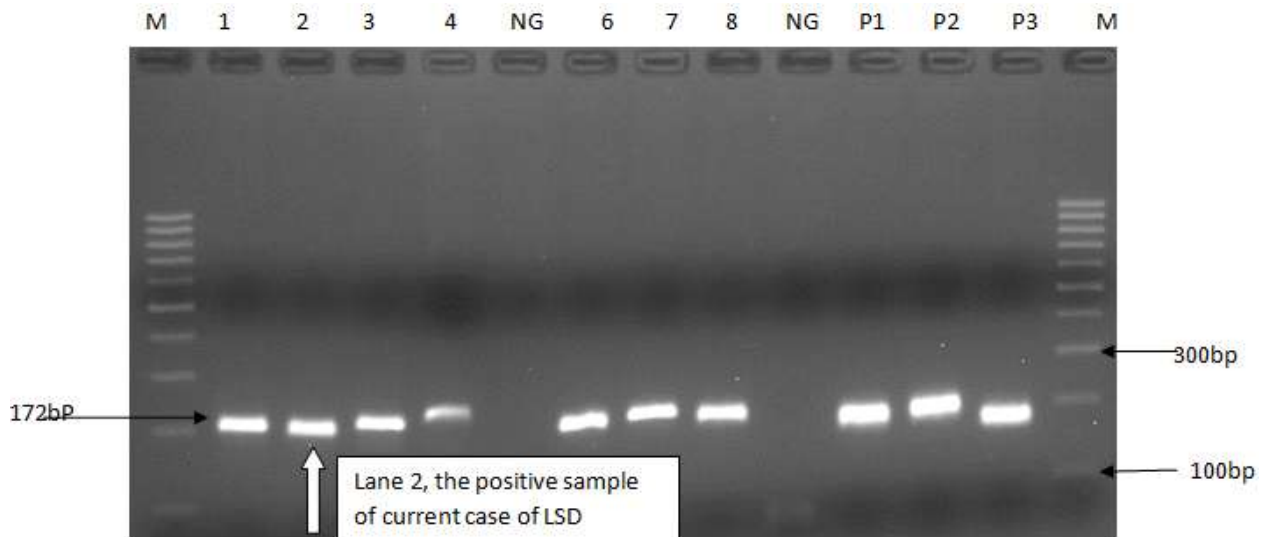
Systemic physical examination: detailed examination of the affected system \_\_\_\_\_

Laboratory diagnosis methods employed Tentative and definitive diagnosis, prognosis \_\_\_\_\_

Treatment: drug, dose, route, regime, follow-up \_\_\_\_\_

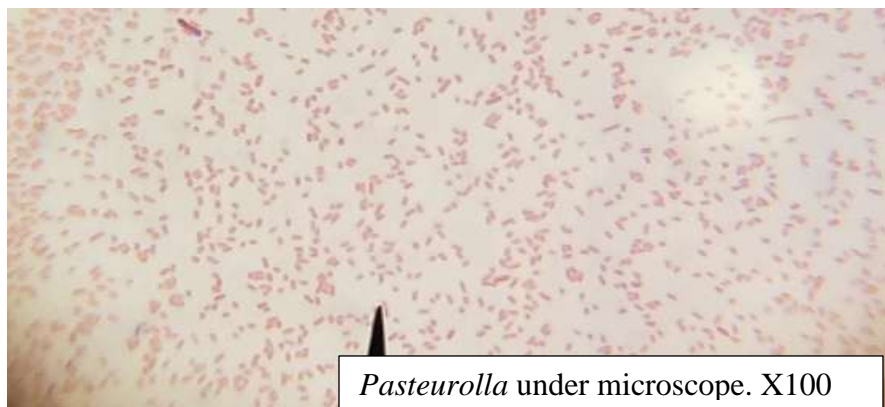
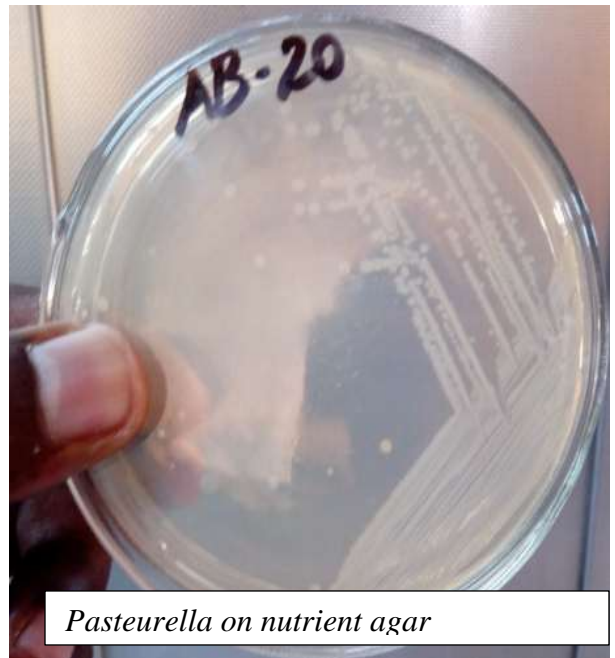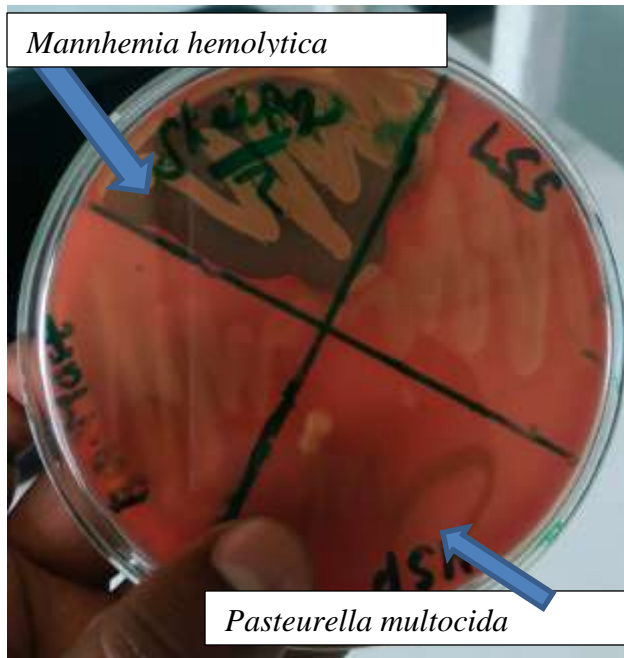
Control & prevention: control methods prescribed, prevention and corrective management measures recommended \_\_\_\_\_

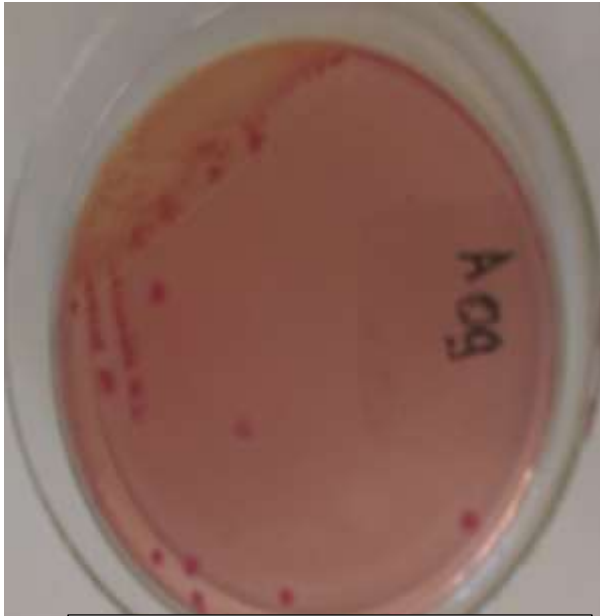
**Annex 4: Positive PCR Result of the Lumpy Skin Disease Suspected Bull**



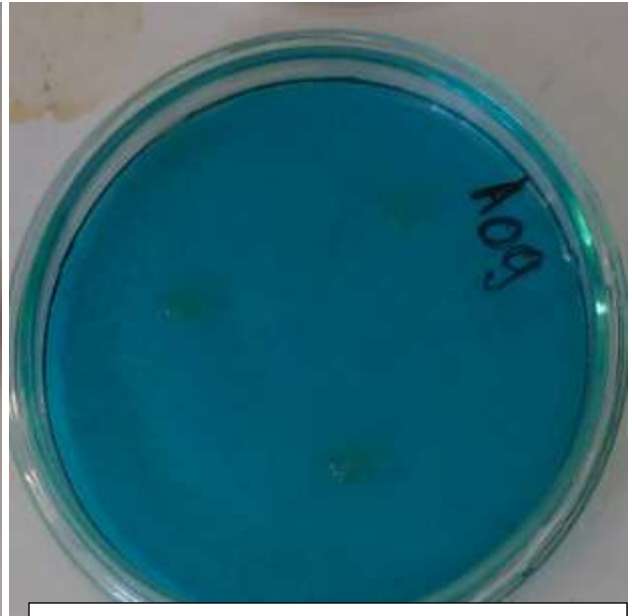
Lane M: DNA marker (Ladder) Lane 1-4 Represent positive sample; where Lane 2 was positive sample for the current LSD case. Lane:5 Represent negative sample Lane:6-8 Represent positive sample Lane: NG Represent negative control Lane:P1 Positive control of LSD Lane:P2 positive control of Goat pox Lane:P3 Positive control of sheep pox

**Annex 5:** Laboratory works (bacteriology)

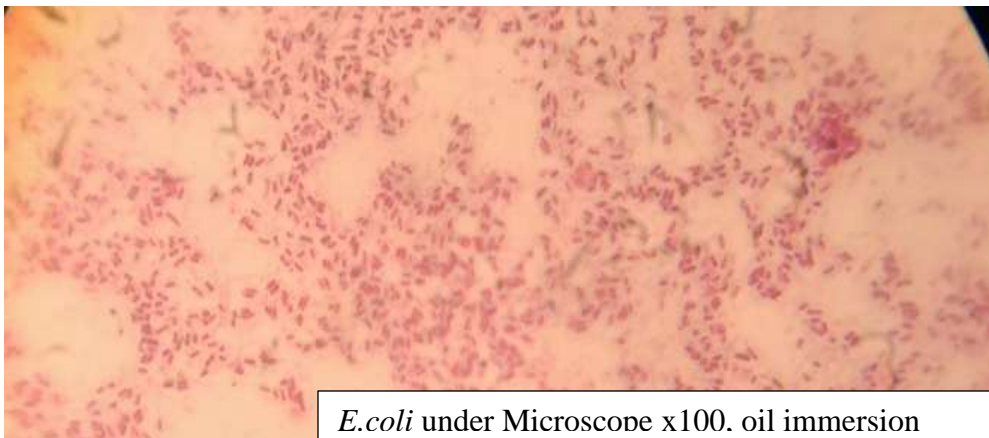




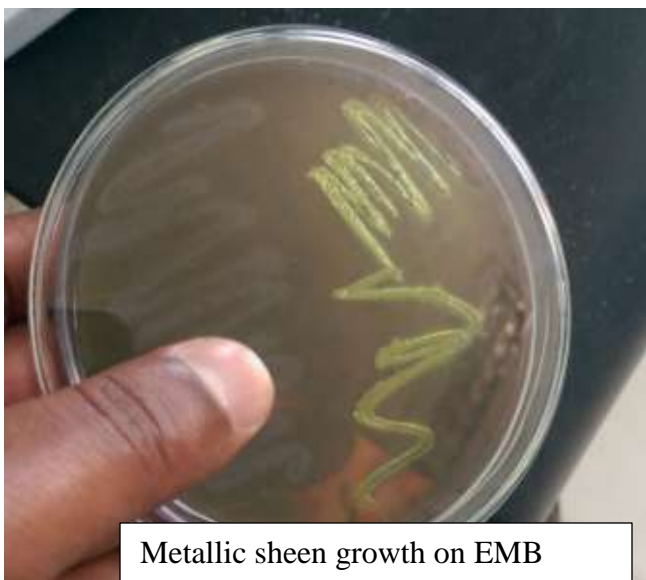Ecoli on S. MaCckonkey




Rappaport broth medium with no growth



*E.coli* under Microscope x100. oil immersion



Metallic sheen growth on EMB



Hemoglobin concentration of the bull with hemoglobinuria

