

Thesis Ref No

**CASE REPORTS ON SELECTED CLINICAL CASES OF DOMESTIC ANIMALS
PRESENTED TO ANIMAL HEALTH FACILITIES IN AND AROUND ADAMA AND
BISHOFTU, ETHIOPIA**

MVSc THESIS



By:

BETHEL BEFEKADU

ADDIS ABABA UNIVERSITY

COLLEGE OF VETERINARY MEDICINE AND AGRICULTURE

DEPARTMENT OF CLINICAL STUDIES

MVSc PROGRAM IN VETERINARY CLINICAL MEDICINE

August, 2021

Bishoftu, Ethiopia

**CASE REPORTS ON SELECTED CLINICAL CASES OF DOMESTIC ANIMALS
PRESENTED TO ANIMAL HEALTH FACILITIES IN AND AROUND ADAMA AND
BISHOFTU, ETHIOPIA**



**Thesis Submitted To College of Veterinary Medicine and Agriculture of Addis Ababa
University in Partial Fulfillment of the Requirements for the Degree of Master of Science
in Veterinary Clinical Medicine**

**By:
BETHEL BEFEKADU**

**August, 2021
Bishoftu, Ethiopia**

SIGNATURE SHEET

Addis Ababa University

College of Veterinary Medicine and Agriculture

Department of clinical studies

As MSc research advisor, I certify that I have read and evaluated this Thesis

Prepared under my guidance by Bethel Befekadu entitled

“Case Reports On Selected Clinical Cases of Domestic Animals Presented To Animal Health Facilities in and Around Adama and Bishoftu, Ethiopia”

Submitted by Bethel Befekadu

Name of the student

Signature

Date

I recommend that it can be submitted as fulfilling the MVSc thesis requirement

Abdi Feyisa (DVM, MVSC, ASSIST.PROF.) -----

Name of adviser

Signature

Date

Department

Haileleul Neguse (DVM, MVSC, ASSOC.PROF.) -----

Name of department head

Signature

Date

APPROVAL SHEET

Addis Ababa University

College of Veterinary Medicine and Agriculture

Department of clinical studies

As members of the Examining Board of the final MSc open defense, we certify that we have read and evaluated the Thesis prepared by: Bethel Befekadu Entitled **“Case Reports On Selected Clinical Cases of Domestic Animals Presented To Animal Health Facilities in and Around Adama and Bishoftu, Ethiopia”** and recommend that it be accepted as fulfilling the thesis requirement for the degree of Masters of Science in veterinary clinical medicine.

Dr.	_____	_____
Chairman (title and name)	Signature	Date

Dr.	_____	_____
Internal Examiner (title and name)	Signature	Date

Dr.	_____	_____
External Examiner (title and name)	Signature	Date

DEDICATION

I dedicate my thesis work to my beloved younger sister Saron Befekadu. I become very excited if you were with me to earn this kind of achievement and follow my steps as you do before but unfortunately God takes you to him which is best for you. Therefore this work is for your unforgettable and missed personality.

STATEMENT OF THE AUTHOR

First, I declare that this thesis is my genuine work and that all sources of material used for this thesis have been properly acknowledged. This thesis has been submitted in partial fulfillment of the requirements for an advanced (MVSc) degree at Addis Ababa University, College of Veterinary Medicine and Agriculture and is placed at the university /college Library to be made accessible to borrowers under rule of the Library, I solemnly declare that this thesis is not submitted to any other institution anywhere for the award of any academic degree, diploma or certificate. Brief quotations from this thesis are allowable without special permission provided that accurate acknowledgement of source is made. Requests for permission for extended quotation from or reproduction of this manuscript in whole or in part may be granted by the head of the major department or the Dean of the College when in his or her judgment the proposed use of the materials in the interest of scholarship. In all other instances, however permission must be obtained from the author.

Name: Bethel Befekadu

Signature: _____

College of Veterinary Medicine and Agriculture, Bishoftu

Date of Submission: _____

ACKNOWLEDGMENTS

First of all I thank father GOD, the head of all knowledge and wisdom, for helping me from the beginning to the end of this thesis work and write up and also in all my life.

Next I would like to thank my advisor Dr. Abdi Feyisa, the young and motivated lecturer for his guidance and encouragement to write a good paper.

It's also my pleasure to extend my gratitude to my beloved families for their non-ceasing love and support especially my father Befekadu Jaleta, my mother Zewdnesch Antewan and my aunt Meseret Jaleta.

I am also thankful to my friends, teachers, VTH staffs, laboratory personals and owners of the animals for their contribution to have this kind of paper.

At last but not the least, I thank Addis Ababa University female scholarship program for sponsoring me this Msc program and offering me a fund to accomplish this thesis.

TABLE OF CONTENT

Contents

DEDICATION	IV
STATEMENT OF THE AUTHOR	V
ACKNOWLEDGMENTS.....	VI
TABLE OF CONTENT	VII
LISTS OF ABBREVIATIONS.....	IX
LIST OF FIGURE	X
LIST OF ANNEXES	XII
ABSTRACT	XIII
1. INTRODUCTION.....	1
2. MATERIALS AND METHODS	3
2.1 Study Area	3
2.2 Study Animals	4
2.3 Study Design and Approaches	4
2.4 Case Reporting Format	6
3. REFERENCES	7
4. SUMMERY OF CASE REPORTS.....	9
5. COMPILED CASES	10
5.1 Diseases Caused By Viral Agents	10
<i>5.1.1 Treatment outcome of Foot and mouth disease in two exotic calves</i>	<i>10</i>
<i>5.1.2 Newcastle disease (NCD) outbreak and intervention in a flock with unknown history</i>	<i>19</i>
<i>5.1.3 Canine parvovirus enteritis (CPE) in 4-month-old puppies</i>	<i>29</i>
<i>5.1.4 Pox lesion in sheep and goat and severe respiratory complex</i>	<i>36</i>
<i>5.1.5 Peste des petits ruminants (PPR) in a doe</i>	<i>45</i>
5.2 Diseases Caused By Bacterial Agents.....	51
<i>5.2.1 Diarrheic calf and the identification of E. coli O157</i>	<i>51</i>
<i>5.2.2 Prophylactic intervention in listeriosis affected flock of goats</i>	<i>72</i>

5.2.3 <i>Brucellosis in ram</i>	83
5.2.4 <i>Urinary tract infection in ram</i>	90
5.2.5 <i>A multifactorial clinical mastitis in cow and heifer</i>	100
5.3 Diseases caused by parasites	110
5.3.1 <i>Diagnosis and treatment approach towards Babesiosis in male and female cattle</i>	110
5.3.2 <i>Flea allergy dermatitis in a dog</i>	121
5.3.3 <i>Otitis in a rabbit</i>	127
5.4 Disease Caused By Fungal Agent	134
5.4.1 <i>Dermatophytosis in puppy</i>	134
5.5 Metabolic Diseases	140
5.5.1 <i>Ruminal acidosis and its treatment outcome in Sheep</i>	140
5.5.2 <i>Hypocalcemia diagnosis approach and the fastest treatment</i>	147
5.6 Diseases Caused By Hormonal Problem	154
5.6.1 <i>Urinary incontinence and other complications in a bitch</i>	154
5.7 Tumor case	163
5.7.1 <i>Canine transmissible venereal tumor in a bitch</i>	163
5.8 Mechanical Disease	174
5.8.1 <i>Sole ulcer in a dairy cattle</i>	174
6. CONCLUSION AND RECOMMENDATIONS	181
7. ANNEXES	182
8. APPENDIX	196

LISTS OF ABBREVIATIONS

AAU	Addis Ababa University
Bid	Twice a day
C-ELISA	Competitive Enzyme-Linked Immunosorbent Assay
CPE	Canine parvovirus enteritis
CPV	Canine parvovirus
CVMA	Collage of veterinary medicine
EDTA	Ethylenediamine tetraacetic acid
FAD	Flea allergy dermatitis
FMD	Foot and mouth disease
FNAC	Fine needle aspiration cytology
HR	Heart rate
MCHC	Mean Corpuscular Hemoglobin Concentration
OIE	World organization for animal health
PABA	Para-aminobenzoic acid
PCV	Packed cell volume
PPR	Peste des petits ruminants
RBC	Red blood cell
RR	Respiratory rate
SAT	South Africa territory
SGP	Sheep and goat pox
Sid	Once per day
TVT	Transmissible venereal tumor
UI	Urinary incontinence
UTI	Urinary tract infection
VTH	Veterinary teaching hospital

LIST OF FIGURE

Figure 1: Map of the study areas	4
Figure 2: Steps of Clinical Diagnosis	6
Figure 3: Clinical signs of FMD infected calves	13
Figure 4: qRT PCR result for FMDV	14
Figure 5: FMD recovered calves	15
Figure 6: NCV Infected chickens in VTH during the first visit	22
Figure 7: Post-mortem result of NCV affected chickens	23
Figure 8: RT PCR result in graph of NCV	24
Figure 9: The status of chickens after the treatment against NCV complications.....	25
Figure 10: CPVE affected puppies	31
Figure 11: Both puppies with CPVE under the intravenous fluid therapy	32
Figure 12: Mick; after recovery on alert standing position and playing	33
Figure 13: Pox affected sheep	39
Figure 14: Pox lesion in the buck	40
Figure 15: PPR affected doe.....	47
Figure 16: Diarrheic calf	54
Figure 17: Green metallic sheen on eosin methylene blue (EMB) agar media.....	55
Figure 18: Different biochemical tests to confirm E-coli.....	56
Figure 19: Positive result expressed by agglutination which indicates E-coli o157	56
Figure 20: The status of the E.coli O157 calf after the treatment	57
Figure 21: Listeriosis affected doe under clinical examination.....	65
Figure 22: listeriosis affected flock	66
Figure 23: Laboratory examination of sample from listeriosis affected flock	67
Figure 24: Listeriosis affected doe under clinical examination.....	75
Figure 25: listeriosis affected flock	76
Figure 26: Laboratory examination of sample from listeriosis affected flock	77
Figure 27: A ram with un-proportional testicle.....	85
Figure 28: Rose bengal test	86
Figure 29: The appearance of proportional testicle after treatment	86

Figure 30: UTI infected ram.....	93
Figure 31: Laboratory work on sample taken from UTI infected ram.	94
Figure 32: The two mastitic cows in their house.....	104
Figure 33: Laboratory result of sample from mastitic cow	105
Figure 34: Babesia affected cattle during urination	114
Figure 35: Additional clinical signs of cattle affected by Babesiosis	114
Figure 36: Laboratory and clinical examinations against bloody urine	116
Figure 37: Giemsa stain in babesiosis affected cattle	116
Figure 38: Good response of babesiosis affected cattle	117
Figure 39: FAD affected dog.....	123
Figure 40: The progress of the FAD affected dog after 1 month	124
Figure 41: Rabbit with otitis.....	129
Figure 42: The ear mite or Psoroptes cuniculi under 10x magnification	130
Figure 43: The normal left ear of rabbit after the treatment.....	131
Figure 44: Puppy affected by dermatophytosis, the affected areas are indicated by arrows..	136
Figure 45: Recovered puppy after antifungal treatment.....	137
Figure 46: Sheep affected by Acidosis.....	143
Figure 47: The status of the ram after treatment against acidosis	144
Figure 48: Hypocalcemic ewes	150
Figure 49: Hypocalcemic ewes after treatment.....	151
Figure 50: Bitch with urinary incontinence.....	157
Figure 51: Ultrasound examination of a bitch with urinary incontinence	157
Figure 52: CTVT affected bitch	166
Figure 53: Fine needle aspiration cytology	167
Figure 54: Sole ulcer in cow.....	177

LIST OF ANNEXES

Annex 1: Principles of Clinical Examination	182
Annex 2: Techniques Used During a Physical Examination	185
Annex 3: General approach to the clinical examination	186
Annex 4: cELISA result of PPR suspected doe	189
Annex 5: Blood chemistry result of urinary incontinent bitch	190
Annex 6: Normal Hematological and organ function tests in domestic animals.....	191
Annex 7: Clinical case recording format	192
Annex 8: Normal body parameters according to standard veterinary treatment guideline	193
Annex 9: Case report writing format	195

ABSTRACT

Animals play significant roles in human lives and economic well-being of countries. Thus, if people want to use animals, they must keep them healthy and handle carefully. Despite considerable efforts to prevent domestic animal diseases, their impact remains to be severe across the world. In Ethiopia, although extensive works have been done in veterinary clinics and hospital to diagnose and treat animal diseases, most of the works are being done empirically and getting well-documented data on clinical cases is challenging. Therefore, this study was aimed to give scientific documents on selected clinical cases of domestic animal in Adama and Bishoftu towns. The case handling began with the owner's complaint, then detailed clinical examinations and treatments were prescribed tentatively and later confirmatory laboratory diagnoses were done either to continue or alter treatments, and recommend prevention and control approaches. The animals were followed until they were fully recovered, either at the clinic during subsequent therapies or at home for diseases with prolonged recovery. Each case report was compiled following a scientific case reporting format and different diagnosis and treatment approaches were used depending on the types of the cases. A total of 19 case reports including 24 single animals and 2 flocks are included in this study. Cattle, small ruminants, dogs, chickens, and rabbit were among the domestic animals addressed. These case reports also include diseases that affect different body systems and various causative agents including bacterial, viral, parasites, fungal, metabolic, hormonal, mechanical and tumor cases. Therefore these case reports address and set scientific steps of disease diagnosis methods, rational treatment approaches of different diseases including treatment trial and prophylactic drug usage and gives evidences for the presence of some uncommon diseases and their impact.

Keywords: *Animals, Case report, Diagnosis, Follow up, Treatment and Outcome*

1. INTRODUCTION

In many part of the world animals signify the entire life of human. The concept of animal's health is a broad notion that range from the health of an animal and human to a global security issue. Keeping animal's health has a great impact in all direction of life including food security, global trade and zoonotic importance (NAP, 2001; Paul, King and Carlin, 2010).

Farm animals have made significant contributions in human lives (Kues and Niemann, 2004). Ethiopia has the largest livestock resource in Africa. A report by the Central Statistical Agency indicates the livestock population of Ethiopia is approximately 183 million this include 56.7 million cattle, 58.4 million sheep and goats, 11.0 million equines (horses, donkeys, mules, and camels) and 56.9 million poultry, housed on 16.5 million holdings. Livestock contribute considerably to Ethiopians' livelihoods and to the national economy. It contributes up to 80 percent of farmers' income in Ethiopia and about 20 percent of agricultural GDP. These contributions largely take the forms of food and nutrition, draft power, farmyard manure/fertilization, income-security and foreign currency (Adam *et al.*, 2018).

Beside food animals and working animals, companion animals have a great role in human life and the relationship between human and companion animals begin before human being engaged into the agricultural activities. Now a day this relationship becomes strong. Pet owners spend enormous amounts of energy, time and money to give what their pets are in need including veterinary expenses (O'Haire, 2010).

As globalization increases animal diseases pose a major effect in the world (Martin *et al.*, 2006). Endemic diseases limit livestock productivity and agricultural development. Their influence is related to direct losses due to mortality and indirect effects due to slow growth, low fertility and morbidity related reductions in productivity, particularly among young animals and reproductive females. These losses have significant economic, food security and livelihood impacts (MoA and ILRI, 2015).

Diseases in veterinary medicine are divided in two broad groups: infectious and non-infectious; Infectious diseases are disorders caused by pathogenic microorganisms, such as

bacteria, viruses, parasites and fungi that can be spread directly or indirectly. Non-Infectious diseases are non-communicable diseases like metabolic, cancer and genetic disorders (Constable *et.al.*, 2017).

Diagnosing and treating individual animal is a very basic thing to minimize suffering of an animal, to improve welfare, increase productivity, to decrease a risk of zoonosis and to satisfy the owners of the animals. Accurate and early diagnosis of diseases are a chief road to effective treatment (Prasad, 2021).

Clinical diagnosis and treatment of diseased animal or a group of animals are big and foremost goals of veterinary medicine. Even diagnosis and treatment of animals are done massively in veterinary clinics, hospitals and home to home services a scientific documented data are not communal to get and often works are done empirically. Therefore the objectives of this compiled case reports are:

General objective

- ✚ To give a scientific document on clinical practices of selected veterinary important diseases of different species in Adama and Bishoftu towns.

Specific objectives

- ✚ Stating diseases condition in different physiological status, age and sex groups of animals
- ✚ Explaining different diagnosis and treatment protocols of different diseases
- ✚ Showing an outcome of a particular animal after a proper intervention

2. MATERIALS AND METHODS

2.1 Study Area

The study has been conducted from December 2020 to June 2021 at Veterinary teaching hospital at Bishoftu (In Addis Ababa University, college of veterinary medicine and agriculture compound) and Adama district veterinary clinic. The study also includes animals reside in their paddock of these specific location. Bishoftu town is located in the East Shewa zone of Oromiya regional state at 47 km South of Addis Ababa on the main road to Adama. The absolute location of Bishoftu is 8°45'N latitude and 38°59'E longitude. Topographically the town is located in tepid to cool sub-moist mid highland at an altitude of about 1920 meters above sea level with moderate weather condition. Farmers in this area are known by using a mixed crop and livestock farming system (Minda *et al.*, 2016; Birhanu *et al.*, 2017). As the Bishoftu town is well known in animal production and medication center, many animal specious visit the teaching hospital and different community services and campaigns take places in this town and its surroundings. Cattle, small ruminant, poultry, equines and pet animals are the major livestock species reared in the area.

Adama is located in East Shoa zone, Oromia regional state, 99 km south east of Addis Ababa. The exact location of the area is 39.1°N and 8.31°E at elevation of 1770 meter above sea level. The area has temperature range from 13.9 °C to 27 °C. The area is featured by mixed livestock-crop production where livestock plays an important role Even exact urban farming data are not adequate in the area the poor populations of the city are dependent of farming like dairy farm (Mulugeta, 2010; Beyene, 2014; Beyene and Assefa, 2015).

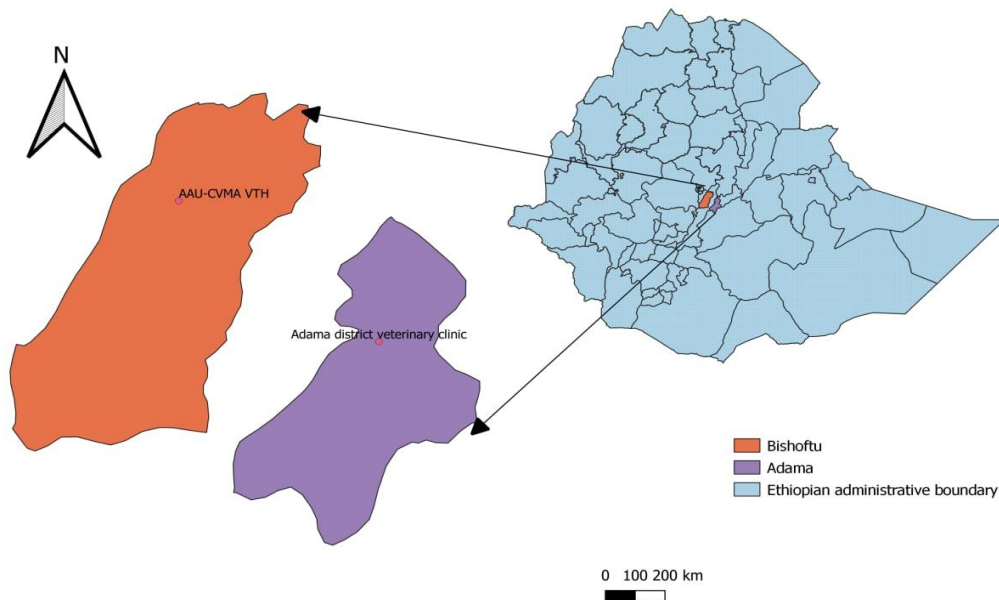


Figure 1: Map of the Adama and Bishoftu towns with veterinary clinic and hospital in these areas.

2.2 Study Animals

The study animals included in this study were cattle, sheep, goats, chickens, dogs and rabbit. Male and female animals, in different physiological status and age groups were included in this study.

2.3 Study Design and Approaches

Descriptive type of case study designs was used to know the details about the study subject by describing the signalment of affected animal like species, breed, age, sex and a detailed description of the clinical signs, diagnosis, treatment, and follow-up of individual animals. Clinical Examination of the individual Animal or groups of animals was begin with history, this include past history, immediate (present) history (which include prior treatment, prophylactic and control measures, Previous Exposure) and management history like nutrition,

reproductive performance and climate conditions. History is then followed by performing a clinical examination that showed in the figure below (figure 2). After complete clinical diagnosis treatments was take place but often treatments were given before the arrival of definitive diagnosis due to time and logistic factors. The third step is advising the owner how to care the diseased animal for example segregating the diseased animal to prevent disease transmission; care associated with the drug like withdrawal period and follows the prescribed drug until the end. Finally follow up was take place until healing or death take place (Jackson and Cockcroft, 2007; Constable *et.al.*, 2017). The principles, techniques and general approach towards clinical examination are given in detail in the annex part (Annex 1-3).

For clinical diagnosis, different approaches depending on the presented cases were used. Mainly problem oriented diagnostic approach was used but complete clinical examination approach for complicated case and evidence based diagnostic approach for unusual cases were used diagnostic approaches. Treatment has been given in evidence based and symptomatic treatment approaches.

To confirm tentatively diagnosed cases appropriate sample is taken and different laboratory tests are performed. These tests include direct microscopy, parasitological tests like flotation and sedimentation, bacterial culture and isolation, pen-side tests, serological test and molecular test like real time PCR test.

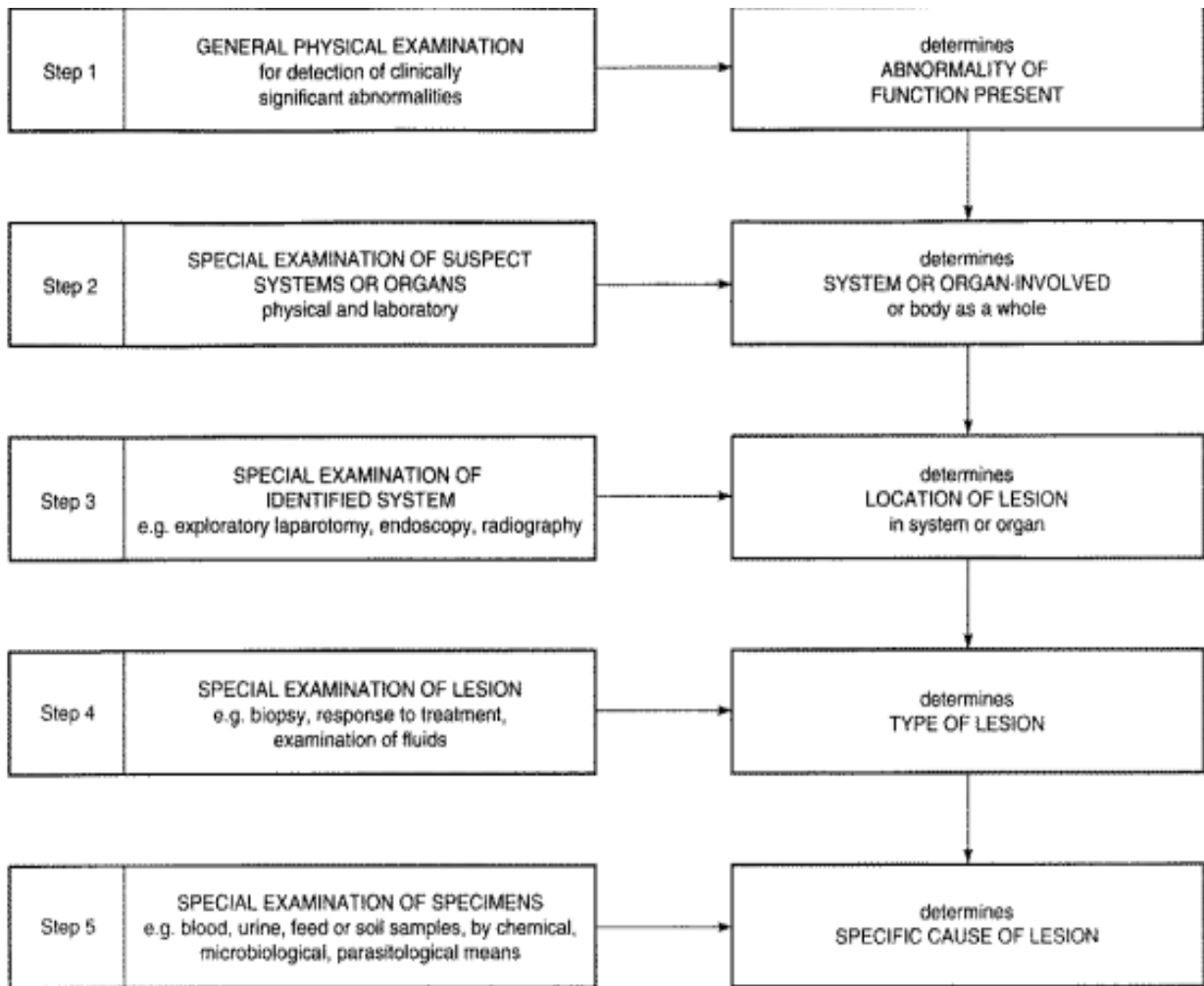


Figure 2: Steps of Clinical Diagnosis

Source (Constable *et al.*, 2017).

2.4 Case Reporting Format

The scientific case reporting format used in this study refer the article entitled “Tips for writing a case report for the novice author” and the detail description put in annex 9 (Sun, 2013).

3. REFERENCES

- Adam, B. *et al.* (2018) ‘Strategies for animal disease control in Ethiopia: A review of policies, regulations and actors’, *Journal of Veterinary Medicine and Animal Health*, **10**(12), pp. 256–265.
- Beyene, T. (2014) ‘Assessment of Plant and Chemical Poisoning In Livestock in Central Ethiopia’, *Journal of Environmental & Analytical Toxicology*, **04**(03), pp. 1–6.
- Beyene, T. and Assefa, S. (2015) ‘Assessment of Rational Veterinary Drugs Use in Livestock at Adama District Veterinary Clinic, Central Ethiopia’, *Journal of Veterinary Science & Technology*, **07**(03), pp. 1–7.
- Birhanu, M. *et al.* (2017) ‘Prevalence of bovine subclinical mastitis and isolation of its major causes in Bishoftu Town, Ethiopia’, *BMC Research Notes*. BioMed Central, **10**(1), pp. 1–6.
- CONSTABLE, P. D. and KENNETH W. HINCHCLIFF STANLEY H. DONE WALTER GRÜNBERG (2017) *VETERINARY MEDICINE 11th edition*.
- Jackson, P. G. G. and Cockcroft, P. D. (2007) *Clinical Examination of Farm Animals, Clinical Examination of Farm Animals*.
- Kues, W. A. and Niemann, H. (2004) ‘The contribution of farm animals to human health’, *Trends in Biotechnology*, **22**(6), pp. 286–294.
- Martin, V. *et al.* (2006) ‘Regional and International Approaches on Prevention and Control of Animal Transboundary and Emerging Diseases’, *ANNALS NEW YORK ACADEMY OF SCIENCES*, **1081**, pp. 90–107.
- Minda, A. G. *et al.* (2016) ‘Seropositivity and risk factors for Brucella in dairy cows in Asella and Bishoftu towns, Oromia Regional State, Ethiopia’, *African Journal of Microbiology Research*, **10**(7), pp. 203–213.
- MoA and ILRI (2015) *Livestock health priorities in the Ethiopia livestock master plan, Ethiopia LMP Brief*.

- Mulugeta, M. (2010) 'Food security attainment role of urban agriculture: a case study from Adama City', *Ethiopian Journal of Business and Economics*, **12**(3), pp. 223–249.
- NAP (2001) 'Animal health at the cross border: preventing, detecting and diagnosing animal disease', in *The national academy press*, pp. 1–24.
- O'Haire, M. (2010) 'Companion animals and human health: Benefits, challenges, and the road ahead', *Journal of Veterinary Behavior: Clinical Applications and Research*. Elsevier Inc, **5**(5), pp. 226–234.
- Paul, M., King, L. and Carlin, E. P. (2010) 'Zoonoses of people and their pets: a US perspective on significant pet-associated parasitic diseases', *Trends in Parasitology*, **26**(4), pp. 153–154.
- Prasad, M. (2021) 'Imaging Techniques in Veterinary Disease Diagnosis', in *Advances in Animal Disease Diagnosis*, p. 43.
- Sun, Z. (2013) 'Tips for writing a case report for the novice author', *Journal of Medical Radiation Sciences*, **60**(3), pp. 108–113.

4. SUMMERY OF CASE REPORTS

In this thesis “selected clinical cases” are presented. The major criteria behind this are the economic importance, frequency and emerging capacity of the disease. A total of 19 types of disease containing 24 individual animal and 2 flocks were the selected study animals.

This study comprises different specious of animal including: 8 cattle, 9 small ruminants and 1 flock of goats, 6 dogs, 1 flock of chicken and 1 rabbit. This study also contains different disease types including infectious and non-infectious. From infectious disease, 5 viral diseases (FMD, Newcastle, parvovirus, pox and PPR), 5 bacterial diseases (Brucellosis, Listeriosis, Diarrhea caused by *E. coli* O157, Urinary tract infection by *E.coli* and mastitis), 3 parasitic diseases (Babesiosis, Flea allergy dermatitis and otitis due to *Psoroptes cuniculi*), 1 fungal (Dermatophytosis). From the non-infectious diseases, 2 metabolic diseases (Ruminal acidosis and Hypocalcemia), 1 mechanical disease (Sole ulcer), 1 hormonal disease (Urinary incontinence) and 1 tumor case (Canine transmissible venereal tumor).

All cases were definitively diagnosed; treatments were given in the right regimen, the prognosis was determined and the cases were followed until recovery or death. Among properly diagnosed, treated and followed 24 individual animals, 15 animals are fully recovered, 6 animals were dead, 2 were refractory and 1 case was euthanized. The goal of the diagnosed and treated animal in the 2 flocks was in order to control and prevent the disease as a flock level and the diseases in the affected flocks were successfully controlled and prevented.

The cases or diseases are put based on the body systems they affect and they reside first. The order starts from the diseases that affect multiple body systems and continue to specific ones.

Therefore generally these compiled case reports address and set scientific steps of disease diagnosis methods, rational treatment approaches of different diseases including treatment trial and gives evidences for the presence of some uncommon diseases and their impact.

5. COMPILED CASES

5.1 Diseases Caused By Viral Agents

5.1.1 Treatment outcome of Foot and mouth disease in two exotic calves

Abstract

Foot-and-mouth disease (FMD) is a highly contagious viral disease that affects cloven-hooved animals, with a higher mortality rate in young stock. On December 2020, different farm owners in Bishoftu reported sore mouths, difficulties in eating, and salivation on their single animal or herd. A case of two calves (one male and one female) in one small-scale dairy farm with a similar complaint is present in this report. Clinical signs such as salivation, a blister on the gum, a sloughed tongue, fever (40.3°C and 39.7°C), and depression were seen during an examination of the calves in their paddock. There has no lesion seen in the foot, and the respiratory and heart rates were within the normal range. The case was diagnosed tentatively as a foot-and-mouth disease based on the history, clinical signs, and outbreak reports of similar cases from other areas; later, the reverse transcriptase-polymerase chain reaction (RT-PCR) confirmed the cases as foot-and-mouth disease caused by FMDV. As supportive treatments, enrofloxacin 10% with a dose of 4 mg/kg/day for five days, and Diclofenac sodium, 2 mg/kg/day for two days, were administered intravenously and intramuscularly, respectively. All clinical signs disappear within a month, and the calves become active and return to normal health. FMD cases are highly fatal in young stocks and this can affect the livelihood of smallholders and further the national economy. Hence, putting stringent prevention strategies and early treatment of diseased animals are essential to save both the animal's life and the income.

Key Words: *Calves, Early intervention and Foot and mouth disease*

Introduction

Foot-and-mouth disease (FMD) is extremely contagious, acute, trans-boundary and notifiable list A viral disease of livestock with high economic consequence and affects both domestic and wild cloven-hooved animals throughout many countries in Africa and Asia. The disease is

caused by FMD virus, family Picornaviridae and genus Aphthovirus, which is highly diverse with seven antigenically distinct serotypes O, A, C, Asia 1, SAT 1, SAT 2 and SAT 3 and with multiple topotypes occurring within each serotype. In Africa except Asia 1 all the different serotypes of the virus are present. In east Africa serotypes circulating serotypes are O, A and South African Territory (SAT–1 and 2) (Gudata, 2019). In Ethiopia O, A, C, SAT1 and SAT2 serotype were identified and according to Ayelet, G. *et.al* Serotype O is predominated, followed by serotype A but type C was not recognized after 1983 (Ayelet et al., 2009). The virus transmitted by ingestion, direct and indirect contact, as well as by aerosols. The SAT1, SAT2 and SAT3 viruses are normally restricted to sub-Saharan Africa (Admassu et al., 2015; Gizaw et al., 2020; Gudata, 2019; Seid, 2020). Ruminants are more susceptible for aerosol transmission than either direct or indirect contact in which they may be infected experimentally by airborne exposure to as little as 10 tissue culture 50% infective doses (TCID₅₀) whereas pigs require more than 10³ TCID₅₀. When this dose is inhaled by recipient animals a proportion of these particles will be deposited in the respiratory system specifically in the pharynx mucus membrane. This is called primary multiplication and after initial replication in the pharynx, the virus spreads through the lymphoid system into the general circulation. Following secondary replication in other glandular tissues, the virus appears in different body fluids such as appearance of frank clinical signs of FMD. Gross lesions develop only in areas subjected to mechanical trauma. Bacterial complication generally aggravates the lesions (Admassu et al., 2015; Alexandersen et al., 2003).

The clinical signs of FMD are anorexia, fever up to 41°C, weight loss, vesicles/blisters on the mucus membranes, especially those of mouth, feet and udder, excess salivation, lameness, reluctant movement and rising due to pain and discomfort from the lesions. The incubation period of FMD virus infection is 2 to 14 days. Even though adult mortality rate is very low, the young animals may die due to multifocal myocarditis which can occur without developing the characteristic blister lesions noted in adult cattle (Aktas et al., 2015; Gudata, 2019). Exotic and cross-bred cattle suffer more severely, with a mortality rate of 10 to 20 percent, against only 2 to 3 per cent in the local breeds (Tufani, 2013).

FMD has no specific treatment because it is a viral disease but symptomatic treatment can be provided to reduce the secondary complications like, lameness and weight loss due to

anorexia. Treatments are only allowed in countries where FMD is endemic. This treatment includes antibiotics, antipyretics, anti-inflammatory agent, local administration of antiseptics, soothing agents and fly repellents. If treatment is not started early the disease may cause complications like sloughing of tongues, hooves and in adult animal teat can also slough (Tufani, 2013). In FMD endemic areas vaccination is the most selective way in preventing and controlling the disease. In Ethiopia the most prevalent serotypes are used in combination for this purpose. Serotype O281 and A110 bivalent vaccine were used for long period of time. But since 2009/2010 many outbreaks were reported due to serotype SAT2 therefore a trivalent inactivated vaccine containing serotype O-ETH/38/2005, A-ETH/7/2008 and SAT2-ETH/76/2009 are used (Admassu et al., 2015; Tadesse et al., 2017).

This economic impact of FMD can be direct losses and indirect loss. Direct loss is due to production decrease and changes in herd structure and the indirect economic losses are related to the significant costs of control and management of the disease (Admassu et al., 2015). The presence of FMD makes the export of live cattle and their products to FMD free countries impossible and cause high economic loss. In Ethiopia for example by Egyptian ban the import of livestock due to the presence of the disease, Ethiopia lost 14.36 million USD, milk yield was reduced by 80% and also other related benefits estimated \$9 per dose (Seid, 2020; Tadesse et al., 2017).

Therefore the objectives of this case report are to assess the influence of FMD in exotic calves and the impact of early intervention.

Case description

In December 2020 different cattle owners in Bishoftu, had similar complaint on their herd of cattle. Mouth sore, difficulty in feeding and salivation on their single animal or as a herd level were there mutual signs of these animals. Some of these were visit Addis Ababa University College of Veterinary Medicine, Veterinary Teaching Hospital and some of them were diagnosed in their paddock. In December 26, 2020 an exotic breed of one eight month old male and one three month female calves were examined in Bishoftu town 04 Kebele in one small holder farm. The chief complaints were wound on the mouth of the calves, unable to feed properly and decreased body condition. On the clinical examination of these calves

depression (Figure 3A) excessive salivation (Figure 3B), blister on the gum, sloughed tongue (Figure 3C), fever (40.3°C and 39.7°C) were found but no lesion was found in limb as well lameness and respiratory and heart rate were within a normal range. The female calf was affected first and then the male but by the first day of examination the male calf has no blister on its mouth but on the next follow-up days the blisters were found. The management system was good in having different barn for the calves and the cows but it is poor in the term of hygiene and feeding. The cows have a vaccination history but the calves have not. Based on history, epidemiology and the visible clinical signs the tentative diagnosis is foot and mouth disease.



Figure 3: Clinical signs of FMD infected calves: (A); Depressed and weak calf due to disease (B); Excess salivation due to FMD and (C); Sloughed tongue due to FMD

Differential diagnosis of FMD

Vesicular stomatitis, Blue tongue, Bovine viral diarrhoea, malignant catarrhal fever (MCF) and Rinderpest.

Laboratory investigation and findings

For further confirmatory diagnosis swab stick was gently rotated in the site of lesion until blood come out or tissue cut off. Then the swab was transported to CVMA, microbiology laboratory by keeping its cold chain, then after 2 months in deep freeze the sample was taken to National Animal Health Diagnostic Center (NAHDIC), Sebeta, Ethiopia. Then a real time reverse transcriptase polymerase chain reaction (qRT-PCR) was made to detect the presence of viral genome by using universal primer. The result confirmed the presence of the virus. Therefore the case was definitively diagnosed as foot and mouth disease.

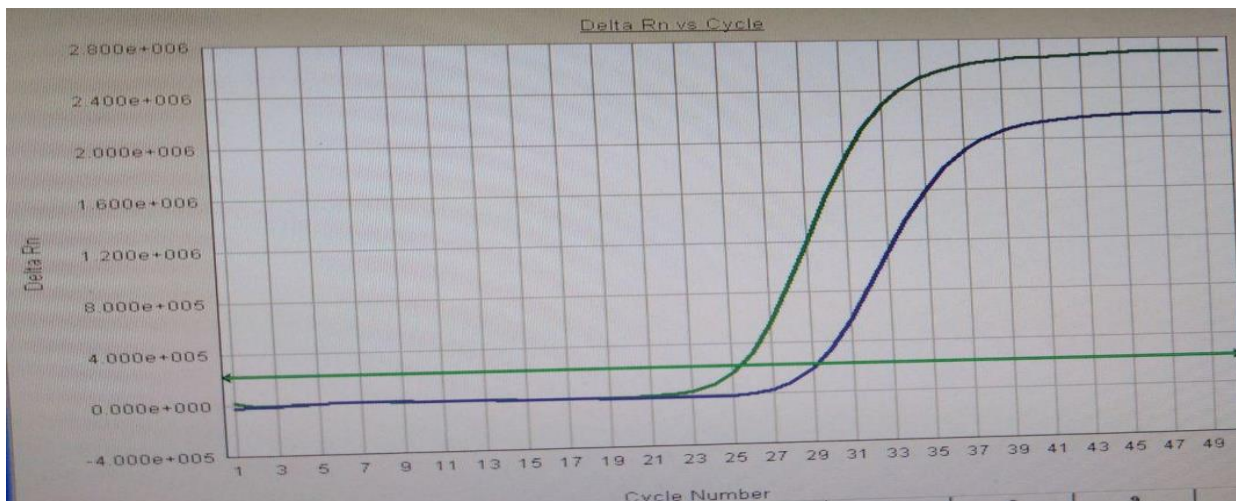

Figure 4: qRT PCR result for FMDV: The two colored lines moving upward represent the two calves sample with a positive result and Ct value of 25.5 and 29.

Case management and follow up

As the suspected disease is a viral disease, the treatment was with the aim of supporting the animal by reducing secondary bacterial complications and pain due to inflammation.

Therefore, Enrofloxacin 10% (Ashienro) injection with a dose of 4 mg/kg/day IV for the first day and then IM for four consecutive days and Diclofenac sodium in 2 mg/kg/day for two consecutive days was given intramuscularly for both calves. The treatments were commenced as soon as possible. Then the owner was advised to give soft feeds for his calves until recovery and also uphold in the way he segregate the infected animals from the healthy cows. After one month the calves become healthy with no previous FMD signs, they become active (Figure 5 A&B) and no scar was left on the gum and tongue (Figure 5C).



Figure 5: FMD recovered calves: (A) & (B); Active calves after recovery from and (C); FMD recovered animals from FMD, no salivation and wound

Discussion

Foot and mouth disease is known by its high morbidity but is not remarkable in high mortality, except in young (less than 6 month) animals. The mortality rate of adult ruminants is about 5 % but the rate can be reach up to 50 % by myocardial damage in young animals. In the current study both calves are survived this might be as a result of early treatment because as Wang et

al reported that timely and accurate recognition of foot and mouth disease is very essential to combat the severity of the disease, means treatment can respond better if it is given early (Aktas et al., 2015; Wang et al., 2018).

According to Constable et.al, and Alhameed and Rhaymah FMD has a clinical signs of high fever (40° to 41° C) accompanied by severe depression and anorexia, followed by painful acute stomatitis. There is plentiful salivation which hanging in long rope-like strings and loss of body weight. Therefore this clinical findings are aline with this case. But there is no lesion or lameness in the feet was found. This might be due to the phatogenesis of the disease in which gross lesions develop only in areas subjected to mechanical trauma, but the calves are not that much subjected to such trauma. Another reason is according to Constable et.al young animals may not show typical vesicular lesions in mouth and feet (Constable.*et.al* 2017; Rhaymah and Abd- Alhameed, 2010).

As FMD is a viral disease we had taken only supportive cares. OIE measures for FMD in endemic countries or regions agree with this measure. This is a combination of antibiotic in order to prevent secondary infection and anti-inflammatory to reduce pain and inflammation due to the virus. Enrofloxacin was an antibiotic drug used in order to prevent secondary bacterial complication this is supported by the work of Tufan which recognizes the effectiveness of this drug. After the treatment all the clinical signs are removed and become healthy and start to eat properly by 1 week time as indicated in Constable et.al, in which eating is resumed in 2 to 3 days as lesions heal, but the period of recovery may be as long as 6 months (Aftosa, 2015; Constable et.al, 2017; Tufani, 2013).

Conclusion

FMD is a viral disease with high morbidity in all age group of cattle and high mortality in calves but if early intervention is applied the impact of the disease can has mitigated and to suspect FMD lesion on foot and lameness are not be mandatory clinical signs.

Acknowledgement

I am thankful to Mr. Dereje Gudeta and Dr. Eyerusalem Fetene.

References

- Admassu, B. *et al.* (2015) ‘Review on Foot and Mouth Disease: Distribution and Economic Significance’, *Academic Journal of Animal Diseases*, **4**(3), pp. 160–169.
- Aftosa, F. (2015) ‘Foot and Mouth Disease Foot and Mouth Disease’, *CFSPH*, (3), pp. 1–9.
- Aktas, M. S. *et al.* (2015) ‘Myocarditis associated with foot-and-mouth disease in suckling calves’, *Veterinary Archives*, **85**(3), pp. 273–282.
- Alexandersen, S. *et al.* (2003) ‘The Pathogenesis and Diagnosis of Foot-and-Mouth Disease’, **129**(03), pp. 1–36.
- Ayelet, G. *et al.* (2009) ‘Genetic characterization of foot-and-mouth disease viruses, Ethiopia, 1981-2007’, *Emerging Infectious Diseases*, **15**(9), pp. 1409–1417. .
- CONSTABLE, P. D. and KENNETH W. HINCHCLIFF STANLEY H. DONE WALTER GRÜNBERG (2017) *VETERINARY MEDICINE 11th edition*.
- Gizaw, D. *et al.* (2020) ‘Molecular characterization of foot-and-mouth disease viruses circulating in Ethiopia between 2008 and 2019’, *Transboundary and Emerging Diseases*, **67**(6), pp. 2983–2992.
- Gudata, D. (2019) ‘A Review on Foot and Mouth Disease - Ethiopian Prospective’, *veterinary clinical science*, **07**(02), pp. 27–36.
- Seid, H. A. (2020) ‘Review on the Epidemiology and Economic Impacts of Foot and Mouth Disease in Ethiopia’, **9**(2), pp. 92–103.
- SH. Rhaymah, M. and A. Abd- Alhameed, M. (2010) ‘Clinical study of foot and mouth disease in feedlot calves in Mosul region’, *Iraqi Journal of Veterinary Sciences*, **24**(1), pp. 11–16.
- Tadesse, B., Alamir, K. and Demssie, E. (2017) ‘Review on the Control of Foot and Mouth Disease by Vaccination’, *International Journal of Basic and Applied Virology*, **6**(2), pp. 9–18.

Tufani, N. A. (2013) ‘Complications of foot and mouth disease in cattle and their clinical management’, *Progressive research*, **8**(1), pp. 127–129.

Wang, X. *et al.* (2018) ‘Chinese guidelines for the diagnosis and treatment of hand, foot and mouth disease (2018 edition)’, *World Journal of Pediatrics* **14**(5), pp. 437–447.

5.1.2 Newcastle disease (NCD) outbreak and intervention in a flock with unknown history

Abstract

Newcastle disease (NCD) is a highly contagious and economically damaging viral disease that affects chickens all over the world. It is marked by high mortality, which in unvaccinated flocks might reach 100%. This case study describes a NCD outbreak at a small-scale poultry farm in the Bela sub-city of Addis Ababa, Ethiopia. This farm began with 75 chickens with no previous flock history. When the owners visited the veterinary teaching hospital in Bishoftu, 15 chickens were died and 10 chickens were sick with a history of reduced feed intake, coughing, wing dropping, neck twisting, and incoordination. In addition, there were greenish watery diarrhea and depression. Hemorrhages in the trachea, gut, proventriculus, and cloaca were discovered during post-mortem exams for gross pathological evaluation on two of the sick chickens. Further, at the National Animal Health Diagnostic Center (NAHDIC), pooled tracheal and cloacal samples were obtained for confirmation of the case using Real-time reverse transcriptase-polymerase chain reaction (RT-PCR), which confirmed the cause of the sickness as New-castle disease virus (NCDV). To save the lives of the remaining chickens and prevent economic losses, enrofloxacin oral suspension (1ml per one liter of drinking water) was administered to 10 chickens with evident clinical signs for 5 days in a row. All fifty-eight (58) chickens were administered resergen oral immune stimulant suspension at a dose of 1g/5lit until excellent development was warranted. Finally, the remaining 27 chickens healed completely and began producing eggs. Thus, to avoid economic harm to the farm or perhaps the country, poultry farming should be done using flocks that have a recognized history.

Key words: *Enrofloxacin, Immune stimulant, New castle disease and Vaccination*

Introduction

Newcastle disease is well known by its most significant and economically important disease in the poultry industry worldwide. Chickens are particularly susceptible species and morbidity and mortality rates can reach up to 100%. In developing countries outbreaks in backyard chickens have a great impact on in chickens health (Narayanan *et al.*, 2010; CFSPH, 2016).

Newcastle disease virus (NDV), also called avian paramyxovirus serotype 1, is the causative agent of new castle disease. This virus is belongs to the genus Avula and family Paramyxoviridae. NDV is enveloped, single-stranded negative sense RNA virus and has approximately 15 kb genome that contains six genes encoding major structural proteins and the main protein that contribute for the pathogenesis NCV is F protein precursor as well as the presence of a number of basic residues in the fusion protein cleavage site According to their pathogenicity these virus can be categorized into three main groups. velogenic strains, highly pathogenic one, cause severe intestinal lesions with neurological disease, resulting in high mortality in chickens. Mesogenic viruses have intermediate virulence and cause respiratory disease. The Lentogenic isolates do not usually cause any disease in adult birds and are considered to be mildly virulent or avirulent (Miller and Afonso, 2011; Mulisa *et al.*, 2014).

Newcastle disease is transmitted through direct contact with infected birds. When infected birds are introduced into susceptible flocks all birds will be infected within 2 to 6 days. Aerosol transmission is another important route of transmission. This disease can affect around 230 species of birds including poultry. NCD also can cause conjunctivitis in human because it has mild zoonotic importance (Yune and Abdela, 2017).

Various clinical signs are present in NCD affected animal that depend on the virulence and tropism of the NCD virus involved, the species, age of host and the immune status of the host and environmental conditions. Initial clinical signs vary but include anorexia, lethargy, ruffled feathers, edema and injection of conjunctiva. As the disease progresses, birds may develop watery greenish or white diarrhea, and dyspnea. In later stages of the disease, neurologic signs including; wing/leg paresis or paralysis, tremors, spasms, torticollis and aberrant circling behavior are evident. In layers sharp egg drop abnormalities in egg can be seen (Alders, 2001; Getabalew.M, Alemneh.T and Getahun, 2019).

Clinical diagnosis is made based on history, clinical signs and post mortem findings to establish a strong tentative diagnosis but many other diseases like infectious bronchitis, infectious laryngotracheitis and avian influenza can have similar characteristics. Therefore the laboratory confirmation by diagnostic assays such as Enzyme linked immune-sorbent assay (ELISA), haemagglutination (HA) and haemagglutination inhibition (HI) test, virus neutralization test, plaque neutralization test and reverse-transcriptase polymerase chain

reaction (RT-PCR) are used for confirmation of the ND virus (MSD, 2012; Sahlu, 2015; Bhutia *et al.*, 2017). Real-time PCR is now one of the most important techniques for the detection and monitoring of NCV infections because real-time PCR is sensitive and specific in a rapid format (Al-habeeb and Mohamed, 2013).

The general approaches to the control of Newcastle disease are sanitization (cleaning, disinfection, limiting access to wild birds and personal hygiene) and vaccination, which is the most effective way. As a treatment no specific treatment is found for Newcastle disease but antibiotics can be given for 3–5 days to prevent secondary bacterial infections like *E. coli* (Butcher, Jacob and Mather, 2018; Getabalew.M, Alemneh.T and Getahun, 2019).

Therefore the objective of this case report is to show the diagnosis and treatment approaches and the impact of those interventions towards New Castle outbreak in a small scale farm.

Case description

On January 12, 2021, two owners arrive with their two chickens, which have been severely affected by an unknown disease that has spread over their farm in Addis Ababa's Bela sub-city. There were 75 chickens in the farm, but 15 of them were dead when they arrived at the veterinary teaching hospital in Bishoftu, Ethiopia and 10 chicks suspected of having the same condition were isolated. Reduced feed intake, coughing, wing drooping and twisting their necks were the main complaints and clinical signs that shown in Figure 6. Because the chickens were purchased from a local market (with no flock records), no information regarding vaccination history, age or breed was available. The chickens showed depression, wing and limb paralysis, incoordination, and greenish watery diarrhea during physical examination at the veterinary teaching hospital. The two chickens were subjected to a post-mortem examination after an in-depth clinical examination, which revealed hemorrhage in the trachea, gut, proventriculus, and cloaca (Figure 7). The farm was not built in the standard way during the farm visit, but was properly aired, dry, and the chickens were uniformly dispersed, as illustrated in figure 6B. However, the chickens did not grow as expected. The sick chickens were isolated, but they were not properly cared for. When the flock became ill, they used oxytetracycline antibiotics and vitamins, even though they were unaware of its

usage. The owners are aware of biosecurity precautions in theory, but they do not have a foot bath or working protective clothing and shoes. The case was tentatively identified as Newcastle disease based on the history, clinical signs, pathological findings, and farm visit (NDV).



Figure 6: NCV Infected chickens in VTH during the first visit (A); status of the flock during the course of the diseases (B); and Diseased chickens in isolation area, some of them were with twisted neck, and loss of coordination (C& D)

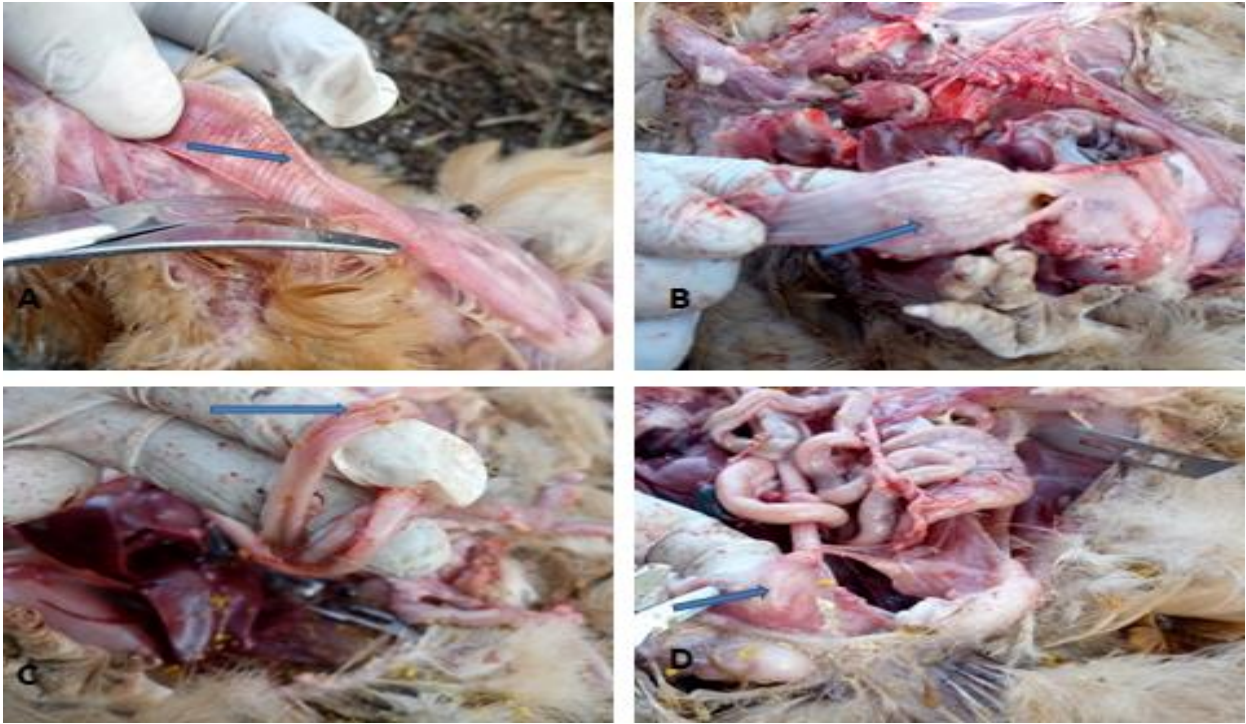

Figure 7: Post-mortem result of NCV affected chickens (A); Tracheal hemorrhage (B); Slight hemorrhage in proventricules (C); Hemorrhage in the intestine and (D); Petechial hemorrhage in cloaca

Differential diagnosis of Newcastle disease

Highly pathogenic avian influenza, Infectious bronchitis, laryngotracheitis, Fowl pox (diphtheritic form), Fowl cholera, psittacosis (chlamydiosis), Mycoplasmosis, Salmonellosis, and Aspergillosis.

Laboratory investigation and findings

For further confirmation of the case, pooled tracheal and cloacal samples were taken by using sterile swab from affected chickens and virus transporting media (VTM) was used to collect and store the sample until processing. Then Real-time reverse transcriptase polymerase chain reaction (RT-PCR) confirmatory diagnosis was done at National Animal Health Diagnostic Center (NAHDIC), Sebeta. This test indicated the cycle threshold (CT value) for the positive control as 25.71 and 23.26 for the sample. This indicates the sample is positive for Newcastle

virus (Figure 8). Therefore, the laboratory finding complemented the tentative diagnosis and confirmed the chickens were affected by NCD.

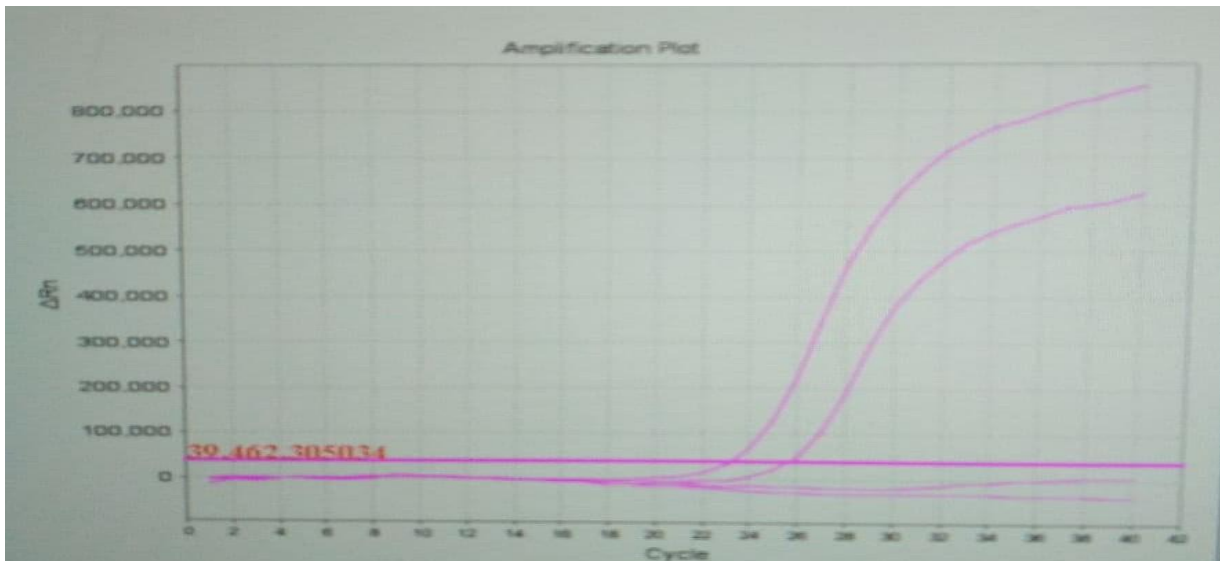


Figure 8: RT PCR result in graph of NCV: Two lines moving up from which the first one is the positive control (known sample having Ct value=23.26) and the other consecutive one is the target sample (unknown one with Ct value=25.71). Below the cut off line (Ct value grater or equal to 35), there is a negative control lying on the horizontal straight line.

Case management and out come

The disease was tentatively diagnosed as New-castle disease after physical and post-mortem examinations. As a result, the treatment was targeted at reducing secondary bacterial problems, reducing environmental stress, and increasing immunity. To reduce secondary bacterial complications, enrofloxacin (ASHIENRO 10%) oral suspension 1ml per liter of drinking water was given to 10 diseased chickens for 5 consecutive days, and an immune stimulant called Resurgen (Quadragen VetHealth Pvt. Ltd) oral suspension containing essential oils, vitamin E, and selenium was given to all 58 chickens in a dose of 1g/5lit until good progress was being made. After the first fatality, two or three deaths each day were documented. Even though the mortality rate reached 64%, the deaths stopped a few weeks later, and the surviving flock returned to normal status. The owners were also given tips on how to raise chickens and how to avoid and treat NCD and other poultry illnesses. After two

months, the flock's physical conditions as well as the size of the layers returned to normal, and they began to lay eggs (Figure 9).



Figure 9: The status of chickens after the treatment against NCV complications

Discussion

Newcastle disease in these clinically affected chickens involves different systems and organs. Signs associated with GIT include anorexia and diarrhea, signs associated with respiratory systems like coughing and signs associated with nervous symptoms like paralysis of wings and legs, twisting of neck were highly visible signs. These clinical signs are in line with the clinical signs listed by Bhaiyat et al. (Ashraf & Shah, 2014). The post mortem findings indicate the presence of hemorrhage in gastrointestinal tract and respiratory tract that include tracheal, periventricular and cloacal hemorrhage. This is in agreement with the review of Alexander.DJ et.al (Getabalew.M, Alemneh.T and Getahun, 2019).

From prevention and control perspective as vaccination history of the flock is not known because the flock was brought from a local market, two possible scenarios can be proposed about the mortality of the affected flock. The first scenario is the flock's infection and mortality might be due to absence of vaccination because vaccination is the only protective

way against the endemic NCD. This idea is in line with Usman M report. The second one is as many reports the mortality rate of NCD in unvaccinated flock can reach 100%, but in this case the mortality was 64 %. This may be due to the vaccination of the remained flock, protect them from more complicated case and mortality because as Abdisa and Tagesu review says that ND vaccination usually protects the bird from the more serious consequences of disease in the presence of the virus (Ashraf, and Shah, 2014; Abdisa and Tagesu, 2017).

Regarding vaccination the challenge in this small scale farm is about the vaccine itself. As the remained flock has to be vaccinated protecting the proper vaccination procedure is very important for its effectiveness but challenges are present like the vaccine is prepared for high numbered flock but to overcome this challenge local traders are taken as a choice to get the vaccine in the available flock number but still management problem like transportation and vaccine handling were the challenges this idea is agree with Alders ,Abdisa & Tagesu study and review (Alders, 2001; Abdisa and Tagesu, 2017).

Enrofloxacin was used in this case to combat secondary bacterial complications. The reason behind was that the flock was previously treated with oxytetracycline groups therefore to change the mechanism of fighting against the secondary bacterial complications, Fluoroquinolones group of drug was used. The other reason was this group of drugs have a very good action in different body systems including GIT and respiratory systems, this is in agreement with Sahu and Saxena (Sahu and Saxena, 2014).

The aim of the vitamin treatment was in order to boost the immune system, reduce the signs related to nervous system, gastrointestinal and muscular system. There for immunomodulant called Resergen was administered because it has essential oils and significant amount of vitamin E (10g) and selenium (100ppm). According to different authors vitamin E is one of the most effective nutrients known to modulate immune system to fight off invading bacteria and viruses, used as nature's most effective antioxidant for prevention of encephalomalacia, in a specific role with selenium, for prevention of exudative diathesis as well as prevention of nutritional muscular dystrophy (Moriguchi and Kaneyasu, 2003; Lewis, Meydani and Wu, 2019; M.L.Scott, 2021).

Conclusions

Newcastle disease (NCD) is a highly infectious and deadly viral disease that may kill up to 100% of unvaccinated flocks. However, instant antibiotic treatment combined with immunomodulators may improve cure rates and save financial losses.

Acknowledgment

I am grateful to Dr. Yobsan Tamiru and Yamlaksira Ayalkbet (Msc fellows), Yosef Yohannes (3rd year DVM student) and the owner of the chickens.

References

- Admassu, B. *et al.* (2015) 'Review on Foot and Mouth Disease: Distribution and Economic Significance', *Academic Journal of Animal Diseases*, **4**(3), pp. 160–169.
- Aftosa, F. (2015) 'Foot and Mouth Disease Foot and Mouth Disease', *CFSPH*, (3), pp. 1–9.
- Aktas, M. S. *et al.* (2015) 'Myocarditis associated with foot-and-mouth disease in suckling calves', *Veterinary Archives*, **85**(3), pp. 273–282.
- Alexandersen, S. *et al.* (2003) 'The Pathogenesis and Diagnosis of Foot-and-Mouth Disease', **129**(03), pp. 1–36.
- Ayelet, G. *et al.* (2009) 'Genetic characterization of foot-and-mouth disease viruses, Ethiopia, 1981-2007', *Emerging Infectious Diseases*, **15**(9), pp. 1409–1417. .
- CONSTABLE, P. D. and KENNETH W. HINCHCLIFF STANLEY H. DONE WALTER GRÜNBERG (2017) *VETERINARY MEDICINE 11th edition*.
- Gizaw, D. *et al.* (2020) 'Molecular characterization of foot-and-mouth disease viruses circulating in Ethiopia between 2008 and 2019', *Transboundary and Emerging Diseases*, **67**(6), pp. 2983–2992.
- Gudata, D. (2019) 'A Review on Foot and Mouth Disease - Ethiopian Prospective', *veterinary clinical science*, **07**(02), pp. 27–36.

- Seid, H. A. (2020) 'Review on the Epidemiology and Economic Impacts of Foot and Mouth Disease in Ethiopia', **9**(2), pp. 92–103.
- SH. Rhaymah, M. and A. Abd- Alhameed, M. (2010) 'Clinical study of foot and mouth disease in feedlot calves in Mosul region', *Iraqi Journal of Veterinary Sciences*, **24**(1), pp. 11–16.
- Tadesse, B., Alamir, K. and Demssie, E. (2017) 'Review on the Control of Foot and Mouth Disease by Vaccination', *International Journal of Basic and Applied Virology*, **6**(2), pp. 9–18.
- Tufani, N. A. (2013) 'Complications of foot and mouth disease in cattle and their clinical management', *Progressive research*, **8**(1), pp. 127–129.
- Wang, X. *et al.* (2018) 'Chinese guidelines for the diagnosis and treatment of hand, foot and mouth disease (2018 edition)', *World Journal of Pediatrics* **14**(5), pp. 437–447.

5.1.3 Canine parvovirus enteritis (CPE) in 4-month-old puppies

Abstract

Canine parvovirus enteritis (CPV-2) is a highly infectious and deadly disease that affects dogs, particularly pups. Although the disease has worldwide distribution, the reports are scarce in Africa. Two 4-month-old puppies named 'Blacky' and 'Mick' were brought to the veterinary teaching hospital in Bishoftu with a history of reduced appetite, bloody diarrhea, and vomiting. 'Blacky' was the first to display clinical signs and was lethargic, with a sub-normal temperature (38.3°C) and mild dehydration. On the other hand, 'Mick' was alert because of an immediate hospital visit. Ringer lactate IV infusion, gentamycin (9 mg/kg) and diclofenac sodium (2 mg/kg) IM for five days, and anti-emetics metoclopramide at the dose of 0.3 mg/kg IM till the vomit stopped were all used as supportive therapies for both pups. 'Mick' made an excellent recovery after a week of rigorous therapy while 'Blacky' died the night of the first day of treatment. This case report shows that the prompt treatment of canine parvovirus with supportive and symptomatic therapies has an excellent outcome.

Key Words: *Canine parvovirus, puppies and supportive therapy*

Introduction

Canine Parvoviral Enteritis [CPE] is highly contagious, acute viral enteritis and associated with high mortality and morbidity. The disease affect young puppies and immune-compromised domesticated and wild canidae (Odueko 2020).

Canine parvovirus enteritis is caused by three variants of canine parvovirus type 2 in a family of Parvoviridae and Genus *Parvovirus*. The three variants are CPV-2a, CPV-2b, and CPV-2c with same pathogenicity and indistinguishable clinical disease. The pathogenesis of this virus start when the virus enters to the body and replicate abundantly in the lymph nodes. The incubation period is 3-7 days. Then after two days the virus enters to the blood stream. After 3-4 days the virus replicate in highly dividing cells like bone marrow, intestinal epithelial cells, within the bone marrow the virus inhibits the proliferation of young immune cells by distracting them and make the body unable to defend itself. Therefore the virus is very known by minimizing white blood cells and interacellular eosinophilic bodies. this disease is very

known as it cause myocarditis in puppies (Mylonakis, Kalli, and Rallis 2016; Nandi and Kumar 2010).

The clinical signs of CPE at early stage include depression, loss of appetite, diarrhea (with no constant appearance it can be watery, yellow or blood tinged in color), vomiting and high fever. But later the fever subsides and become subnormal, there will be severe dehydration, metabolic acidosis (or alkalosis), bacterial septicemia and toxemia, systemic inflammatory response syndrome (SIRS), organ dysfunction, hypercoagulability and death (Goddard and Leisewitz 2010; Nandi and Kumar 2010; Prittie 2004).

Enteritis due to CPV-2 can affect any age, breed and sex group of dogs but puppies aged between 6 weeks and 6 months are more susceptible for this disease than other age groups. According to sex intact males are twice susceptible than intact female dogs. The disease is become sever in dogs with no vaccination history. The predisposing factors to CPV-2 are stressful conditions, lack of hygiene, intestinal parasite and lack of protective immunity. Then transmission take place through direct transmission of fecal-oral route or indirect contact through fomite (Goddard and Leisewitz 2010; S. A. Godsall, J. H. Stavisky 2010).

Supportive treatment is very crucial in dogs with CPE. The mortality rate can exceed 90% if no intervention has taken but if supportive drugs are used the survival rate can be more than 80%. The first fundamental treatment to replace the lost fluid through diarrhea and vomiting is fluid therapy. In order to combat secondary bacterial complication broad spectrum antibiotics and to decrease inflammatory reaction anti-inflammatory drugs are very important. to cease vomiting due to CPE symptomatic anti-emetics therapy are used (Mylonakis et al. 2016; Odueko 2020).

Case description

On February 19/2021 the dog owner brought her four month puppies named Blacky (Figure 10A) and Mick (Figure 10B) with a chief complaint of runny bloody feces, vomiting and decreased feed intake. According to the owner Blacky was the first to show the clinical signs and was in a bad condition when she brought them to veterinary teaching hospital at Bishoftu. As the owner said there was same condition in other neighboring puppy which started days prior to this case. Additionally, these puppies have no medication history including

vaccination and no feed change has been made. On the physical examination, the puppies were found lethargic especially 'Blacky' and dehydration level was mild in 'Mick' and moderate in 'Blacky' and the body temperature was sub-normal (38.3°C). No egg or oocyte was observed under microscopic examination of a fecal sample. Thus, based on the age, disease prevalence, history and clinical findings the disease was tentatively marked as Canine parvovirus enteritis (CPE).

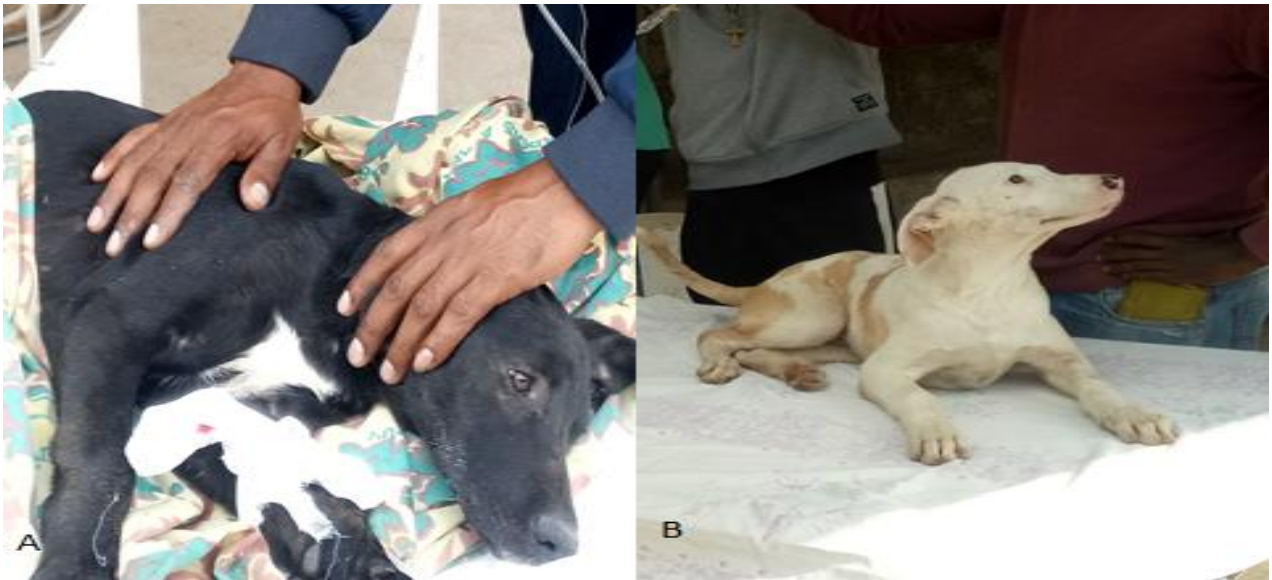

Figure 10: CPVE affected puppies (A); Blacky in the examination and (B); Mick in the examination

Differential diagnosis of parvovirus enteritis

Enteritis caused by bacterial agent like *E coli*, viral agent like coronavirus, and parasitic agents (*Trichuris vulpis*, *Ancylostoma* spp, *Uncinaria* spp), systemic disturbances with secondary GI involvement like hypoadrenocorticism, coagulopathy, severe GI ulceration neoplasia and GI perforation of any etiology.

Case management and follow-up

Based on the tentative diagnosis both puppies were managed by supportive and symptomatic treatments. The first goal of the treatment was to restore the lost electrolytes and fluids. Therefore, ringer lactate intravenous suspension (Addis Pharmaceutical factory PLC) as Deficit replacement volume ($\% \text{ dehydration} \times \text{body weight (kg)} \times 1000^b \times 0.80$, where dehydration level for the 'Blacky' was taken as 5 and 7 for 'Mike') and Maintenance Volume ($(30 \times \text{BW}_{\text{Kg}}) + 70$) were used for days as they reach to good health status. To combat the bacterial complication gentamycin (Humanwell pharmaceutical Ethiopia, PLC) at a dose of 9mg/kg bid for five successive days was given IM but when the treatment was found less effective penstrip 1ml/20kg/day for three days was given IM. To reduce the inflammation and pain due to enteritis diclofenac sodium 2mg/kg was used for five successive days. Metoclopramide antiemetic was also used at a dose of 0.3 mg/kg IM until vomiting stopped. The effect of the treatment could not be seen in the case of 'Blacky', mean death occurred in the first night when treatment commenced. After aggressive therapy, for more than a week, 'Mike' was returned to its normal health status as shown in the figure 12 but it takes longer to retain its appetite back.



Figure 11: Both puppies with CPVE under the intravenous fluid therapy




Figure 12: Mick; after recovery on alert standing position and playing

Discussion

Even though CPE has a worldwide distribution there is less documented data in the context of Africa. As the study of Dogonyaro in 2010 said that no available document for the presence of Canine parvovirus type 2 in Africa. Therefore much concern is not given for this disease in Africa. But there are less indicative documents for the presence of the disease in Africa. One study carried out in Ethiopian wolves and domestic dogs in Bale National park indicate the sero-positivity of all sampled animals for canine parvovirus. Another recent study in South Africa showed the presence of the CPV-2 in molecular test. As this study the presented animals for this disease were with the clinical signs of anorexia, diarrhea and vomiting also they were responsive for the given symptomatic therapies, also in this case report the puppies were presented with the same clinical signs and treatment was responsive and successful in the case of “Mike” (Laurenson et al. 1998; OGBU, I., ANENE, M., NWEZE, E., OKORO, I., DANLADI, M. AND SOCHAI 2017; Oosthuizen et al. 2019). Beside the clinical signs age of 4 months, lack of vaccination and presence of the same case in the same area were taken as components to state the tentative diagnosis as indicated by different authors (Dong et al. 2020; Goddard and Leisewitz 2010; S. A. Godsall, J. H. Stavisky 2010).

The treatment approach towards enteritis cause by parvovirus in this case report include fluid therapy containing electrolytes and mineral, gentamycin which is an aminoglycoside bacteriocidal antibiotics and also penstrip which is also a bacteriocidal drug. The study of Oduko indicates aminoglycocides as an effective drugs against CPE. Additionally, metoclopramide anti-emetic drug and antipain were used to treat the case. The combination of this four types of treatments were indicated by different studies and guidliness (DACA 2006; Gerlach et al. 2020; Oduko 2020).

The recovery rates of the two puppies were about 50%. The possible justification for this: in the case of ‘Blacky’ the symptom of the disease was started days before ‘Mike’ and when it reached to VTH the puppy was in severe stage mean “Blacky” had late hospital visit and as the expression of Falls Village Veterinary Hospital treatment is very essential and must be early to cure puppies affected by Parvo virus. Additionally, as stated by Prittie survival rate can reach up-to 95% if supportive treatments are given (Prittie 2004; Village 2020).

Conclusion

Enteritis in puppies due to CPE is tentatively known by its clinical signs, epidemiology like young age and the presence of the same disease in the same environment and absence of vaccination history. Supportive treatment has a very good effect if it is given early and aggressively against CPE.

Acknowledgment

I would like to thank you Mr. Dereje Gudeta and Kiruble (a 5th year DVM student) and the owner of the puppies.

References

DACA (2006) *Standard veterinary treatment guidelines of Ethiopa*.1-154

Dong, B. *et al.* (2020) ‘A systematic literature review and meta-analysis of characterization of canine parvoviruses 2 prevalent in mainland China’, *Virology Journal*. BioMed Central, **17**(1), pp. 1–10.

Gerlach, M. *et al.* (2020) ‘[Therapy of canine parvovirus infection - review and current

- insights].’, *Tierärztliche Praxis. Ausgabe K, Kleintiere/Heimtiere*. Germany, **48**(1), pp. 26–37.
- Goddard, A. and Leisewitz, A. L. (2010) ‘Canine Parvovirus’, *Veterinary Clinics of North America - Small Animal Practice*, **40**(6), pp. 1041–1053.
- Laurenson, K. *et al.* (1998) ‘Disease as a threat to endangered species: Ethiopian wolves, domestic dogs and canine pathogens’, *Animal Conservation*, **1**(4), pp. 273–280.
- Mylonakis, M., Kalli, I. and Rallis, T. (2016) ‘Canine parvoviral enteritis: an update on the clinical diagnosis, treatment, and prevention’, *Veterinary Medicine: Research and Reports*, **7**, pp. 91–100..
- Nandi, S. and Kumar, M. (2010) ‘Canine parvovirus: Current perspective’, *Indian Journal of Virology*, **21**(1), pp. 31–44.
- Odueko, F. D. (2020) ‘Literature review on canine parvoviral enteritis variants in Nigeria’, **9**(1), pp. 26–32.
- OGBU, I., ANENE, M., NWEZE, E., OKORO, I., DANLADI, M. AND SOCHAI, O. (2017) ‘Canine parvovirus : A review’, *Journal of the South African*, **2**(2), pp. 74–95.
- Oosthuizen, A. *et al.* (2019) ‘Canine parvovirus detected from a serval (*Leptailurus serval*) in South Africa’, *Journal of the South African Veterinary Association*, **90**(2019), pp. 0–6.
- Prittie, J. (2004) ‘Canine parvoviral enteritis: a review of diagnosis, management, and prevention’, *veterinary emergency and critical care*, **14**(3), pp. 167–176.
- S. A. Godsall, J. H. Stavisky, A. D. R. and G. P. (2010) ‘Epidemiology of canine parvovirus and coronavirus in dogs presented with severe diarrhoea to PDSA PetAid hospitals’, *vet Record*, **167**(6).
- Village, F. (2020) ‘The First Signs of Parvo’, *CHAIROT*.

5.1.4 Pox lesion in sheep and goat and severe respiratory complex

Abstract

Sheep and Goat Pox are OIE-listed diseases of small ruminants, with mortality rates ranging from 10 to 85% in susceptible hosts. In this case report, a sheep and goat (ewe and buck) with a history of decreased feed intake and depression are described. Both animals were febrile and exhibited typical pox lesions in different parts of their bodies. Based on the clinical findings, sheep and goat pox were diagnosed tentatively. Additionally both animals had severe respiratory complications. The animals were then administered 10% oxytetracycline medications to prevent subsequent bacterial complications. However, a buck returned to the hospital three days after the final day of therapy, but this time the condition had worsened, and the buck was weak. Again, oxytetracycline treatment (but with a different brand) commenced for the second time; but unfortunately, both animals died. Although stringent preventative measures are recommended to combat the spread and occurrences of sheep and goat pox, early treatment has substantial benefits towards saving animals and reducing economic losses.

Keywords: *Buck; ewe; pox lesions*

Introduction

Sheep and Goat Pox is a highly contagious viral disease of sheep and goats. It is an OIE list “A” disease Sheep and Goat Pox (SGP) is one of the most significant diseases of sheep and goats in Africa following Peste des Petits Ruminants (PPR) and Contagious Caprine Pleuropneumonia (CCPP) (Fentie *et al.*, 2017; Gitao *et al.*, 2017).

Sheeppox virus (SPPV), goatpox virus (GTPV) are in genus Capripoxvirus, subfamily Chordopoxvirinae, family Poxviridae (Babiuk *et al.*, 2008). Capripoxvirus is DNA virus. They are closely related antigenically. However, these viruses cannot be differentiated using routine serological test (Al-Salihi, 2014; Takele Tesgera *et al.*, 2018). Capripoxvirus is highly stable in normal environment (Takele Tesgera *et al.*, 2018).

Sheep pox virus and goat pox virus cause clinical disease in sheep and goats, respectively; however, there is a wide range of clinical disease seen with different field isolates. Differentiate between sheep and goat pox is very difficult and it is based on field observation of the species affected whether sheep or goats but some isolates are uniformly pathogenic in both sheep and goat (Tuppurainen *et al.*, 2017; Takele Tesgera *et al.*, 2018).

Infected sheep and goats shed virus in oral, nasal and ocular secretions and transmission occurs through aerosols and direct contact (Bowden *et al.*, 2008). Direct contact and contact with contaminated materials can spread the infection through skin abrasions or by insects (Mirzaie, Barani and Bokaie, 2015; Mahmoud and Khafagi, 2016).

SGPV is endemic in Africa Outbreaks were recorded during all months of the year, but during cold seasons, sheep are exposed to low temperature which exposes them to stress and this stress could suppress the immune system, and finally the sheep become vulnerable to infection (Takele Tesgera *et al.*, 2018; Fares *et al.*, 2019).

First the virus is deposited in most tissues, including the skin. The pathogenesis of the disease is associated with both viral and host factors. The control of virus replication by the host likely determines the clinical outcome (Babiuk *et al.*, 2008; o. M. Radostits, 2010).

Clinical signs of sheep and goat pox are similar. The incubation period ranged from 4-21 days. Clinical sign of SGP can be either malignant or benign. The malignant form is the most common type. There is marked depression and prostration, a very high fever and discharges from the eyes and nose. Affected lambs may die during this stage before typical pox lesions develop. But when they develop the lesion it occurs on unwooled skin and on the buccal, respiratory, digestive and urogenital tract mucosae additionally fevers which peak at 40-42 °C, dyspnea and discharge from eye and nose. Benign form of sheep pox is characterized only by skin lesions that occur particularly under the tail. This form of sheep pox is common in adult. Systemic reaction not found and the animal recovers in one month. In susceptible herds, SGP has 75-100% morbidity rate is and 10-85% mortality rate, depending on the virulence of the virus is between (o. M. Radostits, 2010; Mirzaie, Barani and Bokaie, 2015; Fentie *et al.*, 2017; Takele Tesgera *et al.*, 2018).

Diagnosis of SGP is based on clinical signs, generalized nodular skin lesions and enlarged superficial lymph nodes in affected animals, gross pathology and the host species affected. But definitive diagnosis requires laboratory confirmation like serological tests and polymerase chain reaction (PCR) (Rao and Bandyopadhyay, 2000; Abdulqa *et al.*, 2016; Zein, Mahmoud and Khalafalla, 2016; Gitao *et al.*, 2017; Mulatu and Feyisa, 2018)..

For capripox viruses like most viruses no specific antiviral treatment has been found. But the first measure that is taken is to isolate diseased animals from the herd and follow palliative treatment such as antibiotics, anti-inflammatory drug, and vitamin injections (Abdulqa *et al.*, 2016). To give relief of respiratory related sign washing and cleaning the nostril with weak solution of potassium permanganate is also recommended. For the control and prevention of the disease biosecurity measures and vaccination are important points (Takele Tesgera *et al.*, 2018).

Therefore the objective of this case report is to show the effect of sheep and goat pox and their respiratory complex.

Case description

Case 1

On April 5/2021, the owner was brought her ewe to Adama district veterinary clinic, with a complaint of reduced feed intake, coughing and nasal discharge which start few days before the examination day. According to the owner, the ewe fed intensively and was the only animal with the signs. Upon physical examinations, the ewe was depressed markedly, serous nasal discharges from both sides (Figure 13B) and pox lesions especially under the tail (Figure 13C) were the visible signs. During auscultation, the lung had abnormal sound and rhythm. Respiration was costo-abdominal, harsh and crackling sounds were audible and prolongation in the expiratory phase of respiration was appreciated. The rectal body temperature of the ewe was 40.5°C and the heart rate was 120 pulse/min. Therefore based on the history and typical pox lesions, sheep pox was diagnosed tentatively.

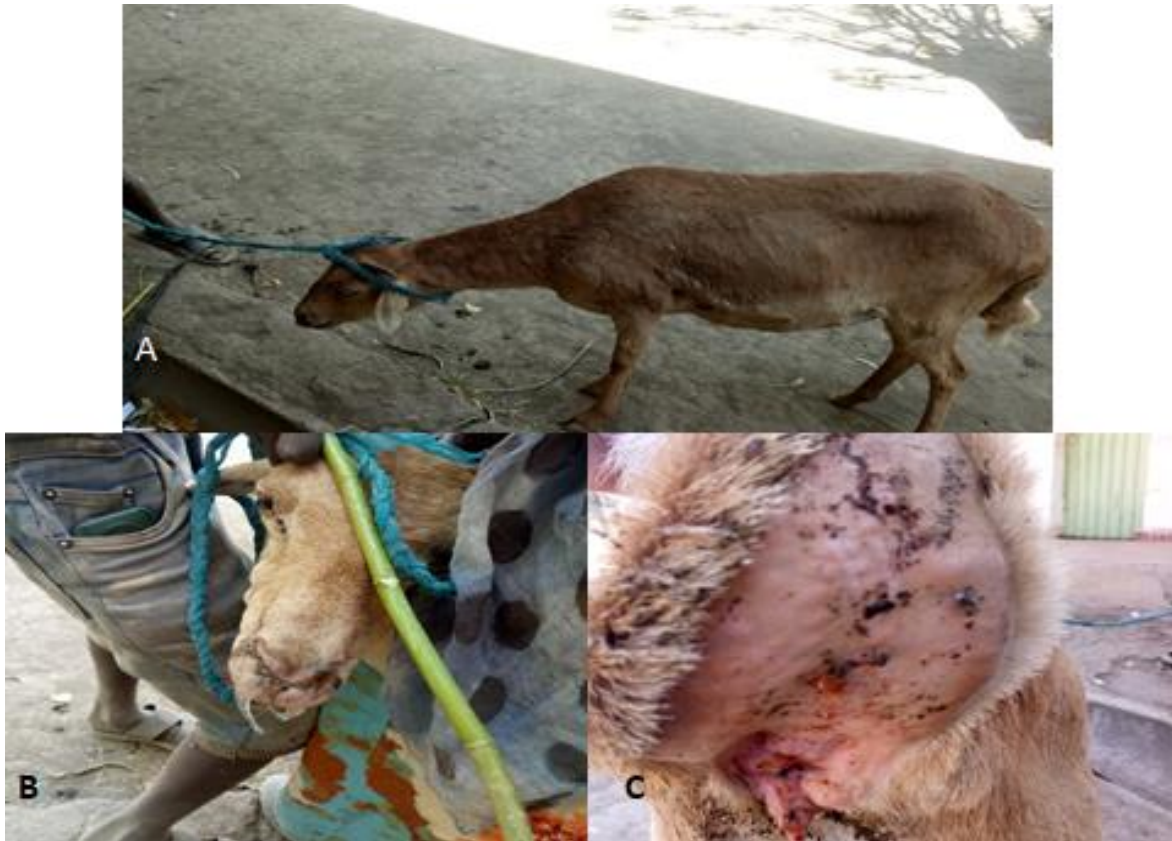

Figure 13: Pox affected sheep (A) Pox lesion all over the sheep's body (B); Nasal discharge in pox affected sheep and (C); pox lesion in the tail of the sheep

Case 2

On April 9/2021 a flock of goats was brought to veterinary teaching hospital, Bishoftu with a chief complaint of decreased appetite and depression in a buck. The owner also complained that he found dry swellings around the buck's thigh during grooming. Upon physical examinations, the buck was depressed and febrile with rectal body temperature of 41°C. Additionally, typical pox lesions were found in the hind limb and around testicle (Figure 14B). Then the animal started his follow up and a selected drug was given. During the due time the animal was in a good progress but after three successive days treatment the follow up was ceased. Then 3 days later the owner brought the buck again and upon the examination the case was found sever and complicated. At the same time ultrasound examination was done and the lung was found pneumonic. In this round additionally respiratory abnormalities were found in

which mucopurulent nasal discharge from both nostrils and ocular discharge were found (Figure 14C).



Figure 14: Pox lesion in the buck (A); the first presentation of the buck with pox lesion (B); pox lesion around scrotum and (C) pox lesion on the face

Differential diagnosis of pox

Contagious pustular dermatitis virus(orf), Blue tongue, Insect bites, Bluetongue, Peste des petits ruminants, Photosensitisation, Dermatophilosis, Parasitic pneumonia, Caseous lymphadenitis and Mange.

Case management

After sheep and goat pox were tentatively diagnosed, the cases were subjected to supportive treatments. The sheep was treated by 10% oxytetracycline (Alfasan, international, WOERDEN-HOLLAND) 3 ml/ 50 kg, IM and diclofenac sodium 2.5 mg/kg IM. The same treatment was given for the buck but oxytetracycline brands were different. The first round treatment was Oxytetracycline 10% (Hebei Kexing pharmaceutical Co.Ltd) at a dose of

0.2ml/10kg/day and the second round treatment after 3 days gap (phenoxy) 1 ml/10kg for 2 days was given. But finally both cases were unable to survive. The ewe passed away in the first night of the treatment while the buck died in the next day of the second round treatment.

Discussion

Based on the history and the presence of typical pox lesion the case was confirmed as sheep and goat pox. Malignant form of pox lesion was seen in both pox cases which is expressed the presence of lesions all over the body especially in the ewe fatty tail part and in the hind limb of the goat, by high fever, by the presence of marked depression and discharges from the eyes and nose. The lesion type in the ewe was papule to nodular and in the goat the lesion type was like scabby. The clinical findings and the complications due to the disease are supported by the review of Mirzaie, Barani and Bokaie and case report of Botlagunta (Botlagunta, 2014; Mirzaie, Barani and Bokaie, 2015). The prominent clinical signs in these pox affected sheep and goat were the presence of severe respiratory problem. As the description of Gitao *et al.* animals that affect by pox lesions often have labored breathing due to blisters inside the respiratory tract and lungs (Gitao *et al.*, 2017).

Both pox affected animals were died. The reason may be due to the severity of the disease because when the ewe was first presented marked depression, weakness and complications due to respiratory problems (abnormal rhythm and sound) were found. According to the expression of Radostits complication of pox virus may result to pneumonia and abortion which may lead to high mortality and morbidity up to 100% (o. M. Radostits, 2010; Nunes *et al.*, 2020). The second reason may be due to termination of antibiotic treatment, which may lead to systemic complication (pneumonia in the goat ultrasound image). According to Siddhartha underuse drug is one of irrational way of using drugs that can lead to unacceptable health and financial ramifications (Siddhartha Dutta, 2019).

Oxytetracycline was the drug of choice for both cases because the drug is a broad spectrum antibiotics used for different disease conditions including pneumonia ad septicemia. According to Papich oxytetracycline is used for the treatment of pneumonia caused by different bacterial agents which is good for the treatment of pox related complications (Papich,

2021). To reduce pain and inflammation Diclofenac treatment which is Nonsteroidal anti-inflammatory drugs (NSAIDs) are used worldwide to treat pain and inflammation was used (Schellack, 2017).

Conclusion

These cases show malignant type sheep and goat pox and their related complications especially in respiratory system. The complications were associated with delayed intervention and premature cessation of prescribed treatments. Therefore early treatment and rational use of drug are very important to attack pox complications.

References

- Abdulqa, H. Y. *et al.* (2016) 'LUMPY SKIN DISEASE', *iMedPub Journals*, **1**(4:25). doi: 10.21767/2476-1974.100025.
- Al-Salihi, K. a (2014) 'Lumpy Skin disease : Review of literature', *Mirror of Research in Veterinary Sciences and Animals*, **3**(3), pp. 6–23.
- Babiuk, S. *et al.* (2008) 'Capripoxviruses: An emerging worldwide threat to sheep, goats and cattle', *Transboundary and Emerging Diseases*,**2**(4), pp. 263–272.
- Botlagunta, S. (2014) 'A case report: Visceral smallpox in a sheep flock in Andhra Pradesh, India', *J Veterinar Sci Technolo*, **5**(3), p. 76.
- Bowden, T. R. *et al.* (2008) 'Capripoxvirus tissue tropism and shedding: A quantitative study in experimentally infected sheep and goats.', *Virology*. United States, **371**(2), pp. 380–393.
- Fares, M. R. *et al.* (2019) 'A Comprehensive Review of Sheep and Goat Pox Viruses : Perspective of Their Epidemiology and Economic Importance in Egypt', *SCVMJ*, **24**(2), pp. 313–327.
- Fentie, T. *et al.* (2017) 'Sero-prevalence , risk factors and distribution of sheep and goat pox in Amhara Region , Ethiopia'. *BMC Veterinary Research*,**3**(1), pp. 1–8.

- Gitao, C. G. *et al.* (2017) 'Review of Sheep Pox Disease in Sheep', *Journal of Veterinary Medicine and Research*, **4**(1), pp. 1–5.
- Mahmoud, M. A. and Khafagi, M. H. (2016) 'Detection, identification, and differentiation of sheep pox virus and goat pox virus from clinical cases in Giza Governorate, Egypt', *Veterinary World*, **9**(12), pp. 1445–1449.
- Mirzaie, K., Barani, S. M. and Bokaie, S. (2015) 'A review of sheep pox and goat pox: Perspective of their control and eradication in Iran', *Journal of Advanced Veterinary and Animal Research*, **2**(4), pp. 373–381.
- Mulatu, E. and Feyisa, A. (2018) 'Review : Lumpy Skin Disease Journal of Veterinary Science & Review : Lumpy Skin Disease', *J Vet Sci Technol*, **9**(3), pp. 1–8.
- Nunes, M. *et al.* (2020) 'Recycling the purpose of old drugs to treat ovarian cancer', *International Journal of Molecular Sciences*, **21**(20), pp. 1–24.
- o. M. Radostits (2010) *VETERINARY MEDICINE A textbook of the diseases of cattle, horses, sheep, pigs and goats*. 10th edn. Edited by o. M. R. C. C. G. K. W. H. P. D. Constable.
- Papich, M. G. (2021) 'Oxytetracycline', in Papich, M. G. (ed.) *Papich Handbook of Veterinary Drugs (Fifth Edition)*. Fifth Edit. St. Louis (MO): W.B. Saunders, pp. 689–691. doi: <https://doi.org/10.1016/B978-0-323-70957-6.00401-5>.
- Rao, T. V. and Bandyopadhyay, S. K. (2000) 'A comprehensive review of goat pox and sheep pox and their diagnosis.', *Animal health research reviews / Conference of Research Workers in Animal Diseases*, **1**(2), pp. 127–136. doi: 10.1017/S1466252300000116.
- Schellack, N. (2017) 'REVIEW A review of nonsteroidal anti-inflammatory drugs', *S Afr Pharm J*, **82**(3), pp. 8–18.
- Siddhartha Dutta (2019) 'Rational Use of Medicines: a Review', *World Journal of Pharmaceutical and Medical Research*, **3**(5), pp. 129–132.
- Takele Tesgera, H. *et al.* (2018) 'A Review on Sheeppox and Goatpox: Insight of Epidemiology, Diagnosis, Treatment and Control Measures in Ethiopia', *Journal of*

Infectious Diseases and Epidemiology, **4**(3), pp. 1–8.

Tuppurainen, E. S. M. *et al.* (2017) ‘Review: Capripoxvirus Diseases: Current Status and Opportunities for Control’, *Transboundary and Emerging Diseases*, **64**(3), pp. 729–745.

Zein, A., Mahmoud, E. and Khalafalla, A. I. (2016) ‘An epidemiological study of sheep and goat pox outbreaks in the Sudan’, *Food Biology*, **5**(3), pp. 1–5.

5.1.5 Peste des petits ruminants (PPR) in a doe

Abstract

Peste des petits ruminant's disease is economically significant in small ruminants, especially in goats. The morbidity and mortality rate of the disease might reach 100%. On May 4/2021, the owner of the goat brought his pregnant doe with a complaint of watery feces, decreased appetite, coughing and nasal discharge to VTH, Bishoftu. Previously, the same disease happened in the flock and the affected 2 goats died. Upon physical examinations, the goat had intermittent coughing and diarrhea, elevated vital parameters, and swollen lymph nodes. The case was later confirmed as Peste des petits ruminants by c-ELISA testing. Oxytetracycline (10%) at a dose of 0.2ml/10kg/day, IM was intended to prevent subsequent bacterial complications; however, the doe died after three days of treatment. In conclusion, the PPR case poses the greatest threat to small ruminant production and health, and while treating an animal infected with Peste des petits ruminants is beneficial, focusing on strategic disease prevention, particularly through vaccination, is advised.

Key Words: *Goats; Peste des petits ruminants*

Introduction

Peste des petits ruminants (PPR) is an acute, highly contagious and fatal disease of ruminants where its morbidity and mortality rates exceeds 90%. PPR is classified as an OIE list A disease (Kumar *et al.*, 2014).

Peste des petits ruminant's virus (PPRV) has been classified under family Paramyxoviridae, Order Mononegavirales and Genus Morbillivirus. The virus has the same genes with rinderpest virus, canine and porcine distemper virus, measles virus and dolphin morbillivirus in which the group has immunological cross reaction (Diallo *et al.*, 2007). PPRV is a single stranded RNA virus, enveloped and longest of all morbilliviruses. The virus has six structural proteins named fusion protein, nucleoprotein, phosphoprotein, matrix Protein, hemagglutinin protein and large polymerase protein (Bailey *et al.*, 2007; Mdetele *et al.*, 2021).

PPRV enters to the body through respiratory system and localize mandibular and pharyngeal lymph nodes and tonsil because the virus is lymphotropic and epitheliotropic which produces severe lesions in organ rich in lymphoid and epithelial tissues. Viremia may develop after 2-3 days of entry and disseminated to bone marrow, spleen, gastrointestinal and respiratory mucosa. The onset of clinical signs is after 1-2 days of the viremia (Ousman, 2020).

The clinical sign of PPR is mainly related to respiratory and gastrointestinal systems. PPR increase body temperature up to 41°C, the nasal discharge is watery oculonasal discharge and become muco purulent gradually, the eyelids mated together, has tongue coughing, stomatitis and diarrhea. Even acute form of the disease is known this disease has per acute, acute and sub-acute forms (Kabir *et al.*, 2019).

PPR is a recently recognize disease compared to render pest disease which is often difficult to differentiate between them. However the disease is endemic in developing countries of African and Asian worlds. This disease is highly known by affecting goats severely and sheep. but the disease has sub-clinical character in large ruminants and also cause disease in wild animals (Diallo *et al.*, 2007; Majeeda Rasheed, 2020).

PPR is diagnosed tentatively by the clinical signs and postmortem lesions and the definitive diagnosis is done by molecular and serological tests which detect specific antibody and viral antigen (Kabir *et al.*, 2019).

As PPR is a viral disease there is no effective treatment against it but giving broad spectrum antibiotics against bacterial complication and other fluid therapy to restore the lost fluid can support the animal (Torsson *et al.*, 2016). Controlling measures against the disease include proper vaccination, segregation and quarantine of the affected animal (Balamurugan *et al.*, 2014).

PPR has high economic importance in small ruminant population especially in goats. Therefore the objective of this case report is to show the diagnostic approach, the intervention and the outcome of a goat with respiratory and gastrointestinal disorder.

Case Description

In May 4/2021 an owner brought his pregnant doe to veterinary teaching hospital with a complaint of watery feces and decreased appetite 4 days prior to the examination day. As the owners explanation the doe exhibited additional signs like coughing and sneezing. The doe was raised from the beginning at home and graze. The doe had no prior treatment and vaccination history but, there were 2 goats from the same flock affected by same disease and died. Upon the clinical examination, the vital parameters were increased (Temperature =40.7° c, RR= 44 breath/min and HR= 120 beat/min), pre-scapular and pre-femoral lymph nodes were slightly swollen, the back area of the doe was found solid and dirty due to diarrhea, there was intermittent coughing, clear nasal discharge and lesions in the oral mucosa. Therefore, based on the clinical signs the goat was a suspect of Peste des petits ruminant (PPR).



Figure 15: PPR affected doe: Arrow indicates the solid area of the doe due to diarrhea and the circled area indicates the oral lesion as well as the serous discharge from nose

Differential diagnosis of PPR

Heart water, Pneumonic pasteurellosis, Contagious Caprine Plueropneumonia, Contagious Bovine Plueropneumonia, Helminthiasis, Coccidiosis, Contagious ecthyma and Possibly Nairobi sheep disease

Laboratory investigation and findings

As the clinical signs visible in this ewe were shared by other diseases, confirmatory diagnosis was useful to confirm the case. Therefore, blood sample was taken from the jugular vein and

stored in the deep freeze until the laboratory test has been done. Then, the sample was processed in National Veterinary institution (NVI). The diagnostic test done was c-ELISA and the PPRV antibody was found in the test (Annex 4).

Case management and outcome

After blood sample was taken for further confirmation supportive treatment was started to prevent further complications. Oxytetracycline 10% (Hebei Kexing pharmaceutical Co.Ltd) at a dose of 0.2ml/10kg/day and Multivitamin (Aether center, Beijing, biology co.,Ltd), 2ml/head were given IM. But after three days of treatment the doe passed away.

Discussion

The case was confirmed as Peste des petits ruminants (PPR) based on history, clinical signs and cELISA test. PPR has many differential diagnoses and as the report of OIE this disease has similarity in clinical sign with rinderpest, contagious caprine pleuropneumonia (CCPP) and pasteurilosis and in addition to this disease the review Ousman indicate bluetongue, Orf, FMD, heart water, coccidiosis and mineral poisoning as differential diagnosis. Therefore, the contagious nature of the disease, the epidemiological character and the presence of clinical sign which include both respiratory and GIT systems and the lesion are taken as differentiating ways in addition to the laboratory confirmation (OIE, 2008; Ousman, 2020).

The confirmatory test that used in this case was competitive ELISA because as the study of Zaher this test is a rapid, specific and sensitive for PPRV antibody detection in sick animals. Even serological tests are used as screening test, in this case it was used as a confirmatory test because there was no known history of vaccination that make confusion with the antibody that get from the disease and also the animal was showing the clinical signs but if the animal was vaccinated as the vaccine is lifelong no clinical signs were visible. Therefore it can be said that the serological test that found positive confirm the presence of the PPR (Zaher and Ahmed, 2014).

In the present case, the outcome of the doe was death. The possible reasons for the death can be putted as (1) the severity of the case because as the report of Kumar *et al* the morbidity and mortality of the disease can exceed 90% and as Fentahun, T. and M. Woldie it can reach to 100% (Kumar *et al.*, 2014; Ousman, 2020). (2) PPR has high mortality rate in goats because of its affinity and the study of Wose indicate the low recovery rate observed in goats (Biruk Alemu, 2014). (3) The animal was presented to VTH after 4 days when the case weakens the animal. The study of Adu FD & Joannis TE explain about early treatment of PPR as this study even in advanced cases healing can occur if treatment is given early (Kabir *et al.*, 2019).

As the disease has significant importance in goat population vaccinating animals is the major measure that has been taken in order to control and prevent the disease. As the study of Libeau *et al.*, the recent outbreaks of PPR is due to the cessation of rinderpest vaccination and cross protecting antibody loss. Therefore in the present case if the animal was vaccinated against PPR or rinderpest it has a great chance to not be diseased (Libeau *et al.*, 2011).

Conclusion

Even treating animals affected by PPR disease is a good thing focusing in the prevention and control of the disease is a better way to eradicate the disease. In this instance the effort of OIE and FAO in order to eradicate the disease from the world in 2030 is an encouraging step and individual focusing at this goal helps as to attain the goal.

Acknowledgment

I am grateful for Birhanu (an externship student), Kedir from NVI and the owner of the animal.

References

- Bailey, D. *et al.* (2007) 'Reverse genetics for peste-des-petits-ruminants virus (PPRV): Promoter and protein specificities', *Virus Research*, **126**(1), pp. 250–255.
- Balamurugan, V. *et al.* (2014) 'Diagnosis and control of peste des petits ruminants: a comprehensive review', *VirusDisease*, **25**(1), pp. 39–56.
- Biruk Alemu (2014) *EPIDEMIOLOGY AND IDENTIFICATION OF PESTE DES PETITS*

RUMINANTS (PPR) VIRUS CIRCULATING IN SMALL RUMINANTS OF EASTERN AMHARA REGION BORDERING AFAR, ETHIOPIA.

- Diallo, A. *et al.* (2007) ‘The threat of peste des petits ruminants: progress in vaccine development for disease control’, *Vaccine*, **25**(30), pp. 5591–5597.
- Kabir, A. *et al.* (2019) ‘Peste des petits ruminants: A review’, *Pesquisa Agropecuaria Brasileira*, **8**(2), pp. 1214–1222.
- Kumar, N. *et al.* (2014) ‘Peste des petits ruminants virus infection of small ruminants: a comprehensive review.’, *Viruses*, **6**(6), pp. 2287–2327.
- Libeau, G. *et al.* (2011) ‘Peste des petits ruminants, growing incidence worldwide’, *OIE Bull*, **52**(4), pp. 1–2.
- Majeeda Rasheed, Tanveer Akhtar, Nadia Mukhtar, Muhammad Furqan Shahid, Muhammad Imran, S. Y. (2020) ‘Sero-prevalence of Peste des Petits Ruminant (PPR) Virus in Sheep and Goat Population of Gilgit Baltistan Province of Pakistan’, *Journal of Zoology*, **35**(1), pp. 123–127.
- Mdetele, D. P. *et al.* (2021) ‘Review of peste des petits ruminants occurrence and spread in tanzania’, *Animals*, **11**(6).
- OIE (2008) *MANUAL OF DIAGNOSTIC TESTS AND VACCINES (mammals , birds and bees)*.
- Ousman, A. (2020) ‘Review on the Epidemiology of Peste Des Petits Ruminants (PPR) in Ethiopia’, **9**(1), pp. 1–13.
- Torsson, E. *et al.* (2016) ‘History and current status of peste des petits ruminants virus in Tanzania’, *Infection Ecology and Epidemiology*, **6**(1).
- Zaher, K. S. and Ahmed, W. M. (2014) ‘Isolation and Identification of Field Isolate of Peste des Petits Ruminants Virus in Egypt’, **12**(5), pp. 667–672.

5.2 Diseases Caused By Bacterial Agents

5.2.1 Diarrheic calf and the identification of *E. coli* O157

Abstract

Diarrhoea in calves can be caused by different causative agents. *Escherichia coli* O157 is known for its high pathogenicity and zoonotic effect. A 3-month-old calf with a chief complaint of watery diarrhea was brought to Addis Ababa University, CVMA-VTH, Bishoftu. During a physical examination, the calf was depressed, had mucoid diarrhea with mucous and slightly increased respiration rate. Laboratory tests including, bacteriological tests, for salmonella and *E.coli* and parasitological tests, for *Eimeria* were done. The bacterial culture was negative for salmonella, and no *Eimeria* oocysts were found during the parasitological techniques. However, the bacteriological culture and biochemical tests were positive for *E. coli*. To distinguish between the pathogenic and non-pathogenic *E.coli* sample was grown on sorbitol MacConkey agar and checked using *E. coli* O157 latex agglutination test that confirmed that *E. coli* O157 was a cause of the disease. The calf was treated with sulphadimidine sodium 33.3% with an initial dose of 0.5 ml/kg, IV and maintenance dose of 0.05 ml/kg, IM, for two days, and a multivitamin 2ml/ head. The calf made a good recovery. Animals with *E. coli* O157-induced diarrhea become carriers and continue to shed the agent, which has significant zoonotic implications; hence, early intervention is critical because it promotes rapid recovery in animals and reduces the agent's shedding.

Key Words: *Calf diarrhea; E. coli* O157

Introduction

Calf diarrhea is a disease which has a serious financial and animal welfare impact in both dairy and beef industries. Calves diarrhea is a multifactorial disease with causative agents of bacteria, viruses, protozoa and intestinal parasites. Among bacteria, enterotoxigenic *Escherichia coli* and *Salmonella* are known to be the most common. The viral causative agent of calf diarrhea include, bovine corona virus, bovine rotavirus group A and bovine viral

diarrhea virus and cryptosporidia is protozoan cause of calf diarrhea. Beside to *E. coli*, salmonella and *Clostridium perfringens* are also bacterial cause of calf diarrhea. Non-infectious factors also contribute for the occurrence of this disease such as insufficient uptake of colostrum, poor sanitation, stress, overcrowding in the calf pens and cold weather (Achá *et al.*, 2004; Muktar Yimer, 2015).

Escherichia coli (*E. coli*) is member of the Enterobacteriaceae family, gram negative, rod-shaped motile or non-motile, facultative anaerobic and non-spore forming bacteria which reside in the gastrointestinal tract of warm-blooded animals as normal flora (Frydendahl, 2002). Different strains of *E. coli* are associated with a number of typical diarrheal illnesses. Among them enterotoxigenic *E. coli* (ETEC), enteroinvasive *E.coli* (EIEC) and Shiga toxin-producing *E.coli*(STEC) are prominent. From the STEC, *E.coli*O157:H7 is the prototypic strain. Each class of *E. coli* has distinct somatic (O) and flagellar (H) antigens and specific virulence characteristics (Makvana and Krilov, 2015).

Enterohemorrhagic *E.coli* (EHEC) O157:H7 can produce Shiga like toxin and the name Shiga toxin-producing *E. coli* (STEC) is derived from this. Cattle have been implicated as an important reservoir of Shiga-like toxin-producing *E.coli*O157:H7. Naturally or experimentally-infected cattle can shed low levels of *E. coli* O157:H7 long-term infection, but little is known about the pathogenesis of *E. coli* O157:H7 infection in cattle. But in human *E. coli* O157 infection ranges from asymptomatic colonization with body, to lethal hemorrhagic uremic syndrome (HUS) and hemorrhagic colitis disease. HUS is a disease characterized by hemolytic anemia, thrombocytopenia and acute renal failure signs (Dean-Nystrom, Bosworth and Moon, 1997; Saeedi *et al.*, 2017). From *E. coli* pathogenic groups STEC is the only zoonotic *E-coli* because as the shiga toxin is transmitted from animal reservoirs through the food chain (Wasteson, 2002).

Ancillary treatments of calf diarrhea mainly include parenteral administration of antimicrobials. Antimicrobial treatment of diarrheic calves caused by *E.coli* should aimed two infection sites which are in the small intestine and blood. The evaluation of the response is, by the clinical response affected calves. There are many classes of drugs used for calf diarrhea including Sulphonamides groups. Sulphonamides are bacteriostatic drugs. Micro-organisms sensitive to this drug group require p-Amino benzoic acid (PABA) for the synthesis of folic

acid which is essential for the production of nucleic acid. Sulphonamides are competitively inhibiting PABA due to structural similarity. This causes folic acid deficiency, resulting in arrest of bacterial growth as well as division. Sulfadimidine is one of the most widely used sulfonamide drugs in veterinary medicine. especially this drug is widely used antibacterial agent against enteritis (Woodward, 2003; Constable, 2004; D.Constable, 2009; Lavanya, 2017; Pandey, Kandasamy and Ahmad, 2020).

According to prevention of the disease, there is no much difference in prevention of calf diarrhea according to each etiological agent but knowing of causal pathogen(s) is important for assessing the current status of the affected farm accurately and developing further interventions (Cho and Yoon, 2014). To reduce the exposure of cattle to *E. coli* O157 biosecurity and environmental management are essential measures, this can include feed and drinking water hygiene, reduced exposure to insects or wildlife and improved cleanliness of the bedding or pen floor (LeJeune and Wetzel, 2007).

As *E. coli* o157 is known by its high zoonotic importance, the prevention and control of *E. coli* O157:H7 infection requires control measures at all stages of the food chain. This includes avoiding raw milk and meat consumption and keeping hygiene following contact with cattle and their excreta (Engdaw and Temesgen, 2016).

Therefore the objective of this case report is to show the treatment protocol of *E. coli* O157 infected calf.

Case description

On January, 29/2020 an owner presents her 3-month-old calf to Addis Ababa University, CVMA-VTH, Bishoftu, with a complaint of watery feces which was started 15 days before the day of examination. In the meantime the calf was treated by unknown oral suspension and the response was not good enough. Then the calf decrease in feed intake and body weight gain. Additionally it was known the excess “frushka” intake of the calf. During the farm visit, the calf was a member of one intensive small scale dairy farm located around Air force in Bishoftu town. The calf has a separate barn but, with poor hygiene. Upon physical examinations, the calf had mucoid diarrhea with soiled hind legs. The calf was dyspneic up on auscultation but, the heart rate (82 beat/min) and body temperature (38.7 ° c) was with in a

normal range. Based on the history and clinical signs, colibacillosis, coccidiosis and salmonellosis were considered the differentials of the case and fecal sample was collected for further laboratory investigations.



Figure 16: Diarrheic calf (A); The affected calf with dry and dirty back (B); Yellowish mucoid diarrhea from the calf

Differential diagnosis of calf diarrhea

Viral agents like corona virus and rotavirus, bacterial agents like enterotoxigenic *E. coli* and *Salmonella* spp, protozoal causes like *Cryptosporidium* and feeding problem.

Laboratory investigations and findings

The fecal samples were collected from the rectum of the calf and submitted to Parasitology and Microbiology laboratories of College of Veterinary Medicine and Agriculture, Bishoftu. In parasitology laboratory the sample was processed for the presence of *Eimeria* oocyst by Sheather's flotation technique and the result was negative. For bacterial identification, in microbiology laboratory peptone water was used as a transporting medium and incubated for 24 hours in 37⁰c. Then the sample was cultured in to Xylose Lysine Deoxycholate agar (XLD)

(a selective media for the isolation of *Salmonella* and *Shigella*) and MacConkey agar and both medias were grown bacteria. The bacteria on XLD media was characterized as Large, Flat, Yellow Colonies and it was more supposed to be *E.coli* rather than salmonella or shigella. The sample that grown on macConkey was then cultured on eosin methylin blue agar (EMB) and black colony with green metallic sheen was observed (Figure 17). Then 4 biochemical tests were done. Therefore, all the culture and biochemical tests indicate that the case was caused by *Escherichia coli* (*E.coli*). But here, dealing about the pathogenicity of these bacteria was very important and thus, tests to differentiate between pathogenic and nonpathogenic *E.coli* were required. To do that the colony was cultured into sorbitol MacConkey agar and the result indicate yellow colored colony because of sorbitol non-fermenting characteristics of the colony which indicate the colony was pathogenic *E. coli*. Then the final test was very specific for the detection of the much known pathogenic *E. coli* called E-coli O157. For this, latex agglutination test for E-coli O157 was done and the result indicated visible agglutination in less than a minute. Thus, it was concluded that the calf's diarrhea was due to *E. coli*O157.

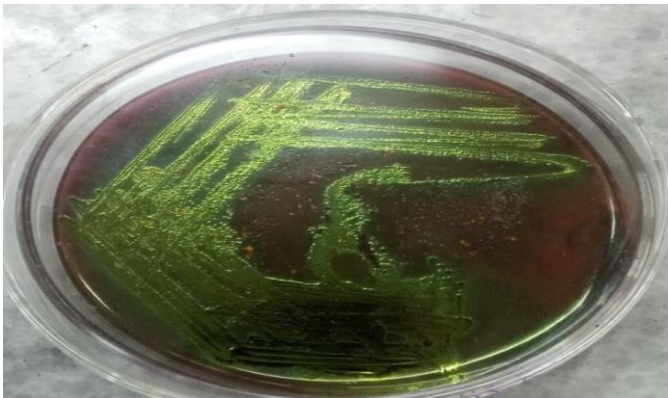


Figure 17: Green metallic sheen on eosin methylene blue (EMB) agar media




Figure 18: Different biochemical tests to confirm *E. coli* (A); Indole test on SIM media indicate positive result (B); Methylin red test with positive result, Figure (C); TSI and Simon citrate tests were positive for *E. coli* and (D); Vogues proskauer (VP) test with negative result




Figure 19: Positive result expressed by agglutination which indicates *E. coli* o157

Case management

Therefore the case was managed before the bacteriological laboratory results obtained based on the tentative diagnosis and parasitological test results. Sulphadimidine sodium 33.3% (MEHECO) at a dose of 0.5 ml/kg IV for initial dose and 0.05 ml/kg, IM, for two successive days was given. Additionally, multivitamin (Aether center, Beijing, biology co.,Ltd) 2 ml/head was given once. After 3 days, the calf was returned to normal health status as shown in the figure below.



Figure 20: The status of the E.coli O157 calf after the treatment

Discussion

According to the clinical signs and laboratory conformation the cause of diarrhea in this calf is E-coli o157 which has low pathogenicity in cattle. The clinical sign that is mainly visible in this affected calf is diarrhea which starts 15 days before examination day but other parameters were found normal with slight depression and which agreed with the study of Dean-Nystrom according to this study whether naturally or experimentally- E. coli O157:H7 infected cattle can shed low levels of long-term infection. Another study by Brown and moon indicate that in calves affected by E. coli -o157 after an initial brief period of pyrexia in experimental three calves and transient mild diarrhea in five calves, calves were clinically normal throughout the

13- to 27-day study which indicate the low severity of the disease in calves (Brown *et al.*, 1997; Dean-Nystrom, Bosworth and Moon, 1997).

The exposing factors of this calf to the disease may associate with the feed change which is the uptake of excess “furishka” and due to poor management which is associated with loss of hygienic conditions. These exposing factors were the same that listed by the study of Yimer which states that E-coli is normal flora of cattle and only become problematic with nutritional stress, injury, changes in management (Muktar Yimer, 2015).

The diagnosis of this disease was performed on different bacteriological tests which can differentiate the exact causative agent of the disease. As the causes of calf diarrhea is many the sample was first diagnosed for salmonella and *Eimeria* oocyte and the result was found negative. The protocols were the same with Cummings discription for salmonelosis and Verma’s description for coccidiosis (Cummings *et al.*, 2009; Verma, 2018). Then the bacteria culture on MacConkey and then eosin methylin blue agar (EMB) showed black colony with green metallic sheen which is the characteristics of E-coli, this is in agreement with the discription given by Antony (Antony *et al.*, 2016). Then different biochemical tests were done and also cultured on sorbitol-MacConkey (SMAC) media as indicated by the work of Tasneem and also in the work of Makvana and Krilov (Tasneem Farasat, Tahira Mughal, 2010; Makvana and Krilov, 2015). The biochemical tests proved that the cause of this calf diarrhea was E-coli and the sorbitol MacConkey proved the agent as pathogenic strain of E-coli. To detecting E. coli 0157:H7 latex agglutination test was done as the test is become commercially available for rapid presumptive detection of E. coli belonging to the serogroup 0157 this is also supported by the study of March and Ratnam (March and Ratnam, 1989; Molina-Bolívar and Galisteo-González, 2005).

Calf diarrhea which related with E-coli o157 has a mild effect on the affected animal. Therefore treatment was in order to restore the calf to normal status with a little effort. Hence antibiotics where parentally used which is supported by the study of Bashahun (Bashahun and Amina, 2017). But this is in disagreement with the description of Yimer which state the use of antibiotics in diarrheic calves is contraindicated due to further disruption of gut flora (Muktar Yimer, 2015).

Conclusion

Calf diarrhea can be caused by a multiple causative agents from them E-coli O157 is the most pathogenic cause of a diarrhea. Even this agent cause a mild disease condition the present calf its shedding capacity to infect other hosts is very significant.

Acknowledgment

I am grateful to Dr. Gemechu from Ambo for supporting me in the laboratory work and Yamlaksira Ayalkbet supporting me in the home visits.

References

- Achá, S. J. *et al.* (2004) ‘Studies on calf diarrhoea in mozambique: Prevalence of bacterial pathogens’, *Acta Veterinaria Scandinavica*, **45**(1–2), pp. 27–36.
- Antony, A. C. *et al.* (2016) ‘Comparative evaluation of EMB agar and hicrome E. coli agar for differentiation of green metallic sheen producing non E. Coli and typical E. Coli colonies from food and environmental samples’, *Journal of Pure and Applied Microbiology*, **10**(4), pp. 2863–2870.
- Bashahun, G. and A. A. (2017) ‘Colibacillosis in calves: A review of literature’, *Journal of Animal Science and Veterinary Medicine*, **2**(3), pp. 62–71.
- Brown, C. A. *et al.* (1997) ‘Experimental Escherichia coli O157:H7 carriage in calves’, *Applied and Environmental Microbiology*, **63**(1), pp. 27–32.
- Cho, Y. il and Yoon, K. J. (2014) ‘An overview of calf diarrhea - infectious etiology, diagnosis, and intervention’, *Journal of Veterinary Science*, **15**(1), pp. 1–17.
- Constable, P. (2004) ‘Antimicrobial Use in the Treatment of Calf Diarrhea’, *Journal of veterinary internal medicine / American College of Veterinary Internal Medicine*, **18**, pp. 8–17.
- Cummings, K. J. *et al.* (2009) ‘Fecal shedding of Salmonella spp among cattle admitted to a veterinary medical teaching hospital.’, *Journal of the American Veterinary Medical Association*. United States, **234**(12), pp. 1578–1585.

- D.Constable, P. (2009) ‘Treatment of Calf Diarrhea: Antimicrobial and Ancillary Treatments’, *Veterinary Clinics of North America: Food Animal Practice*, **25**(1), pp. 101–120.
- Dean-Nystrom, E. A., Bosworth, B. T. and Moon, H. W. (1997) ‘Pathogenesis of O157:H7 Escherichia coli infection in neonatal calves.’, *Advances in experimental medicine and biology*. United States, **412**, pp. 47–51.
- Engdaw, T. A. and Temesgen, W. (2016) ‘O157 : H7 Serotype of Escherichia coli as an Important Emerging Zoonosis Woreta City Office of Agriculture and Environmental Sanitation , Woreta , Ethiopia’, **7**(1), pp. 9–17.
- Frydendahl, K. (2002) ‘Prevalence of serogroups and virulence genes in Escherichia coli associated with postweaning diarrhoea and edema disease in pigs and a comparison of diagnostic approaches.’, *Veterinary microbiology*. Netherlands, **85**(2), pp. 169–182.
- Lavanya, R. (2017) ‘Sulphonamides: A Pharmaceutical Review’, *International Journal of Pharmaceutical Science Invention ISSN*, **6**(2), pp. 1–03.
- LeJeune, J. and Wetzel, A. (2007) ‘Preharvest control of Escherichia coli O157 in cattle’, *Journal of animal science*, **85**, pp. 73-80.
- Makvana, S. and Krilov, L. R. (2015) ‘Escherichia coli Infections’, *Pediatrics in Review*, **36**(4), pp. 167–171.
- March, S. B. and Ratnam, S. (1989) ‘Latex agglutination test for detection of Escherichia coli serotype O157’, *Journal of Clinical Microbiology*, **27**(7), pp. 1675–1677.
- Molina-Bolívar, J. A. and Galisteo-González, F. (2005) ‘Latex immunoagglutination assays’, *Journal of Macromolecular Science*, **45** (1) pp. 59–98.
- Muktar Yimer, B. T. and D. B. K. (2015) ‘A review on major bacterial causes of calf diarrhea and its diagnostic method’, *Journal of Veterinary Medicine and Animal Health*, **7**(5), pp. 173–185.
- Pandey, H. K., Kandasamy, K. and Ahmad, A. H. (2020) ‘Pharmacokinetics of sulphadimidine in Indian cattle calves’, *the pharma Innovation*, **9**(3), pp. 536–538.

- Saeedi, P. *et al.* (2017) 'A review on strategies for decreasing E. coli O157:H7 risk in animals', *Microbial Pathogenesis*, **103**, pp. 186–195. doi:
- Tasneem Farasat, Tahira Mughal, A. B. and F.-N. (2010) 'Isolation and Biochemical Identification of E. Coli From Waste Effluents of a Dairy Industry', *Journal of Applied Pharmacy*, **2**(2), pp. 86–88.
- Verma, R. (2018) 'Clinical coccidiosis in calves and its treatment coccidiosis View project All India Network Programme on Gastrointestinal Parasitism View project', *Journal of Entomology and Zoology Studies congested*, **6**(2), pp. 2964–2967.
- Wasteson, Y. (2001) 'Zoonotic Escherichia coli', *Acta Veterinaria Scandinavica*, **95**, pp. 79–84.
- Woodward, K. N. (2003) 'ANTIBIOTICS AND DRUGS | Uses in Food Production', in Caballero, B. (ed.) *Encyclopedia of Food Sciences and Nutrition (Second Edition)*. Second Edi. Oxford: Academic Press, pp. 249–254.

5.2.2 Prophylactic intervention in listeriosis affected flock of goats

Abstract

Listeriosis is one of the most significant diseases in ruminants with sporadic occurrence. On March 13, 2021, a doe was presented to veterinary teaching hospital, Bishoftu with the history of incoordination, muscle spasm and stiffness of neck. On physical examination lack of coordination and neck sided to both sides were seen but further diagnosis were found normal. Based on the history and physical examination listeriosis, was a tentative diagnosis. Then procaine penicillin 44, 000 IU, IM was administered for 5 successive days. But after two days the treatment was mandated to cease and in a field visit the doe was severely affected which revealed by recumbence and being febrile (39.6°C). Additionally on the field visit it was able to know the presence of the same disease as a flock level. Then confirmatory bacteriological tests were done and for the presumptive identification of *Listeria* a rapid slide agglutination test was done. These tests confirm the presence of listeria in clinically affected animals and also as a flock level. Therefore, oxytetracycline 0.2ml/10kg/day, IM was administered for 3 successive days for the entire flock as a prophylactic treatment. Even the treatment of the goats with a nervous clinical signs was not successful due to late intervention, the remaining flock found in a good health status due to the prophylactic intervention. Additionally as the disease can transmit to human in the conception of raw meat and milk, the owners were advised in a way they protect themselves.

Key words: *Doe, Goats, Listeriosis, Nervous signs and Prophylaxis*

Introduction

Listeriosis is an infectious and fatal disease of animals and humans where septicemia and encephalitis are predominantly observed. It is a bacterial infection that caused by a wide range *Listeria* species which lives as saprophytes in the environment like soil. The common route of transmission is ingestion of contaminated food (Dhama *et al.*, 2015; Cfsph, 2019).

There are 7 species with many serotypes of *Listeria* but only *L. monocytogenes* and *L. ivanovii* are pathogenic for domestic animals and *L. innocua* is occasionally reported (Brugère-Picoux, 2008; Gezali, Begna and Jilo, 2016). Listeriosis is a disease that is most

frequently encountered in cattle, goats and sheep. *Listeria* mortality is more common in small ruminant than cattle and encephalitis is more common in sheep than goats (Zekarias and Dema, 2019).

Listeriosis has worldwide distribution and mostly sporadic occurrence. The disease occurs more frequently in the winter and the early spring. The organism is isolated from a wide source of contaminants but the major source of infection is by ingestion. The most unique character of these bacteria is to survive in a wide range of temperatures. Mortality rate depends on different factors but it may vary between 5-25% and mortality varies according to the forms, for the nervous form it can pass 90% and very lower in the abortive form (Gezali, Begna and Jilo, 2016; Hamidi *et al.*, 2020).

Pathogenesis of *Listeria* starts when the host ingests the bacteria and reaches to intestinal epithelial cells. Then *Listeria* observed in phagocytic cells like microphage and further dissemination occurs via the blood stream. *Listeria* is a highly invasive intracellular pathogen and it has unique virulence factor. Afterward through blood and lymph node the bacteria reach to various organs. The pathogen may disseminate to the placenta in pregnant animal or to brain. But in brain there is another proposed route of entry. That is through damaged oral, nasal or ocular mucosal surfaces via trigeminal nerve (Desai *et al.*, 2015; Zekarias and Dema, 2019).

There are three major clinical forms of listeriosis those are: septicemic form, encephalitic form and abortion form. The outcomes of the disease depends on the number of ingested organisms, strain's pathogenic properties and the host immune status (Desai *et al.*, 2015). Incubation periods of listeriosis vary depending on the form in which for septicemic one usually 1-2 days, for abortion 2 weeks and longer for the encephalitic form (Zekarias and Dema, 2019). The encephalitic form is the most common form in ruminants. Incoordination, head deviation sometimes with head tilt, anorexia and depression, walking in circles, unilateral facial hypalgesia and facial paralysis are usually present. The septicemic form is known by marked depression, in appetite, fever and death. Animals became recumbent and death is due to respiratory collapse. Pregnancy associated cases result in abortion, stillbirth or premature labor (Hoelzer, Pouillot and Dennis, 2012).

Treatment must be administered for a prolonged period of time because recovery may take longer time. Penicillin is considered the drug of choice for treatment of listeriosis. For listerial encephalitis/meningitis the most commonly used treatments is penicillin administered at a dose of 44 000 IU/kg BW every 12 hours or every 24 hours given IM. *Listeria monocytogenes* is susceptible to most commonly used antimicrobial drugs. The treatment of choice consists of a β -lactam antibiotic alone or in combination with an aminoglycoside. To control listeriosis proper environmental management is important especially in silage preservation. Vaccination is also recommend in available areas (Mateus *et al.*, 2013; CONSTABLE *et.al*2017).

Listeriosis is known by its zoonotic importance where the main source of infection is through the consumption of contaminated food, ready-to-eat foods, meat and meat products and milk and milk product; therefore, peoples should avoid undercooked animal products. The infection is severe in high risk individuals (Adzitey and Huda, 2010; Guyot, 2011; Serventi *et al.*, 2020).

Therefore the objective of this case review is to show the diagnosis approach and the treatment option towards listeriosis and showing the prevention and control of the disease by prophylactic treatment.

Case description

On March 13, 2021, the owner brought a doe to veterinary teaching hospital, Bishoftu with the history of incoordination, muscle spasm and stiffness of neck. The owner has tried to treat the doe traditionally for days in the suspect of a problem locally called “berde” but didn’t found any response and the case got serious. Additionally, the owner told that the case was not found only in her doe but her neighbors also challenged with the same case. Up on physical examination the doe had lethargy, lack of coordination, neck sided to both side with a rigid pattern (Figure 21) and the skin was oily due to the local treatment but the parameters were found to be normal in that day. Based on history and clinical findings, listeriosis was suspected tentatively although coenurosis and mechanical injury were doubted. .



Figure 21: Listeriosis affected doe under clinical examination (A) Stiffened and one sided neck (B) Physical examination of the affected doe

Case management, follow-up and treatment outcome

After blood samples were collected for further laboratory diagnosis, the treatment was commenced based on the tentative diagnosis with procaine penicillin at a dose of 44,000 IU, IM and diclofenac sodium 2.5 mg/kg for 5 (five) successive days. But after 2 days of treatment, the owner discontinued the treatment for unknown reason. Again after 2 days, I managed to visit the doe at home (In Babugaya, Bishoftu where Somalia displaced peoples are residing) but I found the case become worsen, the doe failed, unable to eat and temperature was raised to 39.6^oc) and other goats from the same flock were found sick with the same problem. Then I invited the owners to VTH but they didn't due to financial problem. During the visit, 2 goats out of 40 total numbers were exhibited the same clinical signs; there were also immediate abortion and mortality history and birth of kid with abnormality in nervous system. The flock browses and were kept in the same area which has a scarcity of feed. Even treatment was administered for three goats with nervous clinical signs the treatment was not successful because of late intervention.



Figure 22: listeriosis affected flock (A) severely affected doe (B) Other affected goat from the flock (C): Flock of goats which has the affected animal

Laboratory investigation and findings

For the first affected animals blood samples were taken and processed. First the sample was enriched on buffered listeria enrichment broth for 48 hours then it transferred to listeria identification agar (PALCAM) and also incubated for 48 hours and brown-black complex seen as a black halo around colonies as it is indicated in figure 23C. For the presumptive identification of Listeria a rapid slide agglutination test was done and the result indicates the clumping of the listeria antigen and antibody as indicated in figure 23D. Then to know the status of the flock 4 milk samples were taken and processed in the same way as the previous one and from them 1 sample agglutinated in latex agglutination test. To identify in strain level The CAMP test (Christie–Atkins–Munch-Peterson) was performed and positive test result was found which indicate *L.monocytogen*. Therefore, the laboratory result indicates the presence of listeria in the flock level.




Figure 23: Laboratory examination of sample from listeriosis affected flock (A) Milk sample collection from the affected flock (B) Blood and milk sample in (C) Blood sample on listeria selective media listeria enrichment broth (D) latex agglutination test result indicate antigen-antibody clumping

Treatment protocol and control of the disease in the flock level

As the laboratory diagnosis confirms the presence of listeriosis, prophylactic treatment was administered to the entire flock. There for 10% oxytetracycline (Hebei Kexing pharmaceutical Co.Ltd) 0.2ml/10kg/day, IM was administered for 3 successive days for the entire flock. After the treatment the flock is found in a good health status but feed scarcity in the area is still a problem. We informed the owners about the zoonotic transmission of the disease therefore the owners were well cooperative to stop the transmission by accepting the given advises.

Discussion

The present case in a flock of goats was diagnosed as listeriosis based on the risk factors, typical clinical pictures and laboratory confirmation. Different risk factors were exposed this flock for listeriosis, from those risk factors the presence of nutritionally affected flock which grazes extensively in resource scarce areas was the main. As the work of Guyot poor nutritional status and other stressful conditions increase risks susceptibility of animals to *Listeria* (Guyot, 2011).

Clinical signs of listeriosis affected animals include anorexia, fever, lethargy but nervous signs were prominently visible signs in the clinically affected goats. This finding agreed with the study of Ehrensperger that has been taken in 67 goats which indicates nervous signs as a prominent clinical manifestation. As a flock level, abortion and death of animals with listeriosis was seen. These finding is in agreement with two outbreaks reports those indicate that abortions and mortality in flock of goats and sheep as a clinical manifestations of listeriosis (Braun, Stehle and Ehrensperger, 2002; Cvetkovikj *et al.*, 2015). As a confirmatory test bacteriological tests were used because as the study of Guyot bacteriological tests are the classical methods used for diagnosis of listeriosis in animal specimens. And latex agglutination test was the chosen test for the exact identification of the bacteria because studies show the 100% sensitivity and 100% specificity of this test (Guyot, 2011; Diagnostics, 2020).

For further explanation of the case as a flock level and to associate other characteristics of the disease, second round milk sample from the apparently healthy does were collected and checked for listeria and the result indicates the presence of the bacteria among the flock. The work of Addis indicate that *L. monocytogenes* can invade the goat mammary tissue without showing any clinical sign and establish a chronic intra mammary infection but resulting in the release of high numbers of viable bacteria in milk. Therefore, in this case infection in kids can be associated with this specific reason because they might get the infection through milk (Addis *et al.*, 2019). The other flock history were abortion and kid with nervous sign starting from birth, this can be related with listeriosis again because as Serventi study vertical transmission can occur transplacentally to the fetus or via birth (Serventi *et al.*, 2020).

The mortality rate of the disease in this flock which showed a nervous clinical signs were significant due to delayed intervention and treatment termination. As the review of Gezali and a work of Delić indicate that antibiotic for listeriosis have not been established in experimental and clinical trial, cases other than nervous signs like abortion and septicemia respond well to antibiotic treatments. The first doe was good in the first presentation and walking well with sign of nervous system but after two days of treatment termination it become recumbent and was lethargic. Therefore, the treatment was not effective in this doe this rational is supported by the work of Erdogan H.M Animals that remain walking are likely to recover but recumbent animals rarely survive (Delić *et al.*, 2014; Gezali, Begna and Jilo, 2016).

Finally to protect the flock from the risk of the disease Prophylaxis was administered. As Bousquet-melou explained that prophylaxis is measure taken to maintain health and prevent disease not to cause a distraction. Therefore, this notion was the base for prophylactic usage in this listeriosis risky group. Oxytetracycline was the chosen drug for prophylactic use in this case because it has a wide and effective use for infectious disease which is also supported by the work of Abdullah. Giving prophylaxis for listeriosis case is supported by the work of Stein (Bousquet-melou, 2015; Abdullah, 2018; Stein *et al.*, 2018).

Conclusion

Listeriosis is an infectious disease which has a massive distraction in goats specially which shows a nervous clinical signs. Hence, removing exposing factors, early treatment intervention, using appropriate drugs to control and prevent the disease from further transmission are effective measures in order to tackle the disease in animals and educating the community how to handle the case was taken measure to prevent zoonotic transmission.

Acknowledgement

I thank you Adem Hussen (5th year DVM student) who handle the case with me, VTH head Dr. Zerihun Asefa for his material support in order to help this poor community and Dr. Webeshet for the laboratory work.

References

- Abdullah, S. (2018) 'In use stability studies of two veterinary medicinal products : Albendazole and Oxytetracycline', *Assiut Vet. Med. J.*, **59**(136), pp. 11–15.
- Addis, M. F. *et al.* (2019) 'Chronic intramammary infection by *Listeria monocytogenes* in a clinically healthy goat - A case report', *BMC Veterinary Research*. BMC Veterinary Research, **15**(1), pp. 1–7.
- Adzitey, F. and Huda, N. (2010) 'Listeria monocytogenes in foods: Incidences and possible control measures', *African Journal of Microbiology Research*, **4**(25), pp. 2848–2855.
- Bousquet-melou, A. (2010) 'Prophylaxis & Metaphylaxis in Veterinary Antimicrobial Therapy', *Ecolie national veterinary*, pp. 1–29.
- Braun, U., Stehle, C. and Ehrensperger, F. (2002) 'Clinical findings and treatment of listeriosis in 67 sheep and goats', *Veterinary Record*, **150**(2), pp. 38–42.
- Brugère-Picoux, J. (2008) 'Ovine listeriosis', *Small Ruminant Research*, **76**(1–2), pp. 12–20. doi: 10.1016/j.smallrumres.2007.12.022.
- Cfsph (2019) *Listerellosis, Circling disease, 1-12.*
- CONSTABLE, P. D. and KENNETH W. HINCHCLIFF STANLEY H. DONE WALTER GRÜNBERG (2017) *VETERINARY MEDICINE 11th edition.*
- Cvetkovikj, I. *et al.* (2015) 'Outbreaks of listeriosis in small ruminants with different clinical manifestations in the Republic of Macedonia', *Mac Vet Rev*, **38**, pp. 53–54.
- Delić, S. *et al.* (2014) 'A case report of *Listeria monocytogenes* meningoencephalitis in General Hospital "Dr Radivoj Simonovir" Sombor', *Medicinski pregled*, **67**(11–12), pp. 407–409.
- Desai, N. D. *et al.* (2015) 'Listeriosis : An Important Food-borne Zoonosis', *Journal of Foodborne and Zoonotic Diseases*, **3**(1), pp. 15–18.
- Dhama, K. *et al.* (2015) 'Listeriosis in animals, its public health significance (food-borne zoonosis) and advances in diagnosis and control: a comprehensive review', *Veterinary Quarterly*, **35**(4), pp. 211–235.

- Diagnostics, H. (2020) *Latex Agglutination Test kits*, 1-5.
- Gezali, A., Begna, F. and Jilo, K. (2016) 'Listeriosis and Its Public Health Importance: A Review', *Global Veterinaria*, **17**(1), pp. 52–62.
- Guyot, H. (2011) 'Case report: Two cases of ocular form of listeriosis in cattle herds', *Cattle Practice*, **19**(1), pp. 61–64.
- Hamidi, A. *et al.* (2020) 'A case report of sporadic ovine listerial meningoencephalitis in kosovo', *Veterinaria Italiana*, **56**(3), pp. 205–211.
- Hoelzer, K., Pouillot, R. and Dennis, S. (2012) 'Animal models of listeriosis: A comparative review of the current state of the art and lessons learned', *Veterinary Research*. BioMed Central Ltd, **43**(1), p. 1-27.
- Mateus, T. *et al.* (2013) 'Listeriosis during Pregnancy: A Public Health Concern', *ISRN Obstetrics and Gynecology*, **2013**, pp. 1–6.
- Serventi, L. *et al.* (2020) 'Pregnancy Complicated by *Listeria Monocytogenes*: A Case Report and Review of the Literature', *Journal of the National Medical Association*, **112**(4), pp. 428–432.
- Stein, H. *et al.* (2018) 'Listeriosis in fattening pigs caused by poor quality silage - A case report', *BMC Veterinary Research*. BMC Veterinary Research, **14**(1), pp. 1–9.
- Zekarias, T. and Dema, T. (2019) 'Listeriosis in Ruminants and its Zoonotic Importance : A Review', *Advances in Biological Research*, **13**(2), pp. 52–61.

5.2.2 Prophylactic intervention in listeriosis affected flock of goats

Abstract

Listeriosis is one of the most significant diseases in ruminants with sporadic occurrence. On March 13, 2021, a doe was presented to veterinary teaching hospital, Bishoftu with the history of incoordination, muscle spasm and stiffness of neck. On physical examination lack of coordination and neck sided to both sides were seen but further diagnosis were found normal. Based on the history and physical examination listeriosis, was a tentative diagnosis. Then procaine penicillin 44, 000 IU, IM was administered for 5 successive days. But after two days the treatment was mandated to cease and in a field visit the doe was severely affected which revealed by recumbence and being febrile (39.6°C). Additionally on the field visit it was able to know the presence of the same disease as a flock level. Then confirmatory bacteriological tests were done and for the presumptive identification of *Listeria* a rapid slide agglutination test was done. These tests confirm the presence of listeria in clinically affected animals and also as a flock level. Therefore, oxytetracycline 0.2ml/10kg/day, IM was administered for 3 successive days for the entire flock as a prophylactic treatment. Even the treatment of the goats with a nervous clinical signs was not successful due to late intervention, the remaining flock found in a good health status due to the prophylactic intervention. Additionally as the disease can transmit to human in the conception of raw meat and milk, the owners were advised in a way they protect themselves.

Key words: *Doe, Goats, Listeriosis, Nervous signs and Prophylaxis*

Introduction

Listeriosis is an infectious and fatal disease of animals and humans where septicemia and encephalitis are predominantly observed. It is a bacterial infection that caused by a wide range *Listeria* species which lives as saprophytes in the environment like soil. The common route of transmission is ingestion of contaminated food (Dhama *et al.*, 2015; Cfsph, 2019).

There are 7 species with many serotypes of *Listeria* but only *L. monocytogenes* and *L. ivanovii* are pathogenic for domestic animals and *L. innocua* is occasionally reported (Brugère-Picoux, 2008; Gezali, Begna and Jilo, 2016). Listeriosis is a disease that is most

frequently encountered in cattle, goats and sheep. *Listeria* mortality is more common in small ruminant than cattle and encephalitis is more common in sheep than goats (Zekarias and Dema, 2019).

Listeriosis has worldwide distribution and mostly sporadic occurrence. The disease occurs more frequently in the winter and the early spring. The organism is isolated from a wide source of contaminants but the major source of infection is by ingestion. The most unique character of these bacteria is to survive in a wide range of temperatures. Mortality rate depends on different factors but it may vary between 5-25% and mortality varies according to the forms, for the nervous form it can pass 90% and very lower in the abortive form (Gezali, Begna and Jilo, 2016; Hamidi *et al.*, 2020).

Pathogenesis of *Listeria* starts when the host ingests the bacteria and reaches to intestinal epithelial cells. Then *Listeria* observed in phagocytic cells like microphage and further dissemination occurs via the blood stream. *Listeria* is a highly invasive intracellular pathogen and it has unique virulence factor. Afterward through blood and lymph node the bacteria reach to various organs. The pathogen may disseminate to the placenta in pregnant animal or to brain. But in brain there is another proposed route of entry. That is through damaged oral, nasal or ocular mucosal surfaces via trigeminal nerve (Desai *et al.*, 2015; Zekarias and Dema, 2019).

There are three major clinical forms of listeriosis those are: septicemic form, encephalitic form and abortion form. The outcomes of the disease depends on the number of ingested organisms, strain's pathogenic properties and the host immune status (Desai *et al.*, 2015). Incubation periods of listeriosis vary depending on the form in which for septicemic one usually 1-2 days, for abortion 2 weeks and longer for the encephalitic form (Zekarias and Dema, 2019). The encephalitic form is the most common form in ruminants. Incoordination, head deviation sometimes with head tilt, anorexia and depression, walking in circles, unilateral facial hypalgesia and facial paralysis are usually present. The septicemic form is known by marked depression, in appetite, fever and death. Animals became recumbent and death is due to respiratory collapse. Pregnancy associated cases result in abortion, stillbirth or premature labor (Hoelzer, Pouillot and Dennis, 2012).

Treatment must be administered for a prolonged period of time because recovery may take longer time. Penicillin is considered the drug of choice for treatment of listeriosis. For listerial encephalitis/meningitis the most commonly used treatments is penicillin administered at a dose of 44 000 IU/kg BW every 12 hours or every 24 hours given IM. *Listeria monocytogenes* is susceptible to most commonly used antimicrobial drugs. The treatment of choice consists of a β -lactam antibiotic alone or in combination with an aminoglycoside. To control listeriosis proper environmental management is important especially in silage preservation. Vaccination is also recommend in available areas (Mateus *et al.*, 2013; CONSTABLE *et.al*2017).

Listeriosis is known by its zoonotic importance where the main source of infection is through the consumption of contaminated food, ready-to-eat foods, meat and meat products and milk and milk product; therefore, peoples should avoid undercooked animal products. The infection is severe in high risk individuals (Adzitey and Huda, 2010; Guyot, 2011; Serventi *et al.*, 2020).

Therefore the objective of this case review is to show the diagnosis approach and the treatment option towards listeriosis and showing the prevention and control of the disease by prophylactic treatment.

Case description

On March 13, 2021, the owner brought a doe to veterinary teaching hospital, Bishoftu with the history of incoordination, muscle spasm and stiffness of neck. The owner has tried to treat the doe traditionally for days in the suspect of a problem locally called “berde” but didn’t found any response and the case got serious. Additionally, the owner told that the case was not found only in her doe but her neighbors also challenged with the same case. Up on physical examination the doe had lethargy, lack of coordination, neck sided to both side with a rigid pattern (Figure 24) and the skin was oily due to the local treatment but the parameters were found to be normal in that day. Based on history and clinical findings, listeriosis was suspected tentatively although coenurosis and mechanical injury were doubted. .



Figure 24: Listeriosis affected doe under clinical examination (A) Stiffened and one sided neck (B) Physical examination of the affected doe

Case management, follow-up and treatment outcome

After blood samples were collected for further laboratory diagnosis, the treatment was commenced based on the tentative diagnosis with procaine penicillin at a dose of 44,000 IU, IM and diclofenac sodium 2.5 mg/kg for 5 (five) successive days. But after 2 days of treatment, the owner discontinued the treatment for unknown reason. Again after 2 days, I managed to visit the doe at home (In Babugaya, Bishoftu where Somalia displaced peoples are residing) but I found the case become worsen, the doe failed, unable to eat and temperature was raised to 39.6^oc) and other goats from the same flock were found sick with the same problem. Then I invited the owners to VTH but they didn't due to financial problem. During the visit, 2 goats out of 40 total numbers were exhibited the same clinical signs; there were also immediate abortion and mortality history and birth of kid with abnormality in nervous system. The flock browses and were kept in the same area which has a scarcity of feed. Even treatment was administered for three goats with nervous clinical signs the treatment was not successful because of late intervention.



Figure 25: listeriosis affected flock (A) severely affected doe (B) Other affected goat from the flock (C): Flock of goats which has the affected animal

Differential diagnosis of Listeriosis

Listerial encephalitis must be differentiated from

Pregnancy toxemia in sheep(pregnant lipidosis), Nervous ketosis in cattle, Rabies, Gid(Coenurus cerebralis), Polioencephalomalacia, Scrapie (transmissible spongiform encephalopathy(TSE) in sheep and bovine spongiform encephalopathy(BSE).

Listerial abortion must be differentiated from

Brucellosis, Listeriosis, Campylobacteriosis, Leptospirosis, Trichomoniasis, Mycosis and Epizootic bovine abortion

Laboratory investigation and findings

For the first affected animals blood samples were taken and processed. First the sample was enriched on buffered listeria enrichment broth for 48 hours then it transferred to listeria identification agar (PALCAM) and also incubated for 48 hours and brown-black complex seen as a black halo around colonies as it is indicated in figure 30C. For the presumptive identification of Listeria a rapid slide agglutination test was done and the result indicates the clumping of the listeria antigen and antibody as indicated in figure 30D. Then to know the status of the flock 4 milk samples were taken and processed in the same way as the previous one and from them 1 sample agglutinated in latex agglutination test. To identify in strain level The CAMP test (Christie–Atkins–Munch-Peterson) was performed and positive test result was found which indicate *L.monocytogen*. Therefore, the laboratory result indicates the presence of listeria in the flock level.



Figure 26: Laboratory examination of sample from listeriosis affected flock (A) Milk sample collection from the affected flock (B) Blood and milk sample in (C) Blood sample on listeria

selective media listeria enrichment broth (D) latex agglutination test result indicate antigen-antibody clumping

Treatment protocol and control of the disease in the flock level

As the laboratory diagnosis confirms the presence of listeriosis, prophylactic treatment was administered to the entire flock. There for 10% oxytetracycline (Hebei Kexing pharmaceutical Co.Ltd) 0.2ml/10kg/day, IM was administered for 3 successive days for the entire flock. After the treatment the flock is found in a good health status but feed scarcity in the area is still a problem. We informed the owners about the zoonotic transmission of the disease therefore the owners were well cooperative to stop the transmission by accepting the given advises.

Discussion

The present case in a flock of goats was diagnosed as listeriosis based on the risk factors, typical clinical pictures and laboratory confirmation. Different risk factors were exposed this flock for listeriosis, from those risk factors the presence of nutritionally affected flock which grazes extensively in resource scared areas was the main. As the work of Guyot poor nutritional status and other stressful conditions increase risks susceptibility of animals to *Listeria* (Guyot, 2011).

Clinical signs of listeriosis affected animals include anorexia, fever, lethargy but nervous signs were prominently visible signs in the clinically affected goats. This finding agreed with the study of Ehrensperger that has been taken in 67 goats which indicates nervous signs as a prominent clinical manifestation. As a flock level, abortion and death of animals with listeriosis was seen. These finding is in agreement with two outbreaks reports those indicate that abortions and mortality in flock of goats and sheep as a clinical manifestations of listeriosis (Braun, Stehle and Ehrensperger, 2002; Cvetkovikj *et al.*, 2015). As a confirmatory test bacteriological tests were used because as the study of Guyot bacteriological tests are the classical methods used for diagnosis of listeriosis in animal specimens. And latex agglutination test was the chosen test for the exact identification of the bacteria because

studies show the 100% sensitivity and 100% specificity of this test (Guyot, 2011; Diagnostics, 2020).

For further explanation of the case as a flock level and to associate other characteristics of the disease, second round milk sample from the apparently healthy does were collected and checked for listeria and the result indicates the presence of the bacteria among the flock. The work of Addis indicate that *L. monocytogenes* can invade the goat mammary tissue without showing any clinical sign and establish a chronic intra mammary infection but resulting in the release of high numbers of viable bacteria in milk. Therefore, in this case infection in kids can be associated with this specific reason because they might get the infection through milk (Addis *et al.*, 2019). The other flock history were abortion and kid with nervous sign starting from birth, this can be related with listeriosis again because as Serventi study vertical transmission can occur transplacentally to the fetus or via birth (Serventi *et al.*, 2020).

The mortality rate of the disease in this flock which showed a nervous clinical signs were significant due to delayed intervention and treatment termination. As the review of Gezali and a work of Delić indicate that antibiotic for listeriosis have not been established in experimental and clinical trial, cases other than nervous signs like abortion and septicemia respond well to antibiotic treatments. The first doe was good in the first presentation and walking well with sign of nervous system but after two days of treatment termination it become recumbent and was lethargic. Therefore, the treatment was not effective in this doe this rational is supported by the work of Erdogan H.M Animals that remain walking are likely to recover but recumbent animals rarely survive (Delić *et al.*, 2014; Gezali, Begna and Jilo, 2016).

Finally to protect the flock from the risk of the disease Prophylaxis was administered. As Bousquet-melou explained that prophylaxis is measure taken to maintain health and prevent disease not to cause a distraction. Therefore, this notion was the base for prophylactic usage in this listeriosis risky group. Oxytetracycline was the chosen drug for prophylactic use in this case because it has a wide and effective use for infectious disease which is also supported by the work of Abdullah. Giving prophylaxis for listeriosis case is supported by the work of Stein (Bousquet-melou, 2015; Abdullah, 2018; Stein *et al.*, 2018).

Conclusion

Listeriosis is an infectious disease which has a massive distraction in goats specially which shows a nervous clinical signs. Hence, removing exposing factors, early treatment intervention, using appropriate drugs to control and prevent the disease from further transmission are effective measures in order to tackle the disease in animals and educating the community how to handle the case was taken measure to prevent zoonotic transmission.

Acknowledgement

I thank you Adem Hussen (5th year DVM student) who handle the case with me, VTH head Dr. Zerihun Asefa for his material support in order to help this poor community and Dr. Webeshet for the laboratory work.

References

- Abdullah, S. (2018) ‘In use stability studies of two veterinary medicinal products : Albendazole and Oxytetracycline’, *Assiut Vet. Med. J.*, **59**(136), pp. 11–15.
- Addis, M. F. *et al.* (2019) ‘Chronic intramammary infection by *Listeria monocytogenes* in a clinically healthy goat - A case report’, *BMC Veterinary Research*. *BMC Veterinary Research*, **15**(1), pp. 1–7.
- Adzitey, F. and Huda, N. (2010) ‘*Listeria monocytogenes* in foods: Incidences and possible control measures’, *African Journal of Microbiology Research*, **4**(25), pp. 2848–2855.
- Bousquet-melou, A. (2010) ‘Prophylaxis & Metaphylaxis in Veterinary Antimicrobial Therapy’, *Ecolie national veterinary*, pp. 1–29.
- Braun, U., Stehle, C. and Ehrensperger, F. (2002) ‘Clinical findings and treatment of listeriosis in 67 sheep and goats’, *Veterinary Record*, **150**(2), pp. 38–42.
- Brugère-Picoux, J. (2008) ‘Ovine listeriosis’, *Small Ruminant Research*, **76**(1–2), pp. 12–20. doi: 10.1016/j.smallrumres.2007.12.022.
- Cfsph (2019) *Listerellosis, Circling disease, 1-12.*
- CONSTABLE, P. D. and KENNETH W. HINCHCLIFF STANLEY H. DONE WALTER

GRÜNBERG (2017) *VETERINARY MEDICINE 11th edition*.

Cvetkovikj, I. *et al.* (2015) 'Outbreaks of listeriosis in small ruminants with different clinical manifestations in the Republic of Macedonia', *Mac Vet Rev*, **38**, pp. 53–54.

Delić, S. *et al.* (2014) 'A case report of *Listeria monocytogenes* meningoencephalitis in General Hospital "Dr Radivoj Simonovir" Sombor', *Medicinski pregled*, **67**(11–12), pp. 407–409.

Desai, N. D. *et al.* (2015) 'Listeriosis: An Important Food-borne Zoonosis', *Journal of Foodborne and Zoonotic Diseases*, **3**(1), pp. 15–18.

Dhama, K. *et al.* (2015) 'Listeriosis in animals, its public health significance (food-borne zoonosis) and advances in diagnosis and control: a comprehensive review', *Veterinary Quarterly*, **35**(4), pp. 211–235.

Diagnostics, H. (2020) *Latex Agglutination Test kits, 1-5*.

Gezali, A., Begna, F. and Jilo, K. (2016) 'Listeriosis and Its Public Health Importance: A Review', *Global Veterinaria*, **17**(1), pp. 52–62.

Guyot, H. (2011) 'Case report: Two cases of ocular form of listeriosis in cattle herds', *Cattle Practice*, **19**(1), pp. 61–64.

Hamidi, A. *et al.* (2020) 'A case report of sporadic ovine listerial meningoencephalitis in kosovo', *Veterinaria Italiana*, **56**(3), pp. 205–211.

Hoelzer, K., Pouillot, R. and Dennis, S. (2012) 'Animal models of listeriosis: A comparative review of the current state of the art and lessons learned', *Veterinary Research*. BioMed Central Ltd, **43**(1), p. 1-27.

Mateus, T. *et al.* (2013) 'Listeriosis during Pregnancy: A Public Health Concern', *ISRN Obstetrics and Gynecology*, **2013**, pp. 1–6.

Serventi, L. *et al.* (2020) 'Pregnancy Complicated by *Listeria Monocytogenes*: A Case Report and Review of the Literature', *Journal of the National Medical Association*, **112**(4), pp. 428–432.

Stein, H. *et al.* (2018) 'Listeriosis in fattening pigs caused by poor quality silage - A case report', *BMC Veterinary Research*. BMC Veterinary Research, **14**(1), pp. 1–9.

Zekarias, T. and Dema, T. (2019) 'Listeriosis in Ruminants and its Zoonotic Importance : A Review', *Advances in Biological Research*, **13**(2), pp. 52–61.

5.2.3 Brucellosis in ram

Abstract

Brucellosis is a highly contagious bacterial disease known by causing orchitis in rams. This case report describes a case of brucellosis in a ram. On February 8/2021 a ram was presented with a problem of decreased appetite, depression and testicular enlargement to AAU, CVMA, Bishoftu. Up on physical examination the ram had un-proportional enlarged testicle, fever (41°C) and depression. Based on history and clinical findings the case was diagnosed as brucellosis. To confirm the case modified rose bengal plate test was used and positive result was found. Then oxytetracycline, 0.2ml/10kg/day, IM for 3 successive days and dexamethasone, 0.2 mg/kg/day for two days was given. Then after the treatment the ram showed a good progress but the ram was sold before the completion of the treatment. As the disease has economic and zoonotic importance the owner was able to get professional advices. Therefore brucellosis is an important zoonotic disease which needs a long term antibiotics to be removed.

Key words: *Brucellosis, Orchitis, Oxytetracycline and Ram*

Introduction

Brucellosis is a highly contagious disease caused by the Gram negative bacteria of the genus *Brucella*. The disease has diverse host range including human, cattle, pig, goat, dog and even ocean animals. Brucellosis is considered as one of the most widespread zoonoses in the world by OIE, WHO and FAO. It is an economically important disease of livestock causing reproductive wastage through infertility both in male and female, delayed heat, loss of calves, retained placenta, endometritis, reduced meat and milk production, culling and economic losses from international trade bans (Cho *et al.*, 2010; Swai and Schoonman, 2010; Beruktayet and Mersha, 2016).

Brucellosis in small ruminants is mainly caused by *Brucella melitensis* (*B.melitensis*) and *B. ovis* in sporadic case by *B.abortus*. This disease is mainly characterized by abortion in females

with the development of yellowish, sticky layers on the placenta. In male animals, it causes orchitis and epididymitis, as well as inflammation of the joints and bursa. The significances of brucellosis in small ruminants expressed by infertility, high mortality rate in lambs and kids, reduced milk production and mastitis (Tilahun *et al.*, 2016).

The main source brucellosis in ruminants is contamination with fetuses, fetal fluids and vaginal discharges. Shedding of *Brucella* is also common in udder secretions and semen. *Brucella* can be isolated from various tissues. The pathogenesis of brucella began when the organism enters animal body. Once *Brucella* spp have invaded, usually through the digestive or respiratory tract, they are capable of surviving intracellular within phagocytic or non-phagocytic host cells. Even Brucellae has the ability to replicate in a wide variety of mammalian cell types, they display strong tissue tropism and replicate within vacuoles of macrophages, dendritic cells (DCs) and placental trophoblasts. Because of intracellular lifestyle of *Brucella*, limits exposure to the host innate and adaptive immune responses also from some antibiotics (Poester, Samartino and Santos, 2013; Figueiredo *et al.*, 2015).

The clinical signs of brucellosis are related with reproductive system like abortion, stillbirth, death of young ones, retained placenta or birth of weak calves, delayed calving marked reduction in milk yield, vesiculitis, orchitis epididymitis and fever. This disease is one of the drug neglected disease and treatment of brucellosis in domestic animals is not indicated, but if necessary the treatment often given are streptomycin, chlortetracycline and chloramphenicol. Humans are usually treated with antibiotics such as, doxycycline and rifampicine (Beruktayet and Mersha, 2016; Khan and Zahoor, 2018).

Rose Bengal plate agglutination test is a simple, rapid, spot test for the detection of *Brucella*. The test depends on the ability of antibody in the patient's serum to agglutinate the stained bacterial antigen. When the test is positive the agglutination becomes clearly visible to the naked eye (Manish *et al.*, 2013).

Case description

On February 8/2021 a ram was presented to AAU, CVMA, Bishoftu in a complaint of decreased appetite, depression and testicular enlargement. As the owner told me that he bought the ram for fattening purpose days before the presentation to the hospital. The disease condition was seen in the week of the presentation and no physical trauma has been occurred on the ram. On the physical examination the ram was found depression, febrile (41°C), foamy discharge from mouth and the testicles were not found un-proportional, the right side testicle was enlarged as indicated in the arrow. Therefore from the history and clinical signs brucellosis was a tentative diagnosis.



Figure 27: A ram with un-proportional testicle

Differential diagnosis of Brucellosis

Campylobacteriosis, Trichomoniasis, infectious and non – infectious Epididymitis, Listeriosis, Leptospirosis, *Chlamydiosis* with abortion and Abortion non – infectious etiology.

Laboratory investigation and findings

To confirm the case a serum sample was taken from the ram then stored -20 °C until screened and tested for antibodies against natural *Brucella* exposure analysis using modified Rose Bengal Plate Test (mRBPT) to at microbiology laboratory CVMA, AAU. The antigen used was Rose Bengal antigen, which is made up of *B. abortus* suspension. First normal rose bengal test was performed and it shows barely visible agglutination and then a modified rose bengal

test (75 μ l of serum and 25 μ l of antigen were mixed on a test plate and rocked for 4 minutes) was performed which shows a indicates fine agglutination.

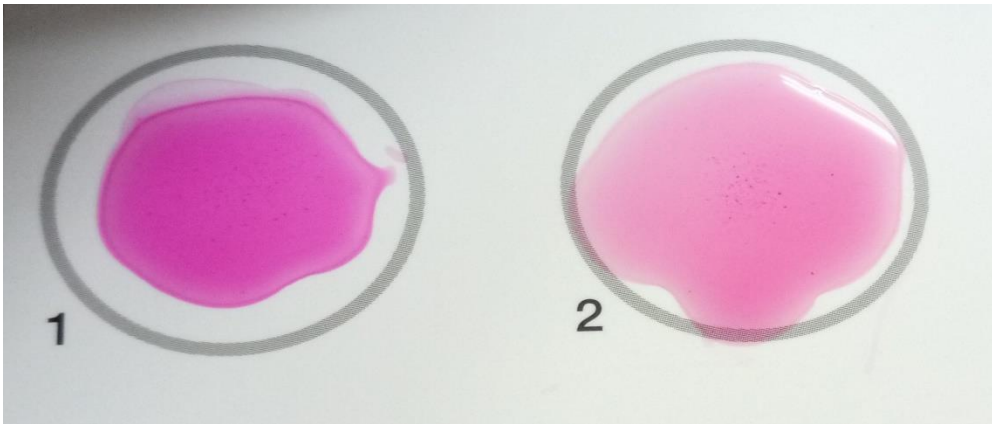


Figure 28: Rose bengal test (A) Rose bengal test showing a slight positive result and (B) modified rose bengal test showing moderate agglutination

Case management

After serum sample was collected for further laboratory diagnosis, a treatment was commenced based on the tentative diagnosis. The ram was treated with oxytetracycline (Hebei Kexing pharmaceutical Co.Ltd) 0.2ml/10kg/day, IM for 3 successive days and dexamethasone 0.1 mg/kg at a dose of 0.2 mg/kg/day for two days treatment. After the treatment the enlarged testicle decrease in size and disease signs were become subside.



Figure 29: The appearance of proportional testicle after treatment

Challenge

As the size of the testicle was become decreased the owner stops the follow up and sold the ram. This prevents the continuity and change of the treatment after the confirmatory diagnosis.

Discussion

The main clinical sign of the ram with brucellosis was orchitis and the right side testicle was more enlarged than the left one. This is supported by the work of Foster. It says that the main clinical sign of brucellosis in males is manifested by orchitis and also is often associated with a vesiculitis and epididymitis. Even both sides are affected the infection is usually unilateral. Systemic involvement of the disease was also seen in this particular case mainly manifested by fever and depression. Also this is supported by Wang and Guo study (Wang and Guo, 2016; Foster, 2017).

Because orchitis has many causative reasons modified rose bengal test was used to confirm the tentative diagnosis. As the study of Ekiri indicates RBPT has test sensitivity (DSe) 87.5% and specificity (DSp) of 100% it was found compatible to confirm the case properly. The reason of using modified type of rose-bengal test was because the RBPT is made up of *B.abortus* antigen therefore it has a decreased sensitivity to detect ovine brucellosis. Therefore to increase the sensitivity of the test the modified one was used (Ekiri *et al.*, 2020)

For the purpose of treatment oxytetracycline 10% was used. Even most of the time to treat animal infected by brucella is not common and neglected long term treatment with antibiotics can heal the animal. In the text book of Radostits 11th edition using long-acting oxytetracycline every 3 days for 24 days with a combination of dihydrostreptomycin sulfate daily IM cure of 90% of experimentally infected rams. But in this case even using oxytetracycline alone had a good progress in three days follow-up (o. M. Radostits, 2010).

In conclusion brucellosis in this affected ram was manifested by local and systemic complications. As the disease has a high economic and zoonotic importance the owners were able to get professional advice to take a care for themselves and their animals.

Acknowledgments

I thank you Mr. Muluken Tekle for supporting me in the laboratory work and Dr. Tewdrose for handling the case with me.

References

- Beruktayet, W. and Mersha, C. (2016) 'Review of Cattle Brucellosis in Ethiopia', *Academic Journal of Animal Diseases*, 5(2), pp. 28–39. doi: 10.5829/idosi.ajad.2016.28.39.
- Cho, D. *et al.* (2010) 'Quantitative rose bengal test for diagnosis of bovine brucellosis', *Journal of Immunoassay and Immunochemistry*, 31(2), pp. 120–130. doi: 10.1080/15321811003617420.
- Ekiri, A. B. *et al.* (2020) 'Utility of the Rose Bengal Test as a Point-of-Care Test for Human Brucellosis in Endemic African Settings: A Systematic Review', *Journal of Tropical Medicine*, 2020. doi: 10.1155/2020/6586182.
- Figueiredo, P. De *et al.* (2015) 'Pathogenesis and Immunobiology of Brucellosis Review of Brucella e Host Interactions', *The American Journal of Pathology*. American Society for Investigative Pathology, 185(6), pp. 1505–1517. doi: 10.1016/j.ajpath.2015.03.003.
- Foster, R. A. (2017) 'Chapter 19 - Male Reproductive System1', in Zachary, J. F. (ed.) *Pathologic Basis of Veterinary Disease (Sixth Edition)*. Sixth Edit. Mosby, pp. 1194–1222.e1. doi: <https://doi.org/10.1016/B978-0-323-35775-3.00019-9>.
- Khan, M. Z. and Zahoor, M. (2018) 'An overview of brucellosis in cattle and humans, and its serological and molecular diagnosis in control strategies', *Tropical Medicine and Infectious Disease*, 3(2). doi: 10.3390/tropicalmed3020065.
- Manish, K. *et al.* (2013) 'Brucellosis: An updated review of the disease', *Indian Journal of Animal Sciences*, 83(1), pp. 3–15.
- o. M. Radostits (2010) *VETERINARY MEDICINE A textbook of the diseases of cattle, horses, sheep, pigs and goats*. 10th edn. Edited by o. M. R. C. C. G. K. W. H. P. D. Constable.
- Poester, F. P., Samartino, L. E. and Santos, R. L. (2013) 'Pathogenesis and pathobiology of

brucellosis in livestock Pathogenesis of brucellosis infection in cattle', 32(1), pp. 105–115.

Swai, E. S. and Schoonman, L. (2010) 'The use of rose bengal plate test to asses cattle exposure to Brucella infection in traditional and smallholder dairy production systems of Tanga Region of Tanzania', *Veterinary Medicine International*, 2010. doi: 10.4061/2010/837950.

Tilahun, Alebachew *et al.* (2016) 'Review on Small Ruminant Brucellosis in Ethiopia', *Advances in Life Science and Technology*, 46, pp. 16–24.

Wang, W. and Guo, Z. (2016) '[Brucella orchitis: A retrospective study of 69 cases].', *Zhonghua nan ke xue = National journal of andrology*. China, 22(1), pp. 46–51.

5.2.4 Urinary tract infection in ram

Abstract

Urinary tract infection indicates infection anywhere in the urinary tract. There are many causes of urinary tract infection but *Corynebacterium renale* and *Escherichia coli* are the common causative agents. In rams urolithiasis is the most common urinary tract problem but in this case report urinary tract infection caused by *Escherichia coli* was found. The diagnosis approach to find out this goes from the simplest to the complicated one to reach to the exact cause of the disease. On the physical examination hyperemic penis and pus like fluid on the tip of the penile sheath was found in visualization and pain was found upon palpation of urogenital area. To confirm the case both penile swab and blood samples were taken and cultured on blood agar and MacConkey agar. Culture from blood sample was found negative, and culture from penile swab was found positive with characteristic figure of E-coli in selective culture medias. The pathogenicity of the bacteria was checked on sorbitol MacConkey agar and found pathogenic. Oxytetracyclin antibiotics were used to treat the infection and had progressive change day to day. And finally the ram was display for the holiday market with a good health status. Therefore giving appropriate antibiotics for urinary tract infection can heal the diseased animal and prevent other complications.

Key words: *Escherichia coli*, *Urinary tract infection* and *urolithiasis*

Introduction

Urinary tract infection (UTI) is a non-specific term used to indicate infection anywhere in the urinary tract. The infection in different parts of the urinary tract has their own specific names like cystitis is an infection of bladder and phylonephritis is an infection of kidney infection. The infection of urethra and ureter are referred to as urethritis and ureteritis respectively. Lower urinary tract infection includes bladder infection and the descending parts which are most of the time asymptomatic. Complications of lower UTI include ascending infection leading to pyelonephritis, renal failure and sepsis. There are both symptomatic and asymptomatic urinary tract infection (Vasudevan, 2014; Sekharan *et al.*, 2017; NICE, 2018).

While infection associated with urinary tract in sheep can be caused by different etiological

agents like bacteria, viruses and mycoplasmas, their occurrence is believed to be sporadic with small number of individuals rather than the whole flocks. Infections are most of the time are bacterial, *Corynebacterium renale* and *Escherichia coli* are the organisms which are most frequently responsible for either upper or lower urinary tract infections in ruminants (Divers, 1988; Nicholas, 2020).

Escherichia coli is the most frequent cause of urinary tract infection. The organism is one of the normal flora found in urinary tract. A major virulence factor of uropathogenic *E. coli* is its ability to adhere to epithelial cells of the urinary tract by means of pili. Clinical evidence suggests that UTI results from faecal contamination of the urogenital tract or loss of normal urinary tract defenses were infected with *Corynebacterium renale*. *Corynebacterium* organisms were isolated not only from the urine but also from swabs of the vaginal vestibule. *C. renale* is a commonly found renal pathogen in cattle, causing cystitis and, infrequently, ascending (Yeruham *et al.*, 2006).

The clinical and pathological findings of urinary tract infection is characteristic by inflammation, frequent urination of small volumes of urine, blood and pus in the urine and the urine smelling strongly of ammonia. In addition bacteriuria, proteinuria and inflammatory cells were observed in the urine analysis. Azotaemia was a very uncommon finding, which indicated that the kidneys were not involved (Elad *et al.*, 2004).

To confirm urinary tract infection bacterial culture from suspected animals is done frequently. Samples can be urine and also vaginal or preputial for culture and identification of the causative organism. Bacteriological samples were inoculated onto blood agar (5% sheep), nutrient agar and McConkey agar and examined after 24 h of incubation (Yeruham *et al.*, 2006). To make accurate diagnosis knowledge of clinical history and animal's diet are important and also they are the key to successful control of urinary tract disease. Other important data required include: previous treatments, age of castration and time since parturition and (Nicholas, 2020).

Urinary tract infections treatment should be selected based on quantitative urine culture. The characteristics the selective drug should be active against the causal bacteria, be excreted and concentrated in the kidney and urine, be active at the pH of urine, have low toxicity,

particularly nephrotoxicity, be easily administered, be low in cost, have no harmful interactions with other concurrently administered drugs. General principles of treatment of urinary tract infections were presented earlier (Constable *et. al.*, 2017).

Case description

On April 22 an owner brought his sheep in a complaint of unable to void urine, depression and decreased in feed intake. As the explanation of the owner the sheep were bought from the market recently for fattening purpose but one of them died due to the same problem. Upon physical examination the urogenital area was palpated and visualized for abnormalities based on the history. During visualization pus-like fluid was found on the tip of the penile sheath (Figure 30B). Palpation reveals the presence of pain around the urogenital area but the ram was able to urinate merely without urethral process amputation. Then the penis was manipulated to come out from the sheath and the area was found hyperemic (Figure 30C). The temperature was elevated (41.5°C), heart rate was fast (120 beats/min) and respiratory rate was increased (44 breath/min) were found. Based on the history and physical examination urinary system infection was suspected.

Differential diagnosis of UTI caused by *E. coli* in ram

Urolithiasis and UTI other than *E. coli* like *Corynebacterium renale*.

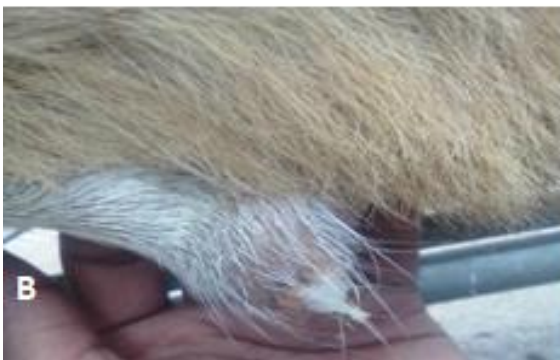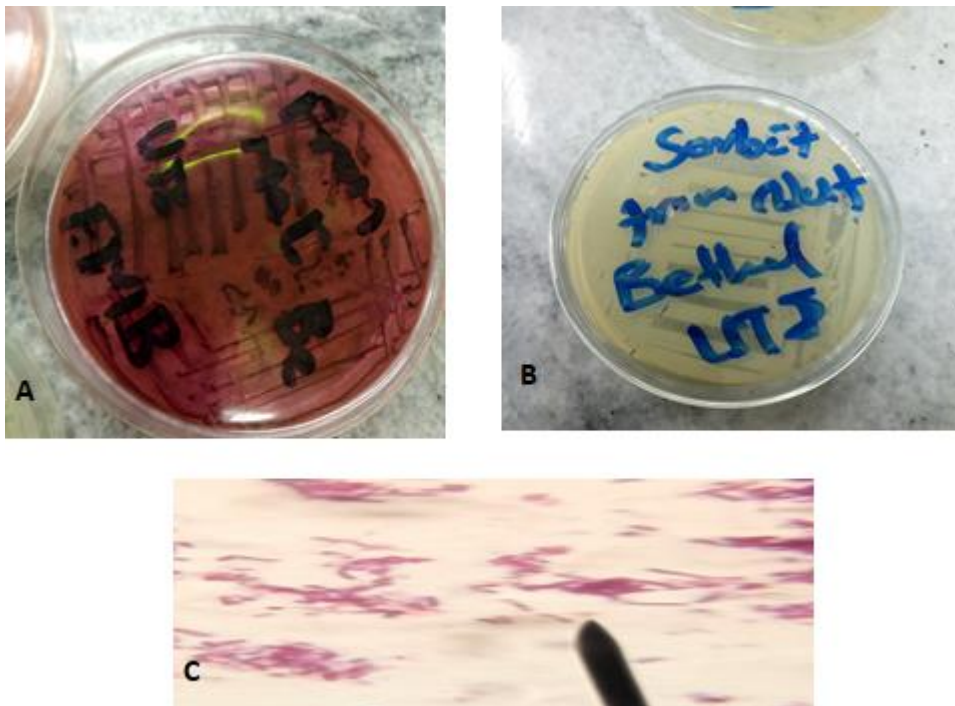


Figure 30: UTI infected ram (A); the diseased ram in VTH, (B); pus like fluid on the tip of the penile sheath and (C) hyperemic penis

Laboratory investigation and findings

Based on history and clinical findings the ram was suspected for urinary tract problem. Then appropriate sample which is a penile swab and blood were taken and processed in microbiology laboratory. The penile swab was first brought by using tryptone soya broth transport media and then after 24 hrs of incubation the samples were cultured on 5% blood agar and MacConkey agar. On the blood agar the sample that has been taken from the blood had no growth but the swab sample show beta hemolysis. Again the same sample that was cultured on MacConkey agar indicate no growth for the blood sample but swab sample was grown on this media as a pink colony. Then the sample that was grown on the blood agar subculture on the nutrient agar to do a gram stain. The gram stain indicates a gram negative

rod shaped bacteria. On the other way sample that has grown on MacConkey agar subculture on eosin methylin blue agar (EMB) and black colony with green metallic sheen was found which a characteristics of E-coli. Finally to differentiate the pathogenic tendency of the isolate the colony was subculture on sorbitol MacConkey agar and the result indicate yellow colored colony because of sorbitol non-fermenting characteristics of means the presence of pathogenic E-coli.



Laboratory work on sample taken from UTI infected ram

Figure 31: Laboratory work on sample taken from UTI infected ram (A); Black colony with green metallic sheen in eosin methylin blue agar (EMB) (B); pathogenic E-coli on sorbitol MacConkey agar and (C) rod shaped gram negative colony on the gram stain.

Case management and treatment outcome

The ram was treated with 10% oxytetracycline (Hebei kexing Pharmaceutical Co., Ltd, China) IM at 1ml/10kg/day for three days. During the treatment the ram showed a good progress. In which it urinate properly without pain, the ram become active and the owner told the returning

of the appetite to normal position. After three days because the owner looked the progress of the ram he sold it for the holyday market.

Discussion

Based on the history, clinical sign and laboratorial findings the case was confirmed as lower urinary tract infection. Different clinical signs were seen in this affected ram which is more or less called inflammation which is characterize by hyperemia, pain in touch, swelling and loss of tissue function (Chen *et al.*, 2018).

Urolithiasis is a common urinary tract infection in ruminants. As a review of Makhdoomi and Gazi Urolithiasis has been extensively reported in ruminant species and is a common problem encountered in male sheep, goat and cattle. Both sexes are affected by this case but it is a major problem only in males. There for in this case based on the history the first suspicion was urolithiasis but on the palpation and glans penis exteriorization the ram can urinate without urethral process amputated, there for the diagnosis was mandated to go further (Makhdoomi and Gazi, 2013). The Clinical signs of urinary tract infection mimic those of urolithiasis, but based on laboratory findings it can be differentiated including by bacterial culture. Therefore laboratory diagnosis was take place to differentiate the case (Pignon and Mayer, 2021).

To diagnose the case a chosen method was to goes from the simplest to the complicated one. There for first the step was checking for urolithiasis which was become negative. Then penile swab and blood samples were taken and cultured on different medias to isolate the causal agent. As the explanation of Constable *et al* *Corynebacterium renale* and *Escherichia coli* are the most common causative agents of urinary tract infection in rams. *Corynebacterium renale* is the cause of Ovine posthitis (pizzle rot) which has ulceration of the prepuce near the orifice (Constable *et al.*, 2017; Foster, 2017).

Based on the laboratory finding the causative agent of urinary tract infection was confirmed as E-coli. The gram staining indicates a gram negative rod shaped bacteria which remove the suspicion of *Corynebacterium renale* from the tentative diagnosis because this bacteria is a non-motile gram-positive rods bacteria. Therefore urinary tract infection in this ram is due to

pathogenic E-coli. Therefore further diagnosis was not performed because the diagnosis reached to the definitive one (Underwood *et al.*, 2015).

Antibiotic treatment was administered in this case in which the prognosis was found best and has a day to day progress until final dose because the case was found mild and appropriate antibiotics was used. This is supported by the idea of Constable *et al.* Beyond the laboratory conformatiion response for the drug was taken to evaluate the good diagnosis approach towards the cae (Constable *et al.*, 2017).

Conclusion

Even urinary tract infection is not common in rams, *Escherichia coli* is a common cause of this infection. Therefore use an appropriate antibiotics can heal the animal and prevent the disease from further complication.

Acknowledgments

I am grateful to Getachew Adamu and Adem Hussen (5th year students) for their collaboration.

References

- Chen, L. *et al.* (2018) ‘Inflammatory responses and inflammation-associated diseases in organs’, *Oncotarget*, **9**(6), pp. 7204–7218.
- Constable, P. D. *et al.* (eds) (2017) ‘13 - Diseases of the Urinary System’, in *Veterinary Medicine (Eleventh Edition)*. Eleventh E. W.B. Saunders, pp. 1095–1154. doi:
- CONSTABLE, P. D. and KENNETH W. HINCHCLIFF STANLEY H. DONE WALTER GRÜNBERG (2017) *VETERINARY MEDICINE 11th edition*.
- Divers, T. J. (1988) ‘Urinary Tract Disorders in Cattle’, *THE BOVINE PRACTITIONER*, 24.
- Elad, D. *et al.* (2004) ‘Four-year survey of urinary tract infections in calves in Israel’, *veterinary record*, **154**, pp. 204–206.
- Foster, R. A. (2017) ‘Chapter 19 - Male Reproductive System1’, in Zachary, J. F. (ed.) *Pathologic Basis of Veterinary Disease (Sixth Edition)*. Sixth Edit. Mosby, pp. 1194-1222.

- Makhdoomi, D. M. and Gazi, M. A. (2013) 'Obstructive urolithiasis in ruminants - A review', *Veterinary World*, **6**(4), pp. 233–238. doi: 10.5455/vetworld.2013.233-238.
- NICE (2018) *Urinary tract infection (lower): antimicrobial prescribing guideline*.
- Pignon, C. and Mayer, J. (2021) '21 - Guinea Pigs', in Quesenberry, K. E. et al. (eds) *Ferrets, Rabbits, and Rodents (Fourth Edition)*. Fourth Edi. Philadelphia: W.B. Saunders, pp. 270–297.
- Sekharan, C. B. *et al.* (2017) 'Evaluation of the Prevalence of Urinary Tract Infection in Females Aged 6-50 Years at Kinondoni District , Tanzania', *Sci. Int.*, **5**(2), pp. 43–46.
- Underwood, W. J. *et al.* (2015) 'Chapter 15 - Biology and Diseases of Ruminants (Sheep, Goats, and Cattle)', in Fox, J. G. et al. (eds) *Laboratory Animal Medicine (Third Edition)*. Third Edit. Boston: Academic Press (American College of Laboratory Animal Medicine), pp. 623–694.
- Vasudevan, R. (2014) 'Urinary tract infection : an overview of the infection and the associated risk factors', **1**(2), pp. 42–54. doi: 10.15406/jmen.2014.01.00008.
- Yeruham, I. *et al.* (2006) 'A herd level analysis of urinary tract infection in dairy cattle', *Veterinary Journal*, **171**(1), pp. 172–176.

- Abdelrahman, M. M., Kincaid, R. L. and Elzubeir, E. A. (2010) Mineral Nutrition of Livestock, 4th Edition, Mineral deficiencies in grazing dairy cattle in Kordofan and Darfur regions in Western Sudan, 1-576.
- Almaghamsi, A., Almalki, M. H. and Buhary, B. M. (2018) ‘Hypocalcemia in pregnancy: A clinical review update’, *Oman Medical Journal*, **33**(6), pp. 453–462.
- CGH, M. I. (2015) Acute Treatment of Hypocalcaemia (adults), GHNHSFT Drug & Therapeutics Committee.
- CONSTABLE, P. D. and KENNETH W. HINCHCLIFF STANLEY H. DONE WALTER GRÜNBERG (2017) VETERINARY MEDICINE 11th edition.
- El-Khodery, S. et al. (2008) ‘Hypocalcaemia in Ossimi sheep associated with feeding on beet tops (*Beta vulgaris*)’, *Turkish Journal of Veterinary and Animal Sciences*, **32**(3), pp. 199–205.
- Martins-Bessa, A. et al. (2003) ‘Hypocalcemic tetany in a pet lamb fed with cow milk Giadinis’, *Journal of the Hellenic Veterinary Medical Society*, **85**(1), pp. 3–11.
- o. M. Radostits (2010) VETERINARY MEDICINE A textbook of the diseases of cattle, horses, sheep, pigs and goats. 10th edn. Edited by o. M. R. C. C. G. K. W. H. P. D. Constable.
- Oetzel, G. R. (1988) ‘Parturient paresis and hypocalcemia in ruminant livestock.’, *The Veterinary clinics of North America. Food animal practice. United States*, **4**(2), pp. 351–364.
- Olfati, A., Moghaddam, G. and Bakhtiari, M. (2013) ‘Diagnosis , Treatment and Prevention of Pregnancy Toxemia in Ewes’, **1**(11), pp. 1452–1456.
- Thilsing-Hansen, T., Jørgensen, R. J. and Østergaard, S. (2002) ‘Milk fever control principles: A review’, *Acta Veterinaria Scandinavica*, **43**(1), pp. 1–19.
- Tinawi, M. (2021) ‘Disorders of Calcium Metabolism: Hypocalcemia and Hypercalcemia’,

Cureus. *Cureus*, **13**(1), pp. e12420–e12420.

Woldemeskel, M., Eneyew, M. and Kassa, T. (2000) ‘Study on ovine hypocalcemia in ewes in central Ethiopia’, *Revue de Medecine Veterinaire*, **151**(4), pp. 345–350.

5.2.5 A multifactorial clinical mastitis in cow and heifer

Abstract

Mastitis is one of the most important diseases in the dairy industry. This disease has multiple economic impacts either by direct milk loss or indirectly through cost of the treatment. One dairy farm located in Adama, Ethiopia around “Amde market” was very challenged by relapsing udder disease in a Jersey cross breed heifer and a Holstein Friesian cow which was started months before examination date. As the complaint of the owner when the disease starts the milk become abnormal, the cows have depression; they failed down on the ground and their muzzle become dry. On the farm visit, the animals were found active, feed properly but milk of the cow was found blood tinged and the heifer’s milk clotted immediately after draining. Biosecurity measures were not kept in this farm therefore hygiene was a prominent problem of the farm. Additionally the owner’s misuse of drugs was evaluated as the drawback. To confirm the causative agent, milk sample were taken from the affected teats and cultured. The result indicates the presence of both environmental and contagious mastitis. To control and prevent the disease, the owner was advised to focus on creating hygienic and comfortable environment to the cows additionally penstrip 1ml/20kg/day for five days was administered to both animals. After the intervention the animals were returned to normal health condition but applying biosecurity measures fully was found very difficult to this owner. Therefore mastitis can be occurred in a dairy cow by multiple pathogens and the measures that are taken to control and prevent types of mastitis are different and dependent on the causative agents.

Key words: *Biosecurity, Clinical Mastitis, Environmental mastitis and Hygiene*

Introduction

Mastitis refers the inflammation of the mammary gland. Mastitis is the most costly disease facing the dairy industry that has been associated with a great loss or reduction of productivity, influences the quality and quantity of milk yield, direct death of animal and its zoonotic importance. Most estimates of mastitis have shown a 30% reduction in productivity per

affected quarter and a 15% reduction in production per cow/lactation. Mastitis can be clinical or subclinical and has diverse etiological agents. Sub clinical mastitis refers inflammation of the mammary gland in the absence of observable gross lesions on the udder or its secretion but there are pathogenic microorganisms and unusual number of somatic cells in the milk (Ruegg and Reinemann, 2002).

Clinical mastitis is infection of the udder that results in visible changes in the udder quarter and milk, may it be acute, sub-acute or chronic characterized by heat, pain, swelling and redness of the udder, along with reduced as well as an abnormal nature of milk yield. It is usually accompanied by a mild fever and the animal is depressed. The affected quarter is sensitive to touch and painful to the. The development of clinical mastitis in dairy cows can be detected with high sensitivity and specificity in advance of visible changes in foremilk or udder tissue by determining the electrical conductivity of the foremilk (Fadl-El-Moula, 2019).

Based on the causative micro-organisms mastitis can be classified into contagious and environmental mastitis. In contagious type of mastitis bacteria lives on skin of teat and udder. Therefore the infection transmits from infected to susceptible through contaminated hand and fomites. After the contact the bacteria establish itself on the surface of teat and the canal which is used as a bridge to enter to the mammary gland. The major of pathogens responsible for contagious mastitis cause sub-clinical mastitis and it includes staphylococcus aureus, streptococcus agalactiae and streptococcus dysgalactiae. the control measures for this type of mastitis include milking hygiene, dry cow therapy, segregation and culling (Andrews *et al.*, 2004; Kibebew, 2017).

Environmental mastitis is mastitis in which the cow's environment is used as a reservoir for the infection. These environmental factors includes: straw bedding, sawdust, manure and pasture. The disease transmits between milking or on the preparation for milking. Environmental mastitis is highly prevalent in hot and wet environment. The major pathogens for environmental mastitis are: *E. coli*, *Streptococcus uberis*, *Klebsiella* spp and *Bacillus* spp. Controlling environmental mastitis are related removing uncomfortable conditions such as providing a clean environment, appropriate disposal of waste, removing suffocated

atmosphere, preparing dry and inorganic bedding and removing stagnant waters (Andrews *et al.*, 2004; Hogan and Smith, 2012; Klaas and Zadoks, 2018).

Diagnosis of clinical mastitis is based the udder size, consistency, symmetry, fibrosis and inflammation signs. The milk is also looked for clot, pus, blood and wateriness in the diagnosis of mastitis. The standard definitive confirmatory diagnosis of mastitis is a bacterial culture and also culturing the sample is a measure of determining udder health (Ibrahim, 2018; Shoukat *et al.*, 2018; Giri *et al.*, 2020).

To treat clinical mastitis antimicrobial therapy is not the ultimate option. Most of the time drug treatment has significant effect on contagious mastitis but has no effect on environmental types of mastitis. The most common route of antimicrobial causing mastitis is intermammary infusion but for *S. aureus* infection and severe form of coliform mastitis systemic administration of antibiotics are recommended. Combining both systemic and IMM are best to treat mastitis cases (Hillerton and Berry, 2005; Argaw, 2016).

Mastitis has significant economic effect on dairy farms including reduction in milk yield, loss of milk components, veterinary and treatment costs, low quality milk, extra labor, other complications including reproductive disorder and culling (Nielsen, 2009). Therefore the objective of this case report is to diagnose the causative agent of mastitis in frequently distressed heifer and cow and put the important interventions in order to prevent and control the disease in this farm.

Case description

On February 12 a dairy farm owner and animal health expert communicate me in a problem of dairy cows found around “Amede market”, Adama, Ethiopia. The farm had a total of three cows, one calf and bulls. As their explanation the 2 cows were (Figure 32A) frequently affected by udder disease and exhibit symptoms like abnormal colored, consistence and amount of milk, depression, falling down on the ground and being dried around their muzzle. The first cow was an adult cross breed Holstein Frisian cow which had three parties and the last parity was before 5 months. This cow shows the clinical sign of mastitis 8 months before the day of examination. The second one was a Jersey cross breed heifer which had a first

parity 3 months ago. Then the clinical signs of mastitis were seen 2 months ago. Therefore; since that time the owner used many drugs frequently in combination to tackle the relapsing mastitis. For example as he said that he used penstrip injectable solution as intera-mammary infusion and IM for days then he looked a good progress but the case relapsed after 2 months again. Then he used drugs like gentamycin, procaine penicillin and metronidazole in combination for 5 successive days and again he looked a good progress but the case was not totally cured from the farm and relapsed within 30 day after the treatment. Hence the owner was tired of treating the cows and loss of the milk due to the disease he was in need of professional intervention. On the farm visit the cows were found active, they feed properly and the temperatures of both cows were found normal. But the farm was not found hygienic (Figure 32B & D), there was stagnant water in the room, the handlers were not protective and the fodder house was exposed to contaminants, no restriction and foot bath on entrance of the farm and the house contraction was not found uncomfortable for the cows. Depending on the history the milk of both cows was drained from affected teats and was seen for abnormality. The milk from Holstein Frisian was found full of blood and the milk from the Jersey was found with coagulating minutes after milking (Figure 32D). Therefore based on the history and clinical signs the case was tentatively diagnosed as clinical mastitis.



Figure 32: The two mastitic cows in their house(A); Unhygienic condition indicated by the arrow (B); Milking of the affected teat (C) and (D) A blood tinged milk from affected teat and stagnant water around the cow

Laboratory investigation and findings

For the exact identification of the causative agent milk samples were taken from the affected teats of both cows and submitted to AAU/CVMA microbiology laboratory by keeping the cold chain. Then the samples were cultured in to 5% blood agar and macConkey agar and incubated for 24 hours. The samples cultured on both Medias were grown. Then the sample from macConkey agar sub-cultured on Eosin Methylin Blue (EMB) and colonies from the blood agar cultured on Mannitol salt agar. In the EMB agar black, pink and purple mucoid and pure colonies were grown. These characteristics were of E-coli and Klebsiella (Figure 33 A&B). The colony cultured on Mannitol agar was shown yellowish colony with yellowish

zone (Figure 33C) which an indicative of staphylococcus infection is. Therefore based on the confirmatory diagnosis the case was confirmed as clinical mastitis caused by both environmental and contagious mastitis causing pathogens.

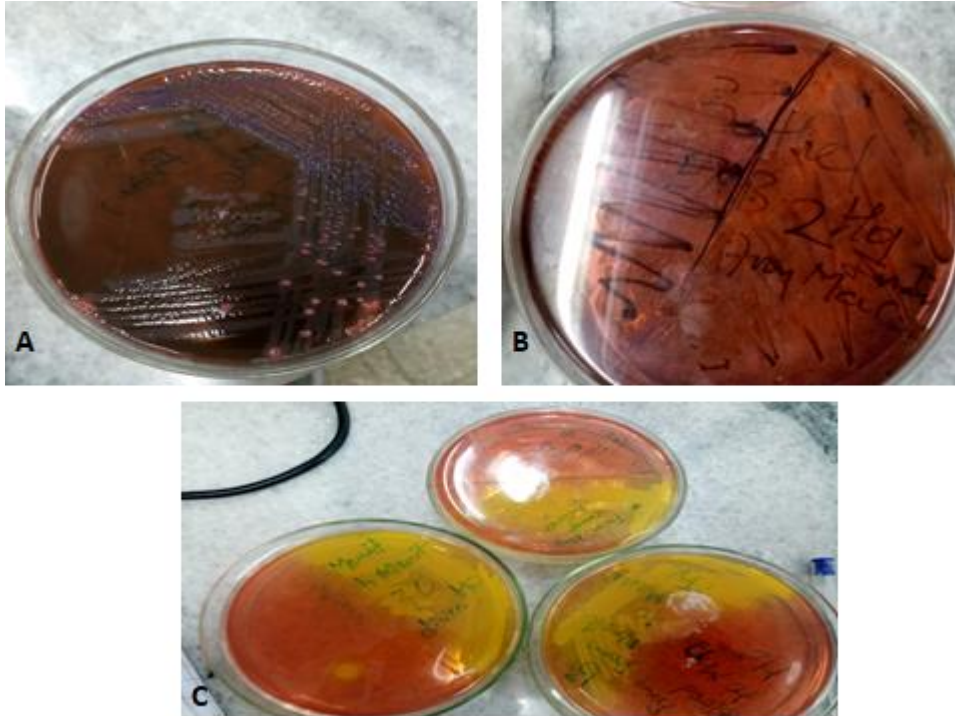


Figure 33: Laboratory result of sample from mastitic cow (A & B): Pink, purple and black colonies on EMB and (C); yellowish colony with yellowish zone in Mannitol salt agar

Case management and out come

After the confirmatory diagnosis of multiple types of bacteria as the causative agents of clinical mastitis and frequent relapse of the case were considered, treating the cows merely by antibiotics was not found to be a permanent measure to cure the animals from this clinical mastitis. Therefore the owner was advised to create hygienic environment by cleaning and disinfecting the house and taking biosafety measures. Additionally the animal health expert and the owner were advised to give penstrip IM, for 5 days as a last medication of this case. Then on the phone follow up the case had a good progress but creating full hygienic condition was found difficult for the owner. Hence full recovery was not able to attain. Therefore based

on professional advice the owner decided to change his cows and improve his environment for the next round. The owner was also aware about his misuse of antibiotics.

Discussion

Based on the history, clinical signs and laboratorial identification the case was confirmed as clinical mastitis caused by multiple pathogens. The history and clinical signs were found indicatives of clinical mastitis except the confirmation of the causative agents. In the history, local and systemic signs were shown but the clinical examinations identify only the presence of abnormal milk. As the study of Malinowski clinical mastitis is the production of atypical milk in color, consistency and amount with or without secondary local or systemic symptoms like raised temperature and swelled quarter (Malinowski E., 2010; Argaw, 2016). The laboratory investigation of the case was done widely because there are multiple causative agents of clinical mastitis. The protocol that has been used in this work was the same with the work of Amer *et.al.* According to Andrew the most responsible pathogen of mastitis includes *S. aureus*, *E. coli* and *Klebsiella* sp. in which most of the organisms were identified in this (Andrews *et al.*, 2004; Amer *et al.*, 2018).

The predisposing factors for this clinical mastitis can be putted as the host factor, the pathogen factor and the environment. Factors related to the host are age, parity and lactating stage. According to Zerihun T., Aya T., and Bayecha R. young adult and adult cows has the rate of mastitis 65% and 93.2%, respectively. This is also true for the present case where the age of the animal is in young and young adult. According to different authors including the previous one the high prevalence of mastitis was recorded in early lactation but the mid and late lactating are also affected as the presented case. Based on the study of Morese *et al.* when the parity increases the occurrence of clinical mastitis is increased. Actually in the present case even the number of parity differs between the cows both are affected but the case was first seen and was sever in the cow with multiple parity (ALI, 2013; Argaw, 2016). Clinical mastitis consequences are highly dependent on the causative agents. According to Kalińska, Gołębiewski and Wójcik, the most responsible pathogen of mastitis in cows are: *S. aureus*, *Streptococcus* sp., *A. pyogenes*, *E. coli* and *Klebsiella* sp. in which most of the organisms

were identified in this work. As Lehtolainen *et al* said this pathogens have their own virulence factors to invade the udder therefore their virulence is related with this fact (Lehtolainen *et al.*, 2003; Kalińska, Gołębiewski and Wójcik, 2017).

In the present study the farm and the cow's hygiene were kept in poor manner. This is the most common reason for the prevalence of environmental mastitis as well as contagious mastitis. According to Klaas even exact classification of environmental and contagious mastitis are difficult loss of hygiene have significant effect for the presence of these type of pathogen which are seen in this case (Klaas and Zadoks, 2018). Therefore the control and prevention practices of clinical mastitis depend on the causative agents and the severity of the cases. This is also supported by the work of Margarita and Elena (Margarita and Elena, 2012).

The very important concept that we look in this work is the misuse of the antimicrobial agents. This includes the loss of consideration on timing, non-stop usage of different drugs and the administration of the drug in the wrong route which affect economic and is prone to antimicrobial resistance. As the review of Argaw antibiotics are prescribed for clinical mastitis and become effective when used early in contagious type of mastitis (Argaw, 2016). According to different authors mentioned on the study Lago indicates using intermammary infusions for gram negative isolates have no value (Lago *et al.*, 2011).

In this case the full concern of the owners against mastitis control and prevention were fully dependent of antibiotics but according to Hogan and Smith and other authors control and prevention of mastitis must focused on creating good and hygienic environment this include removing stagnant water around the cow, provide clean and dry bedding, appropriate disposal of manure frequent manure removal, hygienic milking, segregation and culling. In this case applying different measures were suggested (Andrews *et al.*, 2004; Hogan and Smith, 2012; Kibebew, 2017).

Conclusion

Clinical mastitis has a multiple crises in dairy farms when the case relapses again and again. Therefore it is better to take measures early by giving attention for the environmental hygiene

and way of disease transmission from infected to the susceptible animals as the cause of mastitis in this case is multifactorial.

Acknowledgments

I am grateful to Mr. Beyene (from Adama veterinary clinic), Mr. Muluken (AAU, CVMA, microbiology lab assistant) and the owner of the animals.

References

- ALI, L. (2013) Epidemiology of Mastitis in Dairy Buffalo and Cow in Tehsil Samundri in Clinical Medicine and Surgery Department of Clinical Medicine & Surgery, *Journal of Chemical Information and Modeling*, **53**(9), pp 1689-1699.
- Amer, S. *et al.* (2018) 'Prevalence and etiology of mastitis in dairy cattle in El Oro Province, Ecuador', *Journal of Veterinary Medical Science*, **80**(6), pp. 861–868.
- Andrews, A. H. *et al.* (2004) *Bovine Medicine Diseases and Husbandry of Cattle*, 326-336.
- Argaw, A. (2016) 'Review on Epidemiology of Clinical and Subclinical Mastitis on Dairy Cows', *Food Science and Quality Management*, **52**, pp. 2224–6088.
- Fadl-El-Moula, A.-A. A. (2019) 'Investigations of factors affecting the udder health status of dairy cows in Thuringia' 1-124.
- Giri, A. K. *et al.* (2020) 'A Review on Mastitis in Dairy Animals', *International Journal of Current Microbiology and Applied Sciences*, **9**(9), pp. 1844–1852.
- Hillerton, J. and Berry, E. (2005) 'Treating mastitis in the cow _ a tradition or an archaism', *Journal of Applied Microbiology*, 98.
- Hogan, J. and Smith, K. L. (2012) 'Managing environmental mastitis.', *The Veterinary clinics of North America. Food animal practice*. United States, **28**(2), pp. 217–224.
- Ibrahim, N. (2018) 'Review on Mastitis and Its Economic Effect Review on Mastitis and Its Economic Effect', (January 2017).

- Kalińska, A., Gołębiowski, M. and Wójcik, A. (2017) 'Mastitis pathogens in dairy cattle – a review', *World Scientific News*, **89**(11), pp. 22–31.
- Kibebew, K. (2017) 'Bovine Mastitis: A Review of Causes and Epidemiological Point of View', *Journal Of Biology, Agriculture and Healthcare*, **7**(2), pp. 1–14.
- Klaas, I. C. and Zadoks, R. N. (2018) 'An update on environmental mastitis: Challenging perceptions.', *Transboundary and emerging diseases*. Germany, **65** (1), pp. 166–185.
- Lago, A. *et al.* (2011) 'The selective treatment of clinical mastitis based on on-farm culture results: II. Effects on lactation performance, including clinical mastitis recurrence, somatic cell count, milk production, and cow survival', *Journal of Dairy Science*. Elsevier, **94**(9), pp. 4457–4467.
- Lehtolainen, T. *et al.* (2003) 'Association between virulence factors and clinical course of Escherichia coli mastitis', *Acta veterinaria Scandinavica*, **44**(3–4), p. 203—205.
- Malinowski E., G. Z. (2010) 'Mastitis and fertility disorders in cows', *Polish Journal of Veterinary Sciences*, **13**(3), pp. 555-560.
- Margarita, E. and Elena, R. (2012) 'Bovine Mastitis Pathogens: Prevalence and Effects on Somatic Cell Count', *Milk Production - An Up-to-Date Overview of Animal Nutrition, Management and Health*, 359-374.
- Nielsen, C. (2009) 'Economic Impact of Mastitis in Dairy Cows' *Acta Universitatis agriculturae Sueciae*, **12** pp 1-81
- Ruegg, P. L. and Reinemann, D. J. (2002) *Milk Quality and Mastitis Tests*. 4457-4467
- Shoukat, S. *et al.* (2018) 'Mastitis and Its Diagnosis: A Review', *Recent Research Trends in Veterinary Sciences and Animal Husbandry*, **1**, pp. 69–86.

5.3 Diseases caused by parasites

5.3.1 Diagnosis and treatment approach towards Babesiosis in male and female cattle

Abstract

Babesiosis is a tick borne disease which ranks the second most widespread blood-borne disease of animals. Clinical cases of bloody urine due to hemoparasite called *babesia* in cow and bull and their therapeutic interventions are described in this case report. Two similar cases were present in March 2021 from Dalota and Gute peasant associations to veterinary teaching hospital (VTH), Bishoftu in history of bloody urine, decreased feeding and decreased body condition. Up on physical examination the mucous membranes were pale to yellowish in color; bloody urine was found, normal rectal temperature were found. Due to the parturition and mechanical trauma history, the cow was first looked for gynecological injury but the cow was found normal then the first laboratory test for both cases was centrifuging the urine to differentiate between hemoglobinuria and hematuria, was perform and hemoglobinuria was found. Then giemsa stain was made and piroplasmic organisms of *Babesia* in RBC were found. In the meantime packed cell volume was analyzed and lower values were found. After confirmatory diagnosis was made Diminazene aceturate (1ml/20kg, stat), Ivermectin (1ml/50kg, stat) and multivitamin injection (7ml/ head, stat) were given against the blood protozoa, the vector tick and body building respectively. Then both animals healed in days and as the body of the cow was damaged it takes time to come to normal condition.

Key words: *Babesiosis, Blood protozoa, Diminazene aceturate and Hemoglobinuria*

Introduction

Ticks and tick-borne diseases (TBDs) are diseases with a great economic importance and significant adverse impact on the livelihoods of resource limited cattle production areas. In sub-Saharan Africa, the most common tick-borne diseases are babesiosis, theileriosis, anaplasmosis and cowdriosis. These diseases are widely distributed throughout the world,

particularly in the tropics and subtropics and affect 80% of the world's cattle population (Jabbar *et al.*, 2015; Jabir Yusuf, 2017).

Bovine babesiosis is an emerging tick-borne haemoprotozoan which rank the second most widespread blood-borne disease of animals (Yadav, Sharma and Kuntal, 2019). Babesiosis affects cattle, horses, sheep, goats, pigs, dogs, wild animals and occasionally man. The infection is mainly transmitted by ticks of *Boophilus* species and cattle are the principal hosts of the disease. *Bos indicus* breeds of cattle are more resistance to Babesiosis than *Bos Taurus*. This is a result of evolutionary relationship between *Bos indicus* cattle, *Boophilus* species and *Babesia*. According to age older animals are more susceptible than young animals the possible reason is passive transfer of maternal antibody via colostrum. The disease is prevalent throughout most tropical and subtropical regions which includes North and South America, Southern Europe, Africa, Asia, and Australia. Babesiosis is the greatest incidence occurring soon after the peak of the tick population (Nejash, 2016).

B. bovis, *B. bigemina* and *B. divergens* are the most prevalent babesia species but *B. major*, *B. ovata*, *B. oculatus* and *B. jakimovi* are also prevalent in cattle. *Babesia* is found intracellularly inside RBC almost always singly or as pairs. The morphology of the parasite is typically pyriform but can be rod shaped, elongated round, tetrad, and cigar shaped organism often arranged at characteristic angle with their narrow ends opposed (Bock *et al.*, 2004; Menegesha, 2020).

The life cycle of *Babesia* has 3 phases the first one is conjugation of gametocytes occurs in the tick gut followed by multiplication by multiple fission and migration to various tissues including the salivary glands, second sporogony asexual reproduction in salivary glands and third merogony—aseexual reproduction in the vertebrate host. When Cattle are infected by feeding ticks, they get sporozoites that invade erythrocytes and then sporozoites transfer to feeding stage called trophozoites by merogony reproduction. Then the RBC membrane will break and merozoites invade other new cells. After that when tick feed on the host they take merozoites which develop to gametocytes in the tick gut. Gametocytes develop zygotes. Then zygote undergo different changes and when they reaches to kinetes stage they go to different organs of the tick including ovary which is a means of trans ovarian transmission and salivary gland finally the cycle go through the same process as the kinetes change to sporont then

sporozoites. All the known vectors of this cycle are ixodid or hard ticks (Homer *et al.*, 2000; SIMUUNZA, 2009; Gray *et al.*, 2010).

In bovine the principal pathogenic effects of this parasite are intravascular hemolysis when the infective stage of the parasite called sporozoites enters in to systemic circulation, the vasodilatation accompanied by increased vascular permeability which leads to circulatory stasis and shock, intravascular coagulation and subsequent fatal pulmonary thrombosis (o. M. Radostits, 2010).

The clinical signs of babesia vary depending on with the age and species of the animal and strain of the parasite. Farmers often detect bloody urine as a first protuberant clinical sign. Initially affected animals are febrile for several days before the onset of other clinical signs. Other clinical signs in affected cattle are weight loss, anorexia, pale mucous membrane, labored breathing, cessation of rumination, accelerated heart and respiratory rates and drop in milk production. Furthermore, the sick cattle may isolate itself from the rest of the herd; become depressed, appear weak and reluctant to move (Hussein, Mohammed and Mohammed, 2007; Matheus, 2017).

The economic importance of this disease is high because the disease itself has effects such as loss of production and draft power, ill-thrift, abortions, even mortality and cost to take control measures. The other effect, as it is a tick borne disease the tick itself has many effects on the affected host such as the direct effect of attachment and feeding, the injection of toxins, hide damage due to their bites, a reduction in weight gain due to the sucking of blood it is a tick borne disease which means that (Bock *et al.*, 2004; Jabbar *et al.*, 2015).

Control of bovine babesiosis can be done whether by tick management, immunization, anti-babesia drugs or in combination of these approaches. Chemotherapy of babesiosis is important for controlling the disease. The success of the treatment depends on early intervention and the rational administration drugs. Different antiprotozoal drugs like amicarbalide, imidocarb dipropionate, quinuronium sulfate and diminazene aceturate are used for babesiosis treatment and diminazene is widely used in the tropics as a babesiacide (Olvera-ramírez, Mosqueda and Cantó, 2012). There are many acaricides to remove tick infestation like natural and synthetic pyrethrins and avermectin (Menegesha, 2020).

Therefore the objective of this case paper is to show the diagnostic approach towards bovine babesiosis and putting its effective treatment option.

Case description

History and physical examination

Cattle from Dalota and Gute peasant associations visit Veterinary Teaching Hospital (VTH), Bishoftu in the history of bloody urine in March 2021. The first one was female and gives birth 1 month ago. As the owner complain that bull mount on her few days before the day of examination and the bloody urine were started after that specific moment in a reason of mechanical injury on the due time the cow was unable to feed on the given feeds properly and the body become decreased gradually. The cow is extensive grazer and no medication history was found. Up on physical examination the cow was found very emaciated, the mucous membrane was pale to yellowish in color, the urine had blood, temperature was 38.5 °c, but prescapular and prefemoral lymphnodes were found normal.

The second patient with bloody urine was a bull. As the owner complain that the bull started to have bloody urine 3 days before examination day and also the bull was decreased in feeding. The bull was extensive feeder and has no medication history been found. Upon physical examination the bull body condition was good actually but pale mucous membrane, ticks around tail and scrotal areas, dark urine were found, temperature was found normal (39⁰c), increased respiratory rate (26 breaths/min), normal heart rate (56 beat/min) and the palpated lymph nodes were found normal.

Differential diagnosis of babesiosis

Based on history and clinical signs enzootic hematuria, enzootic bovine pyelonephritis, Babesiosis, tropical theileriosis, post parturient hemoglobinuria, leptospirosis and Chronic copper poisoning were the tentative diagnosis.



Figure 34: Babesia affected cattle during urination: (A); Bloody urine in cow and (B); Bloody urine in bull



Figure 35: Additional clinical signs of cattle affected by Babesiosis (A) pale to yellowish eye mucus membrane, (B) pale eye mucus membrane of bull (C) Tick on scrotal area of bull

Case diagnosis and laboratory findings

As the cow has parturition and bull mounting history the first diagnosis was gynecological diagnosis. The cow reproductive system was inspected by light guided vaginal speculum. During the examination no fluid that oozing from uterus was found. The uterus was evolved and was ready for the next cycle. This made to remove reproductive problem from tentative diagnosis lists. Then after that the bloody urine was directly centrifuge and there was no sedimentation of the intact blood cells. This indicates the presence of hemoglobinuria, which makes the previous diagnosis stronger and differentiate from the bloody urine caused by hematuria (enzootic hematuria and enzootic bovine pyelonephritis). This was also true for the case in bull. Side by side the packed cell volume (PCV) was checked in both cases and lower values (15% and 18%) were recorded. In order to check the presence of haemoprotozoan a thin blood smear was prepared, air dried, fixed with methanol and stained with Giemsa stain (1:10 ratio) for 35 minutes and then washing with tap water. The stained smear was examined under oil immersion lens (100X). The result indicates the presence of babesia blood parasite.


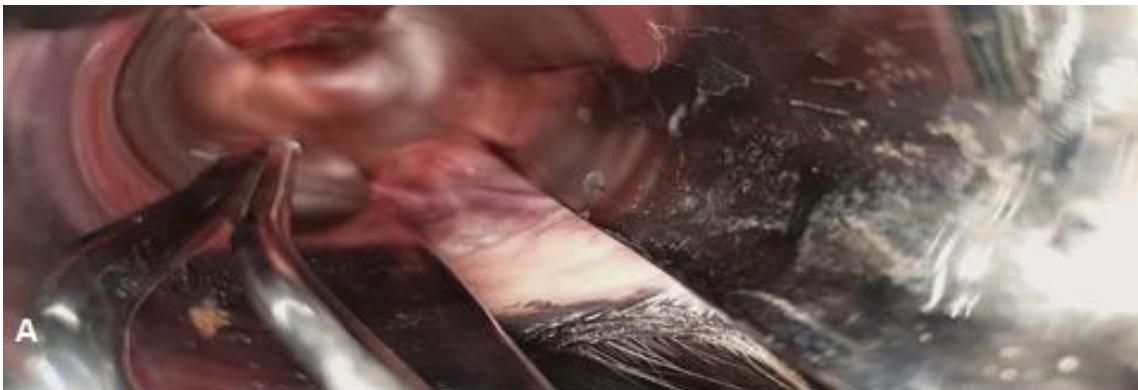


Figure 36: Laboratory and clinical examinations against bloody urine (A) intra-vaginal diagnosis with no fluid (B) bloody urine after centrifuge (C) Lower PCV value

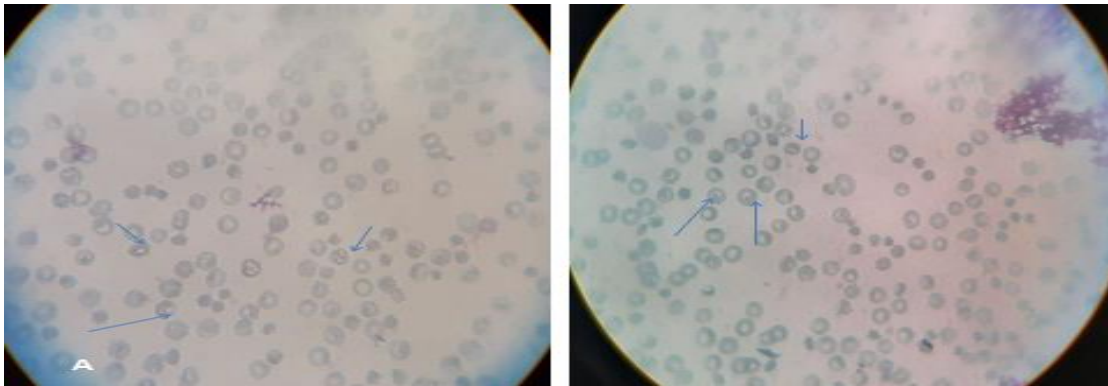


Figure 37: Giemsa stain in babesiosis affected cattle: Stained smear showing piroplasm of *Babesia* species within the affected erythrocytes

Treatment and the outcome

In the first case (in cow) oxytetracycline 10% (Hebei Kexing pharmaceutical Co.Ltd) 0.2ml/10kg/day, IM was given for two days but the cow was not respond. On the third day diminazene aceturate (Alivira animal health limited), 1ml/ 20kg, stat, multi-vitamin (Aether center, Beijing, biology co.,Ltd) stat 7ml/ head and Ivermectin, 1ml/50kg, stat were given. Then the cow responded and the urine become clear, the appetite was back but the body condition takes time to return to normal condition. The bull was treated with the same treatment starting from day one of diagnosis then in phone communication of the next days the owner told me about the good response and the bloody urine was completely removed. Then after 2 weeks I can see the good condition of the bull in its environment.



Figure 38: Good response of babesiosis affected cattle (A); Cow urinating after healing and (B); Bull urinating after healing

Discussion

The typical clinical sign of this disease is the presence of bloody urine. This clinical sign can be caused by different diseases that have listed in the differential diagnosis part. Therefore the first measure that has been taken was to centrifuge the urine to differentiate between hematuria and hemoglobinuria this is agree with the study of Hill. As this work Hemoglobinuria is the presence of hemoglobin in the urine in which after urine centrifuge the urine will not be clear because RBC is lysed whereas hematuria is the presence of intact blood cell in the urine due to hemorrhage then transparent urine that remains pigmented after centrifugation will found. Then the result of both cases was unclear urine after centrifuge and pink to red blood plasma (Hemoglobinuria) which caused by diseases like babesiosis, tropical theileriosis, postparturient hemoglobinuria , bacillary hemoglobinuria, leptospirosis and chronic copper deficiency (HILL, 2012; CONSTABLE, 2017).

Clinical signs that were found in addition to hemoglobinuria were emaciation, pale to yellowish mucous membrane, presence of tick, temperature was found 38.5⁰c and 39⁰c and

increased respiratory rate. This result agrees with the case reports of Ukwueze and Faez (S. Ukwueze and F. Orajaka, 2014; Faez Firdaus Jesse Abdullah, Lawan Adamu, 2016).

In these cases after urine centrifuge packed cell volume (PCV) was evaluated and lower PCV value was found which is true in the case of babesiosis. Then the simple first step was Geimsa to detect blood parasites and staining revealed the presence of piroplasmic organisms of *Babesia* in RBC. The procedure and the result of the test were same with the work of Kumar and Kala and Yadav, Sharma and Kuntal (Kumar and Kala, 2018; Yadav, Sharma and Kuntal, 2019).

Both cases were treated by Diminazene Aceturate injection against the babesia and Ivermectin in order to remove ticks found on the skin of the cattle. Multivitamin was also given in order to increase feed intake and weight gain, to boost the immune system and to increase RBC formation. These drugs are also used in the case of babesia by the work of Ukwueze (S. Ukwueze and F. Orajaka, 2014). The use of multivitamins in cattle also supported by the work of Gadberry (Gadberry, 2008).

Conclusion

Bloody urine is a little common clinical sign in both male and female cattle and in this case report the cause of this bloody urine was found as blood parasite called babesia and if appropriate treatment is given for this case healing take place in days.

Acknowledgement

I would like to thank Dr. Abdi Feyessa and Dr. Mehari Teklu for their support during case handling.

References

Bock, R. *et al.* (2004) 'Babesiosis of cattle', *Parasitology*, **129**, pp. 247–269.

CONSTABLE, P. D. and KENNETH W. HINCHCLIFF STANLEY H. DONE WALTER GRÜNBERG (2017) *VETERINARY MEDICINE 11th edition*.

- Faez Firdaus Jesse Abdullah, Lawan Adamu, A. Y. O. and A. W. H. and A. A. S. (2016) 'Clinical Management of Babesiosis in Cattle: A Case Report', *Research Journal for Veterinary Practitioners*, **4**(2), pp. 30–33.
- Gadberry, S. (2008) 'Mineral and Vitamin Supplementation of Beef Cows in Arkansas', *Agriculture and Natural Resources*, pp. 1–6.
- Gray, J. *et al.* (2010) '.', *Ticks and tick-borne diseases*. Netherlands, **1**(1), pp. 3–10. doi: 10.1016/j.ttbdis.2009.11.003.
- HILL, S. A. (2012) 'Hemoglobinuria', in Wilson, D. A. (ed.) *Clinical Veterinary Advisor*. Saint Louis: W.B. Saunders, pp. 938–939.
- Homer, M. J. *et al.* (2000) 'Babesiosis', *Clinical Microbiology Reviews*, **13**(3), pp. 451–469. doi: 10.1128/CMR.13.3.451-469.2000.
- Hussein, A. H., Mohammed, N. A.-E.-S. and Mohammed, H. K. (2007) 'THEILERIOSIS AND BABESIOSIS IN CATTLE: HAEMOGRAM AND SOME BIOCHEMICAL PARAMETERS', *ISAH*, pp. 143–150.
- Jabbar, A. *et al.* (2015) 'Tick-borne diseases of bovines in Pakistan: Major scope for future research and improved control', *Parasites and Vectors*, **8**(1), pp. 1–13.
- Jabir Yusuf, J. (2017) 'Review on Bovine Babesiosis and its Economical Importance', *Journal of Veterinary Medicine and Research*, **4**(5), p. 1090.
- Kumar, R. and Kala, S. (2018) 'Babesiosis in Calf: A Case Report', *International Journal of Current Microbiology and Applied Sciences*, **7**(07), pp. 3951–3954.
- Matheus, E. K. (2017) *PREVALENCE OF BABESIOSIS IN SANGA CATTLE IN THE OHANGWENA REGION OF NAMIBIA* by University of South Africa Supervisor : Mr J . Oosthuizen Co-supervisor : Dr James , W . Oguttu Master of Science in Agriculture.
- Menegsha, A. (2020) 'A Review on Bovine Babesiosis', *J Vet Med Animal Sci*, **3**(1), pp. 1–6.
- Nejash, A. A. (2016) 'Bovine Babesiosis and Its Current Status in Ethiopia: A Review',

Journal of Medicine, Physiology and Biophysics, **23**(2), pp. 15–23.

- o. M. Radostits (2010) *VETERINARY MEDICINE A textbook of the diseases of cattle, horses, sheep, pigs and goats*. 10th edn. Edited by o. M. R. C. C. G. K. W. H. P. D. Constable.
- Olvera-ramírez, A. M., Mosqueda, J. and Cantó, G. J. (2012) ‘Current Advances in Detection and Treatment of Babesiosis Current Advances in Detection and Treatment of Babesiosis’, (May 2014).
- S. Ukwueze, C. and F. Orajaka, C. (2014) ‘Babesiosis in a Calf: A Case Report’, *IOSR Journal of Agriculture and Veterinary Science*, **7**(11), pp. 72–74. doi: 10.9790/2380-071127274.
- SIMUUNZA, M. (2009) *DIFFERENTIAL DIAGNOSIS OF TICK-BORNE DISEASES AND POPULATION GENETIC ANALYSIS University of Glasgow*.
- Yadav, H. S., Sharma, S. K. and Kuntal, N. S. (2019) ‘A study on babesiosis in HF cattle’, **7**(3), pp. 624–626.

5.3.2 Flea allergy dermatitis in a dog

Abstract

Fleas are the common ectoparasites in dogs responsible for irritation by their presence or as a vector to transmit disease. Flea allergy dermatitis is a condition caused by the irritating chemical in saliva of these ectoparasites in the skin of the dogs. On March 22/2021 a dog owner visit veterinary teaching hospital in the request of medication for his diseased dog at home. In the history it was indicated that the dog has irritation on its body, it was restless and the skin was sloughed. Up on physical examination crusty lesion, alopecia and fleas which hide under hairy part were seen in caudodorsal lumbosacral area and dorsal tail head. And the fleas were also confirmed as *Ctenocephalides felis* under stereomicroscope. Therefore based on the history, clinical signs and laboratory confirmation the case was confirmed as flea allergy dermatitis and treated by hydrocortisone sodium succinate 5 mg/kg IM, and Ivermectin 0.5ml/25kg in SC route, stat. Then the dog had progressive healing and within one month the hair grown in bared parts. Therefore flea allergy dermatitis can be successfully treated by Ivermectin and hydrocortison.

Key Words: Dog, *Ctenocephalides felis*, *Flea allergy dermatitis*, *hydrocortisone sodium succinate* and *Ivermectin*

Introduction

There are different highly significance Arthropod ectoparasites in pet animals. Their effect is either their direct presence or as a vector for disease transmission. Among them, fleas have been known for a long period of time by infesting man and animals. The common fleas specious in dogs are: *Ctenocephalides canis*, *Ctenocephalides felis*, *Pulex irritans* and *chidnophaga allinacea*. These parasites are generally associated to dermatitis, it can cause immunological disorders and in extreme cases the parasites can lead to death (Chanie, 2014).

The life cycle flea passes four stages in each stage a complete metamorphosis has occurred. The adult parasite spends most of the time live on the body cats and dogs. The eggs will hatch into larvae; larvae evolve into pupae (cocoons) that emerge later as adult fleas. For one adult flea found on dogs there are at least one hundred immature fleas in the animal's environment.

The life cycle can be completed in as little as 12 days or take as long as 174 days and is dependent upon the ambient temperature and humidity (Souza, 1997; Ettinger, 2005).

Flea allergy dermatitis or flea-bite hypersensitivity in small animals is the most common dermatologic condition. In some regions of the world, it is the most commonly seen canine disease. Despite the availability of effective modern anti-flea chemotherapeutic products, flea infestation and FAD are still challenges (Lam and Yu, 2009; Elsheikha, 2012).

Flea allergy dermatitis (FAD) in dogs and cats is a progressive form of skin hypersensitivity caused by exposure to flea saliva, which contains a variety of histamine-like compounds, enzymes, polypeptides, and amino acids, through flea bites. Research evidence suggests that both host- and flea associated factors play a crucial role in the pathophysiology of FAD. The most affected parts of the body are caudodorsal lumbosacral area, dorsal tail head, caudomedial thighs, abdomen and flanks. The type of lesions includes pruritic, papular, crusting eruptions with secondary erythema, seborrhea, alopecia, excoriations, pyoderma, hyperpigmentation, and lichenification. FAD has delayed type of hypersensitivity (Elsheikha, 2012; Park, 2012; Iannino *et al.*, 2017).

Diagnosis of flea allergy dermatitis is based on clinical signs and the presence of flea on the skin. As the presence of different skin diseases in dogs it may difficult to say flea allergy dermatitis when there is no flea in the skin. Differentials include other ectoparasites (scabies, cheyletiellosis, pediculosis, demodicosis), atopy, food hypersensitivity, superficial pyoderma, dermatophytosis, demodicosis, and *Malassezia* dermatitis. The successful resolution of the flea allergic in dogs is a continual removal of flea from the dog. Corticosteroids, “cortisone” or “steroids” are also widely used to treat FAD (Ettinger, 2005; Park, 2012).

Therefore the objective of this case report is to show the diagnosis approach and treatment option towards FAD.

Case description

On March 22/ 2021 the dog owner came to veterinary teaching hospital at Bishoftu to get a veterinary help for his diseased dog. As he complained his dog started itching, skin sloughing

and being uncomfortable and restless days before examination day. The dog had aggressive character therefore the owner was not able to brought it to VTH, so I went to his home. The dog serves the owner by safeguarding with another dog but the disease condition was seen only in this dog. Up on physical examination crusty lesion which distributed caudodorsal lumbosacral area and dorsal tail head (Figure 39B) were found. There were also alopecia and a lot of fleas hide under the hairy part. Based on the history and clinical findings the case was suspected as flea allergy dermatitis. To have further certainty the fleas found in the skin were identified through stereomicroscope and the presence of brownish color, elongated head rather than rounded called *Ctenocephalides felis* was confirmed.



Figure 39: FAD affected dog (A); The diseased dog during physical examination (B); Alopecia and crusty lesion visible on dog's Posterior part and (C); *Ctenocephalides felis* under stereomicroscope

Differential diagnosis of FAD

Dermatophytosis, other ectoparasite infestation like lice, immunosuppressive diseases with/without complication.

Treatment outcome

The treatment of this dog was aimed to remove the causative agent of the disease as well as to reduce pain and discomfort. Therefore 1% ivermectin (Hebei Huarun pharmacy Co.,Ltd.China) 0.5ml/25kg in SC route, stat was administered and hydrocortisone sodium succinate (Neon laboratories limiter, India) 5 mg/kg IM, stat were administered. Then during phone follow up the owner was able to know and tell dog's good progressive change. First the discomfort was removed then the hair was grown up gradually. After 1 month when the dog was inspected, hair was grown on the previous affected areas (lower back area and the tail) as shown in the figure below.



Figure 40: The progress of the FAD affected dog after 1 month

Discussion

Based on the clinical signs, the confirmation of the presence of flea on the body of the dog and treatment response the case was confirmed as flea allergy dermatitis. Crusty lesions were found in caudodorsal lumbosacral area and dorsal tail head. As the study of Elsheikha

indicates most affected parts of the FAD affected body parts are caudodorsal lumbosacral area, dorsal tail head, caudomedial thighs, abdomen and flanks (Elsheikha, 2012). The crusty types of lesion, having alopecia and flea on the affected parts were the typical clinical figures in the dog's body. This is supported by the review of Iannino (Iannino *et al.*, 2017).

The main causative agent of this disease was flea both by their direct presence as well the allergy due to the flea's saliva. Therefore to remove the flea ivermectin was used. In dogs, ivermectin is approved for the ectoparasiticide purpose. To response for the allergic reaction Hydrocortisone sodium succinate was used. This drug has both metabolic and anti-inflammatory actions. It is also effective in different types of allergens (Upjohn, 2010).

The treatment of dogs are so usefule for prevent of zoonotic transmtion of flea and flea borne disease because according to the study of Moriello the most common dermatological zoonosis are flea and tick infestations and the diseases they transmit (Moriello, 2003; Eisen and Gage, 2012).

Conclusion

Flea allergy dermatitis is an ectoparasite causing disorder and it can be successfully treated by anti- parasites called Ivermectin and anti-inflammatory agent called hydrocortisone.

References

- Chanie, A. T. and M. (2014) 'Ectoparasites are Major Skin Diseases of Dogs in Gondar , Amhara National Ectoparasites are Major Skin Diseases of Dogs in Gondar , Amhara National', *Int. J. Anim. Veter. Adv.*, **3**(5), pp. 392–396.
- Eisen, R. J. and Gage, K. L. (2012) 'Transmission of Flea-Borne Zoonotic Agents *', *annu.Rev.Entomol*, **57**, pp. 61–82.
- Elsheikha, H. M. (2012) *Flea allergy dermatitis: the continued challenge.*,1.
- Ettinger, F. and (2005) 'Fleas and Flea Allergy Dermatitis', in *Textbook of Veterinary Internal Medicine*, pp. 1–5.
- Iannino, F. *et al.* (2017) 'Pulci di cane e gatto: Specie, biologia e malattie ad esse associate',

Veterinaria Italiana, **53**(4), pp. 277–288.

Lam, A. and Yu, A. (2009) ‘Overview of flea allergy dermatitis.’, *Compendium (Yardley, PA)*. United States, **31**(5), pp. E1-10.

Moriello, K. A. (2003) ‘Zoonotic skin diseases of dogs and cats.’, *Animal health research reviews*. England, **4**(2), pp. 157–168.

Park, E. (2012) ‘FLEA ALLERGY DERMATITIS’, *Lifelearn Inc.*, p. 1.

Souza, C. (1997) ‘Fleas, flea allergy, and flea control: a review’, *Dermatology*, **3**(2), pp. 1–7.

Upjohn, P. & (2010) *SOLU-CORTEF® (hydrocortisone sodium succinate for injection, USP)*
For Intravenous or Intramuscular Administration DESCRIPTION.

5.3.3 Otitis in a rabbit

Abstract

Nowadays rabbits are raised as a pet by many peoples. Rabbits are affected by infectious and non-infectious diseases and otitis due to ear mite called *Psoroptes cuniculi* is one of the common diseases found in rabbits. The rabbit owner visit veterinary teaching hospital, Bishoftu in a case of ear wound on her bunny. On the clinical examination local clinical findings like a brownish exudate and encrustation from left side ear, tilted head to the affected side of ear and etching was inspected but parameters were found normal. On the laboratory examination of ear swab *Psoroptes cuniculi* were identified. To treat this case Ivermectin 0.2mg/kg was administered subcutaneously, two times at one week interval and local drops of mineral oil as a home therapy was also administered. After the treatment the affected ear was become healed with no exudate and encrustation in the ear and the rabbit was found in a good health status. Therefore otitis in rabbit can be caused by mites and treating this infection by Ivermectin and wetting the area by mineral oil can heal the rabbit within a short period of time.

Key words: *Ivermectin, Otitis, Psoroptes cuniculi and Rabbit*

Introduction

Rabbits are nowadays known by their companionship and as they are docile, clean, soft feathered, less noise and low cost of feed they become preferable as an excellent pets (Martino and Luzi 2008; Ramadiani et al. 2018). Beside their accompanies as pet animals rabbits are used as a good source of meat in many countries because their meat is reached in high protein and low fat as well as cholesterol. These animals inhabited a wide range of environment and found all over the world except Australia and Antarctica (Almeria et al. 2021; Mam et al. 2019).

Rabbits like other pet animals affected by different infectious and non-infectious diseases which can cause various health and economic problems. From infectious diseases

pasturellosis, Myxomatosis, Viral hemorrhagic disease, pneumonia, ear mite infestation, cheyletiella mange, are the most common ones and from non-infectious diseases malocclusion, hairball, soar hocks and heat stress are the most common one (Mohammed, M, and MM 2014; N.M. Patton, K.W. Hagen, J.R. Gorham and Domestication 2008; Smith et al. 2009).

Rabbits can be affected by different ectoparasites including fleas, lice, mites and ticks. From these ectoparasites, mites are the most economically significant and have a great welfare issue in rabbit farming. The most common rabbit mange mites are *Psoroptes cuniculi* and *Cheyletiella parasitivorax*. Mange mites are highly contagious by means of direct transmission from infected to healthy rabbits or indirectly through fomites. The presence of the Psoroptic mange in the ear cause brown and waxy exudate, intense pruritus, encrustation (consists of cellular debris, mites, dried blood and keratin), head shaking, pain on ear palpation, foul smelling and ear dropping in extreme cases. High infestation of ear mite can contain around 10,000 mites and the infestation can goes to inner surface of pinna and area out of the ear like head, neck, and even the chin and shoulders. Related problems can reach up to weight loss, reproduction failure and become exposed to secondary bacterial complications (Chebet et al. 2018; N.M. Patton, K.W. Hagen, J.R. Gorham and Domestication 2008).

Treatment of mange mites in rabbits includes both chemotherapeutic as non-chemotherapeutic drugs. The chemoterapic drug includes avermectins groups like Ivermectin, selamectin, doramectin topical permethrin, carbamates, benzyl benzoate, and sulphur-based compounds. Beside these chemotrophic drugs, Oil-based ear mite treatments are effective against ear mites. The oil act by making direct contact with the mites and also by blocking the opening to tunnels within the stratum corneum through which the buried mites breathe, thereby suffocating the parasites (Ogolla et al. 2019).

Therefore the objective of this case report is to show the effect of otitis due to mite infection and putting the effective treatment option.

Case description

On June 3/2021 a rabbit owner brought her bunny in case of ear wound. The rabbit was a gift of the owner with unknown age but stayed around two years with the owner. It was adopted as a pet animal and lives alone with no other pets. As the chief complaint was an ear wound which started three weeks before the day of presentation to VTH, the owner tries to treat it in her home with olive oils but no progress was seen. As the living environment was not suitable for the bunny, the owner tries to create a good environment by buying grass from the market. On the clinical examination a brownish exudate and encrustation was visible in the left side ear, (Figure 41B) head was tilted to the affected side and the rabbit touched the affected ear by its hind limb. The parameters were found normal in which temperature (38.6°C), normal rhythm of both heart and respiratory rate but the beat was faster to count. The palpated lymph nodes were found normal. Therefore based on the history, clinical finding and epidemiology a tentative diagnosis was made as otitis externa due to ear mite with a differential diagnosis of otitis due to bacterial infection.

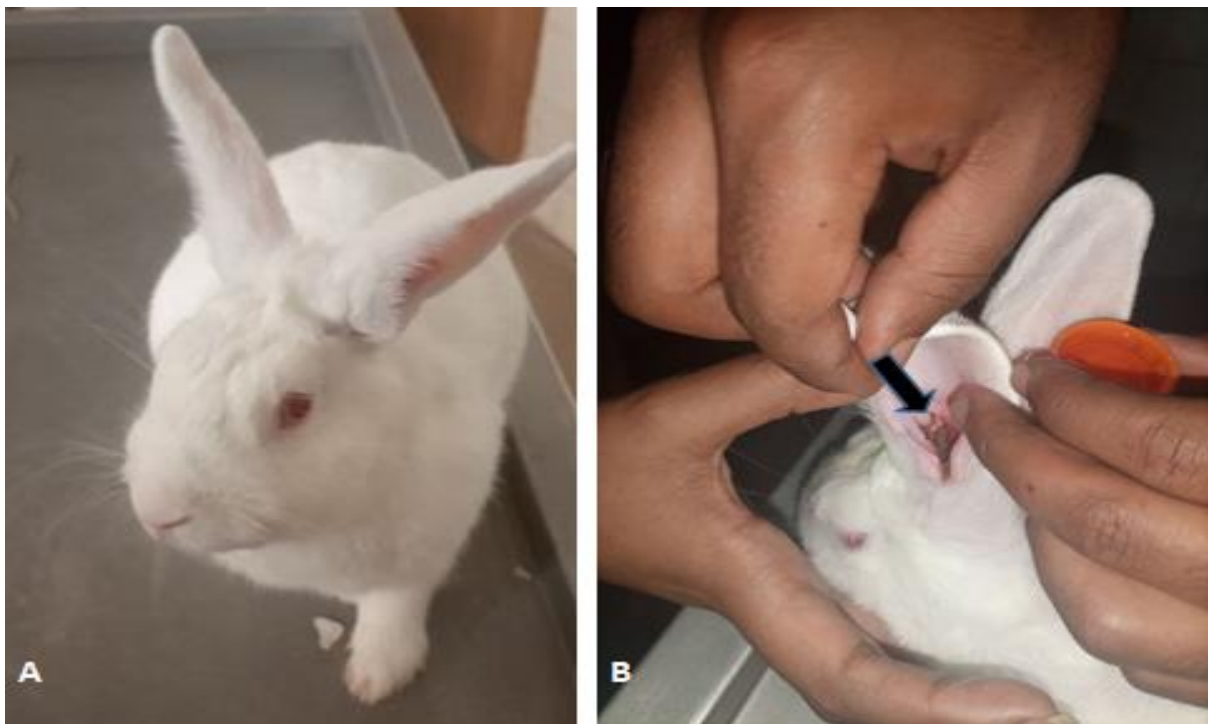

Figure 41: Rabbit with otitis (A); The diseased rabbit during inspection in VTH and (B); The left ear with crusty lesions on the external ear canal indicated by the arrow

Differential diagnosis

Parasites, Bacteria like *Pasteurella multocida*, Fungi, Autoimmune allergies, Foreign bodies and Drugs.

Laboratory investigation and findings

To confirm the causative agent of ear infection an ear exudate was taken by gentle rotating of sterile swab in the ear. Then drops of KOH and the swab sample mixed together and examined under 10x magnifying microscope. The microscopic examination indicated large, oval shaped structure and on the first two pair of legs short segmented stalks with a single bell-shaped structure was found. These were characteristics of *Psoroptes cuniculi* mange mite (Figure 42) and additionally mite movements were clearly identified. Therefore this case was confirmed as otitis due to *Psoroptes cuniculi*.

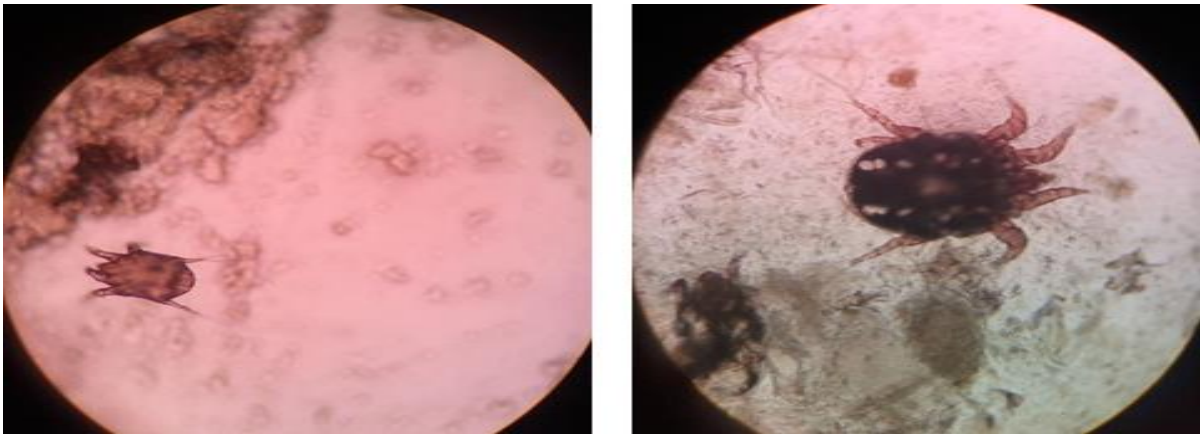


Figure 42: The ear mite or *Psoroptes cuniculi* under 10x magnification

Case management and follow up

As an ear mite was confirmed in the rabbit Ivermectin 0.2mg/kg (Hebei Huarun pharmacy Co.,Ltd.China) was administered subcutaneously, 2 times with one week interval and told the owner to use a droplet of baby oil to the ear. Then after one week the owner visit VTH again

based on the given appointment and it reveals the good progress of the rabbit health and the ear was free from wound, discharge and even scar (Figure 43).



Figure 43: The normal left ear of rabbit after the treatment

Discussion

Based on the history and clinical findings the case was confirmed as otitis externa due to *Psoroptes cuniculi*. As the study of Eatwell indicates clinical signs of otitis externa include scratching of the ear, head shaking, pain, lethargy and thick exudate from the ear with yellowish to brown coloration and again as this study the common causative agent for otitis externa is *Psoroptes cuniculi* but bacteria and dermatopathies are uncommon as a causative of this type of otitis. Therefore both the clinical signs and the causative agent of this disease of this case is in line with this work Eatwell (Eatwell 2013). As the study of Bourdeau PJ *Psoroptes cuniculi* is not a borrowing mite rather the existence of mucus and feces of the parasite results hypersensitivity of the area and it leads to an inflammation and crusty exudate which also seen in this bunny (Mancinelli and Lennox 2017).

This rabbit was raised as a pet animal and as it was suspected the source of ear mite might be associated with the purchased grass because as the study of Ayodhya ear mite in rabbits are associated with unclean environment other environmental conditions as the saying of this

study the ear mite is a common case for both pet and commercial rabbits which is true in this specific case (Ayodhya 2013).

The treatment protocol used in this ear mite infected rabbit was agreed with the protocol mentioned in the book of Patton *et.al* this protocol put Ivermectin injection and locally used mineral oil to treat the otitis due to ear mite (N.M. Patton, 2008).

Conclusion

Otitis in rabbit is a common disease condition and the common cause of this disorder is *Psoroptes cuniculi* therefore giving treatments like Ivermectin and wetting the area by mineral oil can heal the affected rabbit.

References

- Almeria, Sonia, Fernando H. A. Murata, Camila K. Cerqueira-Cézar, Oliver C. H. Kwok, Alicia Shipley, and Jitender P. Dubey. 2021. "Epidemiological and Public Health Significance of Toxoplasma Gondii Infection in Wild Rabbits and Hares: 2010–2020." *Microorganisms* **9**(3):1–12.
- Ayodhya, S. 2013. "Ear Canker and Its Clinical Management in Rabbits." *Int.J.Curr.Microbiol.App.Sci* **2**(11):66–71.
- Chebet, J., R. M. Waruiru, K. O. Ogola, P. K. Gathumbi, P. O. Okumu, M. Wanyoike, and G. O. Aboge. 2018. "Prevalence, Control and Risk Factors Associated with Rabbit Mange in Kiambu and Nyeri Counties, Kenya." *Livestock Research for Rural Development* **30**(6),1-8.
- Eatwell, Kevin. 2013. "Diagnosis of Otitis Externa, Media and Interna in Rabbits." *Vet Times* 1–17.
- Mam, Alaa Eldin, Darwish Ws, El-sayed Seis, and Ali Elsm. 2019. "Journal of Veterinary Science & Rabbit Meat as a Possible Source for Multidrug Resistant Listeria Monocytogenes." *J Vet Sci Technol*, **10**(3), 2-6.
- Mancinelli, Elisabetta, and Angela M. Lennox. 2017. "Management of Otitis in Rabbits." *Journal of Exotic Pet Medicine* **26**(1):63–73.

- Martino, P. A., and F. Luzi. 2008. "Bacterial Infections in Rabbit As Companion Animal : A Survey of Diagnostic Samples in Italy." *Pathology and Hygiene*, 9th World Rabbit Congress, 1013–18.
- Mohammed, Hamed A., Eid AA M, and El-Bakrey R. MM. 2014. "A Review of Rabbit Diseases in Egypt." *Indonesian Bulletin of Animal and Veterinary Sciences* **23**(4):185–94.
- N.M. Patton, K.W. Hagen, J.R. Gorham, and R. E. Flatt, and Domestication. 2008. "Domestic Rabbits Diseases and Parasites." *A Pacific Northwest Extension Publication*,1-31.
- Ogolla, Kennedy O., Joyce Chebet, Robert M. Waruiru, Peter K. Gathumbi, Paul O. Okumu, and Gabriel O. Aboge. 2019. "Efficacy of Ivermectin, Liquid Paraffin, and Carbaryl against Mange of Farmed Rabbits in Central Kenya." *Journal of Tropical Medicine* **2019**, 1-8.
- Ramadiani, Dyna Marissa, Muhammad Labib Jundillah, Azainil, and Heliza Rahmania Hatta. 2018. "Simple Additive Weighting to Diagnose Rabbit Disease." *E3S Web of Conferences* **31**:1–7.
- Smith, Martin H., Cheryl L. Meehan, Justine M. Ma, Nao Hisakawa, H. Steve Dasher, Joe D. Camarillo, and Jennifer Techanun. 2009. "Rabbit Disease: What You Need to Know." *Rabbits: From the Animal's Point of View*, 4, 1-48

5.4 Disease Caused By Fungal Agent

5.4.1 *Dermatophytosis in puppy*

Abstract

Dermatophytosis is a common, contagious and serious fungal infection with a zoonotic importance. A white coted female puppy was examined in veterinary teaching hospital with alopecia and erythema in head, neck, fore limb and hind limb. On the history the owner indicates the onset of the case as above three months before the examination date, itching of the affected area and the presence of poor management, but the animal was active and no appetite loss was found. The first tentative diagnosis was made as allergy due to skin color and ectoparasites because of the epidemiology, management problem and white skin color therefore, Ivermectin and dexamethasone treatments were given but the case got aggravated. Therefore treatment was changed to antifungal drugs due to response to the previous treatment, the anatomical location and clinical signs of the affected. Hence ketoconazole oral tablet and ointment were given. Then the puppy was recovered and its hair was fully grown in a month time. Therefore dermatophytosis is prevalent disease in dogs and treating the disease with oral and topical ketoconazole can heal such disease.

Key Word: *Dermatophytosis, ketoconazole and puppy*

Introduction

Cutaneous disease is one of the most common diseases in developing countries but it hasn't got much concern as its importance. Skin disease in animals can be caused by different causes include bacterial, fungal, parasitic, inflammation and trauma. Dermatophytosis is one of skin diseases which represent a common and serious contagious cutaneous infection of dogs and cats. Its significance is not limited in the animal only but it have a significant zoonotic importance (WHO, 2005; Boehm and Mueller, 2019).

Dermatophytosis is a fungal infection of keratinized skin structures which is a superficial. The disease is caused by fungi in the genera of *Microsporum*, *Trichophyton* and *Epidermophyton*. The first two genera are known by causing disease in both humans and animal. Dermatophytosis has a worldwide distribution and it is the most frequent fungal disease that

affects both man and animals. This disease affects many species of animals including cattle, dogs, cats, horses, rabbits and wild animals. The disease is transmitted from infected to susceptible by contact with the spores. Dermatophyte spores carried by companion animals can be changed to infection in certain predisposing factors like immunosuppression, nutritional deficiency, young age, skin trauma and high environmental temperature and humidity (Moretti *et al.*, 2013; Rovid, 2013; Debnath *et al.*, 2016).

Dermatophytes enter to the body by traumatized hole. This pathogen invades the keratinized layer of the skin namely the stratum corneum and they release keratinase and induces inflammation. There are also fungal enzymes and proteins which helps the fungi to adopt the new environment. After inflammation has occurred in one area then they transfer to other areas and the healing left classical lesion with a ring shape in the affected area (Lakshmiathy and Kannabiran, 2010; Martinez-Rossi, Peres and Rossi, 2017). The most common dermatophytosis clinical signs are alopecia, erythema, pruritus and crust. There may be also papule, scales and the alopecia can be multifocal. This infection most of the time create infection in the head, leg and/or tail areas (Paryuni, Indarjulianto and Widyarini, 2020).

Dermatophyte infections can be treated in diverse topical and oral antifungal drugs. In immunocompetent patient topical antifungal application is enough but in severe cases oral antifungals are selected. This is one prevention way of the disease and additionally cleaning fomites that are in contact with the affected animal is the other prevention of disease transmission and zoonotic importance (Rovid, 2013).

Case Description

On May 21/2021 an owner brought his 10 month female puppy to veterinary teaching hospital (VTH), Bishoftu in a problem that affect skin. The puppy was from rural area around Bishoftu and the area was not safe area to properly handle dogs and the case stays more than three months on the puppy's body. In that span the owner tries to treat the puppy by homemade therapy but no progress was found. As the explanation of the owner the case was started around the neck and affected its head and it has an itching but the puppy was active and no appetite change was found. On the physical examination of the puppy was white in color, has alopecia and erythema (Figure 44) in the head was covered its half part and also affected the

neck, forelimb and hind limbs but the animal was found active. Therefore based on history and physical examination the first tentative diagnosis was allergic due to the color of the puppy and the effect of ectoparasite.



Figure 44: Puppy affected by dermatophytosis, the affected areas are indicated by arrows

Differential diagnosis

Photosensitization, FAD, Dermatophytosis, Ectoparasite infestation, Allergic reactions like food allergy.

Case management and outcome

Therefore based on the tentative diagnosis Ivermectin 1% (Hebei Huarun pharmacy Co.,Ltd.China) 0.5ml/25kg in SC route and dexamethasone (Cadila Healthcare limited) 0.1 mg/kg, IM were given stat. but on the follow up the case become aggressive which implies to change the tentative diagnosis. Therefore based on previous history, the location of alopecia and erythema the tentative, the epidemiology and response to the previous drug diagnosis was changed to dermatophytosis and ketoconazole ointment bid for 4 days and ketoconazole tablet sid for a week were given for days. Then the puppy returned to normal health and the hair was

fully grown in one month time (Figure 45). Therefore based on treatment the definitive diagnosis was made as dermatophylosis.



Figure 45: Recovered puppy after antifungal treatment

Discussion

Dermatophytosis is one of the common case that dermatologist and veterinarian in common. Even though laboratory works are not performed to defiantly identify the case the epidemiology, anatomical location and characteristics of the disease and treatment based diagnosis confirm the case as dermatopytosis. The epidemiology tells as the disease is prevalent in Ethiopia this is supported by the study of Araya and his friends. According to the study Łagowski *et al* even clinical dermatophytosis has low prevalence in pet animals the case is present in dogs. The anatomical location of the abnormality was in the head, neck and limbs. Many authors worked on dermatophytosis indicated the area of focal alopecia, erythema, crust and papule in head, feet, and tail on the animals affected with this (Moretti *et al.*, 2013; Nikonov, 2018; Łagowski *et al.*, 2019; Paryuni, Indarjulianto and Widyarini, 2020; Araya, Abuye and Negesso, 2021).

One of the predisposing factors for dermatophytois is age. According to Gangil Dogs at any age suffer from dermatophyte infection, but ringworm infection is more frequent in the young which is also true for the present case where the animal is puppy. Other associated factors

beside the age are explained in different studies and as the study carried by according to Olivar and Debnath poor nutrition, high density of animals and poor management predispose the animal to such infection. This puppy also was not out of this predisposing factor because it lives in rural area (Cervantes Olivares R.A., 2003; Gangil *et al.*, 2012; Debnath *et al.*, 2016).

As to the treatment, the first line drug in this case was Dexamethasone. According to the study of Williams this drug inhibit allergic reaction, and the rational of using the drug in this case was to suppress the allergic related to the tentative diagnosis that related with the color of the dog and the allergy due to ectoparasite. But in this case the drug aggravates the case because as the report of William dexamethasone has side effect of suppressing immunity which prone to fungal complication. The second line treatment was antifungal drug called ketoconazole. As the study of Vishu *et al* and Gangil *et al* this drug is an effective therapy against dermatophytosis (Gangil *et al.*, 2012; Vishnu *et al.*, 2015; Williams, 2018)

Conclusion

Dermatophytosis is a skin disease that affects dogs in the presence of predisposing factors and treating dogs with oral and topical ketoconazole heals the animal.

Acknowledgement

I am thankful for the owner of the animal and VTH staffs.

References

- Araya, S., Abuye, M. and Negesso, A. E. (2021) ‘Epidemiological characterization of dermatomycosis in Ethiopia’, *Clinical, Cosmetic and Investigational Dermatology*, **14**, pp. 83–89.
- Boehm, T. M. S. A. and Mueller, R. S. (2019) ‘Dermatophytosis in dogs and cats - an update.’, *Tierärztliche Praxis. Ausgabe K, Kleintiere/Heimtiere*. Germany, **47**(4), pp. 257–268.
- Cervantes Olivares R.A. (2003) *Ringworm Infection in Dogs and Cats, In: Recent Advances in Canine Infectious Diseases*.
- Debnath, C. *et al.* (2016) ‘Detection of dermatophytes in healthy companion dogs and cats in

- eastern India', *Iranian Journal of Veterinary Research*, **17**(1), pp. 20–24.
- Gangil, R. *et al.* (2012) 'Incidence of dermatophytosis in canine cases presented at Apollo Veterinary College, Rajashtan, india', *Veterinary World*, **5**(11), pp. 682–684.
- Łagowski, D. *et al.* (2019) 'the Prevalence of Symptomatic Dermatophytoses in Dogs and Cats and the Pathomechanism of Dermatophyte Infections', *Postępy Mikrobiologii - Advancements of Microbiology*, **58**(2), pp. 165–176.
- Lakshmipathy, D. T. and Kannabiran, K. (2010) 'Review on dermatomycosis: pathogenesis and treatment', *Natural Science*, **02**(07), pp. 726–731.
- Martinez-Rossi, N. M., Peres, N. T. A. and Rossi, A. (2017) 'Pathogenesis of Dermatophytosis: Sensing the Host Tissue', *Mycopathologia*. Springer Netherlands, **182**(1–2), pp. 215–227.
- Moretti, A. *et al.* (2013) 'Dermatophytosis in animals: epidemiological, clinical and zoonotic aspects.', *Giornale italiano di dermatologia e venereologia : organo ufficiale, Societa italiana di dermatologia e sifilografia*. Italy, **148**(6), pp. 563–572.
- Nikonov, V. A. (2018) *Dermatophytosis in dogs and cats : molecular identification and epidemiology*, 1-72.
- Paryuni, A. D., Indarjulianto, S. and Widyarini, S. (2020) 'Dermatophytosis in companion animals: A review', *Veterinary World*, **13**(6), pp. 1174–1181.
- Rovid, A. (2013) 'Dermatophytosis: Ringworm, Tinea', *The Center for Food Security and Public Health*, pp. 1–13.
- Vishnu, S. *et al.* (2015) 'Dermatophytes: Diagnosis of dermatophytosis and its treatment', *African Journal of Microbiology Research*, **9**(19), pp. 1286–1293.
- WHO (2005) 'Epidemiology and Developing Countries Diseases in Children in Management of Common Skin', pp. 1–54.
- Williams, D. M. (2018) 'Clinical pharmacology of corticosteroids', *Respiratory Care*, **63**(6), pp. 655–670.

5.5 Metabolic Diseases

5.5.1 Ruminant acidosis and its treatment outcome in Sheep

Abstract

Ruminal acidosis is a problem of ruminants that occurs due to excessive and sudden intake of highly fermentable carbohydrates. Two sheep (ewe and ram) with similar history and clinical signs but distinct disease onset (before 4 and 2 days in ewe and ram, respectively) are described in this case report. Additional clinical signs appreciated in a ewe were prolonged recumbency and a subnormal body temperature (35°C). Local treatment was also administered to the ewe, although the result was unsatisfactory. Rumenocentesis was used to collect ruminal fluid, which was then examined grossly (as watery, milk gray in color, and unpleasant odour) and microscopically (as no protozoal mobility was appreciated). Based on the history, clinical sign and rumen content examination, the case was diagnosed tentatively as ruminal acidosis. Orally, an anti-acid containing magnesium hydroxide at a dose of 1g/Kg and mixed with warm water was given every 6 hours until relief is proven. Intramuscularly, oxytetracycline 20% at a dose of 1ml/10kg was administered. The ewe died as a result of the disease severity and a delayed hospital visit, but the ram made a full recovery. If ruminants are suffering from acidosis, prompt treatment is suggested; however, it is difficult to handle the situation once the animals have become recumbent. Furthermore, locally drenching animals with an unknown medicament have an unfavorable consequence.

Key Words: *Ruminal acidosis; Treatment outcome*

Introduction

Rumen is a complex ecosystem where nutrients are digested anaerobically by the microorganisms such as bacteria, protozoa, and fungi. The main end products of fermentation are volatile fatty acids (VFAs) mainly (acetate, propionate and butyrate) and microbial biomass, which are used by the host ruminant. The symbiotic relationship between microorganisms and the host animal allows ruminants to digest diets rich in fiber and low in protein. In the rumen the environment favors the microorganisms to provide the enzymes

necessary to digest the nutrients. Ruminants have the ability to convert the low quality fibrous materials into products such as meat, milk and fibers, which are useful to humans. The ability of ruminal microorganisms to produce the enzymes necessary for fermentation processes allows ruminants to efficiently obtain the energy contained in forages (Burns, 2008).

One of the main disorders in rumen is a ruminal acidosis. This condition occurred when there is an excessive sudden intake of highly fermentable carbohydrates primarily starches and sugars. The main cause of ruminal acidosis is an imbalance between numbers of lactic acid producer and utiliser which finally resulting in organic acid accumulation particularly lactic acid and drop in ruminal pH to levels that impair proper ruminal and physiological functions. Overall the characteristics of ruminal acidosis are increased lactic acid amount both in rumen and blood, rumen osmotic pressure is increased, gram-positive bacteria proliferate in a way gram-negative are highly decreased due to death, reduction of the number of protozoa, hemoconcentration, dehydration, reduction of urine pH (Nagaraja and Lechtenberg, 2007; Meissner *et al.*, 2010).

Clinical rumen acidosis remains a major cause of morbidity and mortality in modern ruminant production systems so as in small ruminants therefore considering this disease is important for the stakeholders (Snyder and Credille, 2017).

The clinical forms of ruminal acidosis can be divided into acute, per-acute and sub-acute forms. Acute form develop within 8 hours and then clinical metabolic acidosis follow and reach peaks in 36 hours. In acute cases rumen will usually appear distended, dehydration present and during auscultation sloshing of fluid within the rumen is heard. Anorexia will be present, along with watery, profuse and foul-smelling diarrhea. Feces have a gray color and may contain undigested grain. Increased heart rate and respiratory rate are present in many cases. Neurologic manifestations of disease are seen in many cases and include obtundation, blindness, head pressing, opisthotonus, altered gait and loss of palpebral reflex. In subacute cases, affected animals remain bright, alert, and responsive but may have transient anorexia with signs of mild to moderate dehydration. In these cases, rumen motility is reduced, but diarrhea and signs of abdominal pain are inconsistent but in the peracute form animals become recumbent, unconscious and might be found dead in 8 to 10 hours with few or no apparent clinical signs (RAGFAR, 2007; Jaramillo-López *et al.*, 2017; Snyder and Credille, 2017).

The principles of treatment include correction of acidosis both ruminal and systemic and prevent further lactic acid production of, restoration of fluid and electrolyte losses and facilitate fore stomach and intestinal motility to normal. Treatment of severe cases (dehydration level above 8%, if it collapse and have subnormal temperature, static rumen and become diarrheic) is not feasible. Treatment of mild cases of acidosis includes feeding of hay to stimulate saliva by withholding concentrates feeds flow. Additional therapy includes oral antacids such as magnesium hydroxide, magnesium oxide or sodium bicarbonate at 1 g/kg body weight and oral electrolyte solutions, preferably those containing additional sodium bicarbonate to treat metabolic acidosis. Broad spectrum antibiotics can be used including penicillin and tetracycline (RAGFAR, 2007; Alam *et al.*, 2014). Therefore the objective of this case report is to show the diagnosis approach and treatment options towards ruminal acidosis and the impact of disease severity.

Case description

Case1

Rumen distention due to carbohydrate feeding was a common problem in ruminants (especially in small ruminants) during my study period. In February 2020, a ewe was presented to Adama veterinary clinic with a complaint of distended belly, watery feces and inability to feed after feeding on bread. The case has occurred at flock level which had a total of five sheep and 2 of them were dead with the same case while the owners try to treat the case by drenching “Areqe” and they brought the ewe when they give-up by their local treatment after 4 days from the day the case had occurred. Upon physical examination, the ewe was weak, in a recumbent position and presented by the aid of the owners, had bloat, dullness, head pressing and sub-normal temperature (35°c) was found.

Case 2

The same case was also presented to Bishoftu Veterinary Teaching Hospital on March 2, 2021. According to the obtained history, the flock of sheep was exposed to feed called “bulle” 2 days before the hospital visit. Abdominal distention and loss of appetite were the owner’s

chief complaints in one ram from the flock. Upon physical examination, bloat was seen but the ram was active and no other abnormalities were appreciated. The stomach tube was passed through the esophagus to reduce the bloating but no relief was witnessed.

Laboratory investigation and findings

In both cases, fresh rumen content/fluid was taken from the left side of the animals by pushing inwards the rumen and content was aspirate by using syringe by the process called ruminal paracentesis. During physical examination, the rumen fluid was milk gray in color, putrid odor and watery consistency. And then examined for the presence of protozoa and the result shows no protozoal movement at all. Therefore, in both cases the result indicates defiantly the development of rumen acidosis in both sheep.



Figure 46: Sheep affected by Acidosis (A); Acidosis in the ewe and (B); Acidosis in the ram

Differential diagnosis

Blot, Parturient paresis, Pregnancy toxemia and Enteritis

Treatment and case follow up

Immediately following a thorough examination of the animals, anti-acid and antibiotics were administered. An oral suspension containing Magnesium hydroxide (GENO

PHARMACEUTICALS PVT.LTD) at a dose of 1g/Kg mixed with warm water was given to both cases with an interval of 6 hours (q6h) until relief is proven and intramuscular OXY TTC 20% (ALFASAN, Holland and Hebei Kexing Pharmaceutical Co.Ltd) at a dose of 1ml/10kg was also administered. On the second day of phone follow-up, I was able to know the death of the first ewe on the night of the examination date. The other sheep in bishoftu has shown good progress during follow-up and return to normal status and start eating properly.



Figure 47: The status of the ram after treatment against acidosis

Discussion

Based on the history, examination of rumen content and treatment outcome this disease was considered as ruminal acidosis. Feeding history was the first indicator for the diagnosis of the disease. As the history indicates both animals feed on abundant carbohydrate rich feeding which is a reason of acidosis. As the work of Nagaraja and Lechtenberg work indicates that feeding on excessive fermentable carbohydrates by ruminants is the reason for the occurrence of carbohydrate engorgement or ruminal acidosis (Nagaraja and Lechtenberg, 2007).

For the diagnosis of ruminal acidosis physical, microscopic and chemical indicators were used. The consistency of this rumen fluid was watery, the color was not greenish and it had putrid odor. As the work of Petrovski indicate that the normal healthy animal rumen content is olive-green to greenish brown in color, a sweet and fermentative smell and the content is slightly viscous. The microscopic examination for the presence, assortment and activity of the

rumen protozoa indicate the absence of ruminal protozoans as well as their movement as the work of Petrovski rumen fluid should contain variety of sizes and species of movable protozoan and in their 30 seconds examination >10 protozoa should enter a single microscopic field (El-Raof and Galbat, 2008; Petrovski, 2017).

Oral suspension containing Magnesium Hydroxide was used for the correction and stabilizing the rumen pH. This treatment protocol is in line with the protocols given by DACA and by the study of Koondhar, Khaskheli and Jariko. The given reasons for giving Magnesium Hydroxide is the effectiveness of the drug to neutralize systemic acidosis and return the animal to normal condition (DACA, 2006; Koondhar, Khaskheli and Jariko, 2020).

Conclusion

Ruminal acidosis is a metabolic disease of ruminants caused by feeding of highly fermentable carbohydrates and if the animal reached to recumbent stage due to the case it is difficult to return to normal health but if the anti-acid and antibiotics are taken around the onset of the case the chance of recovery is broad. Additionally this case report show as drenching local treatments with unknown mechanism of action affects the animal.

Acknowledgment

I am grateful to Adama district veterinary clinic professionals especially Mr. Beyene.

References

- Alam, M. *et al.* (2014) 'Ruminal acidosis- A case compilation study in SAQ teaching veterinary hospital, Bangladesh', *Veterinary World*, **7**(1), pp. 38–43.
- Burns, J. C. (2008) 'ASAS Centennial Paper: Utilization of pasture and forages by ruminants: A historical perspective', *Journal of Animal Science*, **86**(12), pp. 3647–3663.
- DACA (2006) 'Standard veterinary treatment guidelines of Ethiopia', p. 541.
- El-Raof, A. and Galbat (2008) 'CRYOPRESERVATION OF RUMEN PROTOZOA USING THREE DIFFERENT CRYOPROTECTANTS WITH SUCCESSFUL REFAUNATION OF DEFAUNATED SHEEP', (January), pp. 314–332.

- Jaramillo-López, E. *et al.* (2017) 'Ruminal acidosis: Strategies for its control', *Austral Journal of Veterinary Sciences*, **49**(3), pp. 139–148.
- Koondhar, M. Q., Khaskheli, A. A. and Jariko, A. A. (2020) 'Magnesium Hydroxide as Curative Strategy against Lactic Acidosis in Goat', **39**(2), pp. 121–125.
- Meissner, H. H. *et al.* (2010) 'Ruminal acidosis: A review with detailed reference to the controlling agent *Megasphaera elsdenii* NCIMB 41125', **40**(2), pp. 79–100.
- Nagaraja, T. G. and Lechtenberg, K. F. (2007) 'Acidosis in Feedlot Cattle', *Veterinary Clinics of North America: Food Animal Practice*, **23**(2), pp. 333–350.
- Petrovski, K. R. (2017) 'Assessment of the Rumen Fluid of a Bovine Patient', *Journal of Dairy & Veterinary Sciences*, **2**(3).pp 1-7.
- RAGFAR (2007) Ruminal Acidosis - understandings, prevention and treatment, *A review for veterinarians and nutritional professionals*.
- Snyder, E. and Credille, B. (2017) 'Diagnosis and Treatment of Clinical Rumen Acidosis', *Veterinary Clinics of North America - Food Animal Practice*. Elsevier Inc, **33**(3), pp. 451–461.

5.5.2 Hypocalcemia diagnosis approach and the fastest treatment

Abstract

Hypocalcemia is a common problem in late stage pregnant ewes. This case report indicates the presence, the clinical manifestation, treatment option for hypocalcemia in two late stage pregnant ewes. The clinical signs in the affected ewes were depression, weakness leading to sternal recumbence with head resting on the chest and weak heartbeat. The loss of muscle contraction and associated clinical signs were seen in both ewes. Therefore in this case study pupil dilation, loss of defecation and urination and rapid response for calcium borogluconate treatment was used for diagnosis of the case. Additionally based on history the birth of one lamb in a single birth, the body condition of the animals and loss of response to 5% dextrose in one ewe but the rapid response for calcium treatment in both cases were used to differentiate between hypocalcaemia and pregnancy toxemia. During the follow up of it was able to know the birth of healthy lambs and the good status of the ewes. Therefore properly differentiating hypocalcaemia from hypoglycemia is very important to take the appropriate measure.

Key words: *Calcium borogluconate, Hypocalcemia, Pregnant ewes and Pregnancy toxemia*

Introduction

Hypocalcaemia is a metabolic disorder in lambs that occurs most commonly in lambing time or during early lactation. The disorder presents sporadically and generally affects less than 5% of a flock, but sometimes occurs as an outbreak. Most studies show that hypocalcaemia is occurred in intensively housed ewes and in those fed quality concentrated rations (El-Khodery *et al.*, 2008).

Calcium is the most abundant mineral in which about 99% is found in the skeleton and small proportion calcium, around 1%, lies outside the skeleton is important to survival. The skeleton has many functions in the body like supporting muscles and protects delicate organs and tissues but furthermore, the skeletal reserve of calcium actively supports calcium. The calcium outside of the bone found as the free ion, bound to serum proteins and complexed to organic and inorganic acids. Ionized calcium – 50–60% of the total plasma calcium – is essential for

nerve conduction, muscle contraction and cell signaling. Changes in calcium ion concentrations within and between cells are modulated by vitamin D₃ and the calcium-binding proteins, calmodulin and osteopontin: among other things, they can trigger the immune response (Abdelrahman, Kincaid and Elzubeir, 2010). Calcium homeostasis is controlled by the parathyroid glands which secrete parathyroid hormone, vitamin D produced by kidney and skin and calcitonin secreted by C cells of thyroid gland and; the parathyroid hormone stabilizes blood calcium level and vitamin D facilitates absorption of calcium from GIT (Martins-Bessa *et al.*, 2003).

The most common causes of hypocalcemia are PTH and vitamin D deficiencies, inadequate supply of metabolizable calcium, disturbances in absorption due to diarrhea, malabsorption of vitamin-D and excessive excretion of calcium from kidneys (Woldemeskel, Eneyew and Kassa, 2000; Tinawi, 2021).

Total serum calcium normally falls throughout pregnancy therefore mothers are at risk when they already have hypocalcemia and have to pass stressful conditions to meet the normal maternal needs with the additional needs of calcium during pregnancy and lactation (Almaghamsi, Almalki and Buhary, 2018).

Parturient paresis clinical signs have three progressive stages including early signs such as restlessness, anorexia, rumen atony with mild bloat, and insecure gait. More advanced stages with general muscle weakness leading to sternal recumbency with head lying on the chest, mental depression, dilated pupils, weak heartbeat but the rate is increased, dry muzzle, dry feces, and hypothermia. Last stage characterized by lateral recumbency, severe rumen bloat, inaudible heart sound, tachycardia, coma, circulatory collapse and death (o. M. Radostits, 2010; CGH, 2015; CONSTABLE, 2017).

As a treatment fluid that contains calcium are used but Calcium gluconate and calcium borogluconate are best treatments. To control the occurrence of hypocalcemia in ruminants different measures can be taken like reduction of dietary calcium and potassium intake 2 to 3 weeks and in late gestation respectively. Provide adequate dietary magnesium and vitamin D in late gestation (CONSTABLE, 2017).

Therefore the objective of this case report is to differentiate hypocalcaemia and hypoglycemia and putting the treatment option towards hypocalcaemia.

Case discription

On april 22-2021 an owner brought his ewe to AAU-CVMA-VTH, Bishoftu. According to his compliant the ewe was normal last night before presentation, but in the examination morning the ewe failed down and unable to stand. As Mr. owner said that the ewe was laid down when it stacked in confined space. Additionally it was able to know the ewe's late stage pregnancy and two number of parity before this round but she gives a single birth at a time. In previous parity the newborns were unable to survive due to unknown reason.

Diagnosis approach for a late pregnant ewe in suspecting of both hypocalcaemia and pregnancy toxemia

Both hypocalcaemia and hypoglycemia cases are common in late pregnant ewes and both metabolic diseases in pregnant ruminants are unable to differentiate by simple observation of the diseased animal. In this ewe diagnose trails were made first by looking at defecation and urination of the animal and able to know the absence of both in the diagnosis time. Then the eye of the ewe was covered by hand for around one minute and then checked for the pupil contraction after hand is left up, then on the response the ewe was unable to open its eye in the expected seconds (the starting concept is taken from "<https://www.youtube.com/watch?v=vjaZolhJZTA&t=4s>") Other clinical signs were depression, weakness leading to sternal recumbence with head resting on the chest and weak heartbeat. Then the tentative diagnosis goes to hypocalcaemia which is confirmed after the response of the ewe to calcium borogluconate. The second ewe had the same clinical signs with the first ewe but as a first treatment glucose 5% was administered but the ewe was unable to be active. Then after some minutes calcium borogluconate was given and it had rapid response.



Figure 48: Hypocalcemic ewes (A) and (B) Recombance stage of hypocalcemia affected ewes (C) Pupil examination (D) Rectum with secure feces

Treatment outcome

For the treatment CALCIJECT (calcium borogluconate 40%) was administered, each ml contain 400mg calcium borogluconate and 50 mg magnesium hypophosphate hexahydrate which is the product of Norbrook laboratories limited, Newry, Co. Down, BT35BJP, Northern Ireland. The dose was 1ml/kg, mean that around 40 ml was given through I.V. into jugular vein by keeping the heartbeat at the normal state through hearing the beat by using stetoscope. The drug was given slowly. After the treatment the ewe was assisted to stand by itself there for the ewe does and after around two minutes the ewe start to urinate then able to stand properly and start to move. During the follow up of it was able to know the birth of healthy lambs and the good status of the ewes.



Figure 49: Hypocalcemic ewes after treatment: (A); ewe urinating after treatment (B); the active condition of ewe after treatment and (C); the active condition of the second ewe after treatment

Discussion

Hypocalcaemia was diagnosed in these recumbent ewes based on physiological condition which is late stage pregnancy, clinical findings and rapid response to calcium borogluconate therapy. A review by Martins-Bessa *et al* also indicates the diagnosis approach towards hypocalcaemia based on those methods. Based on this review being pregnant can exposed ewes for hypocalcaemia because during this period the calcium demand for the fetal bone development is very high (Martins-Bessa *et al.*, 2003).

The clinical signs found in these cases were depression, weakness leading to sternal recumbence with head resting on the chest and weak heartbeat. The weakness of the muscle was examined by the inability to urinate and defecate properly on the time of diagnosis. Inability of pupil contraction was also one of the diagnosis way used to address hypocalcaemia

this case, this is based on the notion of that in hypocalcaemia the pupil remain dilated because iris sphincter and dilator muscles are unable to contract due to calcium deficiency. These clinical signs are supported by the explanation of text book of veterinary medicine 11th edition (CONSTABLE, 2017).

One of the aims of this case report is to report the way of diagnose and differentiate between hypocalcaemia and pregnancy toxemia because both affect lambing ewe flocks and have similar signs but different causes. As the history indicates a single lamb was born in one parity. Most of the time pregnancy toxemia is manifested in ewes that give birth for twins. Therefore based on this history, the case was more indicative for hypocalcaemia than pregnancy toxemia. The other thing is pregnancy toxemia more relevant in very over-conditioned ewes but the case indicates the normal status of the ewes. This indicative measurements are align with the work of (Olfati, Moghaddam and Bakhtiari. Finally the differentiation is by the response to therapy. Both ewes were responsive for the calcium borogluconate but in the second ewe the first treatment was more relevant for hypoglycemic case but the ewe had no response for it. This is supported by the treatment part of hypocalcaemia in Radostits text book (o. M. Radostits, 2010; Olfati, Moghaddam and Bakhtiari, 2013).

Conclusion

Hypocalcaemia is a common metabolic disorder in late pregnant ewes. The clinical signs and history are very indicative of the case but it is hard to differentiate between hypocalcaemia and pregnancy toxemia therefore some technique are mentioned to differentiate between them. The animals show a good immediate response due to this correct diagnosis technique.

Acknowledgments

I am grateful to Dr. Cheru Talila and Dr. Mehari Teklu for their collaboration and important advices.

References

Abdelrahman, M. M., Kincaid, R. L. and Elzubeir, E. A. (2010) *Mineral Nutrition of Livestock, 4th Edition, Mineral deficiencies in grazing dairy cattle in Kordofan and*

Darfur regions in Western Sudan, 1-576.

Almaghamisi, A., Almalki, M. H. and Buhary, B. M. (2018) 'Hypocalcemia in pregnancy: A clinical review update', *Oman Medical Journal*, **33**(6), pp. 453–462.

CGH, M. I. (2015) *Acute Treatment of Hypocalcaemia (adults)*, *GHNHSFT Drug & Therapeutics Committee*.

CONSTABLE, P. D. and KENNETH W. HINCHCLIFF STANLEY H. DONE WALTER GRÜNBERG (2017) *VETERINARY MEDICINE 11th edition*.

El-Khodery, S. *et al.* (2008) 'Hypocalcaemia in Ossimi sheep associated with feeding on beet tops (*Beta vulgaris*)', *Turkish Journal of Veterinary and Animal Sciences*, **32**(3), pp. 199–205.

Martins-Bessa, A. *et al.* (2003) 'Hypocalcemic tetany in a pet lamb fed with cow milk Giadinis', *Journal of the Hellenic Veterinary Medical Society*, **85**(1), pp. 3–11.

o. M. Radostits (2010) *VETERINARY MEDICINE A textbook of the diseases of cattle, horses, sheep, pigs and goats*. 10th edn. Edited by o. M. R. C. C. G. K. W. H. P. D. Constable.

Oetzel, G. R. (1988) 'Parturient paresis and hypocalcemia in ruminant livestock.', *The Veterinary clinics of North America. Food animal practice*. United States, **4**(2), pp. 351–364.

Olfati, A., Moghaddam, G. and Bakhtiari, M. (2013) 'Diagnosis , Treatment and Prevention of Pregnancy Toxemia in Ewes', **1**(11), pp. 1452–1456.

Thilsing-Hansen, T., Jørgensen, R. J. and Østergaard, S. (2002) 'Milk fever control principles: A review', *Acta Veterinaria Scandinavica*, **43**(1), pp. 1–19.

Tinawi, M. (2021) 'Disorders of Calcium Metabolism: Hypocalcemia and Hypercalcemia', *Cureus. Cureus*, **13**(1), pp. e12420–e12420.

Woldemeskel, M., Eneyew, M. and Kassa, T. (2000) 'Study on ovine hypocalcemia in ewes in central Ethiopia', *Revue de Medecine Veterinaire*, **151**(4), pp. 345–350.

5.6 Diseases Caused By Hormonal Problem

5.6.1 *Urinary incontinence and other complications in a bitch*

Abstract

Urinary incontinence is involuntary and uncontrolled voiding of urine during its phase of storage. Urinary incontinence can be caused by neurological and non-neurological disorders. This condition is common in female dogs and has significant effect on the animal and also for the owner. On May 11/2021, a five year spayed bitch was presented to veterinary teaching hospital with a chief complaint of urine leakage since one month, loss of appetite and weakness. Additionally three months ago the presence of traumatic injury was indicated on the history. Upon physical examination and inpatient care, the bitch was found urinary incontinent and with other additional complications. Since urinary incontinence is a multifactorial disorder to diagnose the case complete clinical examination approach was used. This include abdominal ultrasound examination of urinary tract and other vital organs, hematological, kidney and liver function tests and blood glucose level. The tests result indicates the normal and functional organs and system except the presence of severe anemia (PCV= 20%). The bitch was treated by vitamin B-complex for five successive days at a dose of 0.16mg/kg/day with the aim of restoring urinary incontinence and penstrip for three successive days 1ml/20kg/day, Ivermectin 0.5ml/25kg/stat and gentamycin eye drop for 5 days for the additional complications. After the treatments the eye was healed fully and appetite was returned back and the bitch became active but urine leakage was still present. Therefore, it was concluded that the urinary incontinence in this bitch was due to spaying because the case is common in 2 to 9 age of spaying in the absence of other underlying causes. But due to lack of drug that treat urinary incontinence in the market the bitch is still suffering. Therefore, urinary incontinence due to spaying is a common problem in bitches and have a significant impact on the animal and to the owners.

Key Words: *Bitch, spaying and urinary incontinence*

Introduction

Urinary incontinence (UI) is involuntary leakage of urine during the storage phase of micturition. This problem is one of the concern in a veterinary practice (Reichler and Hubler,

2014; Thomson and Jaque, 2017). The cause of urinary incontinence are multifactorial and knowing the exact pathophysiology is difficult but the potential risk factors include body weight, gonadectomy, gender, breed, bladder neck position and urethral length (Paula Thomson and Victoria Jaque, 2019).

The causes of UI can be classified as neurological and non-neurological. The function of the lower urinary tract (LUT) is regulated by the autonomic (central and peripheral) and somatic nervous systems. However, there are also other factors such as the reproductive hormones status and the integrity of the bladder and urethral which have important roles in the function of the LUT. The most common causes of urinary incontinence in dogs are urinary sphincter mechanism incompetence (USMI). USMI can develop in both male and female dogs but the prevalence is higher in females than in males, in which spaying is the most common risk factor associated with the condition. Therefore UI is prevalent in spayed dogs than in intact bitches (Forsee *et al.*, 2013; Lessel, 2018). Other factors which can be the cause of UI are polyuria/polydipsia, urinary tract infections and vaginal strictures can exacerbate pre-existing incontinence (Jodi L. Westropp, 2008; Adin., 2013).

The presence of UI in bitch has many consequences like constant or intermittently urine dripping on the hind limbs therefore the area is frequently wet with urine or saliva due a constant licking which expose the animal for irritation and ulceration of perineal area. Constant urine leakage on the other hand form constant and unpleasant odor of urine which is a challenging condition for the owners (Ponglowhapan, Khalid and Church, 2012; Serra, Acabado and Coimbra, 2015).

Diagnosing UI is an easy task but it requires extensive diagnosis to determine the exact cause. To diagnose UI associated with calculi, mass effects and extrinsic non-skeletal abnormalities ultrasonography is best. In case of congenital conditions like ectopic ureter and patent urachus, checking the case since birth or before spaying has been done is used to diagnose the case exactly. Generally doing complete blood count, biochemistry panel, urinalysis is used to support the presumptive diagnosis of UI , if results of these diagnosis found within normal limits when USMI is present in a dog, these tests should be performed to rule out concurrent diseases (Silverman and Long, 2000; Byron *et al.*, 2017; Lessel, 2018; Rory Applegate, Shelly Olin, 2018).

To treat UI in bitches the first choice is a medical treatment. Alpha-adrenergic drugs like phenylpropanolamine and estrogens are treatment of choice. The mechanism of action alpha adrenergic drug called phenylpropanolamine works by increasing urethral sphincter tone by tensioning smooth muscles in both the bladder neck and urethra. Surgery is recommended when medical treatment fails (Scott *et al.*, 2002; Rory Applegate, Shelly Olin, 2018).

Therefore the objective of this work was to diagnose the cause of urinary inconstancy using complete clinical examination approach and treating the chief and other complications.

Case description

In May 11, 2021 a five years old German Shepherd spayed bitch was presented to veterinary teaching hospital (VTH) with a chief complaint involuntary urine leakage since a month, weakness and decreased appetite. Therefore the owner was very unpleasant in the condition besides the bitch suffering. Upon the history taking additionally it was able to know the bitch was injured by stone three months before the day of examination and spaying history four years ago. The physical examination revealed the wetting of the hind limb (Figure 50), the bitch spent most of the time in reclining position but when the bitch stood up the urine become abundant to see in the back area. To follow the bitch was admitted as inpatient for 5 days. During the period the physical parameters were found normal but the animal was so lethargic, had anorexia and very selective to eat, but frequent and ample drinking was found. Additionally the bitch had high tick infestation and eye infection due to trauma. Therefore based on the history and physical examination the bitch was tentatively diagnosed with urinary incontinuity due to unconfirmed reason and additional complications. Hence to diagnose the case complete clinical examination approach was used

Tentative diagnosis: Urinary inconsistency due to ovariohysterectomy/ spaying

Differential Diagnosis: Urinary incontinence due to mass on the bladder and ureter, diabetes, kidney problem, nervous system problem or unknown cause



Figure 50: Bitch with urinary incontinence (A) The circled area indicate the wet part due to the urine (B) Bitch with involuntary urine leakage in seating position

Ultrasound examination and blood chemistry

The bitch was diagnosed by the ultrasound for the presence of mass in the urinary tract, fistula and kidney stone and different organs were looked well for the presence of abnormality (Figure 51). The result indicates normal size and contour of the visible organs. There was no mass in urinary tract, any urethero-vaginal fistula and kidney stone but the bladder was found empty.

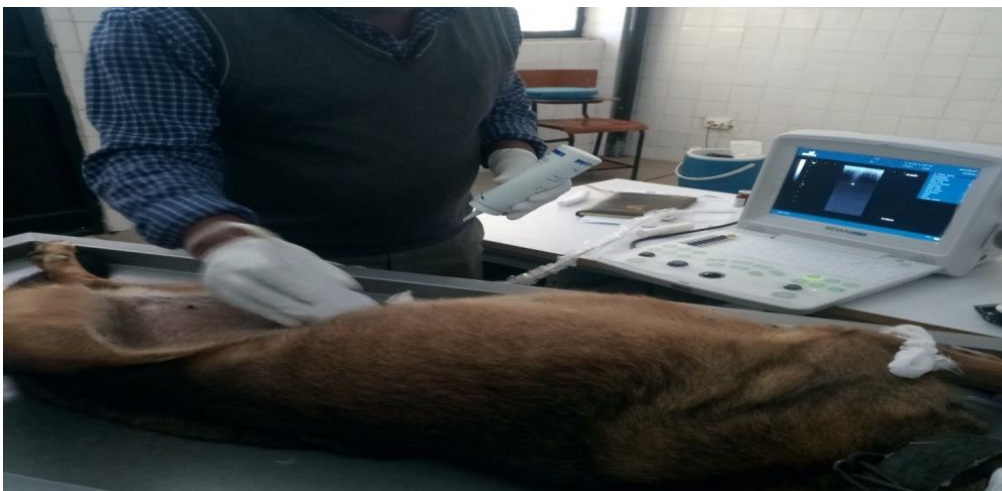

Figure 51: Ultrasound examination of a bitch with urinary incontinence

Laboratory investigation and findings

A blood sample was taken from the cephalic vein using both plain and EDTA coated tubes and taken to Dr. Amanuel Hospital, Bishoftu and to VTH clinical pathology laboratory for further confirmation. Blood chemistry was done to confirm the underlying cause of urinary incontinence. Beside the ultrasound examination the kidney was examined for its functionality where blood urea (29.418 mg/dl) and creatinine (1.324mg/dl) used as indicators. The result for both indicators was failed in normal range. Blood glucose (97.755 mg/dl) was another test in order to check if the incontinency was due to hyperglycemia but still the result was in normal range. Other tests that were done to know the general health status of the bitch were total protein (7.586g/dl), total bilirubin (0.285mg/dl) where again failed in the normal range (Annex 5 & 6). Complete blood count tests mainly PCV and Hemoglobin were done and the result indicates low level of PCV (20%), hemoglobin (4 g/dl) and MCHC (20g/dl). Therefore most of these results show the functionality of tested organs which may lead to cancel other differential diagnosis except UI which due to ovariohysterectomy and the CBC result indicates the presence of anemia.

Case management

The case was first treated by vitamin B complex 0.16mg/kg/day for 5 successive days, penstrip 1ml/20kg/day for three successive days, Ivermectin 0.5ml/25kg/stat and gentamycin eye drop for 5 days. In the meantime as the bitch was so lethargic IV suspension of 5% glucose ($\% \text{ dehydration} \times \text{body weight (kg)} \times 1000^b \times 0.80$, where dehydration level for the taken as 7) and Maintenance Volume ($(30 \times \text{BW}_{\text{kg}}) + 70$) was administered for two days. After the intervention the bitch come to normal health status and its appetite was returned back gradually but due to lack of the drug that treat incontinency due to spaying the bitch hasn't stopped to void urine continuously.

Discussion

Urinary incontinence is an involuntary loss of urine during a storage period of urine and this bitch was diagnosed as urinary incontinent because of continuous urine voiding which revealed by Urin out flow in laying decubitus, resting or sleeping position as indicted in the

history and during inspection. this finding is agreed with the work of DeRossi Rafael (DeRossi Rafael, 2003).

To know the underlining causes of urinary inconsistency in the bitch complete clinical examination approach were used because urinary inconstancy in bitches can be triggered by multiple causes. As the statement of Pegram *et al* appropriate UI diagnosis should include complete history taking, serum chemistry urine analysis and diagnostic imaging. The first diagnostic and treatment approach was based on history of trauma which has been occurred three months before the examination date and it might lead to neurological disorder because neurological disorder was suspect as one cause of urinary incontinency in this bitch case. According to Silverman and Long study, trauma to the cauda equina or luxations of coccygeal vertebrae can be the possible cause of neurogenic incontinence (Silverman and Long, 2000). Therefore to treat a problem associated with nervous system, B-complex drug was used. This agreed with the study of Calderón-Ospina and Nava-Mesa, as this study B-complex drugs have several functions in both central and peripheral nervous system including treating neuropathic pain because these vitamins involve in glucose metabolism and the synthesis of neurotransmitters and myelin (Pegram *et al.*, 2019; Calderón-Ospina and Nava-Mesa, 2020).

The other tentative diagnosis for this urinary incontinence was diabetes. As the study of Smith diabetes has a strong relationship with UI. Therefore it was logical to diagnose diabetes in urinary incontinent dogs. But the finding indicate the normal level of blood glucose (Smith, 2006).

Now the cause of UI in this bitch fails into estrogen deficiency based on the history, signalment and absence of other causes. According to the history the bitch had spaying 4 years ago and as this study of DeRossi Rafael there is a high occurrence of UI after 2-9 age of spaying in female dog because of whether estrogen deficiency or surgical procedure as the risk factor for UI However recent studies disprove the presence of connection between UI and spaying technique. Additionally according to this author high incidence of UI is registered in large breed dogs with second rank of German Shepherd dogs next to (DeRossi Rafael, 2003; Serra, Acabado and Coimbra, 2015).

Finally on the hematological tests the bitch was found anemic. This laboratorial finding can be indicative of different disorders. According to Sosa anemia can occur for different reasons which includes blood loss, cancer, bone marrow disorder, medication, chronic disease and nutritional deficiencies. Anemia in this bitch is more related with nutritional defiance because after the treatment and when its appetite returned gradually, the bitch was showed a good health improvement and become normal. As WHO nutritional deficiency is result of taking a smaller amount of nutrient which is useful for the synthesis of hemoglobin, which was found low in this laboratory test. Therefore it was concluded that the anemia of this bitch might be the result of nutritional deficiency (WHO, 2017; Sosa, 2018).

Conclusion

Urinary incontinence due to spaying is a prevalent disease in a bitch and damage the bitch due to irritation and ulceration and affect the owner by producing unpleasant odor.

Challenges

Taking urine sample, getting the materials to do a urine analysis, cost of laboratory diagnosis and getting treatment for the chief compliant were found very difficult.

Opportunity

The presence of such type of disease in our context opens the door to think wider and elevate our diagnostic approach and lead to have drugs that treat uncommon cases on the need on the owners.

Acknowledgment

I am so grateful to Dr.Tilaye Demissie who helped me on the diagnosis of the case and Beimnet Wondemagegn (a 6th year DVM student) who handle the case with me

References

Adin., C. A. (2013) 'Diagnosis and management of urinary incontinence in residential care', *British Columbia Medical Journal*, **55**(2), pp. 1–4.

Byron, J. K. *et al.* (2017) 'Urethral Sphincter Mechanism Incompetence in 163 Neutered

- Female Dogs: Diagnosis, Treatment, and Relationship of Weight and Age at Neuter to Development of Disease.’, *Journal of veterinary internal medicine*, **31**(2), pp. 442–448.
- Calderón-Ospina, C. A. and Nava-Mesa, M. O. (2020) ‘B Vitamins in the nervous system: Current knowledge of the biochemical modes of action and synergies of thiamine, pyridoxine, and cobalamin’, *CNS Neuroscience and Therapeutics*, **26**(1), pp. 5–13.
- DeRossi Rafael, et al (2003) ‘Post-ovariohysterectomy Colposuspension to Prevent Urinary Incontinence Syndrome in the Bitch’, *journal of animal and veterinary advance*, **2**(8), pp. 437–443.
- Forsee, K. M. *et al.* (2013) ‘Evaluation of the prevalence of urinary incontinence in spayed female dogs: 566 cases (2003-2008).’, *Journal of the American Veterinary Medical Association*, **242**(7), pp. 959–962.
- Jodi L. Westropp (2008) ‘Urinary Incontinence in Dogs: Diagnostics and Management Strategies’, in *World Small Animal Veterinary Association World Congress Proceedings*, pp. 1–4.
- Lessel, A. (2018) ‘Urinary incontinence as consequence of castration in bitches’, *Veterinar*, **56**(1), pp. 26–31.
- Paula Thomson and Victoria Jaque, S. (2019) ‘Medical treatment of urinary incontinence in the bitch’, *Vlaams Diergeneeskundig Tijdschrift*, **88**(1), pp. 1–8.
- Pegram, C. *et al.* (2019) ‘Spaying and urinary incontinence in bitches under UK primary veterinary care: a case–control study’, *Journal of Small Animal Practice*, **60**(7), pp. 395–403.
- Ponglowhapan, S., Khalid, M. and Church, D. (2012) ‘Canine urinary incontinence post-neutering: A review of associated factors, pathophysiology and treatment options’, *Thai Journal of Veterinary Medicine*, **42**(3), pp. 259–265.
- Reichler, I. M. and Hubler, M. (2014) ‘Urinary incontinence in the bitch: an update.’, *Reprod Domest Anim. Germany*, **2**, pp. 75–80.

- Rory Applegate, Shelly Olin, B. S. (2018) 'Urethral Sphincter Mechanism Incompetence in Dogs: An Update', *J Am Anim Hosp Assoc*, **4**(1), pp. 22–29.
- Scott, L. *et al.* (2002) 'Evaluation of phenylpropanolamine in the treatment of urethral sphincter mechanism incompetence in the bitch.', *The Journal of small animal practice*. England, **43**(11), pp. 493–496..
- Serra, I., Acabado, F. and Coimbra, O. (2015) *Urinary Incontinence In Bitches After Ovariohysterectomy*.
- Silverman, S. and Long, C. D. (2000) 'The diagnosis of urinary incontinence and abnormal urination in dogs and cats.', *The Veterinary clinics of North America. Small animal practice*. United States, **30**(2), pp. 427–448.
- Smith, D. (2006) 'Urinary incontinence and diabetes - A review', *Journal of WOCN*, **33**, pp. 619–623.
- Sosa, E. (2018) 'Anemia Associated With Nutritional Deficiencies',
- Thomson, P. and Jaque, S. V. (2017) '20 - Health concerns and burnout', in Thomson, P. and Jaque, S. V. (eds) *Creativity and the Performing Artist*. San Diego:
- WHO (2017) *Nutritional Anaemias : Tools for Effective Prevention, Who*.

5.7 Tumor case

5.7.1 *Canine transmissible venereal tumor in a bitch*

Abstract

A canine transmissible venereal tumor (CTVT) is a common and naturally contagious neoplastic problem of bitches. A 5-year-old bitch was brought to a veterinary teaching hospital with the main complaint of genital swelling over the past six months, with intermittent bleeding and gradual weight loss. The bitch mated many stray dogs. A firm and red protruding mass dangling through the vulva was observed during physical exams, but the bitch was active. Fine needle aspiration cytology was performed afterward, which confirmed the diagnosis of CTVT. Chemotherapy can help to address such problems, but it was not accessible during the case was handled. However, because the CTVT case was becoming a common problem among the bitches brought to VTH, we decided to attempt ivermectin, which has a favorable therapeutic outcome in human reproductive/ovarian cancer and bovine papillomatosis/warts. The trial began with ivermectin at a dose of 2 mg/kg for five weeks in a row, with a week in between, but the results were unsatisfactory. As a result, the dog was euthanized, and a postmortem examination revealed that the tumor had not spread to the surrounding organs, including the uterus. This phenomenon led us to question if ivermectin treatment may help to restrict tumor spread. In conclusion, CTVT is a transmissible tumor that necessitates early chemotherapy. However, because the medication is not readily available for animals, we recommend additional research into ivermectin as a CTVT therapy option.

Key Words: *Canine transmissible venereal tumor and Ivermectin*

Introduction

Tumors are the most common of mortal disorders observed in humans and animals. Among mammals, dogs are most susceptible for tumor. Transmissible venereal tumor (TVT) is one of the dog neoplasia which is benign type of reticulo-endothelial tumor affecting mainly the external genitalia and occasionally the internal genitalia of dogs. It is also known as

transmissible lymphosarcoma, venereal granuloma (Chu *et al.*, 2001; Tella, Ajala and Taiwo, 2010; UÇAR, 2016).

Canine transmissible venereal tumor is unique in oncology because it was the first tumor to be transmitted experimentally, this being achieved by the Russian veterinarian Nowinsky in 1876 (Das and Das, 2000). This viable tumor cells mainly affect the genital region whereas extra-genital cases of TVT has also been discovered including nasal cavity, conjunctiva and eye, skin, buccal and anal mucosa (Mukaratirwa and Gruys, 2003; Chanie, 2015).

Dogs of any breed, age or sex are susceptible. Sexually mature dogs are more susceptible than others especially dogs 2 to 5 years old. The transmission of TVT is more in close contact with one another, with stray and wild dogs. The disease out of gentile area is transmitted based on the behaviors of the dogs like sniffing, licking, scratching (Das and Das, 2000; Abedin, 2012; UÇAR, 2016).

Regarding the cause and pathogenesis of TVT, the old attributed states that the cause of this neoplasia is believed as viral agents, but the current view is that the abnormal exfoliation and transplantation cells of neoplasm due to physical contact inoculate into the susceptible dogs are the vectors of transmission. Implantation is aided by the presence of mucosal lesion or any breach in the mucosal integrity. Then when intact host tumor cells lose the expression of major histocompatibility complex (MHC) class I and II molecules enabling transposition of the tissue to a healthy animal by contact between skin and damaged mucosa (Abedin, 2012; Purohit, 2012; Chanie, 2015).

Clinical sign of CTVT includes abnormal growth, in the external body especially visible when the venereal tumor protrudes from its point of attachment and not hidden by the prepuce or vulva and the size is varied. When external swelling is not visible, genital discharge which needs further clinical examination, usually via digital palpation (if female) or organ exposure are found. The tumor growths is well circumscribed, unencapsulated, friable and bleed easily with slight manipulation (Santiago-flores *et al.*, 2012). Metastasis of this tumor is uncommon and it can only occur in puppies and immunocompromised dogs. CTVT is frequently reported in dogs as a cause of high morbidity and economic losses (Das and Das, 2000; Hiblu, Khabuli and Gaja, 2019).

For the treatment of TVT, various possibilities such as surgery, radiotherapy, immunotherapy and chemotherapy are used. Among these options chemotherapy has been shown to be the most effective and practical therapy, with vincristine sulfate being the most frequently used drug (Nak *et al.*, 2005; Purohit, 2012). Vincristine sulfate ceases mitosis of spindle fibers which contributes to cellular division arrested in metaphase stage by binding to tubulin dimer. The typical course of vincristine treatment is four to eight week of intravenous administration at 0.5 to 0.7 mg/m² body surface area (BSA) or 0.025 mg/kg body weight and other chemotherapeutics such as doxorubicin, vinblastine, methotrexate and prednisolone. Surgery has been used extensively for the treatment of small, localized TVTs, although the recurrence rate can be as high as 50 - 68% in cases of large invasive tumors (Abedin, 2012; Sudjaidee, Theewasutrakul and Techarungchaikul, 2012; Hiblu, Khabuli and Gaja, 2019).

Therefore the objective of this case report is to report the presence and alarming situation of canine transmissible venereal tumor, showing the diagnostic approach towards the disease and showing the available drugs of treatment and their feat.

Case description

A 5 –year-old German shepherd bitch was brought to VTH with a complaint of swelling in a genital area since half year with occasional bleeding, gradual loss of body condition. The owner also explained the bitch meet many street dogs outside. The bitch was recently gave birth for two puppies but the case was present before parturition and the puppies were free from the case. Upon physical examinations, the bitch was found active, the temperature was normal (38.3^oc), there was red protruding mass hanging through vulva. The mass was hard, hemorrhagic (not always) and it was extending from the vulva to the inner part of the genital organ and the extension was unable to determine by simple palpation. Most of the time this hard mass was seen closed and dry. The mass was only confined in the genital area. The puppies were always with the bitch and have a close contact with their mother. Dogs with the same problem were presented to VTH before and after this bitch which indicate the distribution of the case. Based on the history and clinical findings, canine transmissible venereal tumor (CTVT) was suspected and samples were collected using fine needle aspiration (FNA) technique for cytology.

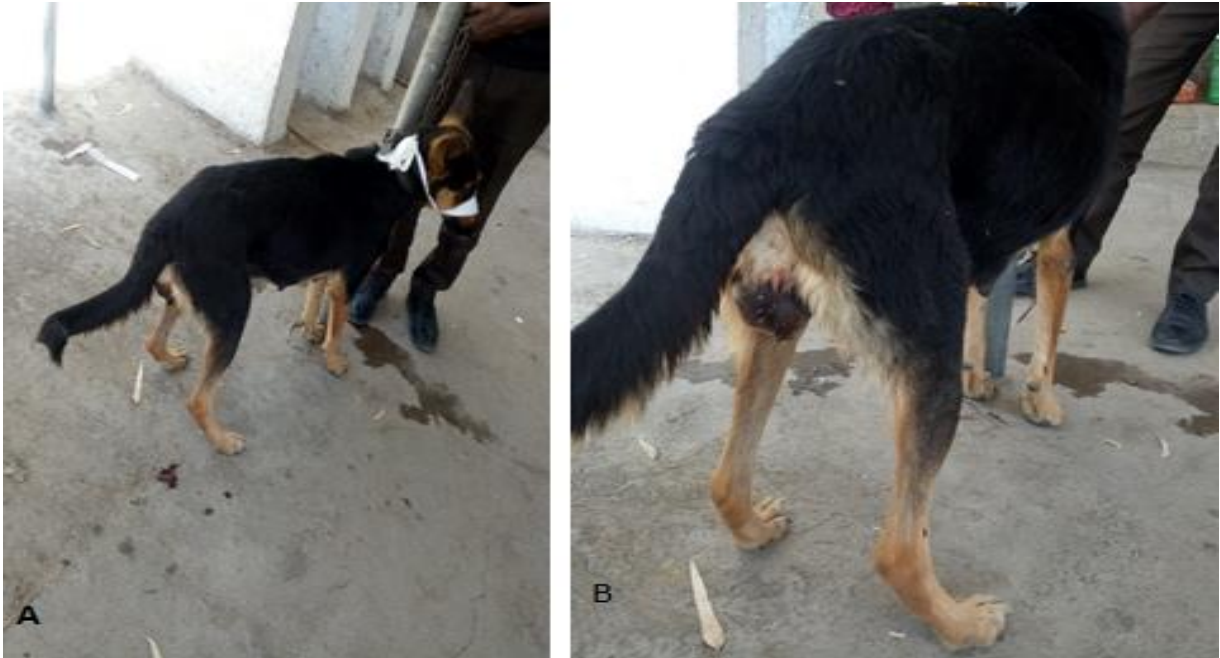

Figure 52: CTVT affected bitch

Differential diagnosis of CTVT

Vaginal prolapse, Hematoma, Hernia and Bite.

Laboratory investigation and findings

To confirm the cause of the disease a sample was taken by fine needle aspiration technique and cytology was made. After the sample was taken a thin smear was made and stained by giemsa stain. Then the smear was examined with oil immersion under microscope using 100X objective lens. The cells were large in size but vary somehow, numerous in number, shape of the cells were varied and the cells were discrete; the nucleus was found prominent, round to oval shaped; the chromatin was deeply stained; the cytoplasm was foamy and typical mitotic figure was found. There was no inflammatory cell found. Therefore, these microscopic findings were confirmed that the cause of this disease was canine transmissible venereal tumor.

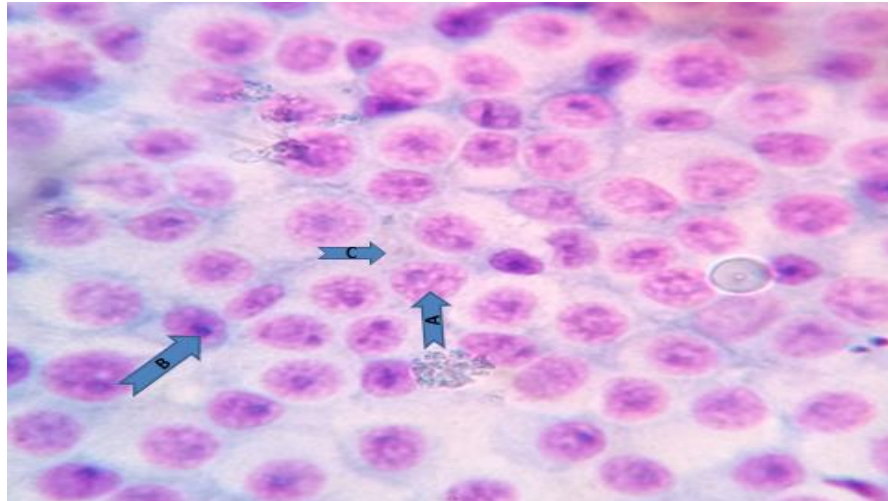


Figure 53: Fine needle aspiration cytology (A); Indicating mitotic figure (B); Deeply stained chromatin and (C); Foamy cytoplasm

Case management

After the confirmatory diagnosis, the case was explained to the owners as it was a tumor case. Getting the conventional and effective treatment was not successful due to unavailability of chemotherapy in the market. Surgical intervention was not also found feasible for this case. Therefore, after talking with the owners we decided to attempt ivermectin, which has a favorable therapeutic outcome in human reproductive/ovarian cancer and bovine papillomatosis/warts. The trial began with ivermectin at a dose of 2 mg/kg for five weeks in a row, with a week in between, via parenteral routes and local infiltration. Simultaneously, penstrip (1 ml/25kg) for 5 days was given to prevent subsequent complications related to bleeding in the genital area. The progress of the bitch was not satisfactory and the genital masses were present until the end of the treatment. Therefore, the treatment was ceased and based on the disposition of the owners, the bitch was euthanized and post mortem examination was done and the lesion was found only in the genital organ which does no metastasis to other organs even to the uterus. This phenomenon made us to wonder if Ivermectin was capable of having some contribution to stop the metastasis.

Discussion

The bitch with a protrude mass in the genital area was diagnosed as diseased by canine transmissible venereal tumor based on the clinical manifestations, the affected body site, the recent occurrence of the same case in other dogs and by cytological examination. On the physical examination large, hard mass hanging through vulva was found, while passing finger through the vulva, more mass was palpated and the extent was not be able to determine exactly. This finding is the same with the finding in the case studies of Sreekumar and Ajidhan and Gahalot. The bitch was found active and other vital parameters were normal and the owner's concern and chief compliant was the mass in genital area. According to the case study of Sreekumar and Ajidhan from five CTVT examined dogs two were found active and their parameters were normal (Sreekumar KS and Ajidhan, 2015; Gahalot, 2019).

Rendering to the history the bitch stays long out side of the kennel and as well as out of home and mate other dogs. According to the review of Purohit for the high incidence of TVT uncontrolled sexual behavior and a large stray dog population appear to be one reason (Purohit, 2012).

Fine needle aspiration cytology (FNAC) was used as the confirmatory diagnosis because the technique was found simple, fast, safe and low-cost, which allows through the evaluation of cell morphology to establish prognosis, define surgical margins, monitor chemotherapy protocols, monitor lesion growth, validate indication euthanasia during surgery in neoplastic (Noeme Sousa Rocha, Tália Missen Tremori, 2014). The laboratory finding indicates the large sizes of cells, numerous in numbers, variation in both size and shape of the cells and the cells were discrete and round to oval in shape and the chromatin was deeply stained. These findings are agreed with the finding of Simoni and Knoll where discrete round cells with mild anisocytosis and anisokaryosis are the main characteristics of their finding. The other main feature of this TVT case was foamy cytoplasm and the presence of typical mitotic figure, which is also indicated in TVT case done by Santiago-flores *et al* (Simoni and Knoll, 2008; Santiago-flores *et al.*, 2012).

Ivermectin was the available option to try as a treatment in this TVT case. The rationale behind was that recently scientists have discovered Ivermectin as a strong anticancer drug for

different types of cancer including reproductive cancers. In 2020 study titled “Ivermectin, a potential anticancer drug derived from an antiparasitic drug” indicates the multi-use of the drug like antiviral effects, promising inhibitory effect on the SARS-CoV-2 virus and for different types of cancer in human. Also in another study titled as “Recycling the purpose of old drugs to treat ovarian cancer” Ivermectin was putted as an option for the treatment of ovarian cancer. Ivermectin for the treatment of canine transmissible venereal tumor was not tried alone but in one study Ivermectin was used in combination with vincristine sulfate and the result indicates vincristine/ivermectin combination was efficacious against CTVT than vincristine alone, which indicate the promising effect of Ivermectin (Ferreira Bulhosa *et al.*, 2020; Nunes *et al.*, 2020; Tang *et al.*, 2020). The dose of Ivermectin was tried by 2mg/kg based on the reference by Tang *et al.* as the report of these author in individual trial Ivermectin 2 mg/Kg dosage has no serious adverse reactions rather the lethal dose (LD50) of IVM was 10-50 mg/Kg. The failure of the drug may associate with the severity of the disease, different unknown host factors and absence of the protocol that made before this study. The interval of the ivermectine was in a week difference which is also indicated in the work of Ferreira. To reduce the complications occurred related to the bleeding. Antibiotic was given because antibiotics led to temporary cessation of the discharge. This idea is supported by the study of Santiago-flores *et al* (Santiago-flores *et al.*, 2012; Ferreira Bulhosa *et al.*, 2020; Tang *et al.*, 2020).

Conclusion

Canine transmissible venereal tumor is a disease that should get enough attention and treated because treating the animal is one way of controlling and preventing such tumor. Therefore, the conventional treatment should be available on the market and we should look to other available and affordable treatments like Ivermectin because even in this trial Ivermectin wasn't give as much as required result, if the work is done in an organized way there will be a probability to make such treatment successful.

Acknowledgment

I am so grateful to Dr. Tilaye Demissie, Dr. Cheru Telila, Dr. Zerihun Mulatu and the owner of the animal.

References

- Abedin, S. (2012) 'Canine Transmissible Venereal Tumor: A Review', *The Internet Journal of Veterinary Medicine*, **6**(1), pp. 596–599.
- Beruktayet, W. and Mersha, C. (2016) 'Review of Cattle Brucellosis in Ethiopia', *Academic Journal of Animal Diseases*, **5**(2), pp. 28–39.
- Chanie, M. (2015) 'A Review on Canine Transmissible Venereal Tumor: from Morphologic to Biochemical and Molecular Diagnosis Effects of Adoption of Recommended Mastitis Control Procedures on Herd Milk Production and Incidence of Mastitis : a clinical trial study View project', **4**(3), pp. 185–195.
- Cho, D. *et al.* (2010) 'Quantitative rose bengal test for diagnosis of bovine brucellosis', *Journal of Immunoassay and Immunochemistry*, **31**(2), pp. 120–130.
- Chu, R. M. *et al.* (2001) 'Heat shock proteins in canine transmissible venereal tumor', *Veterinary Immunology and Immunopathology*, **82**(1–2), pp. 9–21.
- Das, U. and Das, A. K. (2000) 'Review of canine transmissible venereal sarcoma', *Veterinary Research Communications*, **24**(8), pp. 545–556.
- Ekiri, A. B. *et al.* (2020) 'Utility of the Rose Bengal Test as a Point-of-Care Test for Human Brucellosis in Endemic African Settings: A Systematic Review', *Journal of Tropical Medicine*, **2020**, pp. 1–20.
- Ferreira Bulhosa, L. *et al.* (2020) 'Vincristine and ivermectin combination chemotherapy in dogs with natural transmissible venereal tumor of different cyto-morphological patterns: A prospective outcome evaluation', *Animal Reproduction Science*. Elsevier, **216**(2020), pp. 1–13.
- Figueiredo, P. De *et al.* (2015) 'Pathogenesis and Immunobiology of Brucellosis Review of

- Brucella e Host Interactions’, *The American Journal of Pathology*. American Society for Investigative Pathology, **185**(6), pp. 1505–1517.
- Foster, R. A. (2017) ‘Chapter 19 - Male Reproductive System1’, in Zachary, J. F. (ed.) *Pathologic Basis of Veterinary Disease (Sixth Edition)*. Sixth Edit. Mosby, pp. 1194-1222.e1.
- Gahalot, S. C. (2019) ‘THERAPEUTIC MANAGEMENT OF TRANSMISSIBLE VENERAL TUMOR IN A BITCH: A CASE REPORT’, *International Journal of Science, Environment*, **6**(6), pp. 3346–3349.
- Hiblu, M. A., Khabuli, N. M. and Gaja, A. O. (2019) ‘Canine transmissible venereal tumor: First report of three clinical cases from Tripoli, Libya.’, *Open veterinary journal*, **9**(2), pp. 103–105.
- Khan, M. Z. and Zahoor, M. (2018) ‘An overview of brucellosis in cattle and humans, and its serological and molecular diagnosis in control strategies’, *Tropical Medicine and Infectious Disease*, **3**(65), pp. 1–14.
- Manish, K. *et al.* (2013) ‘Brucellosis: An updated review of the disease’, *Indian Journal of Animal Sciences*, **83**(1), pp. 3–15.
- Mukaratirwa, S. and Gruys, E. (2003) ‘Canine transmissible venereal tumour: Cytogenetic origin, immunophenotype, and immunobiology. A review’, *Veterinary Quarterly*, **25**(3), pp. 101–111.
- Nak, D. *et al.* (2005) ‘A clinico-pathological study on the effect of vincristine on transmissible venereal tumour in dogs’, *Journal of Veterinary Medicine Series A: Physiology Pathology Clinical Medicine*, **52**(7), pp. 366–370.
- Noeme Sousa Rocha, Tália Missen Tremori, J. A. M. C. (2014) ‘Fine Needle Aspiration Cytology in the Diagnosis of Canine Cutaneous Transmissible Venereal Tumor—Case Report’, *Journal of Veterinary Medicine*, **4**(9), pp. 204–209.
- Nunes, M. *et al.* (2020) ‘Recycling the purpose of old drugs to treat ovarian cancer’, *International Journal of Molecular Sciences*, **21**(20), pp. 1–24.

- o. M. Radostits (2010) *VETERINARY MEDICINE A textbook of the diseases of cattle, horses, sheep, pigs and goats*. 10th edn. Edited by o. M. R. C. C. G. K. W. H. P. D. Constable.
- Poester, F. P., Samartino, L. E. and Santos, R. L. (2013) 'Pathogenesis and pathobiology of brucellosis in livestock Pathogenesis of brucellosis infection in cattle', **32**(1), pp. 105–115.
- Purohit, G. N. (2012) 'Canine Transmissible Venereal Tumor: A Review', *The Internet Journal of Veterinary Medicine*, **6**(1), pp. 1–7.
- Santiago-flores, M. L. *et al.* (2012) 'Clinical Profile of Canine Transmissible Venereal Tumor Cases', *Philipp. J. Vet. Anim. Sci.*, **38**(1), pp. 63–72.
- Simoni, R. and Knoll, J. S. (2008) 'Canine transmissible venereal tumor: The cytologic clues', *Veterinary Medicine*, **103**(6), pp. 296–304.
- Sreekumar KS, P. N. and Ajidhan, and V. (2015) 'Case Study of Canine Transmissible Venereal Tumor', *EC Veterinary Science*, **2**(2), pp. 109–117.
- Sudjaidee, P., Theewasutrakul, P. and Techarungchaikul, S. (2012) 'Treatment of Canine Transmissible Venereal Tumor Using', *Thai J Vet Med. 2012.*, **42**(1), pp. 117–122.
- Swai, E. S. and Schoonman, L. (2010) 'The use of rose bengal plate test to asses cattle exposure to Brucella infection in traditional and smallholder dairy production systems of Tanga Region of Tanzania', *Veterinary Medicine International*, **2010**, pp. 1–8.
- Tang, M. *et al.* (2020) 'Ivermectin, a potential anticancer drug derived from an antiparasitic drug', *Pharmacological Research*, **163**(2021), pp. 1–12.
- Tella, M., Ajala, O. and Taiwo, V. (2010) 'Complete regression of transmissible venereal tumor (TVT)in Nigerian mongrel dogs with vincristine sulphate chemotherapy', *African Journal of Biomedical Research*, **7**(3), pp. 133–138.
- Tilahun, Alebachew *et al.* (2016) 'Review on Small Ruminant Brucellosis in Ethiopia', *Advances in Life Science and Technology*, **46**, pp. 16–24.

UÇAR, M. (2016) 'Transmissible Venereal Tumor: A Review', *Kocatepe Veterinary Journal*, **9**(3), pp. 230–235.

Wang, W. and Guo, Z. (2016) '[Brucella orchitis: A retrospective study of 69 cases].', *Zhonghua nan ke xue = National journal of andrology*. China, **22**(1), pp. 46–51.

5.8 Mechanical Disease

5.8.1 Sole ulcer in a dairy cattle

Abstract

Claw disorder is an underestimated problem but it can affect production efficiency of cows and sometimes it can lead to culling of affected animals. In my visit to one dairy farm that located in Bishoftu and communication with the farm attendants, lameness due to claw disorder was a major and frequent problem of the farm. According to the attendants the problem was widespread and it can affect the productivity of the farm and reaches up to slaughter in affected animals. Previously, the farm has routine hoof dipping protocol but in that instant the custom was discontinued. From this dairy cows the cow which discussed in this case report is one of the cows affected by this problem frequently. This cow showed the clinical sign of liming, pain and decreased appetite. On hoof examination the overgrown claw was trimmed from both side hooves and sole ulcer was found in deep investigation of right side lateral claw. Therefore oxytetracycline 100% powder was given and the area is wrapped by using bandage. After 3 days the bandage was removed and within a week the cow was fully recovered. Therefore as claw disorder is a significant disease in a dairy farm close follow up of animals, treating the affected cows early and taking good environment to the cow is very important.

Key Words: *Claw Disorder, Dairy cows, hoof trimming and Oxytetracycline*

Introduction

Foot and leg problems are the major disease in dairy, cow-calf and feedlot. Lameness is one of foot and leg problem characterize by painful condition associated with gait abnormalities and discomfort. Lameness has significant economic importance which expressed by decreasing fertility, reduction in milk yield, treatment cost and decreases carcass weight and value (Metre, Wenz and Garry, 2005; Alsaad, Fadul and Steiner, 2019).

Lameness and hoof lesions are multifactorial. Lameness can be caused in related to hygiene, nutrition, genetics, age, social rank, body condition, cow comfort, trimming and footbath routines. Lameness is also putted as one of the three most common disorders affecting dairy cows therefore it is a major animal welfare issue and affect cow's behavior. As the disease (Moreira *et al.*, 2019).

From multiple causes of lameness claw disorder can reach up to 90% (Bautista-Fernández *et al.*, 2021). Claw disorder often underestimated disease by the owners because unless the lesions are typically characterizing the disorder stay in sub-clinical stage and lameness is not an immediate sign but as the result of different studies the estimated prevalence of this disease range from 8% to 60% (Néstor Tadicha, Efrén Florb, 2010).

Claw disorder can be classified as infectious and non-infectious. Infectious disorders are caused by microorganisms such as bacteria, viruses and parasites. This group contain digital dermatitis (DD), interdigital dermatitis (ID) and foot rot and they are caused by *Treponema spp.*, *Dichelobacter nodosus* and *F. necrophorum* respectively (Berry, 2001; Moore, L. J., Woodward, M. J. and Grogono-Thomas, 2005). In the other side non-infectious claw disorder is mechanical injury without infection some of this disorder are traumatic injury such as interdigitalis hyperplasia and laminitis associated to metabolic disorder. Lameness has a clinical signs of sole ulcer, sole hemorrhage double sole white line disease and horn fissure or crack (Moreira *et al.*, 2019).

Treating claw disorder starts from a correct diagnosis of the case. The most common and first approach to this is trimming and debridement. Then after parenteral or topical administration of antibiotics careful bandage application will follow. Sometimes applying an orthopedic block is the suggestive way against this problem (Huxley *et al.*, 2014).

The prevention measures to be taken in claw disorder include early detection and diagnosis. But the specific measure differs based on the causative factors. In infectious type of claw disorder frequent cleaning for such concert type of floor and creating dry environment for straw yard floor system are important. In other way traumatic type of claw disorder needs proper building , routine hoof trimming and correcting diets are useful measures (Alvergnas *et al.*, 2019).

claw disorder] is not an easy thing if the case is not properly treated the condition can progress to bone, joints, tendons and ligaments (Metre, Wenz and Garry, 2005; Blowey and Weaver, 2011; Guard, Peek and Fecteau, 2018).

Claw disorder in dairy cows is a painful condition, is serious welfare issue and cause of high economic loss. Therefore the aim of this case report is to show the impact of claw disorder in dairy cow, the diagnostic approach and control and prevention measures.

Case description

Dairy farm industry is a common farming sector in Bishoftu, Ethiopia. From these farms I get a chance to visit one large scale dairy farm targeting to provide quality milk for the community. The farm has a free style housing system and deep litter flooring system. In my visit, the farm was found in a good situation but suffering by some common disease. From these diseases lameness due to claw disease was found as a headache of the farm. To prevent such condition the farm has a trend of hoof dipping. But in the time of my visit the trend has been stopped due to market problem therefore the case got aggressive and attack many cows. In severely affected cows the case reached up to slaughter. Cow with a tag number of 174 was one of these cows attacked by lameness. This cow was exhibiting clinical signs of limping, pain and loss of appetite two days prior to the examination date. The case was not new for this cow but was present 2 months ago and healed after the treatment but relapses again. On hoof examination the hind limbs was examined for abnormality and the overgrown claw was removed from both side hooves. In deep investigation the lateral claw of the right side hoof was found ulcerated (Figure 54C) but no interdigital lesion and swelling around the heel. Therefore based on history and the exhibiting clinical signs the case was tentatively diagnosed as claw disorder due to sole ulcer.

Differential diagnosis: Digital Dermatitis, Foot rot, Sole hemorrhage, Laminitis and White line disease.



Figure 54: Sole ulcer in cow (A); Lame limb and appearance of affected hoof (B); Trimming of hoof for both diagnosis and treatment purpose (C) ulceration in deep lateral claw indicated in arrow (D) Oxytetracycline powder on the affected hoof and (E) Wrapping of the hoof after treatment

Case management and outcome

To manage this case the first step was to know the exact location of the abnormality. Then to reach to that finding the hoof was trimmed properly and muted part was removed and depending on the diagnosis lateral claw of right side hoof was cleaned by using water and the oxytetracycline 100% powder (Dopharma) was applied to the area and was wrapped by using bandage (Blockit, Lauwtape flex) .Then after 3 days the bandage was removed and within a week the cow was fully recovered, appetite was returned back and the laming leg was started

to function properly. The farm was also resume its formalin dipping routine therefore the case had a low chance to be back.

Discussion

Claw health seems simple as it is used as cosmetic purpose only. But in this work it can be said that claw disorder is one of the biggest challenge of the farm which can reach up to slaughter of cows. Noordhuizen puts a good definition for this, it says: if there is no claws there will no cow (Alvergnas *et al.*, 2019).

There are many factors which used as differential diagnosis for lameness due to sole ulcer. The possible causes of lameness are studied and reviewed by different studies. the critical measures that were used to say lameness due to sole ulcer is history, anatomical position of the lesion, the removal of the routine of using formalin dipping and the response to the given drug (Randall *et al.*, 2016; Heringstad *et al.*, 2018; Bautista-Fernández *et al.*, 2021).

There are different risk factors that predispose cows to claw disorder. The first one is environmental factors. From these factors one is a type of floor. According to Somers for the overall health of the cow slatted floors are prefer than concrete floors and for the hoof health grooved floors are better. But generally floors of straw yards are generally considered as the best floor type. In opposite to this finding the occurrence of claw disorder found in deep litter flooring system this might related with the wetness of specific area (Somers *et al.*, 2003). The other environmental factor associated with claw health is management system. As the review of Adams zero grazing herd has higher risk to be affected both infectious and non-infectious lameness which found true for the present case where animals are managed intensively (Adams *et al.*, 2017).

To treat claw disorder in this dairy cattle oxytetracycline powder and bandage were used, according to Shearer soluble powder of tetracycline or oxytetracycline are frequently used medication against claw disease and bandage is also the recommended (Shearer, 2009).

Conclusion

Claw disorder is a significant disease in the dairy farms which can reach up to slaughter of the affected animal therefore preventive measures like formalin dipping and treating the animal by appropriate topical antibiotics can heal sole ulcer.

Acknowledgments

I am grateful to Dr. Mihret Teferi and Dr. Abenezer Tesfaye

References

- Adams, A. E. *et al.* (2017) ‘Associations between housing and management practices and the prevalence of lameness, hock lesions, and thin cows on US dairy operations’, *Journal of Dairy Science*, **100**(3), pp. 2119–2136.
- Alsaad, M., Fadul, M. and Steiner, A. (2019) ‘Automatic lameness detection in cattle’, *Veterinary Journal*. Elsevier Ltd., **246**, pp. 35–44.
- Alvergnas, M. *et al.* (2019) ‘Claw disorders in dairy cattle: Effects on production, welfare and farm economics with possible prevention methods’, *Livestock Science*, **222**, pp. 54–64.
- Bautista-Fernández, M. *et al.* (2021) ‘Claw disorders as iceberg indicators of cattle welfare: Evidence-based on production system, severity, and associations with final muscle pH’, *Meat Science*, **177**(2021), 1-10.
- Berry, S. L. (2001) ‘Diseases of the Digital Soft Tissues’, *Veterinary Clinics of North America: Food Animal Practice*, **17**(1), pp. 129–142.
- Blowey, R. W. and Weaver, A. D. (2011) ‘Chapter 7 - Locomotor disorders’, in Blowey, R. W. and Weaver, A. D. (eds) *Color Atlas of Diseases and Disorders of Cattle (Third Edition)*. Third Edit. Edinburgh: Mosby, pp. 99–146.
- Guard, C. L., Peek, S. F. and Fecteau, G. (2018) ‘12 - Musculoskeletal Disorders’, in Peek, S. F. and Divers, T. J. (eds) *Rebhun’s Diseases of Dairy Cattle (Third Edition)*. Third Edit. Elsevier, pp. 553–604.

- Heringstad, B. *et al.* (2018) ‘Invited review: Genetics and claw health: Opportunities to enhance claw health by genetic selection’, *Journal of Dairy Science*. American Dairy Science Association, **101**(6), pp. 4801–4821.
- Huxley, J. N. *et al.* (2014) ‘An update on the treatment of claw horn lesions in cattle’, *Veterinary Medicine: Research and Reports*, **6**, pp. 273–292.
- Metre, D. C. Van, Wenz, J. R. and Garry, F. B. (2005) ‘Lameness in cattle: rules of thumb’, *Annual Convention, American Association of Bovine Practitioners*, pp. 1–9.
- Moore, L. J., Woodward, M. J. and Grogono-Thomas, R. (2005) ‘The occurrence of treponemes in contagious ovine digital dermatitis and the characterisation of associated *Dichelobacter nodosus*’, *Veterinary Microbiology*, **111** (3-4). pp. 199-209.,
- Moreira, T. F. *et al.* (2019) ‘Risk factors associated with lameness and hoof lesions in pasture-based dairy cattle systems in southeast Brazil’, *Journal of Dairy Science*, **102**(11), pp. 10369–10378. \
- Néstor Tadicha, Efrén Florb, L. G. (2010) ‘Associations between hoof lesions and locomotion score in 1098 unsound dairy cows in the South of Chile.’, *The Veterinary Journal*, **184**(1), pp. 60–65.
- Randall, L. V. *et al.* (2016) ‘Lameness in dairy heifers; impacts of hoof lesions present around first calving on future lameness, milk yield and culling risk’, *Preventive Veterinary Medicine*. Elsevier B.V., **133**, pp. 52–63.
- Shearer, J. K. (2009) ‘CHAPTER 52 - Infectious Disorders of the Foot Skin’, in Anderson, D. E. and Rings, D. M. (eds) *Food Animal Practice (Fifth Edition)*. Fifth Edit. Saint Louis: W.B. Saunders, pp. 234–242.
- Somers, J. G. C. J. *et al.* (2003) ‘Prevalence of Claw Disorders in Dutch Dairy Cows Exposed to Several Floor Systems’, *Journal of Dairy Science*, **86**(6), pp. 2082–2093.

6. CONCLUSION AND RECOMMENDATIONS

These compiled case reports contain different types of diseases that affect various body systems of domestic animals in the study areas. The case report includes diseases that caused by both infectious and non-infectious agents as well as the presence, the spread and the impact of a particular disease in an animal or as a flock. Alongside, various disease diagnosis and treatment approaches as well as their follow up and prognosis until improvement made, were displayed. This case report mainly disclosed the potential diseases that have not got enough emphasis in our country and rational treatment approach to common and fatal diseases. Late hospital visit, premature treatment termination, lack of available and affordable diagnosis facilities, lack of treatment for uncommon diseases in the market and absence of adequate team work were among challenges encountered during this work. Therefore, depending on the conclusions the following recommendations were forwarded;

- ✚ Creating awareness to animal owners on how to handle their diseased animals,
- ✚ Regular training of animal health professionals on new developments about animal diseases, diagnosis and treatment approaches,
- ✚ Renovating of veterinary hospitals/clinics with up to date diagnostic tools such as imaging tools, kits for pet animal infectious diseases, rapid test kits and hematological machines
- ✚ The market should offer different drugs for different diseases therefore the professional have to contribute a significant role here,
- ✚ Encouraging team works between different veterinary specialists
- ✚ Policy makers and government bodies should give more attention to works at the clinic and hospital levels

7. ANNEXES

Annex 1: Principles of Clinical Examination

The clinical examination

The clinical examination ideally proceeds through a number of steps. The owner's complaint, the history of the patient, the history of the farm and the signalment of the patient are usually established at the same time by interview with the owner or keeper of the animal. Observations of the patient and environment are performed next. Finally a clinical examination of the patient occurs, followed by additional investigations if required.

Owner's complaint

This information usually identifies which individuals and groups of animals are affected. It may also indicate the urgency of the problem. The owner may include the history of the patient and the signalment in the complaint. Stockpersons usually know their animals in detail, and reported subtle changes in behavior should not be dismissed. However, pinions expressed regarding the etiology should be viewed with caution as these can be misleading. The extent of the problem or the exact nature of the problem may not be appreciated by the owner, and the clinician should attempt to maintain an objective view.

Signalment of the patient

Signalment includes the identification number, breed, age, sex, color and production class of animal. Some diseases are specific to some of these groupings and this knowledge can be useful in reducing the diseases that need to be considered.

History of the patient(s)

Disease information

Disease information should include the group(s) affected, the numbers of animal affected (morbidity) and the identities of the animals affected; the number of animals that have died (mortality) should be established. Information regarding the course of the disease should be obtained including the signs observed.

Risk factors

Possible predisposing risk factors should be identified. These may include the origin of the stock, current disease control programmes (vaccination, anthelmintic programmes, biosecurity) and nutrition.

Response to treatment

Clinical improvement following treatment may support a tentative diagnosis.

History of the farm

The disease history of the farm will indicate diseases that should be considered carefully and may indicate some of the local disease risk factors operating. The sources of information may include farm records, practice records, colleagues and the owner. Husbandry standards, production records, biosecurity protocols, vaccination and anthelmintic programs may all be relevant.

Observation of the environment

The environment in which the animals were kept at the time of the onset or just before the onset of the illness should be carefully examined. The animals may be housed or outside. Risk factors outdoors may include the presence of toxic material, grazing management, biosecurity and regional mineral deficiencies. Risk factors indoors may include ventilation, humidity, dust, stocking density, temperature, lighting, bedding, water availability, feeding facilities and fitments.

Observation of the animal at a distance

Ideally this procedure should be performed with the patient in its normal environment. This enables its behavior and activities to be monitored without restraint or excitement. These can be compared with those of other member of the group and relative to accepted normal patterns. However, sick animals have often been separated from their group and assembled in collecting yards or holding pens awaiting examination. Observations are most frequently made in this situation; they may include feeding, eating, urinating, defecation, interactions between group members and responses to external stimuli. The patient can be made to rise and walk. The posture, contours and gait can be assessed, and gross clinical abnormalities detected. Useful information is often derived from these observations and this stage in the clinical examination should not be hurried.

Detailed observations of the animal

Detailed observations can be made in docile animals without restraint; however, restraint may be necessary to facilitate this procedure. Closer observation of the patient may detect smaller and more subtle abnormalities.

Examination of the animal

Restraint is usually necessary for the examination and to ensure the safety of the animal and clinician. The clinical examination usually proceeds topographically around the animal, with clinicians starting at different points dependent upon personal preference. Each topographical area may encompass several components of the different body systems and these are examined concurrently. Frequently the topographical approach is used to identify major clinical abnormalities which are then examined in a more detailed manner using a systems approach.

Further investigations

Further investigations may be required before a diagnosis can be made. These may include laboratory tests, post-mortem examination, and a wide range of advanced techniques. Careful consideration should be given to the additional cost and what additional diagnostic or prognostic information will be gained from the additional procedures.

Annex 2: Techniques Used During a Physical Examination

Palpation (touching)

Changes in shape, size, consistency, position, temperature and sensitivity to touch (pain response) can be assessed by palpation.

Auscultation (listening)

Changes in the frequency, rhythm and intensity of normal sounds can be detected. Abnormal sounds can be identified. Stethoscopes are often used to increase the acuity.

Percussion (tapping)

The resonance of an object can be determined by the vibrations produced within it by the application of a sharp force. The sound produced provides information regarding the shape, size and density of the object.

Manipulation (moving)

Manipulation of a structure indicates the resistance and the range of movements possible. Abnormal sounds may be produced, and the pain produced in response to the movement can be assessed.

Ballottement (rebound)

This is performed by pushing the body wall sharply and forcefully so that internal structures are first propelled against the body wall then on recoil rebound against the operator's fingers. This enables the presence or character of an internal structure to be assessed.

Visual inspection

This is used to identify abnormalities of conformation, gait, contour and posture. Visual appraisal may help determine the size and character of a lesion.

Olfactory inspection

This is used to identify and characterize abnormal smells which may be associated with disease.

Annex 3: General approach to the clinical examination

The patient should always be treated humanely. A quiet word as the patient is approached will often help to reassure the animal and calm an anxious owner. A *thorough examination* of the patient should always be carried out. The consequences of not doing so can be embarrassing and potentially dangerous.

Respiratory rate

This should be counted over a period of 1 minute before the animal is caught or restrained for examination. Inspiratory or expiratory movements of the chest wall or flank can be counted. In cold weather exhaled breaths can be counted. If the animal is restless the clinician should count the rate of breathing for a shorter period and use simple multiplication to calculate the respiratory rate in breaths/minute. Mouth breathing is abnormal in cattle and is usually an indication of very poor lung function or a failing circulation.

Restraint for examination

The animal must be restrained so that it can be examined carefully, safely and with confidence. Calves are usually held by an assistant with one arm round their necks and may be backed into to a corner. Adult cattle can be restrained in a crush if available or (less satisfactorily) behind a swing gate. Quiet animals can be held using a halter or head collar. Unhandled cattle may be caught with a lasso if no crush is available. Additional control can be achieved using bulldogs or the nose ring in the case of a bull. An antikick bar may also be useful.

Chemical restraint

The use of a drug such as xylazine is helpful with nervous or difficult animals, but the restrictions of milk or meat withdrawal times must be observed.

Detailed observation

Once the animal has been restrained it should be visually examined more closely to see if any further abnormalities can be detected at close quarters. A small eye lesion that might not be spotted from a distance in an animal with profuse epiphora (excessive production of tears)

may now be readily visible. Any swelling or other lesions on the body seen earlier can now be inspected more closely and palpated.

Temperature

The body temperature is taken using a mercury or digital electronic thermometer placed carefully into the rectum. The thermometer should be lubricated before insertion and checked (in the case of a mercury thermometer) to ensure that the mercury column has been shaken down before use. It should be held whilst it is in the rectum. Sudden antiperistaltic movements in the rectum may pull the thermometer out of reach towards the colon. The thermometer is left in position for at least 30 seconds; the clinician should ensure the instrument is in contact with the rectal mucosa, especially if a lower than expected reading is obtained. The thermometer must be cleaned after removal from the patient. It must not be wiped clean on the patient's coat. If the animal's temperature is higher or lower than anticipated it should be checked again.

Pulse

The patient's pulse is taken from the caudal artery palpable along the midline of the ventral surface of the tail approximately 5 to 10cm from the tail head. Alternative sites are the median artery or the digital arteries of the forelegs. The median artery is palpable as it runs subcutaneously on the medial aspect of the forelimb at the level of the elbow joint. The digital arteries are palpable on the lateral aspect of the forelimb just caudal to the metacarpus. In calves the femoral artery can be used. It is located on the medial aspect of the thigh between the gracilis and Sartorius muscles. If a peripheral pulse is not palpable direct measurement of the heart rate can be used – by auscultating the heart and counting the beats per minute. There is a small chance of missing a pulse deficit by this latter method. The pulse rate can rise rapidly in nervous animals or those which have undergone strenuous exercise. In such cases the pulse should be checked again after a period of rest lasting 5 to 10 minutes.

Examination of the mucous membranes



Those of the eye can be demonstrated using the single or two handed technique. In both methods the eyelids are everted as the eye (protected by the eyelids) is gently pushed into the

orbit. The color of the mucosa of the conjunctiva is revealed. Alternative accessible mucosae are the vulva in the female and the mouth in both sexes. In some cattle black pigmentation makes assessment of the oral mucosal color in parts of the mouth difficult. The ocular and other visible mucosae should be salmon pink in color. *Pallor of the mucous membranes* may indicate anemia caused by direct blood loss or by haemolysis – in the latter case the pallor may be accompanied by jaundice. A *blue tinge* may indicate cyanosis caused by insufficient oxygen in the blood. A *yellow color* is a sign of jaundice. The mucosae may be *bright red* (sometimes described as being ‘injected mucous membranes’) in febrile animals with septicemia or viraemia. Bright red coloration of the conjunctiva is often seen, for example, in cases of bovine respiratory syncytial virus infection. A *cherry-red* coloration may be a feature of carbon monoxide poisoning. A *greyish tinge* in the mucosae may be seen in some cases of toxemia – such membranes are sometimes said to be ‘dirty’. High levels of methaemoglobin, seen in cases of nitrate and/or nitrite poisoning, may cause the mucosae to be *brown* colored.

Capillary refill time (CRT)

This is taken by compressing the mucosa of the mouth or vulva to expel capillary blood, leaving a pale area, and recording how long it takes for the normal pink color to return. In healthy animals the CRT should be less than 2 seconds. A CRT of more than 5 seconds is abnormal, and between 2 and 5 seconds it may indicate a developing problem. An increase in CRT may indicate a poor or failing circulation causing reduced peripheral perfusion of the tissues by the blood.

Annex 4: cELISA result of PPR suspected doe

	NATIONAL VETERINARY INSTITUTE		Document No. NVI-QMS-QF-158	
			Title Laboratory Test Result Report Form	Effective Date 15/04/2019

Client Name: Dr. Bethel, Gishu & Tolosa

Tel:

Client address: Bishoftu/DebreZeit

Test Report No: SE024/21

Sample History	Animal species	Sample type	Number of Samples	Origin of animals	Sample. Ref. No.
	Shoats	Serum	3		SE132/21

Samples Collected By: Customer

Date of sample collection: 15/05/21

Date of Sample Submission to lab: 08/06/21

Date of Test Conducted: 14/06/21

Date of Test Report: 23/06/21

Test Method used

C-ELISA

Purpose: To Detect antibody specific to PPRV antigen

Criteria for positive result:

Test result:

Number of Positive Samples	Number of Negative Samples	Total Number Tested
3	0	3

ID of Positive samples: **BG, 90 & TPP**

Opinion and Interpretation: NA

**This test result is related only to sample Reference Number mention on this Laboratory test result report form*


Tested By:

Checked By:

Approved By:

Name: Wubet W/Medihin (Senior Researcher) Abinet Legesse: (Senior Researcher) Dr. Belayneh Getachew (TM)

Signature: 







Tel. +251-114-338411 Fax: +251-1-339300 E-mail: nvi-rt@ethionet.net Website: <http://www.nvi.com.et> P.O.Box:19, Debre-Zeit, Ethiopia

Annex 5: Blood chemistry result of urinary incontinent bitch

Test Report
 Hospital: Dr. Ammanuel Clinic
 Print date: 27.05.2021
 Sample No: 24
 Name: Esheta
 Sex: Female
 Age: 5
 Species: Canine
 Laboratory: General

A veterinary Teaching Hospital
 Laboratory test order Format
 Requested (veterinarian): Dr. P. Shete
 Species: Canine

Circle the

TEST	Result
Hb(g/dl)	97.75mg/dL
PCV(%)	70.000-105.000
MCV(fL)	0.285mg/dL
MCH(pg)	0.000-1.200
MCHC(g/dl)	7.586g/dL
RBC count	6.600-0.790
ESR	29.416mg/dL
Platelet count	18.000-45.000
	*1.324mg/dL H
	0.600-1.300

HEMATOLOGY

TEST	RESULT	TEST	RESULT
Count (TLC)		Blood Smear	
ng/dL)		Thin smear	
tial		Thick smear	
unt)		Gram stain	
s		Giemsa stain	
		Haemoparasite exam.	
		Others (specify)	

Biochemistry

TEST	RESULT	TEST	RESULT
Albumin (g)		Electrolytes (mmol/l)	
Globulin (g/l)		Sodium (Na)	
Total protein (g/l)		Potassium (K)	
Total bilirubin (μmol/l)		Chloride (Cl)	
Direct creatinine (μmol/l)		Magnesium	
Urea (mmol/l)		Calcium	
Glucose (mmol/l)			

glutamate dehydrogenase (GLDH) (iu/l)
 gamma glutamyl transpeptidase (GGT) (iu/l)
 ALT (alanine aminotransferase) or SGPT (iu/l)
 Alkaline phosphatase (AP) (iu/l)
 Creatine phosphokinase (CPK) (iu/l)
 AST (aspartate aminotransferase)/SGOT (iu/l)

Remarks (if any)

Urinalysis tests

TEST	RESULT	TEST	RESULT	TEST	RESULT
Color		Red blood cells		Granular casts	
quantity		Pus cells		Hyaline casts	
PH		Epithelial cells		Crystals	
Albumin		Viable bacteria		Specific gravity	
Glucose		Mucus		Nitrites	
Bilirubin		Haemoglobinuria		Others (specify)	
Ketones		Heavy metals (Pb, F, HG)			

Remarks (if any)

Annex 6: Normal Hematological and organ function tests in domestic animals



Card for Laboratory Test Order: **Haematology**

Date: _____

Owner's name: _____ Species: _____

Case No.: _____

Requested Test	Reported Lab Finding	Normal values				
		Cattle	Sheep	Goat	Dogs	Cats
Haematology						
• Haemoglobin (g/dL)		8.0-15.0	9.0-15.0	8.0-12.0	12.0-18.0	8.0-15.0
• Haematocrit (PCV) (%)		24.0-46.0	27.0-45.0	22.0-38.0	39.4-56.2	33.6-50.2
• RBC ($\times 10^6/\mu\text{L}$)		5.0-10.0	9.0-15.0	8.0-18.0	5.5-8.5	5.0-10.0
• MCV (fL)		40.0-60.0	28.0-40.0	16.0-25.0	65.7-75.7	42.6-55.5
• MCH (pg)		11.0-17.0	8.0-12.0	5.2-8.0	22.6-27.0	13.4-18.6
• MCHC (g/dL)		30.0-36.0	31.0-34.0	30.0-36.0	34.3-36.0	31.3-33.5
• Thrombocytes ($\times 10^3/\mu\text{L}$)		100-800	250-750	300-600	290	370
• Fibrinogen (mg/dL)		200-700	200-500	200-300	150-300	150-300
• WBC ($\times 10^3/\mu\text{L}$)		4.0-12.0	4.0-12.0	4.0-13.0	5.5-19.5	4.0-12.0
• Differential WBC Count		15-45	10-50	30-48	60-70	35-75
• Neutrophils (mature) %						
• Neutrophils (band) %		0-2	0	Rare	0-3	0-3
• Lymphocytes %		45-75	40-75	50-70	12-30	20-55
• Monocytes %		2-7	0-6	0-4	3-10	2-7
• Eosinophils %		2-20	0-10	1-8	2-10	2-12
• Basophils %		0-2	0-3	0-1	Rare	Rare
• Other (e.g. haemoparasite):						



Card for Laboratory Test Order: **Organ Function**

Date: _____

Owner's name: _____

Species: _____

Case No.: _____

Renal function						
• Urea nitrogen (mg/dL)		6.0-27	8.0-20	12-26	8-27	15-35
• Creatinine (mg/dL)		1.0-2.0	1.2-1.9	0.6-1.6	0.5-1.6	0.5-2.3
Liver function						
• Total bilirubin (mg/dL)		0.01-0.5	0.1-0.5	-	0-0.2	0.1-0.5
• Conjugated bilirubin (mg/dL)		0.04-0.44	0-0.27	-		
Protein						
• Total protein (g/dL)		5.7-8.1	6-7.9	6.2-7.9	5.5-7.2	5.4-8.9
• Albumin (g/dL)		2.1-3.6	2.4-3	2.9-4.3	2.8-4.0	3.0-4.2
Metabolites						
• Glucose (mg/dL)		45-75	50-80	-	73-116	63-150
• Cholesterol (mg/dL)		65-220	43-103	-	138-317	42-265

Annex 7: Clinical case recording format

ADDIS ABABA UNIVERSITY
COLLEGE OF VETERINARY MEDICINE AND AGRICULTURE
Daily Clinical Activity Recording Form

Date: -----

Site/Name of the clinic _____ Address _____

Owner's name _____ Address _____ Phone number _____

Patient identification:

Species _____, Breed _____, Sex _____, age _____, Color _____

Markings (Ear tag no) _____

History: past immediate, environment, management, feeding and no affected, no at risk, place of origin etc. _____

General physical examination: temperature, heart rate, respiratory rate, rumen motility, visible mucous membrane etc...

Systemic physical examination: detailed examination of the affected system _____

Laboratory diagnosis methods employed Tentative and definitive diagnosis, prognosis _____

Treatment: drug, dose, route, regime, follow-up _____

Control & prevention: control methods prescribed, prevention and corrective management measures recommended _____

Annex 8: Normal body parameters according to standard veterinary treatment guideline

Normal Body Temperature

Animal	°C±0.5°C
Horse	38.0
Cow	38.5
Sheep	39.5
Goat	39.0
Pig	39.0
Dog	39.0
Cat	38.5
Rabbit	39.3

Normal Respiratory Rate

Animal category/spp.	Rates per minute	Animal category /spp.	Rate per minute
Foal	14-15	pig	10-12
Horse, adult	9-10	Dog, young	20-22
Calf, newborn	56	old	14-16
2 wks	50	cat	20-30
5 wks	37	Rabbit	50-60
6 mo	30	Guinea-pig	100-150
yearling	27	Camel	5-12
Cattle, adult	12-16	Chicken	15-30
Lamb/kid	12-20	turkey	12-16
Sheep/Goat, adult	12-15	Duck	16-28
Old	9-12	Goose	12-30

Normal Heart Rate

Animal category/app.	Pulse/min.	Animal category/app.	Pulse/min.
Foal, newborn	128	Sheep/Goat, yearling	85-100
• 1-2 days	100-128	• adult	70-80
• 1-2 weeks	80-120	• old	55-60
• 3-6 month.	64-96	Piglets, newborn	130-140
• 6-12 month.	48-72	Piglets, 12-14wk.	110-115
• 1-2 year	40-56	Pig	
Horse, adult,		• adult sow	85-95
• Stallion	28-32	• boar	60-70
• Mare/MC*	33-40	Dog,	
Ass/Mule,		young	110-120
• young	65-75	adult, 5m	80-120
• Adult	45-60	adult, 1 year	60-80
Calf, newborn	115-140	Cat, young	130-140
• 1-2 weeks	108	Cat, adult	100-120
• 1-2 months	100-105	Rabbit	120-150
• 3-6 months	95-100	Camel	30-50
• yearling	90	Elephant	25-30
Cow, adult	40-60	Chicken	180-440 (312 average)
Ox*, adult	35-70	Lamb/kid	110-120

* male castrate

Annex 9: Case report writing format

Table 2. Checklist for writing case reports (based on advice in existing literature).²⁷

Title

Should be brief and informative.

Abstract

Should facilitate retrieval with electronic searching.

Has a word limit of 100 words or less.

Introduction

Should be concise and attract the reader's attention.

Describe the uniqueness of the case and how the case contributes to the existing literature.

Is the message new and relevant to the medical imaging specialists?

Case report

Clearly describe the current medical condition and medical history in chronological order.

Provide details of the clinical presentation and examinations, including those from imaging and laboratory studies.

Describe the treatments, follow-up, and final diagnosis adequately.

Discussion

Summarize the essential features and compare the case report with the literature.

Explain the rationale for reporting the case.

State the lessons/experiences that may be learnt from the case report, and how things can be managed differently in a similar situation/case.

References

Should be relevant to the topic.

Limited to less than 15.

Figures and tables

Limited to one table, and two to three figures.

Illustrations should be effective.

8. APPENDIX

Result for plagiarism checking



Document Information

Analyzed document	Bethel Befekadu.pdf (D111171390)
Submitted	8/11/2021 3:09:00 PM
Submitted by	
Submitter email	abdi.feyisa@aaau.edu.et
Similarity	2%
Analysis address	abdi.feyisa.aauni@analysis.orkund.com

Sources included in the report

W	URL: http://etd.aau.edu.et/bitstream/handle/123456789/12161/ABDI%20THESIS%20FINAL2018.pdf?sequence=1&isAllowed=y Fetched: 6/14/2021 6:22:53 AM		16
SA	University of Addis Ababa / Dese Keyfalew thesis.pdf Document Dese Keyfalew thesis.pdf (D76393384) Submitted by: hagosashenafi@aaau.edu.et Receiver: hagosashenafi.aauni@analysis.orkund.com		1
SA	University of Addis Ababa / Final MVSC Thesis habtamu.docx Document Final MVSC Thesis habtamu.docx (D79371210) Submitted by: shimels.tesfaye@aaau.edu.et Receiver: shimels.tesfaye.aauni@analysis.orkund.com		1
W	URL: https://www.researchgate.net/publication/298494606_Performance_of_subacute_ruminal_Lacidosis_in_dairy_herds Fetched: 3/5/2020 5:54:00 PM		1
SA	University of Addis Ababa / MSc Thesis. Dessalew Habte (2021)_Plagiarism Check.docx Document MSc Thesis. Dessalew Habte (2021)_Plagiarism Check.docx (D108814449) Submitted by: takele.beyene@aaau.edu.et Receiver: takele.beyene.aauni@analysis.orkund.com		1
W	URL: https://archive.org/stream/ClinicalHandbookOfInfectiousDiseases/Clinical%20Handbook%20of%20Infectious%20Diseases_djvu.txt Fetched: 9/27/2019 2:42:42 PM		1
W	URL: https://alonot.com/english/wp-content/uploads/2019/03/STG-For-Veterinary-Clinics-book.doc Fetched: 11/21/2019 4:04:33 PM		1
SA	University of Addis Ababa / Sisay's MSc Thesis.docx Document Sisay's MSc Thesis.docx (D109144475) Submitted by: debebe.ashenafi@aaau.edu.et Receiver: debebe.ashenafi.aauni@analysis.orkund.com		4
SA	University of Addis Ababa / Getachew Ngusie's MVSc Thesis--1.pdf Document Getachew Ngusie's MVSc Thesis--1.pdf (D76901887) Submitted by: hagosashenafi@aaau.edu.et Receiver: hagosashenafi.aauni@analysis.orkund.com		2