

**ADDIS ABABA UNIVERSITY**  
**COLLEGE OF HEALTH SCIENCES**  
**SCHOOL OF MEDICINE**  
**DEPARTMENT OF INTERNAL MEDICINE**



CLINICAL AND IMAGING CHARACTERIZATION OF PAIENTS WITH FOCAL LIVER LESIONS WITH EMPHASIS ON HEPATOCELLULLAR CARCINOMA AT TIKUR ANBESSA SPECIALIZED HOSPITAL (TASH) FROM AUGUST 1, 2019 TO JULY30, 2020.

THESIS SUBMITTED TO THE DEPARTEMENT OF INTERNAL MEDICINE, ADDIS ABABA UNIVERISTY COLLEGE OF MEDICINE AND HEALTH SCIENCE, IN PARTIAL FULFILEMENT OF THE REQUIREMENTS FOR SPECIALITY CERTEFICATE IN INTERNAL MEDICINE

**ADDIS ABABA, ETHIOPIA.**

**DECEMBER, 2020**

**ADDIS ABABAUNIVERSITY**

**Investigator:** Amare Woldie (Final year internal medicine resident)

Email address: [amare.woldie@yahoo.com](mailto:amare.woldie@yahoo.com).

Phone No: +251911805804

**Advisors:** Dr. Dr.Amir Sultan (Internist, consultant Gastroenterologist and hepatologist)

## **Acknowledgement**

I would like to express my sincere and deepest gratitude to **Dr. Amir Sultan** for his valuable, fruitful and continuous support through the conceptualization, preparation, and editing of the research project proposal to this final thesis. I would also like to acknowledge Addis Ababa University, college of health sciences for providing me the opportunity to undergo this research project by provide the necessary funding. I would like to thank Tikur Anbessa Specialized hospital (TASH) GI unit and the nursing staffs which were very cooperative and helpful in providing all the necessary records that enabled me to get basic data. Finally I am great full to the department of internal medicine for organizing and mentoring the study process.

## Abbreviations and Acronyms

AAU: Addis Ababa University

TASH: Tikur Anbessa Specialized Hospital

FLL: Focal liver lesion

CT: Computer tomography

MRI: Magnetic resonant imaging

U/S: Ultrasound

FNAC: Fine needle aspiration cytology

GI: Gastrointestinal

LFT: Liver function test:

AFP: Alpha fetoprotein

HBV: Hepatitis B virus

HCV: Hepatitis C virus

CBC: Complete blood count

CA19-9: Carbohydrate antigen 19-9

CEA-19: carcinoembryonic antigen 19

GC: Gregorian calendar

FNH: Focal nodular hyperplasia

Lab: Laboratory PLA: Pyogenic liver abscess

INR: internationalized normalized

HCC: hepatocellular carcinoma

DM: diabetes mellitus

COR: crude odds ratio

AOR: adjusted odds ratio

## Abstract

**Background:** The accurate and reliable determination of the nature of the liver mass is critical, not only to reassure individuals with benign lesions but also, and perhaps more importantly, to ensure that malignant lesions are diagnosed correctly. Accurate diagnosis allows the appropriate selection of optimal management.

**Objective:** This study was aimed to assess clinical and imaging characterization in patients with focal liver lesions with emphasis on HCC at Tikur Anbessa specialized hospital (TASH) from August 1, 2019 to July 30, 2020.

**Method:** Institution based descriptive and retrospective study was conducted from August 1, 2019 to July 30, 2020. A total of 135 patients with imaging result of focal liver lesion were included in the study data was collected using standardized questionnaire. Clinical and imaging pattern was assessed from records. Summary statistics like mean and median were computed. Both bivariate and multivariate logistic regression was fitted to identify associated variables. A 95% confidence interval odds ratio (OR) was computed and considered variables having p - value less than 0.05 in the multi variable model as significantly associated with the dependent variables.

**Result:** A total of 135 patients were included in the study. The mean age was 49.83(SD 13.866) years. Most of the patients were from Addis Ababa and Oromia (82.3%). Majority of lesions in this study were malignant (81%), hepatocellular carcinoma (63%) and hemangioma (29.9%) being the commonest malignant and benign lesions respectively. Many of the lesions were solitary (62%) and size  $\geq 5$ cm. right lobe was mostly involved (57.1%). Abdominal pain was the commonest presentation (74.8%) in most of the patient. HBV (22.2%) and HCV(7.4%) infection was significantly associated with hepatocellular carcinoma among the risk factors.

**Conclusion:** Majority of lesions in this study were malignant and solitary. Hepatocellular carcinoma and hemangioma were commonest malignant and benign lesions respectively. Right lobe was mostly involved and abdominal pain was the commonest presentation in most of the patient. Among the risk factors HBV and HCV infection was significantly associated with hepatocellular carcinoma.

**Grant source:** Addis Ababa University, college of health sciences, school of medicine

**Key words:** clinical, imaging, characterization, focal liver lesions, Ethiopia.

## Contents

Acknowledgement .....	i
Abbreviations and Acronyms .....	ii
Abstract .....	iii
List of tables and figures .....	v
Introduction .....	1
1.1 Background .....	1
1.2 Statement of the problem .....	4
1.3 Significance of the study .....	4
2. Literature review .....	5
1.3. Justification .....	17
3. Objectives .....	18
3.1 General objective .....	18
3.2 Specific objectives .....	18
4. Methodology .....	19
4.1 Study area.....	19
4.2 Study period.....	19
4.3 Study Design.....	19
4.4 Source Population .....	19
4.5 Study population .....	19
4.6 Inclusion and exclusion criteria for patients .....	19
4.6.1 Inclusion criteria .....	19
4.6.2 Exclusion criteria .....	19
4.7 Study Variables.....	20
4.7.1 Dependent variables.....	20
4.7.2 Independent variables .....	20
4.9 Sample size and Sampling technique.....	21
4.10 Data collection method .....	22
4.10.3 Data analysis and presentation .....	22
5. Ethical consideration.....	23
6. Dissemination of the results.....	23
7. Results.....	24

8. Discussion.....	33
9. Recommendation: .....	35
10. Limitation of the Study .....	35
11. References.....	36
ANNEX.....	42

### List of tables and figures

Table 1: Frequency of Sociodemographic factors.....	30
Table 2: Frequency of clinical presentations.....	32
Table 3: Frequency of laboratory parameters.....	33
Table 4: Ultrasound imaging pattern.....	34
Table 5: CT scan imaging pattern.....	35
Table 6: Pattern of risk factors identified.....	37
Table 7: Bivariate logistic regression showing the association of independent variables on hepatocellular carcinoma.....	37
Table 8: Multivariate logistic regression showing the association of independent variables on hepatocellular carcinoma.....	38
Figure 1: Conceptual frame work of focal liver lesions and associated risk factors in patients with focal liver lesions.....	22
Figure 2: Distribution of age group.....	31
Figure 3: Distribution of sex.....	31
Figure 4: Distribution of address.....	31

# **Introduction**

## **1.1 Background**

Liver masses present a relatively common clinical dilemma, particularly with the increasing use of various imaging modalities in the diagnosis of abdominal and other symptoms(1). The accurate and reliable determination of the nature of the liver mass is critical, not only to reassure individuals with benign lesions but also, and perhaps more importantly, to ensure that malignant lesions are diagnosed correctly(1–4).

This avoids the devastating consequences of missed diagnosis and the delayed treatment of malignancy or the unnecessary treatment of benign lesions with appropriate interpretation of the clinical history and physical examination, and the judicious use of laboratory and imaging studies, the majority of liver masses can be characterized noninvasively. Accurate characterization of liver masses by cross-sectional imaging is particularly dependent on an understanding of the unique phasic vascular perfusion of the liver and the characteristic behaviors of different lesions during multiphasic contrast imaging(1–4).

In the past decades ultrasound has been utilized extensively for the evaluation of various body parts. Abdominal ultrasound is one of the most commonly used imaging modalities in clinical medicine. With the decrement in cost and ease of use, it has become available in different remote areas of the world. In addition since it does not expose the patient for harmful radiation or doesn't use much consumable to run, it is widely preferred in poor countries. The learning curve for training of ultrasound is also not steep making it friendly across different specialties. However there is considerable interobserver variability limiting it as a universal tool(5–10).

In contrast, CT scan and MRI are relatively newer and more expensive imaging tools. In particular CT is associated with radiation risk to the patient and complications with contrast material used for the investigation. MRI is more expensive, cumbersome and contraindicated in

selected group of patients. Both however have a better sensitivity and specificity compared to ultrasound in the evaluation of focal hepatic lesions(11–13).

Focal liver lesions have different causes. Common conditions include Hemangioma, benign liver tumors, malignant liver tumors, Cysts, abscess, metastases. Different studies have reported different prevalence rates for these conditions(1).

In Ethiopia the most widely used tool to evaluate focal liver lesions is ultrasound. It is available in most parts of the country. Evaluation is usually done by radiologists or radiographers. There are no published studies from this country detailing the individual prevalence rates of the above stated conditions. As is observed elsewhere, hospital based versus community based studies might yield very different results. Additional imaging tools like CT and MRI are not commonly available to most patients. Such investigations are only provided in big government or larger private hospitals only. In addition the cost is prohibitive to most patients.

In patients with focal liver lesions, detected incidentally or due to clinical symptoms, non-invasive characterization is important. If malignancy is suspected, exact assessment of the Tumor burden by detection of all liver lesions is needed. It has been shown that MRI with liver specific contrast agents is superior to contrast-enhanced CT in terms of lesion characterization. In particular, MRI with liver-specific agents is superior to CT for differentiation between hepatocellular and non-hepatocellular lesions, with an accuracy of 90% versus 64%(14).

With the high prevalence rate of viral hepatitis and exposure to toxins, there is a high incidence of primary malignant liver disorders like hepatocellular carcinoma. No population based study has been conducted to date and most clinical characterizations have been retrospective in nature. Understanding the clinical features of such patients is very important because it has implication in terms of management and surveillance programs. Observation of patients in Tikur Anbessa hospital is that patients tend to present at a later stage of malignancy which rules out surgery as a therapeutic modality. In addition patients tend to come with advanced cirrhosis as a risk factor. This is a potentially manageable group with institution of strong surveillance program(15–19).

Differentiation between metastases and benign hepatocellular lesions (e.g. focal nodular hyperplasia (FNH)) is achieved with high accuracy. Thus, contrast-enhanced MRI is the technique of choice to characterize equivocal lesions detected at US without wasting time and resources with multiphase CT(6).

Several studies have shown that contrast-enhanced MRI is superior to helical and MDCT in the detection of liver metastases. In the subgroup of patients with small liver metastases (up to 1 cm), MRI proved to be particularly superior to CT. MRI even outperforms PET/CT in patients with colorectal cancer metastases. It has been shown that contrast enhanced MRI is more cost effective than contrast enhanced CT in the evaluation of patients scheduled for liver segment or lobe resection, as additional information provided by MRI may prevent surgical intervention in 33%(6).

When non-invasive characterization is indeterminate, a liver biopsy may be necessary for definitive diagnosis. Standard histologic examination is usually complemented by immunohistochemical analysis of protein biomarkers. Accurate diagnosis allows the appropriate selection of optimal management, which is frequently reassurance or intermittent follow up for benign masses. For malignant lesions or those at risk of malignant transformation, management depends on the tumor staging, the functional status of the uninvolved liver and technical surgical considerations(1,2,14).

Hepatocellular carcinoma (HCC) is a major cause of cancer death worldwide accounting for over half a million deaths per year and its incidence is reported to be increasing in resource-limited countries. It is caused by viral hepatitis, HBV or HCV or other causes of Cirrhosis (alcoholism being the other most common cause). It is preventable hepatic malignance if there is proper screening and early identification and treatment of risk factors(20–22).

## **1.2 Statement of the problem**

Liver lesions are detected through radiographic imaging. But it can be extremely difficult to differentiate a benign liver lesion from a malignant liver lesion. This presents a major diagnostic challenge, making liver lesions easy to misdiagnose. A misdiagnosis can be extremely dangerous and even life-threatening, as the treatment varies greatly for each particular type of liver lesions(23). 23% of patients diagnosed with liver cancer don't accurately have cancer at all. Patients misdiagnosed with liver cancer may receive debilitating treatments that are unnecessary and expensive, while cancerous liver lesions misjudged for benign lesions will have the opportunity to grow and advance into late stage cancer. To prevent diagnostic errors, it is recommended that patients diagnosed with a liver lesion get a second opinion on their medical scans.

## **1.3 Significance of the study**

The study will try to characterize patients with focal liver lesions clinically and with imaging like ultrasound, CT scan, MRI. Only few studies had been published in Ethiopia so far so, the study will generate new data. These data are very important because management of patients with malignant liver conditions is currently lagging behind because of late presentation. In addition depending on the result of the study, patients with malignant condition will be assessed further as to their outcomes. Recommendations will be forwarded for improvement of patient care with regards to clinical management.

## **2. Literature review**

Different authors use various methods to classify focal liver lesions for study purposes. Majority depends on the prevalence of the individual disease entities and availability of additional imaging tools and tissue diagnosis. In this proposal common focal liver lesions will be considered, imaging (ultrasound, CT scan, MRI, others) and clinical characterization will be discussed in the literature review. Further emphasis will be given to hepatocellular carcinoma with regards to clinical profiles.

### ***Hemangioma***

Hepatic hemangioma is common findings in general population. Estimated prevalence of hemangioma is around 7% of the population with female predominance. Most are asymptomatic and solitary in presentation and most often being discovered incidentally during imaging investigations for various unrelated pathologies. . However around 10 % of the cases can be multiple in appearance. Progression of hemangioma to malignant state is very rare. The frequency is higher among adults, with a prevalent age at the initial diagnostic in the range of 30-50 years(1,24–26).

Hemangioma typically appears as a well-defined, homogeneously hyper echoic mass with posterior acoustic enhancement on ultrasound, Well demarcated hypo-dense masses on CT scan and well-defined, smooth, homogenous lesion, hypo intense on T1 and hyper intense on T2 weighted MRI images. In multiphasic CT or MR imaging studies, they show a typical peripheral nodular enhancement in the arterial phase with progressive centripetal filling in towards the center of the mass in the portal venous, and delayed phases(1,24–26).

### ***Hepatic cysts***

Simple hepatic cysts are common in the evaluation of the abdomen. They are the most commonly encountered hepatic lesion, occurring in 2.5% of the general population, and have a slight predominance in females (female-male ratio, 1.5:1). They are also thought to be of biliary origin as a result of deranged development of the biliary tree. They have a thin wall with characteristic distal acoustic enhancement. The margins are smooth and the content of the cyst is

echo free. Simple cysts do not have septations. Most do not have clinical significance but others might occur in conjunction with polycystic kidney disease(1).

Among infectious causes the important ones are hydatid cysts. Hydatid cyst is caused by parasite *Echinococcus granulosus* and *multilocularis*. The liver is the commonest site affected followed by the lung. Cysts can have different appearance on ultrasound depending on the stage and viability of the organisms. Usually the cyst is well outlined and with distal acoustic enhancement. Cysts might be demonstrated with in the cyst itself, known as daughter cysts. Additionally debris might collect inside the cysts giving a heterogeneous appearance. The other variants might have calcifications, either focally or completely. Such appearance indicates non-viable cysts. Rupture of cysts is a serious complication as this might lead to anaphylactic shock(27–29).

It is mainly found in the liver (75% of the cases), being asymptomatic in most cases and discovered accidentally on a routine abdominal ultrasound or an ultrasound performed for diagnosing other pathologies.

Typical imaging features are; membranes, septatae and hydatid sand within the cyst on ultrasound. Although ultrasound is the initial diagnostic tool for HD, CT is more useful in terms of revealing calcification and detecting daughter cysts and therefore is regarded to be more sensitive and accurate than US in the differential diagnosis. Typical CT findings include sharply defined, single or multiple, round or oval cystic masses with fluid attenuation values (3-30 HU) and a thin high attenuation rim that usually does not enhance after the administration of contrast material. Daughter cysts may produce a multi-loculated appearance. Separation of the laminate membrane from the peri-cyst produces a split-wall or floating-membrane appearance. This separation does not necessarily indicate death of the parasite. On MRI, hydatid cysts typically appear as multi-loculated or multi-cystic, with a hypo intense rim on T2 weighted images(1).

### ***Hepatic Abscesses***

Hepatic abscesses can be caused by bacterial or amebic infection. Pyogenic bacterial liver abscesses are usually caused by rupture or leak of the bile duct or bowel. They may be associated with biliary stenting, biliary instrumentation, or trans-arterial chemoembolization of tumor

nodules. There is an increased risk of pyogenic abscess in patients with immunosuppression states like diabetes mellitus and intra-abdominal infections. They are caused by enteric gram negative organisms. 75% of pyogenic liver abscess are solitary but most are central than peripheral in the liver(30–32).

Recently, the etiologies of PLA have shifted from intra-abdominal infections such as acute appendicitis and trauma to pathologic conditions of the biliary tract; however, up to 55% of patients with PLA have no clear risk factors and these cases are called cryptogenic.

The incidence of PLA varies from 8 to 22 patients per 1,000,000 people belonging to a geographical area with substantially higher rates having been reported in Taiwan(31,33).

At US, micro-abscesses (<2 cm) appear as hypo-echoic nodules or ill-defined areas of distorted hepatic echogenicity. Large abscesses range from hypo-echoic to hyper-echoic masses, depending on the presence of internal echoes due to thickened septa and debris. Because echogenicity varies, a pyogenic abscess may simulate a solid lesion. The most common finding at contrast-enhanced CT is a well-defined, low-attenuation, round mass with an enhancing peripheral rim. Abscesses can manifest as a single non-loculated fluid collection, a single multi-loculated cystic mass, a solid (phlegmuous) process, or multifocal lesions. The “double target sign” is a characteristic imaging feature of hepatic abscess seen on contrast-enhanced CT images. At MR imaging, abscesses typically show central low T1-weighted and high T2-weighted signal intensity(1,23,30).

Amebic liver abscess are common in tropical countries and caused by *Entameba Histolytica*. Most patients have preceding GI symptoms, and common presenting features are RUQ pain and fever. 75 % of amebic liver abscess are single where as some others might be multiple. Right lobe of the liver is affected predominantly because of the portal drainage system. Characteristically such abscesses are sub capsular in location(34,35).

The imaging features of hepatic abscesses are dependent on th evolution of the abscess. At earlier stages, abscesses are usually semi-solid and irregular with areas of necrosis, and therefore show variable enhancement. Mature abscesses have large central necrotic area and a variable rim of granulation tissue and capsule comprising hepatocytes and fibrous tissue. Imaging of early

stage abscesses may show poorly-defined masses with heterogeneous enhancement; this changes to a well-defined rounded mass when the abscess is mature(1).

By ultrasonography mature abscesses are not as completely free of echoes as simple hepatic cysts, but nevertheless do not have blood vessels or bile duct structures running through them, On CT, pyogenic liver abscesses appear as loculated, single or multiple lesions with heterogeneous and variable thickness rim enhancement, whereas amoebic liver abscesses tend to be single with a thin enhancing rim and surrounding hypo-density referred to as the halo sign. Mature abscesses usually do not show internal enhancement. They are bright on T2-weighted MRI and show restricted diffusion on DWI(1).

### ***Metastases***

The liver is a common site for deposition of metastases due to its blood flow. Common origin for such tumors includes the GI tract, lung, breast and melanoma. These can be single or multiple in appearance on ultrasound. Characteristic patterns include the Bull's eye lesion where there is hyper echoic lesion surrounded by a hypo echoic rim. Others might be target lesions with central necrosis. Additional patterns might have internal calcifications. Ultrasound is usually employed for localizations in the procedures(1).

They are typically hypo-attenuating on unenhanced CT, enhancing less than surrounding liver following contrast <sup>1</sup>. If there is concomitant hepatic steatosis, then the lesions may be iso- or even slightly hyper-attenuating. Enhancement is typically peripheral, and although there may be central filling in, on portal venous phase, the delayed phase will show washout; helpful in distinguishing a metastasis from a hemangioma(1). FNACs from the lesions can help in undiagnosed cases.

The appearance of liver metastases on MRI is also variable, but MRI is more sensitive than CT for the detection of liver metastases and they typically appear moderately hypo-intense on T1 and mildly to moderately hyper-intense on T2(1).

### ***Primary Liver tumors***

Hepatic adenoma and focal nodular hyperplasia are benign tumors of the liver encountered on imaging. Focal nodular hyperplasia (FNHs) is relatively common benign liver masses. They are present in the livers of approximately 4% of individuals, more commonly in females than in males. On ultrasound, FNH may show very slight changes in echogenicity compared to the surrounding parenchyma and usually appear hypo- or iso-echoic and slightly inhomogeneous due to the central scar. FNH are generally solitary but can be multiple. In multiphase CT or MR imaging studies, FNHs typically show rapid homogeneous uptake of contrast in the early arterial phase with rapid return to near-normal enhancement in the portal venous and delayed phases(1).

Hepatic adenomas are relatively uncommon benign liver masses most commonly seen in women particularly those with metabolic syndrome, oral contraceptive use, anabolic steroids in males, and excessive alcohol use. There is risk of malignant transformation and rupture.

Ultrasound shows a hypo echoic lesion with a capsule. Ultrasound shows a central scar lesion in the mass with increased flow on Doppler study. Contrast CT scan shows the typical spoke and wheel appearance(1).

### ***Hepatocellular carcinoma***

HCC is a common condition causing around 700,000 deaths annually, mainly in developing countries. Conventional risk factors include cirrhosis of any cause, chronic hepatitis B infection, hemochromatosis, aflatoxin exposure(36). In Ethiopia the prevalence of chronic Hepatitis B infection is estimated to be around 10%. This alone would make a large segment of the population at risk for HCC(37). In addition the degree of aflatoxin exposure is not studied largely but is assumed to be significant due to the grain utilization practices. Ultrasound is used widely in the world for surveillance of patients with cirrhosis for the occurrence of HCC. The AASLD and EASL guidelines also recommend doing ultrasound every six months for early diagnosis of hepatocellular carcinoma. Such practices are advised because management of such patients largely depends on the size of the tumor at presentation. According to the Milan criteria for patients to be eligible for curative surgical therapy a single lesion should not be more than 5 cm in size or a maximum of 3 masses each with no more 3 cm size is recommended(38). The size of tumor at presentation in Ethiopian patients has not been studied previously but the clinical observation is that most patients present late, precluding any hope of surgical management. In

addition the clinical presentation of patients has important implication as patients with child's class C or with elevated bilirubin are not candidates for surgical therapy.

The clinical features of Ethiopian patients have been studied previously in retrospective study. The study included 51 patients and used CT scan as diagnostic tool for the diagnosis of HCC. 24 % had hepatitis B and 24 % had hepatitis C infection as a risk factor and 45 % had history of alcohol abuse. 88 % of patients had abdominal pain as a symptom and 21.6 % had ascites at presentation. 41.2% had portal vein thrombosis. Of the patients who had an alpha-fetoprotein level determination in the study, 43% had a value above 500. Imaging characterization was not done in the study as it was a retrospective one in design(39).

A CT scan based cross-sectional, prospective study done on patients with a diagnosis HCC at Tikur Anbessa Specialized Hospital from July, 2016 to July, 2017; a total of 70 cases included the mean age were  $50 \pm 16$  years. Fifty-seven (81.4%) of the participants were males and 13(18.6%) were females. Forty-five (64.3%) came from urban areas, and 25(35.7%) of them were from rural areas. In 42(60%) of the patients, both hepatic lobes were involved by the tumor, while in 19(27%) and 9(13%), it was localized to right lobe and left lobe respectively. Fifty-two (74.3%) of the lesions were focal while 18(23.7%) were infiltrative. Invasion of the vessels was demonstrated in 48(69%) of them; from which the portal vein invasion contributed in 39(55.7%) of the cases. Biliary invasion was observed in 5(7.1%). Late arterial enhancement and venous phase washout are seen in 62(88.6%) and late arterial enhancement and delayed phase washout in 8(11.4%). Liver cirrhosis was identified in 44(62.9%) and no CT evidence of cirrhosis in 26(37.1%) of the cases. Forty-four (62.9%) had ascites. Splenomegaly was seen in 20(28.6%). Fifteen (21.4%) had lymph node metastasis. No distant metastasis is seen in 53(75.7%) cases, and there was metastases to the lung and adrenal in 9(12.9%) and 4(5.7%) respectively. Other site metastasis was detected in 3(4.3%); 1(1.4%) of the cases had lung, adrenal and bone metastases. Positive HBV and HCV test were revealed in 15(21.4%) and 5(7.1%) respectively.(40)

With regards to sonographic features hepatocellular carcinomas tend to be variable. Most small tumors with size less than 5 cm tend to be hypo-echoic whereas larger ones tend to be

heterogeneous. The addition of Doppler study helps in characterizing the surrounding vascular structures and vascularity of the tumor. As estimated 25% of patients have hepatic or portal vein invasion. This also can be assessed with Doppler study, and has implication for the management of patients. Underlying liver parenchyma assessment is important in evaluation of such patients because cirrhosis is the most important risk factor for HCC.

Since the advent of newer technologies in imaging, characterization of focal liver lesion with ultrasound is not commonly done. Most studies currently try to evaluate new technologies or protocols in the backdrop of CT or MRI. Characterization studies with ultrasound are done several decades ago in the western literature but there is scarcity of such studies recently. However such studies have been conducted in developing countries.

In Germany study was conducted in 2005 that tried to evaluate histologically proven HCC with conventional and contrast ultrasound. It enrolled 100 patients and 91% of patients had cirrhosis and half had hepatitis B or C. 43% of patients had a single lesion and 34% had more than 3 lesions. Almost half of the HCC lesions had hypo echoic lesion and 65% had hyper vascular in Doppler study. Portal vein thrombosis was documented in 25%. 69% had a mass more than 3 cm in size. As the study was conducted only in patients with hepatocellular carcinoma, other patients with different lesions were not included in the study(20).

In India, a study was conducted in 2013 which tried to evaluate focal liver lesions with ultrasound as a primary imaging modality. It spanned over a one year period, and enrolled 105 patients. The investigators also did FNAC to make cytology diagnosis. Mean age of patients was 41 and majorities were males. The most common diagnosis made was liver abscess (31%), closely followed by primary malignant tumors of the liver (29%). A quarter of the patients had metastases as a diagnosis. The rest of the patients had hemangioma, cysts and hydatid lesions each accounting to 5% of the diagnoses. In terms of number of lesions 62% were solitary and similar amount were localized to the right lobe only. The most common appearance of the liver abscess was hypo echoic (80%). Only 2.8% of the abscesses were hyper-echoic. The malignant liver tumors were hyper echoic in appearance in 50%, where as 35% were mixed echogenicity. Amongst the metastatic lesions, 38 % were hypo-echoic and close to 20 % had a bulls eye

appearance. In this study the highest sensitivity of ultrasound was for liver abscess at 90 % when FNAC is used as a control. The sensitivity for liver tumors was 80%. (41)

Similar study from India published in 2014 also found liver abscess was the commonest focal liver lesion (36%). In contrast primary liver tumors only accounted for 8% of diagnoses. Metastases accounted for 14 % of cases whereas hemangiomas were 16%. The study spanned 3 months and enrolled 50 patients.(10)

A third study from India also utilized the same methodologies to assess patients with focal and diffuse liver lesions. 118 patients were enrolled and of this 98 had focal liver lesions .In this study too the commonest diagnosis was liver abscess (35%). Liver tumor represented 27% and 22% had metastases. Half of the liver tumors were hyper-echoic and one third had mixed echogenicity. Metastases had hypo-echoic appearance in 36% and a bull's eye lesion in 22%. The sensitivity of ultrasound for liver abscess was 93%, where as it was 84.6% for hepatic tumors. The study used FNAC as a control for confirmation of diagnosis.

In Nigeria a study was conducted to correlate ultrasound findings of focal liver lesion with cytology. Forty seven patients were included and 43 patients (91.5%) were diagnosed to have hepatocellular carcinoma. Abscess accounted only for 4.3% of the cases. 78 % of the ultrasound diagnosed cases of HCC were confirmed by histology, where as 12% were suspicious for malignancy.(42)

A study trying to see the role of ultrasound in the diagnosis of HCC was conducted in Ivory Coast. It included 31 patients with median age of 47. The size of the tumor were less than 5 cm in 61% and 58% were multiple & nodular. Only 9% of the cases had portal vein thrombosis. In the study a significant number of patients (42%) had a normal alpha fetoprotein level.(43)

In Tanzania, study was done to characterize patients with HCCs clinically in 2014(16). In the radiological assessment of the 142 patients 49 % had multiple lesions on ultrasound. A size of 10 cm or more was documented in 60% patients. 66% of patients had hepatitis B and 72.5 % of

patients had a Child-Pugh class C stage disease. In hospital mortality rate of patients was 46.5%. At one year only 28 % of patients survived and remaining were lost to follow-up.(21)

Study done in Pakistan in 2011 with 45 patients, 136 liver lesions (11 benign and 125 malignant) were detected with the help of different enhancement patterns. Out of these, 37(82.2%) patients had malignant while 8 (17.8%) had benign lesions. On later histopathological examination, 35 (77.8%) of the total 45 cases had malignant lesions while 10 (22.2%) were diagnosed as benign lesions. Based on these results, it could be assessed that tri-phasic CT Scan has a sensitivity of 100 %, specificity of 80%, positive predictive value of 94.5%, negative predictive value of 100% and diagnostic accuracy of 95.5 % in differentiating benign from malignant liver lesions.(44)

In study done in Government Medical College, Amritsar from August 2012 to October, 2014 peak incidence was observed in the age group of 41-50 years (31%). The mean age was 43.8 years. 59 cases (59%) were males and 41 cases (41%) were females. The presenting symptoms were pain abdomen (63%) followed by loss of appetite (41%), weight loss (39%), fever (32%), progressive abdominal distension (22%), jaundice (17%) and bowel symptoms such as constipation, anorexia and nausea seen in 8% of cases. On clinical examination, hepatomegaly was seen in 56% patients followed by abdominal tenderness (48%), fever (32%), and icterus (17%). Mass per abdomen was palpable in only 7% of the patients. Anemia and raised serum glutamic oxaloacetic transaminase (SGOT) were observed in 39 % and 34 % of the patients respectively

Benign hepatic lesions accounted for 64 % of the cases and 36% were malignant, based on CT findings. In case of benign hepatic lesions (n=64), segment V was involved in 26.56% patients. Right lobe involvement was seen in 73.84% cases of benign hepatic lesions. 42.18% lesions were within 1–5 cms in size. Peripheral enhancement on contrast administration was noticed in 56.25% cases. Ascites was associated finding in 14.06 % of the cases. Whereas amongst the malignant lesions (n=36), segment VIII was most commonly involved (47.22%). Both lobes were involved in 69.44% of the malignant hepatic lesions. Majority (61.11%) were 5–10 cm in size. Ill-defined margins and hypo-dense lesions were the hallmark in malignant hepatic masses (77.77% cases). 50% of malignant lesions enhanced heterogeneously on contrast studies. Ascites

(86.11 %) and abdominal lymphadenopathy (75%) were the common associated features in an event of malignancy

Pyogenic liver abscess (31.25%), amebic liver abscess (20.31%), simple hepatic cyst (18.75%), hemangiomas (17.18%) and hydatid cysts (12.5%) were in decreasing order of frequency, the probable diagnosis of the benign hepatic lesions (n=64). Metastases were the most common malignant hepatic lesions accounting for 72.22% (26 cases). Most commonly seen were the metastases from gall bladder, lung and colon, each accounting for 11.11% (4 cases each) of the malignant hepatic lesions. Rest was cases of primary hepatic malignancies. These included 5 cases (13.88%) of HCC, 3 cases (8.33%) of cholangiocarcinoma and one case each of fibro lamellar carcinoma (2.77%) and hepatoblastoma (2.77%). Radiological-histopathological correlation was done in 75 out of 100 patients (41 cases of benign lesions and 34 cases with provisional diagnosis of a malignant lesion).

Metastases accounted for 72.22% (n=26) of the total malignant hepatic lesions encountered (n=36).(45)

Another study done in Era's Lucknow Medical college and Hospital from January 2017 to June 2018 with 84 patients shows; 72 (85.7%) were benign and 12 (14.3%) were malignant lesions. Among the benign lesions, 39 (46.4%) were abscess, 10 (11.9%) were Cyst, 13 (15.5%) were Hemangioma, 8 (9.5%) were Hydatid cyst and 2 (2.4%) were Hepatic Granuloma. 12 (14.3%) were Hepatocellular carcinoma. biopsy was done in 90.5% cases and in 9.5% cases the results didn't match.

Among the benign cases detected by MDCT, 97.2% confirmed as benign cases by biopsy. On the other hand, among the malignant cases detected by MDCT only 83.3% cases confirmed as malignant by biopsy. With sensitivity, specificity, PPV, NPV and diagnostic accuracy for malignant lesions was found to be 83.3%, 97.2%, 83.3%, 97.2% and 95.2% respectively.(46)

In another prospective study done in India with 100 patients from March 2010 to May 2012 shows; majority of patients belonged to the age group 30–39 years (29%) and males constituting 55% of cases. The most common clinical presentation was pain in abdomen seen in 57% of cases. The second most common presentation was history of malignancy elsewhere seen in 36%.

The right lobe alone was involved in the majority of patients (40%) followed by bilateral lobe involvement in 39%. The majority of patients were found to have multiple lesions seen in 51% of cases. 47% were malignant, 34% were benign lesions and 19% were inflammatory lesions. Among the benign lesions, the most common diagnosis was simple cyst ( 53% )of cases. The second most common diagnosis was hemangiomas (35%) of cases.

Among the malignant lesions, the most common diagnosis was metastases seen in 67% of cases. The next most common was hepatocellular carcinoma (HCC) seen in 29% of cases.

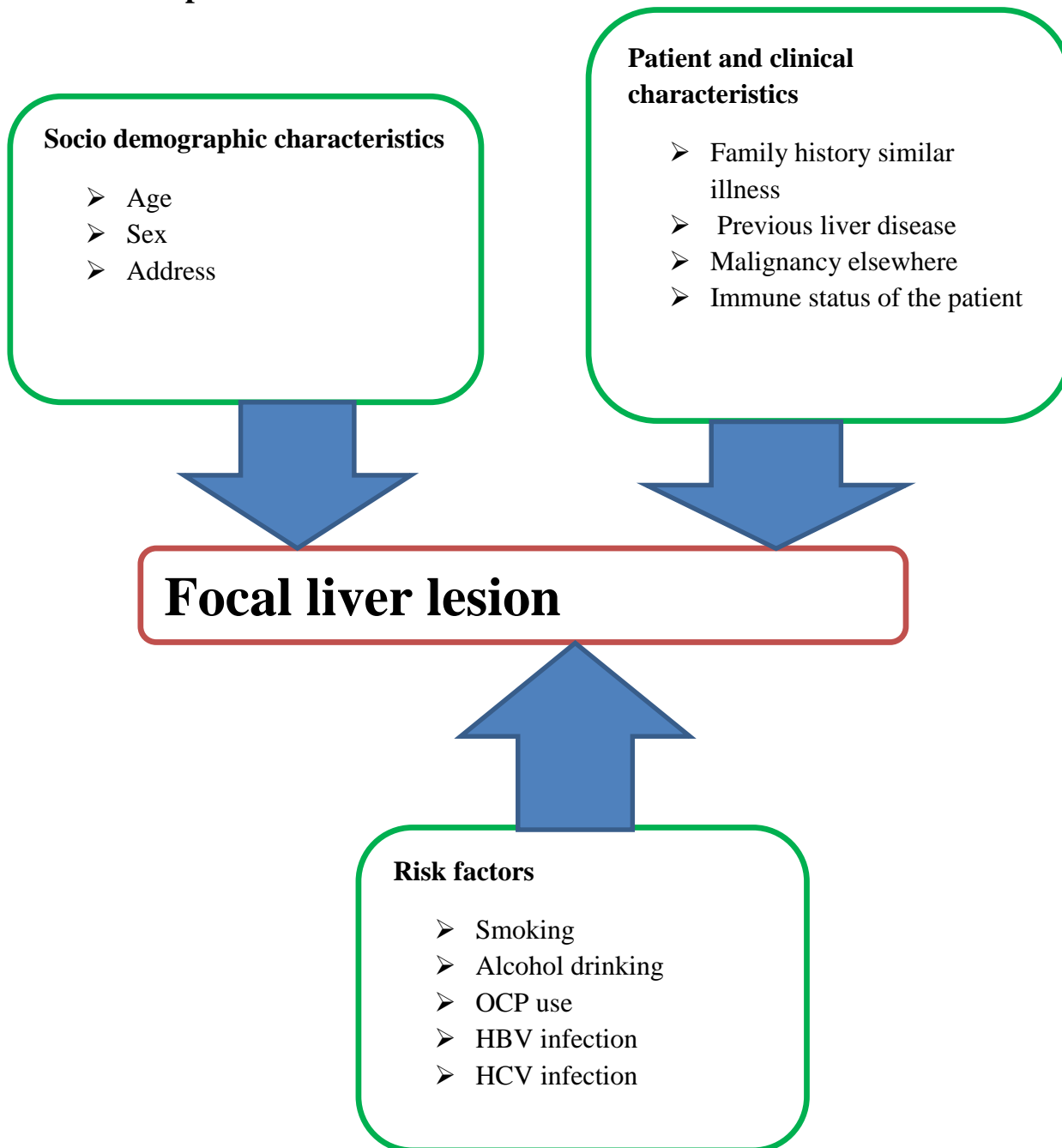
Among the inflammatory lesions, the most common diagnosis was liver abscess seen in 58% of cases followed by hydatid cyst seen in 42% of cases.(47)

MRI based prospective study done in India in 2016 with 42 patients; Out of 42 patients diagnosed initially by ultrasound, 28 were males (68%) and 14 were females (32%). The age range was 20 to 70 years with a mean age of 51 years for malignant lesions. The right lobe of liver was involved in 26 (62%), left lobe in 7 (17%) and both lobes in 9(21%) cases. There were 24 benign and 18 malignant lesions.(48)

In another MRI based study done in 2015 diagnosed by Multi Detector Computed Tomography Out of 30 FLLs diagnosed, 19 (hepatocellular carcinoma: 11 and metastatic FLLs: 8) were malignant and 11 (hemangiomas: 5, abscesses: 3, simple hepatic cysts: 2, focal nodular hyperplasia: 1) were benign.(49)

MRI scans of 124 CT-indeterminate focal hepatic lesions in 98 patients (46 men and 52 women) obtained from January 1997 to December 2001 were analyzed retrospectively; MRI definitely characterized 73 lesions (58%) that were indeterminate on CT. MRI was accurate in 72/73 of these lesions. MRI could not definitely characterize 51 lesions (42%). Ten lesions were not visualized on MRI, and follow-up imaging confirmed that no lesion was present in eight of these cases (pseudo lesions)(50).

## Conceptual frame work



**Figure 1:** Conceptual frame work of focal liver lesions and associated risk factors in patients with focal liver lesions following at GI clinic in Tikur Anbessa specialized Hospital of the year 2020 (n=135).

### **1.3. Justification**

Government health concerns in developing countries primarily concentrated on infectious diseases previously. But recent increases in the prevalence of non-communicable diseases like malignancies have led to the organization of a non-communicable disease control arm in the government health programs. HCC accounts for >80% of primary liver cancers worldwide, it exacts a heavy disease burden and is a leading cause of cancer-related death in many parts of the world, being estimated to be the fourth most common cause of cancer-related death overall worldwide. Despite these studies are limited for focal liver lesions word wide even in Africa the exact epidemiology and etiologies are not clearly known. In our country, one or two studies were done specifically on HCC with limitations and the entire studies showed high malignant rate compared with western studies. Therefore, this study could provide very important information about epidemiology, clinical and imaging patterns of focal liver lesions in our setup. The results of the study could help to know clinical pattern and work up and manage accordingly.

### **3. Objectives**

#### **3.1 General objective**

- To assess clinical and imaging characterization in patients with focal liver lesions with emphasis on HCC at Tikur Anbesa specialized hospital (TASH) from august 1, 2019 to July 30, 2020 .

#### **3.2 Specific objectives**

- To assess clinical and imaging characterization of patients with focal liver lesions with emphasis on HCC.

## **4. Methods**

### **4.1 Study area**

- The study was conducted at Tikur Anbessa specialized hospital GI referral clinic which is the largest hospital in Ethiopia located in the capital Addis Ababa.

### **4.2 Study period**

- Study period was from august 1, 2019 to July, 30, 2020 GC.

### **4.3 Study Design**

- Descriptive institution based retrospective study design was conducted from august 1 to July 30, 2020 GC.

### **4.4 Source Population**

- The source population was all patients with focal liver lesions attending at GI referral clinic of Tikur Anbessa Specialized hospital in study period.

### **4.5 Study population**

- All patient with focal liver lesions attending at TASH GI referral clinic with age  $\geq 18$  and have any liver imaging modalities was considered as study population.

## **4.6 Inclusion and exclusion criteria for patients**

### **4.6.1 Inclusion criteria**

- Patients referred to GI referral clinic with strong clinical suspicion of focal lesion of liver including those with primary malignancy elsewhere.
- Patients already diagnosed with focal liver lesion by ultrasonography
- Patients who gave informed consent

### **4.6.2 Exclusion criteria**

- Patients with diffuse liver diseases
- Patients with mass around the liver with contiguous involvement of liver
- Patients with traumatic injury to liver
- Those unwilling to participate in the study

## **4.7 Study Variables**

### **4.7.1 Dependent variables**

- Focal liver lesion
- Hepatocellular carcinoma

### **4.7.2 Independent variables**

- Sociodemographic factors including age, sex, behavioral factors including smoking and alcohol drinking
- Clinical features in study subjects
- Prior liver disease
- HBV and HCV infection
- Malignancy in other sites
- Lab results like CBC, LFT, AFB, CA19-9, CEA-19
- Previous malignancy
- Family history of similar illness
- DM

## 4.9 Sample size and Sampling technique

The predicted total number of patients attending GI referral clinic in TASH in the study period is <10000.

Since the total number of the study population is < 10000, The required sample size for the study will be determined by using the formula:

$$n = \frac{\frac{Z^2 p(1-p)}{d^2}}{1 + \frac{1}{N} \left( \frac{Z^2 p(1-p)}{d^2} \right)}$$

Where

n = Sample size

Z = standard statistical value, under normal distribution curve, with significance level at 5% (ZA/2=1.96)

P = proportion; most studies showed prevalence of FLL around 10% (benign 9.2%, malignant 0.6% .....South Korean study)

N = total number of Predicted study population is about 1000.

D = standard error = 0.05

$$n = \frac{1.96^2 \times 0.1 \times (1 - 0.1)}{0.05 \times 0.05}$$

$$n = \frac{1.96^2 \times 0.1 \times (1 - 0.1)}{0.05 \times 0.05}$$

$$1 + \frac{1.96^2 \times 0.1 \times (1 - 0.1)}{1000 \times 0.05^2}$$

$$n = 121$$

A sample size of 121 patients was calculated assuming confidence interval of 95% and degree of freedom of 0.05. Given the total population is less than 10,000 the final corrected sample size after 10% was added for possible dropout are determined to be 133.

#### **4.10 Data collection method**

Data was collected using standardized questionnaire. After looking GI clinic registration, we selected patients with abdominal imaging diagnosis of liver lesion. Then we retrieved their medical records and icare number and using appropriate data extraction format data was collected.

##### **4.10.3 Data analysis and presentation**

Data was checked for consistency and cleaned by the investigator. Then it was coded and entered to SPSS version26. The result was summarized by using frequency, tables and graphs. Both bivariate and multivariate logistic regressions were fitted to identify predictor variables. A 95% confidence interval odds ratio (OR) was computed and considered variables having p - value less than 0.05 in the multi variable model as significantly associated with the dependent variable.

## **5. Ethical consideration**

The study protocol was submitted to both ethical review committees of Department of Internal medicine and to IRB of Addis Ababa University, college of medicine and health sciences and the study was done after approval by hospital administration and the department of internal medicine. The study was retrospective and there were no diagnostic or therapeutic interventions for the study purpose.

## **6. Dissemination of the results**

The results of the study will be presented to Addis Ababa University, college of medicine and health sciences, department of Internal Medicine as part of partial fulfillment of postgraduate subspecialty program.

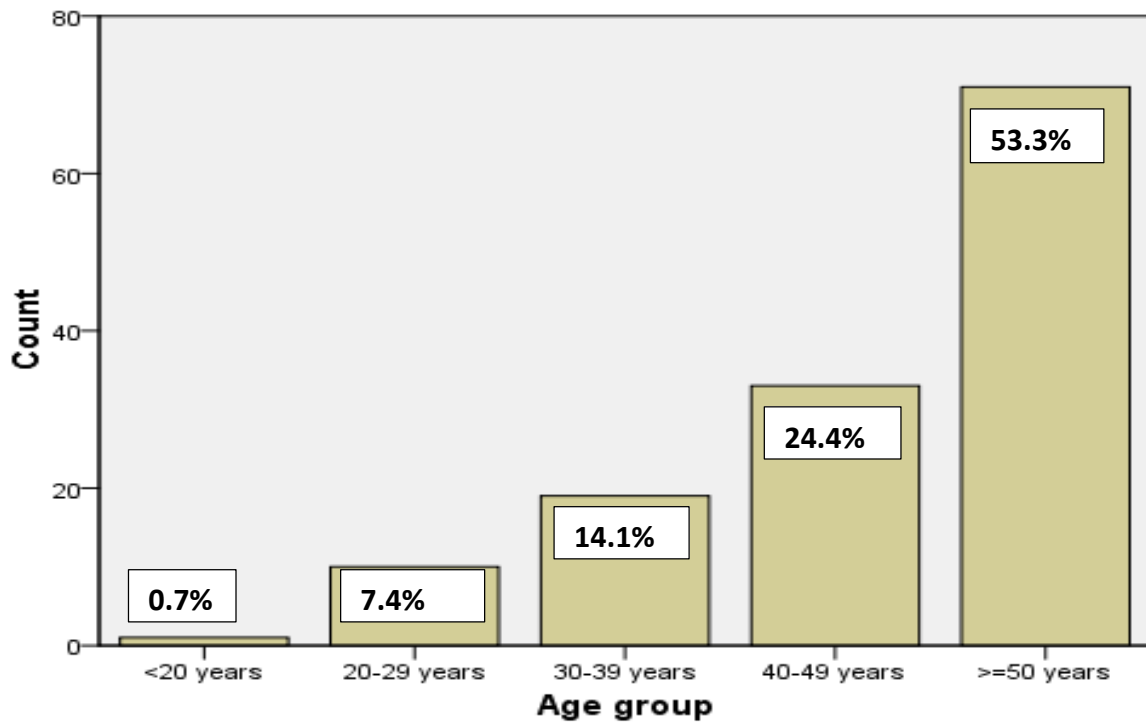
## 7. Results

### Socio demographic characteristics

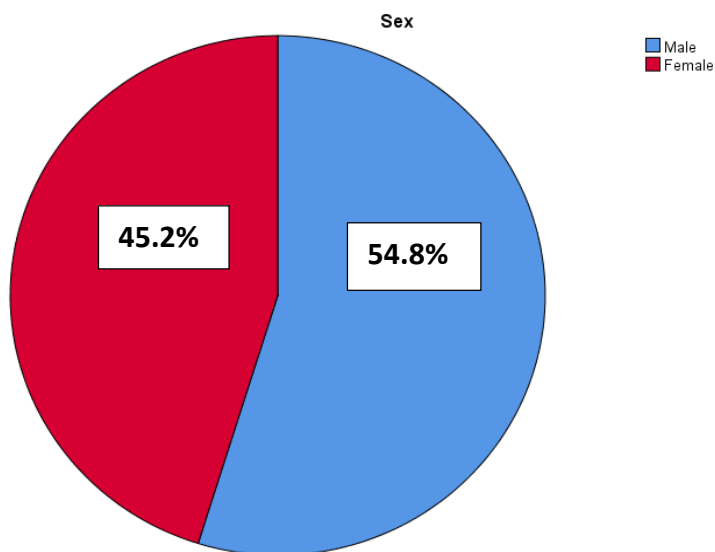
A total of 135 (n=135) patients were included in the study. Demographic characteristics of patients are shown in Table 1. The mean age was 49.83(SD 13.866) and Majority of patients were age >40 years 104 (77%). 74(54.8%) were males and 61(45.2%) were females. 75 (55.6%) were from Addis Ababa and 36(26.7%) of them were from Oromia. More than 80% of patients are from Addis Ababa and Oromia. The presenting symptoms were abdominal pain 101 (74.8%) followed by, weight loss 61(45.2%), abdominal distension 52(38.5%), incidental finding 16 (11.9%), jaundice 12(8.9%) and fever 3 (2.2%). On clinical examination, ascites was seen in 12 (8.9%) of patients followed by, fever 3(2.2%) and icterus 12(8.9%).

**Table 1: Frequency of Sociodemographic factors of patients with focal liver lesions following at GI clinic in Tikur Anbessa specialized Hospital of the year 2020 (n=135).**

Variable	Frequency (%)
Age-years, mean(SD)	49.83 (13.866)
Gender	Male 74 (54.8%)
	Female 61 (45.2%)
Address	Addis Ababa 77 (55.6%)
	Oromia 36 (26.71%)
	Amhara 11 (8.1%)
	SNPPR 8 (5.9%)
	Others 4 (3.7%)
Age group	<20 years 1 (0.7%)
	20-29 years 11 (7.4%)
	30-39 years 19 (14.1%)
	40-49 years 33 (24.4%)
	≥50 years 71 (52.6%)



**Figure 2:** Distribution of age group in patients with focal liver lesions following at GI clinic in Tikur Anbessa specialized hospital of the year 2020 (n=135).



**Figure 3:** Distribution of sex in patients with focal liver lesions following at GI clinic in Tikur Anbessa specialized hospital of the year 2020 (n=135).

## Clinical presentation

**Table 2: Frequency of clinical presentations of patients with focal liver lesions following at GI clinic in Tikur Anbessa specialized hospital of the year 2020 (n=135)**

Variable		Frequency (%)
Incidental finding	Yes	16 (11.9%)
	No	119 (88.1%)
	Total	135 (100%)
Abdominal pain	Yes	101 (74.8%)
	No	34 (25.2%)
	Total	135 (100%)
Abdominal distention	Yes	52 (38.5%)
	No	83 (61.3%)
	Total	135 (61.5%)
Ascites	Yes	12 (8.9%)
	No	123 (91.1%)
	Total	135 (100%)
Jaundice	Yes	12 (8.9%)
	No	123 (91.1%)
	Total	135 (100%)
Fever	Yes	3 (2.2%)
	No	132 (97.8%)
	Total	135 (100%)
Weight loss	Yes	61 (45.2%)
	No	73 (54.1%)
	Total	135 (100%)

## Laboratory characteristics

AST was elevated in 42 (31.2%), ALT was elevated in 24 (17.8%), ALP was elevated in 13(9.6%), INR was prolonged in 5 (3.7%), AFP was high in 15(11.1%) of patients. 16 (11.9%) patients were anemic, 20 (14.9%) of patients were thrombocytopenic, 30 (22.2%) were HBVsAg positive and 10 (7.4%) were HCVAb positive.

**Table 3: Frequency of laboratory parameters of patients with focal liver lesions following at GI clinic in Tikur Anbessa specialized hospital of the yea 2020**

Variable	Mean (SD)	Frequency (%)
AST (n=84)	46 (265.8) U/L	≥40 U/L.....42 (31.2%)
ALT (n=84)	30 (261.6) U/L	≥40 U/L.....24 (17.8%)
ALP (n=74)	173 (327) IU/L	≥270 IU/L.....13 (9.6%)
INR (n=16)	1 (0.613)	≥1.2.....5 (3.7%)
AFP (n=21)	12 (757.5) ng/dl	≥20 ng/ml.....15 (11.1%)
WBC (n=81)	5,700 (9336)	≤4.5K.....8 (5.9%)
		≥11K.....7 (5.2%)
HGB (n=81)	14 (2.2) mg/dl	≤13.5 g/dl.....16 (11.9%)
		≥16 g/dl.....4 (3%)
PLT (n=81)	213,000 (148230.2)	≤150K.....20 (14.8%)
		≥350K.....6 (4.4%)
HBVsAg(+ve) (n=135)		30 (22.2%)
HCVAb(+ve) (n=135)		10 (7.4%)

## Imaging pattern

Based on ultrasound benign hepatic lesions accounted for 36 (48 %) of the cases and 40 (52%) were malignant. The commonest benign hepatic lesions was hepatic hemangioma 23(29.9%) followed by hepatic cyst 8 (10.4%), hepatic abscess 3(3.9%), hydatid cyst 3(3.9%) respectively. Right lobe involvement was seen in 44 (57.1%), left lobe involvement was seen in 13(16.9%) and both lobes were involved in 20(26%) of cases. Majority of lesions 58(81.7%) are between 2-10cm size. Portal vein thrombosis observed in 8(10.4%) of cases. Hepatomegaly in 5(10.4%), splenomegaly 8(6.5%) of cases was observed. Of the malignant hepatic lesions hepatocellular carcinoma 32(41.6%) was the commonest followed by metastases 7(9.1%).

**Table 4: ultrasound imaging pattern of 77 patients with focal liver lesions following at GI clinic in Tikur Anbessa specialized hospital of the year 2020 (n=77)**

Variable		Frequency (n=77) (%)
Ultrasound diagnosis	Hepatocellular carcinoma	32 (41.6%)
	Hepatic hemangioma	23 (29.9%)
	Hepatic abscess	3 (3.9%)
	Hepatic cyst	8 (10.4%)
	Hydatid cyst	3 (3.9%)
	Metastases	7 (9.1%)
	Cholangiocarcinoma	1 (1.3%)
Lesion character	Benign	36 (48%)
	Malignant	41 (52%)
Lesion size	2-5cm	28 (39.4%)
	5-10cm	30 (42.3%)
	>10cm	13 (18.3%)
Lesion lobes	Right	44 (57.1%)
	Left	13 (16.9%)
	Both	20 (26%)
Portal vein thrombosis		8 (10.4%)
splenomegaly		5 (6.5%)
Hepatomegaly		8 (10.4%)

Based on CT scan most of the lesions were malignant 81 (81%) from which HCC accounts 63 (63%) of the cases followed by metastases 12 (12%) and cholangiocarcinoma 6 (6%). Majority of lesions 72(75%) are >5cm size and most of them were solitary. Right lobe was dominantly involved 55 (55%). Venous wash out was noted in more than half of patients and portal vein invasion was seen in 17 (17%) of patients. The commonest benign hepatic lesion was hepatic hemangioma 14(14%) followed by hydatid cyst 2 (2%). Segment IV, V, VI and VII were involved in more than 90% of lesions. Hepatosplenomegaly was documented in one quarter of patients. Almost all patients with malignant lesions were age more than fifty years with comparable sex distribution.

**Table 5: CT scan imaging pattern of 100 patients with focal liver lesions following at GI clinic in Tikur Anbessa specialized hospital of the year 2020 (n=100)**

Variable	Frequency (n=100) (%)	
CT diagnosis	Hepatocellular carcinoma	63 (63%)
	Hepatic hemangioma	14 (14%)
	Hepatic abscess	1 (1%)
	Hepatic cyst	1 (1%)
	Hydatid cyst	2 (2%)
	Metastases	12 (12%)
	Cholangiocarcinoma	6 (6%)
	Others	1 (1%)
	total	100 (100%)
Lesion character	Benign	19 (19%)
	Malignant	81 (81%)
	total	100 (100%)
Lesion size	2-5cm	24 (25%)
	5-10cm	39 (41%)
	>10cm	33 (34%)
Lesion lobes	Right	55 (55%)
	Left	18 (19%)
	Both	26 (26%)
Lesion number	1	62 (62%)
	2	3 (3%)
	3	9 (9%)
	>3	26 (26%)
Portal vein thrombosis	17 (17%)	
splenomegaly	10 (10%)	
Hepatomegaly	15 (15%)	
Venous washout	54 (54%)	

Positive HBV and HCV test were revealed in 30 (22.2%) and 10 (7.4%) respectively. Smoking and alcohol history were revealed in 14 (10.4%) and 39 (28.9%) respectively. 50 (37%) of patients had previously known liver disease. Lesions were confirmed by histopathology in 5(3.7%) of cases (biopsy 4(3%) and FNAC 1 (0.7%)).

**Table 6: Pattern of risk factors identified in 135 patients with focal liver lesions at Tikur Anbessa specialized Hospital of year 2020 (n=135).**

Variable	Frequency (n=135) (%)
Alcohol	39 (28.9%)
Smoking	14 (10.4%)
Previous liver disease	50 (37%)
HBV	38 (22.2%)
HCV	11 (7.4%)

**Table 7: Bivariate logistic regression showing the association of independent variables on hepatocellular carcinoma of patients seen at GI clinic, Tikur Anbessa specialized Hospital of year 2020 (n=135)**

Variable	Frequency (n=135) (%)	COR (95%, CI)	P-value
Mean age mean, (SD)	49.8 (13.9)	0.909 (0.648-1.280)	0.585
Sex	Male 74 (54.8%)	3.925 [1.904-8.091]	0.000*
	Female 61 (45.2%)		
Alcohol history	39 (28.9%)	5.054 [2.203-11.594]	0.000*
Previous liver disease	50 (37%)	15.034 [6.122-36.921]	0.000*
HBVsAg status	30 (22.2%)	8.462 [2.995-23.906]	0.000*
HCVAb status	10 (7.4%)	11.455 [1.408-93.162]	0.000*
AFP mean, (SD)	12 (757.5) ng/dl	0.364 [0.051-2.601]	0.314
Hemoglobin mean, (SD)	14 (2.2) mg/dl	1.306 [0.512-3.335]	0.576
Platelet mean, (SD)	213,000 (148230.2)	0.167 [0.727-1.876]	0.522
INR mean, (SD)	1(0.613)	1.125 [0.078-16.307]	0.931
Splenomegaly mean, (SD)	17cm (0.26)	4.929 [1.006-24.146]	0.049*

In binary logistic regression: sex, alcohol history, history of previous liver disease, HBV infection, HCV infection and splenomegaly were statistically significant at a p value of 0.05.

Significant variables in the bivariate logistic regression were entered into multivariate logistic regression. And in the multivariate logistic regression: HBV infection and HCV infection were significantly associated with hepatocellular carcinoma at p value of 0.05.

HBVsAg positive patients were 92.8% less likely have hepatocellular carcinoma compared to HBVsAg negative patients. (AOR=0.072, 95% CI: 0.02-0.265, p-value 0.000). Among HCVAb positive patients were 37% less likely to have hepatocellular carcinoma as compared to HCVAb negative patients. (AOR=0.63, 95% CI: 0.006-0.644, p-value 0.02) it shows there are unidentified risk factors contributing for HCC other than HCV and HBV in this study.

**Table 8: Multivariate logistic regression showing the association of independent variables on hepatocellular carcinoma of patients seen at GI clinic, Tikur Anbessa specialized Hospital of year 2020 (n=135)**

Variable	Frequency (%)	COR (95%, CI)	AOR (95%, CI)	P-value
Age mean, (SD)	49.8 (13.9)	0.909 (0.648-1.280)	0.988 (0.955-1.023)	0.503
Sex	male 74 (54.8%)			
	female 61 (45.2%)	3.925 [1.904-8.091]	0.667 [0.237-1.872]	0.442
Alcohol history	39 (28.9%)	5.054 [2.203-11.594]	0.412 [0.117-1.1450]	0.0.167
Previous liver disease	50 (37%)	15.034 [6.122-36.921]	0.429 [0.127-1.446]	0.0.172
HBVsAg status	30 (22.2%)	8.462 [2.995-23.906]	0.072 [0.02-0.265]*	0.000*
HCVAb status	10 (7.4%)	11.455 [1.408-93.162]	0.63 [0.006-0.644]*	0.02*
Splenomegaly mean, (SD)	17cm	4.929 [1.006-24.146]	5.677 [0.829-38.902]	0.077

## 8. Discussion

This will be one of the few studies done on focal liver lesions in Ethiopia focusing on clinical, laboratory and imaging pattern characterization of focal liver lesions. Male to female ration of the participants in this study was comparable, with male to female ratio of 1.2:1. But male predominance is noted in most of previous studies. Mean age was 49.83 years which is comparable with majority of studies done so far. The most common presenting symptoms were abdominal pain (74.8%) followed by weight loss (45.2%), abdominal distension (38.5%) which is also comparable with studies done so far, study done in Germany in 2012 (abdominal pain 63%, weight loss 39% and progressive abdominal distension 41%).

Based on ultrasound imaging 48% and 52% of focal liver lesions were benign and malignant respectively. Compared to studies done in other countries malignant lesions are detected more than benign lesions in this study, this might be due to our study area is tertiary hospital in which more advanced cases are seen. The commonest benign hepatic lesions was hepatic hemangioma (29.9%) followed by hepatic cyst 8 (10.4%). Right lobe involvement was seen (57.1%) left lobe involvement was seen in (16.9%) and both lobes were involved in (26%) of cases involvement of hepatic lobes are comparable with other studies reviewed but commonest imaging findings are variable between studies this might be explained by epidemiologic differences. Majority of lesions (81.7%) are between 2-10cm sizes. Portal vein thrombosis observed in (10.4%) of cases. Hepatomegaly in (10.4%), splenomegaly 6.5% of cases was observed. Of the malignant lesions hepatocellular carcinoma 41.6% was the commonest followed by metastases (9.1%) similar findings are seen in other African studies too. But in comparison with our study metastases was the commonest malignant lesion in western studies.

Based on CT scan majority of lesions were malignant and solitary with size  $\geq 5$ cm% which is comparable with most of the reviewed studies. Hepatocellular carcinoma was the commonest malignant lesion followed by cholangiocarcinoma which is again comparable with most of African studies, but in western studies metastases is the commonest finding this might be related with better control of risk factors for HCC in western set ups. Right lobe was dominantly involved and Venous wash out was noted in more than half of patients which is comparable in

most of the studies reviewed. Portal vein invasion was observed in (17%) of cases which are less common compared to other studies reviewed this might be due to low detection rate in our set up. Segment IV, V, VI and VII were involved in more than 90% of lesions. Hepatosplenomegaly was documented in one quarter of patients. Almost all patients with malignant lesions were age more than fifty years with comparable sex distribution.

Positive HBV and HCV test were revealed in 30 (22.2%) and 10 (7.4%) respectively which is comparable with prospective study done on patients with a diagnosis HCC at Tikur Anbessa Specialized Hospital on 201, showing HBVsAg positivity was 21.4% and HCVAb positivity was 7.1% ,similar retrospective study done in our country shows also comparable result but it was low compared to study done in Tanzania which shows 66% HBVsAg positivity. Smoking and alcohol history were revealed in 14 (10.4%) and 39 (28.9%) respectively. 50 (37%) of patients had previously known liver disease. Lesions were confirmed by histopathology in 5(3.7%) of cases (biopsy 4(3%) and FNAC 1 (0.7%) of cases.

Among the risk factors HBV ((AOR=0.072, 95% CI: 0.02-0.265, p-value 0.000) and HCV (AOR=0.63, 95%CI: 0.006- 0.644, p-value 0.02) infection were significantly associated with hepatocellular carcinoma.

**Conclusion:** Majority of lesions in this study were malignant, hepatocellular carcinoma and hemangioma being the commonest malignant and benign lesions respectively. Many of the lesions were solitary and size  $\geq 5$ cm. right lobe was mostly involved, abdominal pain was the commonest presentation in most of the patient. HBV and HCV infection was significantly associated with hepatocellular carcinoma among the risk factors

## **9. Recommendation:**

- ❖ To conduct multicenter prospective studies with large sample size including survival analysis to know the exact epidemiology and prognosis of focal liver lesions in our country.
- ❖ Farther study on risk factors of hepatocellular carcinoma with extensive work up is recommended because we found many hepatocellular carcinoma patients with unknown risk factors.
- ❖ Recommended to have tissue diagnosis for those patients with unknown etiologies

## **10. Limitation of the Study**

- ❖ This is a single centered hospital based retrospective study and results cannot be generalized to the general population since patients that present to this hospital may not represent patients in the whole country. There might be also individual variation in imaging results since it might be done in different area and there were incomplete data like risk factor, laboratory results some imaging were also done outside which we cannot access it.

## 11. References

1. Venkatesh SK, Chandan V, Roberts LR. Liver masses: A clinical, radiologic, and pathologic perspective. *Clin Gastroenterol Hepatol*. 2014;12(9):1414–29.
2. Lope CR De, Reig ME, Darnell A, Forner A. Approach of the patient with a liver mass. 2012;252–62.
3. Venkatesh SK, Chandan V, Roberts LR, Rodríguez de Lope C, Reig ME, Darnell A, et al. Approach of the patient with a liver mass. *Clin Gastroenterol Hepatol*. 2014 Oct;3(9):252–62.
4. Bhajjee F, Anders RA. Hepatic mass lesions : challenges and pitfalls Biliary masses. 2017;544–52.
5. [Liver Ultrasound: Focal Lesions and Diffuse Diseases] - PubMed [Internet]. [cited 2020 Mar 2]. Available from: [https://pubmed.ncbi.nlm.nih.gov/25523277-liver-ultrasound-focal-lesions-and-diffuse-diseases/?from\\_term=%22hydatid+cyst%22+AND+%22liver%22+AND+%22ultrasound%22&from\\_filter=simsearch3.fft&from\\_pos=2](https://pubmed.ncbi.nlm.nih.gov/25523277-liver-ultrasound-focal-lesions-and-diffuse-diseases/?from_term=%22hydatid+cyst%22+AND+%22liver%22+AND+%22ultrasound%22&from_filter=simsearch3.fft&from_pos=2)
6. Hansen N, Weadock W, Morani A, Carlos R. Liver lesions discovered incidentally on ultrasound: evaluation of reader ability to characterize lesions on MRI without intravenous contrast. *Acad Radiol* [Internet]. 2012 Sep 1 [cited 2020 Feb 17];19(9):1087–93. Available from: <http://www.ncbi.nlm.nih.gov/pubmed/22877986>
7. Mergo PJ, Helmberger T, Nicolas AI, Ros PR. Ring enhancement in ultrasmall superparamagnetic iron oxide MR imaging: A potential new sign for characterization of liver lesions. *Am J Roentgenol*. 1996;166(2):379–84.
8. Virmani J, Kumar V, Kalra N, Khandelwal N. Characterization of primary and secondary malignant liver lesions from B-mode ultrasound. *J Digit Imaging*. 2013 Dec;26(6):1058–70.
9. Kim HA, Kim KA, Choi J Il, Lee JM, Lee CH, Kang TW, et al. Comparison of biannual ultrasonography and annual non-contrast liver magnetic resonance imaging as surveillance tools for hepatocellular carcinoma in patients with liver cirrhosis (MAGNUS-HCC): A study protocol. *BMC Cancer*. 2017 Dec 21;17(1).
10. Hapani H, Kalola J, Trivedi A, Chawla A. Ultrasound Evaluation of Focal Hepatic Lesions. 2014;13(12):40–5.

11. Nazarian LN, Wechsler RJ, Grady CK, Needleman L, Halpern EJ, Copit SE, et al. CT done 4-6 hr after CT arterial portography: Value in detecting hepatic tumors and differentiating from other hepatic perfusion defects. *Am J Roentgenol.* 1994;163(4):851–5.
12. Urban BA, Fishman EK, Kuhlman JE, Kawashima A, Hennessey JG, Siegelman SS. Detection of focal hepatic lesions with spiral CT: Comparison of 4- and 8- mm interscan spacing. *Am J Roentgenol.* 1993;160(4):783–5.
13. Kuszyk BS, Bluemke DA, Urban BA, Choti MA, Hruban RH, Sitzmann J V., et al. Portal-phase contrast-enhanced helical CT for the detection of malignant hepatic tumors: Sensitivity based on comparison with intraoperative and pathologic findings. *Am J Roentgenol.* 1996;166(1):91–5.
14. Lecture K. Non-invasive diagnosis of focal liver lesions: an individualized approach. 2012;12(October):365–72.
15. Mekonnen HD esaleg., Sharma S, Shewaye A, Feld J, Lulu E. MAJOR RISK FACTORS, CLINICAL AND LABORATORY CHARACTERISTICS OF PATIENTS WITH HEPATOCELLULAR CARCINOMA; A RETROSPECTIVE STUDY AT TIKUR ANBASSA HOSPITAL, ADDIS ABABA UNIVERSITY, ADDIS ABABA, ETHIOPIA. *Ethiop Med J.* 2015 Jul 1;53(3):127–32.
16. Jaka H, Mshana SE, Rambau PF, Masalu N, Chalya PL, Kalluvya SE. Hepatocellular carcinoma: Clinicopathological profile and challenges of management in a resource-limited setting. *World J Surg Oncol.* 2014 Aug 2;12(1).
17. Kumar M, Kumar R, Hissar SS, Saraswat MK, Sharma BC. Risk factors analysis for hepatocellular carcinoma in patients with and without cirrhosis : A case – control study of 213 hepatocellular carcinoma patients from India. 2007;22:1104–11.
18. Tekle F, Galle PR, Fisseha H, Getinet T. Helicobacter pylori Infection as a Risk Factor for Hepatocellular Carcinoma : A Case-Control Study in Ethiopia. 2018;2018.
19. Zidan A, Scheuerlein H, Schüle S, Settmacher U, Rauchfuss F. Epidemiological Pattern of Hepatitis B and Hepatitis C as Etiological Agents for Hepatocellular Carcinoma in Iran and Worldwide. 2012;12.
20. Ignee A, Weiper D, Schuessler G, Teuber G, Faust D, Dietrich CF. Sonographic characterisation of hepatocellular carcinoma at time of diagnosis. *Z Gastroenterol.* 2005 Mar;43(3):289–94.

21. Hepatocellular Carcinoma: Clinicopathological Profile and Challenges of Management in a Resource-Limited Setting - PubMed [Internet]. [cited 2020 Mar 2]. Available from: [https://pubmed.ncbi.nlm.nih.gov/25085449-hepatocellular-carcinoma-clinicopathological-profile-and-challenges-of-management-in-a-resource-limited-setting/?from\\_single\\_result=Jaka+H%2C+Mshana+SE%2C+Rambau+PF%2C+Masalu+N%2C+Chalya+PL%2C+Kalluvya+SE.+Hepatocellular+carcinoma+%3A+clinicopathological+profile+and+challenges+of+management+in+a+resource-limited+setting.+2014%3A1-9](https://pubmed.ncbi.nlm.nih.gov/25085449-hepatocellular-carcinoma-clinicopathological-profile-and-challenges-of-management-in-a-resource-limited-setting/?from_single_result=Jaka+H%2C+Mshana+SE%2C+Rambau+PF%2C+Masalu+N%2C+Chalya+PL%2C+Kalluvya+SE.+Hepatocellular+carcinoma+%3A+clinicopathological+profile+and+challenges+of+management+in+a+resource-limited+setting.+2014%3A1-9).
22. [Hepatocellular Carcinoma (HCC) Observed in Abidjan: Aspects and Role of Ultrasonography] - PubMed [Internet]. [cited 2020 Mar 2]. Available from: [https://pubmed.ncbi.nlm.nih.gov/9757269-hepatocellular-carcinoma-hcc-observed-in-abidjan-aspects-and-role-of-ultrasonography/?from\\_single\\_result=N'Gbesso+RD%2C+Attia+A%2C+Mahassadi+A%2C+et+a+l.+%5BHepatocellular+carcinoma+%28HCC%29+observed+in+Abidjan%3A+aspects+and+role+of+ultrasonography%5D.+J+Radiol.+1998%3B79%285%29%3A409-414.+http%3A%2F%2Fwww.ncbi.nlm.nih.gov%2Fpubmed%2F9757269.+Accessed+November+2%2C+2016](https://pubmed.ncbi.nlm.nih.gov/9757269-hepatocellular-carcinoma-hcc-observed-in-abidjan-aspects-and-role-of-ultrasonography/?from_single_result=N'Gbesso+RD%2C+Attia+A%2C+Mahassadi+A%2C+et+a+l.+%5BHepatocellular+carcinoma+%28HCC%29+observed+in+Abidjan%3A+aspects+and+role+of+ultrasonography%5D.+J+Radiol.+1998%3B79%285%29%3A409-414.+http%3A%2F%2Fwww.ncbi.nlm.nih.gov%2Fpubmed%2F9757269.+Accessed+November+2%2C+2016).
23. Liver Lesions: Types, Causes, Diagnosis & More [Internet]. [cited 2020 Feb 17]. Available from: <https://www.docpanel.com/blog/post/liver-lesions-types-causes-diagnosis-more#benefits-of-a-liver-lesion-second-opinion>
24. Leon M, Chavez L, Surani S. Hepatic hemangioma: What internists need to know. [cited 2020 Mar 1]; Available from: <https://dx.doi.org/10.3748/wjg.v26.i1.11>
25. Bajenaru N, Balaban V, Săvulescu F, Campeanu I, Patrascu T. Hepatic hemangioma-review. Vol. 8, Journal of Medicine and Life. 2015.
26. Msume Banda F, Slone JS, Anderson A, Beretta M, Walabh P, Loveland J, et al. Case Report Cryptogenic Cirrhosis and Hepatopulmonary Syndrome in a Boy with Hepatic Hemangioma in Botswana: A Case Report and Review of the Literature. 2017 [cited 2020 Mar 1]; Available from: <https://doi.org/10.1155/2017/7940365>
27. Kratzer W, Gruener B, Kaltenbach TEM, Ansari-Bitzenberger S, Kern P, Fuchs M, et al. Proposal of an ultrasonographic classification for hepatic alveolar echinococcosis: Echinococcosis multilocularis Ulm classification-ultrasound. World J Gastroenterol. 2015 Nov 21;21(43):12392–402.

28. Engler A, Shi R, Beer M, Schmidberger J, Kratzer W, Barth TFE, et al. Simple liver cysts and cystoid lesions in hepatic alveolar echinococcosis : a retrospective cohort study with Hounsfield analysis. 2019;54.
29. Botezatu C, Mastalier B, Patrascu T. Hepatic hydatid cyst - diagnose and treatment algorithm. *J Med Life*. 2018 Jul 1;11(3):203–9.
30. Butler TJ, Mccarthy CF. Pyogenic liver abscess. Vol. 10, *Gut*. 1969.
31. Serraino C, Elia C, Bracco C, Rinaldi G, Pomero F, Silvestri A, et al. Characteristics and management of pyogenic liver abscess: A European experience. *Med (United States)*. 2018;97(19).
32. Donovan AJ, Yellin AE, Ralls PW. Hepatic abscess. *World J Surg*. 1991 Mar;15(2):162–9.
33. B ähler P, Baladron MJ, Menias C, Beddings I, Loch R, Zalaquett E, et al. Multimodality imaging of liver infections: Differential diagnosis and potential pitfalls. *Radiographics*. 2016 Jul 1;36(4):1001–23.
34. Kannathasan S, Murugananthan A, Kumanan T, Iddawala D, Renuka De Silva N, Rajeshkannan N, et al. Amoebic liver abscess in northern Sri Lanka: first report of immunological and molecular confirmation of aetiology.
35. Wuerz T, Kane JB, Boggild AK, Kraiden S, Keystone JS, Dsc MF, et al. A review of amoebic liver abscess for clinicians in a nonendemic setting. 2012;26(10):729–33.
36. Cabrera R. Hepatocellular carcinoma: current trends in worldwide epidemiology, risk factors, diagnosis, and therapeutics. *Hepatic Med Evid Res*. 2012 May;4:19.
37. Kefene H, Rapicetta M, Rossi GB, Bisanti L, Bekura D, Morace G, et al. Ethiopian National Hepatitis B Study. *J Med Virol*. 1988 Jan;24(1):75–84.
38. Kudo M. Clinical practice guidelines for hepatocellular carcinoma differ between Japan, United States, and Europe. Vol. 4, *Liver Cancer*. S. Karger AG; 2015. p. 85–95.
39. MAJOR RISK FACTORS, CLINICAL AND LABORATORY CHARACTERISTICS OF PATIENTS WITH HEPATOCELLULAR CARCINOMA; A RETROSPECTIVE STUDY AT TIKUR ANBASSA HOSPITAL, ADDIS ABABA UNIVERSITY, ADDIS ABABA, ETHIOPIA - PubMed [Internet]. [cited 2020 Mar 2]. Available from: <https://pubmed.ncbi.nlm.nih.gov/26677522-major-risk-factors-clinical-and-laboratory->

characteristics-of-patients-with-hepatocellular-carcinoma-a-retrospective-study-at-tikur-anbassa-hospital-addis-ababa-university-addis-ababa-ethiopia/?from\_single\_result=M

40. Getaneh F, Atnafu A. Patterns of Hepatocellular Carcinoma on Computed Tomography at Tikur Anbessa specialized hospital, Addis Ababa, Ethiopia. *Ethiop J Health Sci.* 2020;30(2):209–14.
41. Thimmaiah VT. Evaluation of Focal Liver Lesions by Ultrasound as a Prime Imaging Modality. *2013;1(6):1041–59.*
42. Correlation Between Ultrasound Findings And Ultrasound Guided-Fine Needle Aspiration Cytology In The Diagnosis Of Hepatic Lesions: A Nigerian Tertiary Hospital Experience | Request PDF [Internet]. [cited 2020 Aug 27]. Available from: [https://www.researchgate.net/publication/273624353\\_Correlation\\_Between\\_Ultrasound\\_Findings\\_And\\_Ultrasound\\_Guided-Fine\\_Needle\\_Aspiration\\_Cytology\\_In\\_The\\_Diagnosis\\_Of\\_Hepatic\\_Lesions\\_A\\_Nigerian\\_Tertiary\\_Hospital\\_Experience](https://www.researchgate.net/publication/273624353_Correlation_Between_Ultrasound_Findings_And_Ultrasound_Guided-Fine_Needle_Aspiration_Cytology_In_The_Diagnosis_Of_Hepatic_Lesions_A_Nigerian_Tertiary_Hospital_Experience)
43. M'Bengue AK, Doumbia M, Denoman SR, Ouattara DN, Adoubi I, Pineau P. A major shift of viral and nutritional risk factors affects the hepatocellular carcinoma risk among Ivorian patients: A preliminary report. *Infect Agent Cancer* [Internet]. 2015;10(1):1–10. Available from: <http://dx.doi.org/10.1186/s13027-015-0013-1>
44. Hafeez S, Alam MS, Sajjad Z, Khan ZA, Akhter W, Mubarak F. Triphasic computed tomography (CT) scan in focal tumoral liver lesions. *J Pak Med Assoc.* 2011;61(6):571–5.
45. Gupta K, Gauba N, Gupta G. Role of Computed Tomography in Evaluation of Parenchymal Focal Lesions of Liver. *J Evol Med Dent Sci.* 2015;4(36):6257–68.
46. Jain S, Khanduri S, Shah JK, Yadav P, Krishnam A. Role of MDCT in Detection and Characterisation of Focal Liver Lesions. *J Clin Diagnostic Res.* 2019;13(5):1–5.
47. Rani S, Tripathi P. Imaging Characteristics of Focal Liver Lesions on Contrast-Enhanced Helical Computed Tomography. *2018;6(3):53–6.*
48. M U, Ch. L. Evaluation of focal liver lesions by magnetic resonance imaging and correlation with pathology. *Int J Res Med Sci.* 2016;4(11):4659–68.
49. Kapoor A, Mali R V. Characterisation of Focal Liver Lesions using Diffusion-Weighted Magnetic Resonance Imaging Technique. *Int J Anatomy, Radiol Surg.* 2019;Vol-8(2):33–7.

50. Elsayes KM, Leyendecker JR, Menias CO, Oliveira EP, Narra VR, Chapman WC, et al. MRI characterization of 124 CT-indeterminate focal hepatic lesions: Evaluation of clinical utility. *HPB*. 2007;9(3):208–15.



2.7. Liver tests A) AST.....B) ALT.....C)  
ALP.....D) INR.....

2.8. AFP.....

2.9. CA19-9.....

2.10. CEA-19.....

2.11. HBV<sub>s</sub>AG A) Positive B) Negative C) Not available

2.12. HCVAB A) Positive B) Negative C) Not available

2.13. CBC profile: WBC count ( $10^6/L$ ) \_\_\_\_\_

Hemoglobin (g/dl) \_\_\_\_\_

Platelet \_\_\_\_\_

### 3. Imaging profile

3.1. Abdominal U/S A) Yes B) No

If yes, diagnosis

A) Hepatocellular carcinoma B) Hemangioma C) Amebic abscess D) Pyogenic abscess E)  
Simple hepatic cyst F) Hydatid cyst H)Metastases I) cholangiocarcinoma J)  
Other.....

3.1.1. Lesion number.....

3.1.2. Lesion type A) Benign B) Malignant C) Indeterminate

3.1.3. Lesion size.....

3.1.4. Lesion lobe A) Right B) Left

3.1.5. Lesion segment A) 1 B) 2 C) 3 D) 4 E) 5 F) 6 G) 7 H) 8

3.1.6. Spleen size.....

3.1.7. Liver size.....

3.1.8. Any portal vein thrombosis A) Yes B) No

**3.2. Abdominal CT scan** A) Yes B) No

If yes, diagnosis

A) Hepatocellular carcinoma B) Hemangioma C) Amebic abscess D) Pyogenic abscess E) Simple hepatic cyst F) Hydatid cyst H)Metastases I) cholangiocarcinoma J) Other.....

3.2.1. Lesion number.....

3.2.2. Lesion type A) Benign B) Malignant C) Indeterminate

3.2.3. Lesion size.....

3.2.4. Lesion lobe A) Right B) Left

3.2.5. Lesion segment A) 1 B) 2 C) 3 D) 4 E) 5 F) 6 G) 7 H) 8

3.1.6. Spleen size.....

3.1.7. Liver size.....

3.1.8. Any portal vein thrombosis A) Yes B) No

3.1.9. Portal venous washout A) Yes B) No

**3.3. Abdominal MRI** A) Yes B) No

If yes, diagnosis

A) Hepatocellular carcinoma B) Hemangioma C) Amebic abscess D) Pyogenic abscess E) Simple hepatic cyst F) Hydatid cyst H)MetastasesI) cholangiocarcinoma J) Other.....

3.3.1. Lesion number.....

3.3.2. Lesion type A) Benign B) Malignant C) Indeterminate

3.3.3. Lesion size.....

3.3.4. Lesion lobe A) Right B) Left

3.3.5. Lesion segment A) 1 B) 2 C) 3 D) 4 E) 5 F) 6 G) 7 H) 8

3.1.6. Spleen size.....

3.1.7. Liver size.....

3.1.8. Any portal vein thrombosis A) Yes B) No

3.1.9. Portal venous washout A) Yes B) No

4. Hepatic fibro scan A) Yes B) No if yes, finding.....

#### 4. Tissue diagnosis

4.1. FNAC A) Yes B) No

If yes, diagnosis

A) Hepatocellular carcinoma B) Hemangioma C) Amebic abscess D) Pyogenic abscess E) Simple hepatic cyst F) Hydatid cyst H)MetastasesI) cholangiocarcinoma J) Other.....

4.2. BIOBSY A) Yes B) No

If yes, diagnosis

A) Hepatocellular carcinoma B) Hemangioma C) Amebic abscess D) Pyogenic abscess E) Simple hepatic cyst F) Hydatid cyst H)MetastasesI) cholangiocarcinoma J) Other.....