



Imaging pattern of Brain metastasis of all patients with known primary malignancies presented at Tikur Anbesa Specialized Hospital, Department of radiology, Addis Ababa University, Addis Ababa, Ethiopia from September, 2018 – September, 2020.

Investigator: Menbere Mekonnen (MD, Radiology resident)

**A thesis Submitted to The Radiology Department, College of Health Science,
Addis Ababa University in Preparation for Partial Fulfillment of the requirements for the post Graduate Study Completion in Radiology**

Addis Ababa, Ethiopia

December, 2020

Imaging pattern of brain metastasis of all patients with known primary malignancies presented to radiology department at Tikur Anbesa Specialized Hospital, Addis Ababa University, Addis Ababa, Ethiopia from September 2018– September 2020.

Investigator: Menbere Mekonnen (MD, Radiology resident)

Advisors: Tequam Debebe, MD, Associate Professor of Radiology in AAU College of Health Sciences, TASH, Department of Radiology, AA, Ethiopia

Getachewu Assefa , MD, Professor of Radiology in AAU Collage of Health Science, TASH, Department of Radiology, AA, Ethiopia.

A thesis Submitted to the Radiology Department, College of Health Science, Addis Ababa University in Preparation for Partial Fulfillment of the Requirements for the Post Graduate Study Completion in Radiology.

Addis Ababa, Ethiopia

December, 2020

Abstract

Background: Brain metastasis is one of the leading causes of death in cancer patients due to increasing the options of treatment for primary tumors and increasing life span. Brain metastases have different radiological manifestations which may mimic primary tumor and nonmalignant diseases. Therefore, it is important for the radiologist to be familiar with the full spectrum of findings to facilitate correct diagnosis and this study has tried to look for the pattern of brain metastasis.

Objective: This study aimed to assess the overall brain metastasis patterns.

Methods: A retrospective cross sectional study of 51 patients was done from September 2018-September 2020. A structured questionnaire was used to collect data for analysis.

Results: Of the total 51 cases there were 12 primary sites and the majority cases came from the following site in the descending orders breast (22),lung (11),bladder(4),GTD(3),RCC,STS and thyroid each(2) and colonic, endometrial ca melanoma, nasal SCC and thymic ca each (1)

Cerebral hemisphere was the commonest site to be involved followed by cerebellum and brain stem.

Most common pattern of metastasis was multiple nodular followed by solitary, hemorrhagic, cystic and cavitory

Conclusion: cerebral hemisphere metastasis was the commonest brain parts with multinodular pattern and ring enhancement with associated perilesional edema and presence of diffusion restriction for more than half cases

Acknowledgements

I would like to appreciate the department of radiology, CHS, Addis Ababa University for giving me the chance to undertake this research.

I would like to express my deepest gratitude to my advisors Dr. Tequam. D and Prof. Getachewu A, for their valuable and constructive comments during topic selection, proposal development, data collection and analysis.

I am also thankful to my families, colleagues and friends who helped me in searching and providing the necessary literatures, as well as data.

Abbreviations

A.A.....Addis Ababa

TASH.....Tikur anbesa specialized hospital

CT.....Computed tomography

CHS.....Collage of health sciences

MRI.....Magnetic resonance immaging

NECT.....Non enhanced computed tomography

CECT.....Contrast enhanced computed tomography

Contents

Abstract	3
Acknowledgment	5
Abrrivation	5
List of tables.....	7
List of figues	8
Introduction.....	9
1.1 Background	9
1.2. Statement of the problem and significance of the study	9
2.1. Literature review	11
Objectives	12
3.1. General objective	12
3.2. Specific objectives	12
Methods and materials	12
4.1 Study area and period	12
4.2 Study design	12
4.3 Population	13
4.4 Sampling technique and sample size	13
4.5 Data collection	13
4.6 Data quality control	13
4.7 Data analysis and interpretation	13
4.8 Ethical considerations	13
4.9 The limitation of study	13
Result	16
I. Sociodemographic information of the patients	16
II.Common primaries that has metastasised to brain and pattern of involvme.....	17
Discusstion	29
Conclution	31
Recommendation	31
Reference	32

List of tables

Table 1	1 Sociodemographic data of the patient.....	16
Table 2	1 Age of the patient.....	16
Table 3	1 Common primaries that has metastasize to the brain.....	18
Table 4	1 Common primaries with sex distribution.....	20
Table 5	1 Common part of the brain involved.....	22
Table 6	1 Number of lesion.....	22
Table 7	1 Commonest primary VS number of lesions.....	23
Table 8	1 Pattern of the lesion.....	23
Table 9	1 Commonest primary VS pattern of the lesion.....	24
Table 10	1 Largest size of the lesion.....	24
Table 11	1 Commonest primary VS size of the lesion.....	25
Table 12	1 Enhancement pattern of the lesion.....	25
Table 13	1 Commonest primary VS enhancement pattern.....	26
Table 14	1 Degree of perilesional edema.....	27
Table 15	1 Commonest primary VS degree of perilesional edema.....	27
Table 16	1 Size of the lesion VS degree of perilesional edema.....	27
Table 17	1 Study of diffusion restriction.....	28

List of Figures

Figure 1 1 Age and sex distribution of the patient	17
Figure 2 1 Primaries which metastasize to then brain.....	19
Figure 3 1 primary with sex distribution.....	21
Figure 4 1 Part of the brain involved.....	22

Introduction

1.1 Background

Brain metastasis represents an important cause of morbidity and mortality for cancer patients. Brain metastasis is more common than primary brain tumors. The frequency of brain metastasis increases probably due to longer survival of the patient because of more aggressive treatment introduced for primary tumors (1)

Headache (40-50%), focal neurological deficits (30-40%) and seizures (15-20%) are the most common presenting symptoms. A minority of patients have an acute stroke like onset, more often related to an intratumoral hemorrhage (melanoma, choriocarcinoma and renal carcinoma). Altered mental status or impaired cognition are seen in patients with multiple metastasis and/or increased intracranial pressure, sometimes resembling a metabolic encephalopathy. Contrast-enhanced MRI is more sensitive than enhanced CT (2)

There are no clear cut features on CT or MRI that distinguish brain metastasis from primary brain tumors (more commonly malignant gliomas and lymphomas) or non-neoplastic conditions (abscess, infection, demyelinating diseases, and vascular lesions). A peripheral location, spherical shape, ring enhancement with prominent peritumoral edema and multiple lesions all suggest metastatic diseases: these characteristics are helpful but not prove, even in patients with a positive history of cancer. (2)

Accordingly, progress in the development of systemic treatments, together with the rationalized use of surgical resections, radiosurgery and whole-brain radiotherapy, have led to an increase in the number of long-term survivor and in median survival. The recent emergence of targeted therapies and growing metastasis should allow further improvement in prognosis of this devastating disease.(3)

1.2. Statement of the problem and significance of the study

Brain metastasis often causes clinical problem for patients, limits survival, and worsens the quality of life to prolong the survival of those patients, a vital factor that should be carefully considered and managed is the concurrence of extracranial metastasis and its activity. The presence of extracranial metastasis is known as an independent prognostic factor for survival of patients with brain metastases. Different primary tumor types metastasize with different frequencies and at different sites, so identifying the metastatic pattern would be useful in order to identify the primary tumor. This is more

important for patients with brain metastasis, because the primary tumor is unknown in 5-40% of patients presenting with the symptoms of brain metastases, which should be described in detail in large series of patients for better understanding.(7) There are important challenges in effectively detecting and diagnosing brain metastasis and in accurately characterizing their subsequent response to treatment. These difficulties include discriminating metastases from potential mimics such as primary brain tumors and infection, detecting small metastasis. Therefore, it is important for the radiologist to be familiar with the full spectrum of findings to facilitate correct diagnosis (3)

Knowledge of the biology of brain metastasis is essential for development and optimization of therapies for diseases (8)

So this study is believed to provide the information on the patterns of brain metastatic involvement of the commonly seen malignancies of human body. So that the discrepancy to the accepted theories can be easily compared and most importantly the possible surgical planning or other modalities of treatment can be suggested.

Literatures on this area has never been done in our country and I didn't found a single study which asses the overall metastasis pattern of malignancies to brain. So I believe this study will help as a baseline for the future studies on this area

2.1. Literature review

Imaging plays a key role in the diagnosis of CNS metastasis. Imaging is used to detect metastasis in patients with known malignancies and new neurological sign or symptoms ,as well as to screen for CNS involvement in patients with known cancer .CT and MRI are the key imaging modalities used in the diagnosis of brain metastasis. Although MRI is more sensitive than CT for detection of brain metastases, CT remains a vital tool for initial work-up and preoperative management.

MRI with contrast enhancement currently is more sensitive and specific than other imaging modalities in determining the presence, location and number of metastasis. However, CECT is used widely because of its accessibility and low cost.

Brain metastasis occurs in 15-40% of patients with cancer, many of whom are asymptomatic. NECT is the first line imaging modality for patients with neurological deficits because It is easily obtained, well tolerated and can rapidly exclude life threatening emergencies such as hemorrhage, hydrocephalus or significant mass effect. Subsequent evaluation with CECT or MRI may be indicated.(2)

CECT may be used to screen for metastases if MRI is contraindicated or unavailable and CECT has been shown to be more sensitive than noncontract MRI for the detection of cerebral metastases.

Metastatic diseases display certain cross-sectional imaging features on both CT and MRI. They tend to be located at gray-white junction and at border zones between major arterial vascular territories (1). The distribution of brain metastasis generally parallels blood flow, with 80% occurring in the cerebral hemisphere, 15% in the cerebellum and 5% in brainstem.(9)

Brain metastases may be solitary or multiple. Brain metastases are solitary approximately 50% of the time; 20% of the time there are two lesions and 30% of the time there or more lesions are identified. Some tumors including breast, renal cell, colon and thyroid cancers are more commonly solitary, while others such as lung cancer and melanoma tend to be multiple. Nevertheless, the number of metastases is insufficient to reliably suggest tissue type (5)

Pattern in location of brain metastases may vary between primary tumors. For instance, non-small cell lung carcinoma tends to favor the parietal, occipital lobes, whereas breast cancer metastases may occur more often in the cerebellum. Esophageal metastases typically have a cystic appearance with a small surrounding edema.

Additionally, even subtypes of common tumors may have varying appearance when metastasize to the brain: triple-negative breast cancer metastases tend to be cystic necrotic, compared to other breast cancer subtypes.(6)

Imaging characteristics of metastases may suggest an underlying pathologic diagnosis. For example, metastases may have hemorrhagic change, and certain malignancies are more susceptible to hemorrhage. Metastases that classically hemorrhage include melanoma, renal cell Carcinoma, and lung ca as well as thyroid cancer. Of all hemorrhagic metastases, however, lung and breast cancers are the most common etiologies due to their overall prevalence.

Brain metastases on CT appear as solitary multiple mass lesions with variable surrounding vasogenic edema. IN the absence of hemorrhage, metastases may be hypodense, isodense or hypodense compared with brain. Acutely hemorrhagic metastases appear hyper dense to brain tissue. Melanoma metastases tend to be hyper dense to brain on CT even in the absence of hemorrhage.

Iodine contrast enhancement is vital to the detection of metastases on CT, and brain metastases may demonstrate ring, nodular or solid enhancement. More metastases are visible on delayed imaging, and the size of a given metastasis may appear to increase on delayed imaging. (5)

Non contrast CT is performed to detect hemorrhage into metastasis. Hyperdensity in a metastasis is more likely to be hemorrhage than calcification. IV administration of contrast material (30-40g iodine) increases the diagnosis accuracy of CT. Most metastasis enhance after a standard dose of IV contrast. Use of higher dose of contrast (80-85g of iodine) and delayed scanning by 1-3 hours after injection of the contrast agent lead to a further increases in the detection of multiple metastasis; such an approach is appropriate if MRI is not available.

Of cranial and intracranial locations potentially involved by metastatic diseases, parenchymal metastasis is the most common (7)

Factors which affect the incidence of brain metastasis are the stage of primary cancer age and sex. Age at diagnosis of primary cancer has significant effect on the incidence of brain metastases with the highest incidence occur in patient age between 50 to 80 years. However the peak age for brain metastases from breast cancer seem to be lower. A few studies have reported difference in incidence of brain metastases based on gender. Lung cancer and breast cancer are the most common sources of brain metastases in men and women respectively. However the incidence of primary lung cancer and metastases is increasing in women.

On MRI, metastasis is usually iso or hypo intense on T1, hyperintense on T2, and

exhibit avid enhancement. Some metastasis such as melanoma is T1 hyperintense due to the paramagnetic effect of melanin. Hemorrhagic metastasis may also demonstrate T1 signal hyper intensity depending on the age of hemorrhage. DWI usually demonstrates facilitated diffusion rather than diffusion restriction. Vasogenic edema can be substantial and is unrelated to lesion size in metastasis compared with high grade primary brain tumor. MR spectroscopy is useful tool to distinguish whether the brain mass is neoplastic or non-neoplastic, but has not been shown to reliably distinguish metastasis from high grade primary glial neoplasm such as glioblastoma.

Objectives

3.1. General objective

To assess the CT or MRI imaging pattern of brain metastasis of malignancies of the human body

3.2. Specific objectives

To assess the sociodemographic data of malignancies that metastasizes to the brain

To evaluate the pattern of metastasis on the brain

To correlate the histologic type with the pattern of brain involvement

To identify the common malignancies that metastasizes to the brain

Methods and materials

4.1 Study area and period

The study was conducted at TASH, College of health science, Addis Ababa University, Addis Ababa Ethiopia. TASH, located in the nation's capital Addis Ababa, is a largest referral as well the main teaching hospital. The hospital has provides radiology, oncology, neurosurgery and pathology services. There is CT machines with 64 slices and 1.5T MRI. The hospital provides a tertiary level referral treatment with over 800 beds and is open 24hrs for emergency services. The study will be conducted from September 2018 - September 2020 G.C.

4.2 Study design

A non-convenient retrospective cross sectional study was employed.

4.3 Population

4.3.1 Source population

The source population was all patients with brain CT/MRI from September, 2018-september, 2020.

4.3.2 Study population

The study population was all patients with brain CT/MRI and known to have extra cranial primary malignancy from time period of September 2018- September 2020

4.3.3 Inclusion and exclusion criteria

4.3.3.1 Inclusion criteria

All patients with known malignancies evaluated with brain CT/MRI

4.3.3.2 Exclusion criteria

Patients who present with brain CT/MRI after treatment

Patients with atypical brain involvement for the primary with no histologic diagnosis

Patients with multiple primary malignancies

4.4 Sampling technique and sample size

All patients with brain CT/MRI that has fulfilled the inclusion criteria during the study period were included in the study.

4.5 Data collection

Data collection was undertaken by the principal investigator using structured questionnaire. Patients' charts were reviewed to look for sociodemographic data and the primary tumor. The CT and MRI reports were reviewed and findings are recorded in the questionnaires.

4.6 Data quality control

In order to evaluate the clarity of the questionnaire and to assure the data quality, proper

Designing and pre-testing of the questionnaires was done on 5% of participants.

4.7 Data analysis and interpretation

The data was checked for clarity and completeness. Data was analyzed using nonparametric statistical methods with the help of SPSS version 25 software package. Then summarization and comparison of data was done.

4.8 Ethical considerations

In order to respect patient's bill of right, regulation of the hospital where the study was conducted ethical considerations was taken in to account. Any piece of information was kept confidential by keeping anonymity of the study subjects. Written ethical clearance letters was obtained from the department.

4.9. The limitations of the study

Lack of properly handled charts and inadequate information written on the available charts for most of patients were missed so that histologic diagnosis or presence/absence of any therapeutic interventions were difficult to determine. Nonfunctional MRI machine after mid of the study period and lack of important MRI sequences like GRE

Result

I Sociodemographic data

There were 51 patients included in this study of which females constitutes 42 in number (82.3%) and male accounts 9 (17.7%) from 12 different primary tumors. The majority of patients were in the age range of 31-45 constituting 41% of the sample population.

Table 1 1 sociodemographic data of the patients

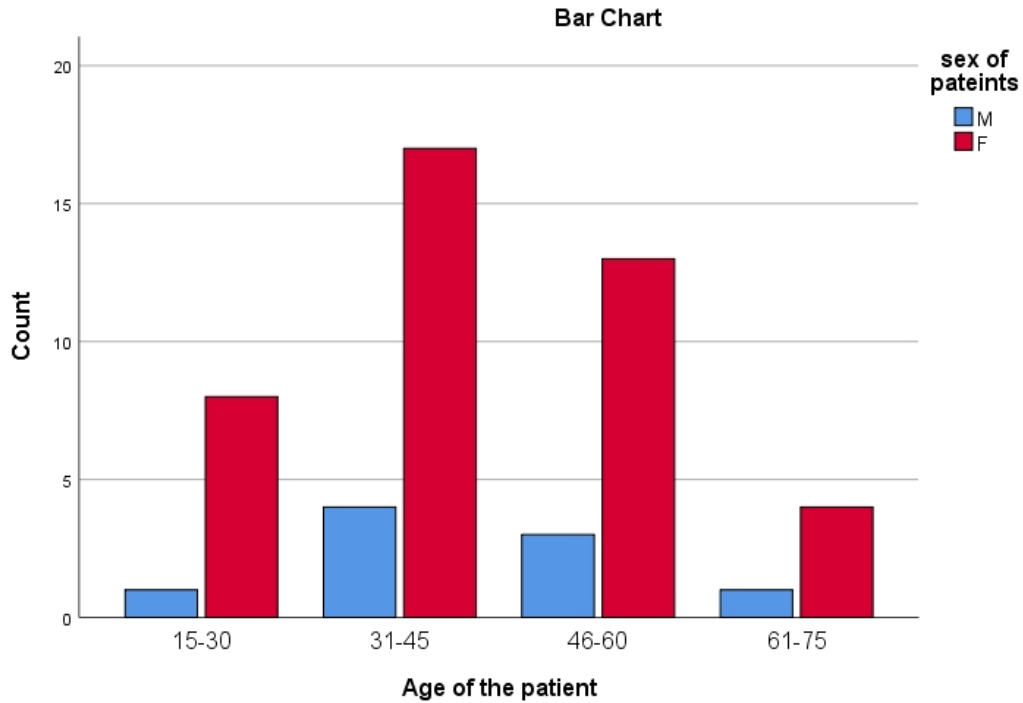
		Sex of patients		
		Frequency	Percent	Valid Percent
Valid	M	9	17.6	17.6
	F	42	82.4	82.4
	Total	51	100.0	100.0

Table 2 1 Age distribution of the patient

Age of the patient Vs sex of patients

		M	F	Total
Age of the patient	15-30	1	8	9
	31-45	4	17	21
	46-60	3	13	16
	61-75	1	4	5
Total		9	42	51

Figure 1 1 Age and sex distribution of the patient



II Common primaries metastasize to brain

Among 51 patients with different 12 primary sites, the commonest primary to metastasize to the brain was breast with 22 cases (43.1%) from which 21 cases were females and 1 male case, lung 11 cases (21.6%) from which 7 cases were female and 4 male cases, bladder 4 cases (7.8%) from which 3 females and 1 male case, GTD 3 (5.9%), RCC, STS, Thyroid each 2 cases (3.9%) and colonic, endometrial, melanoma, nasal SCC and thymic each 1 case (2%).

Table 3 1 Common primaries that has metastasize to the brain

Frequency of primary tumors to metastasize to brain

		Frequency	Percent	Valid Percent
Valid	bladder	4	7.8	7.8
	breast	22	43.1	43.1
	colonic	1	2.0	2.0
	Endometrial	1	2.0	2.0
	GTD	3	5.9	5.9
	lung	11	21.6	21.6
	melanoma	1	2.0	2.0
	nasal	1	2.0	2.0
	RCC	2	3.9	3.9
	STS	2	3.9	3.9
	thymic	1	2.0	2.0
	thyroid	2	3.9	3.9
	Total	51	100.0	100.0

Figure 2 1 primaries metastasize to the brain

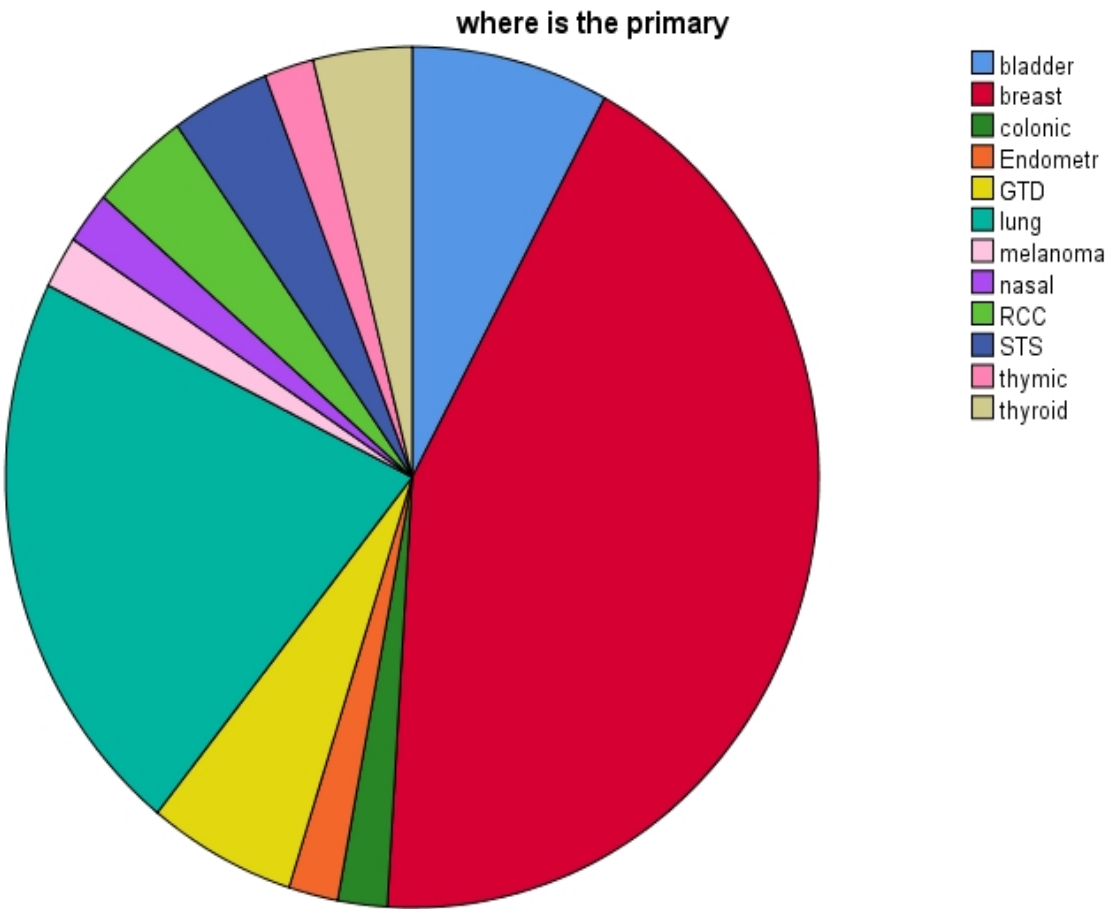
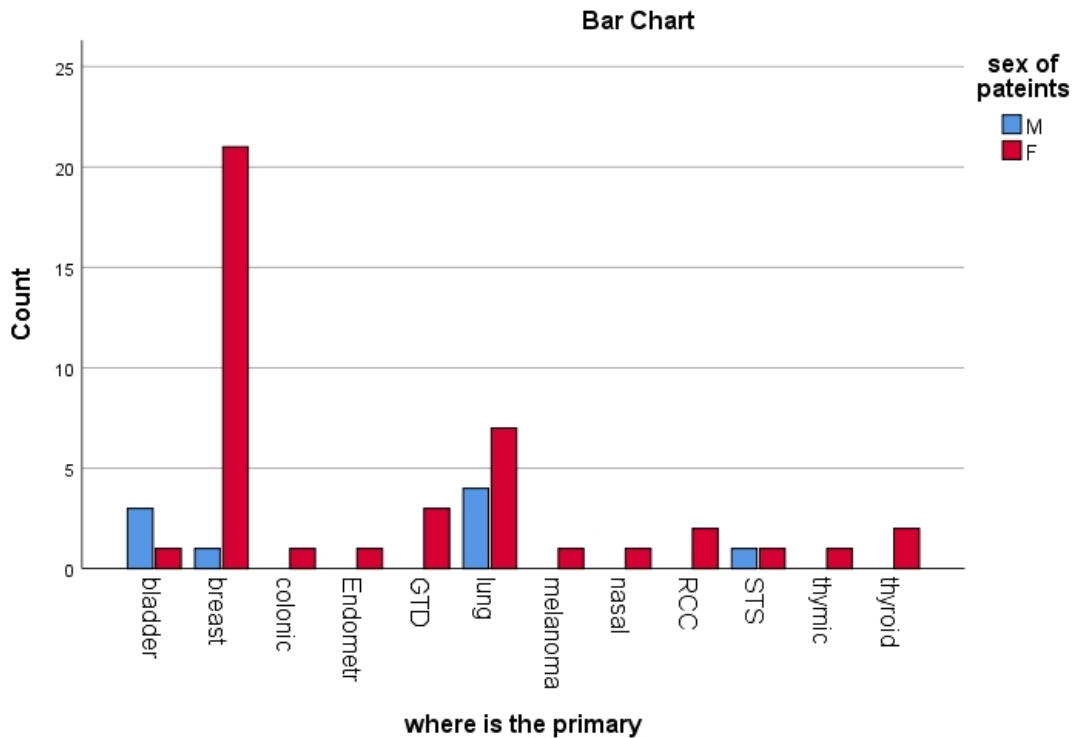


Table 4 1 primary versus sex distribution

primary VS sex of patients Cross tabulation

		sex of patients		Total
		M	F	
where is the primary	bladder	3	1	4
	breast	1	21	22
	colonic	0	1	1
	Endometrial	0	1	1
	GTD	0	3	3
	lung	4	7	11
	melanoma	0	1	1
	nasal	0	1	1
	RCC	0	2	2
	STS	1	1	2
	thymic	0	1	1
	thyroid	0	2	2
	Total	9	42	51

Figure 3 1 primaries VS sex of patients



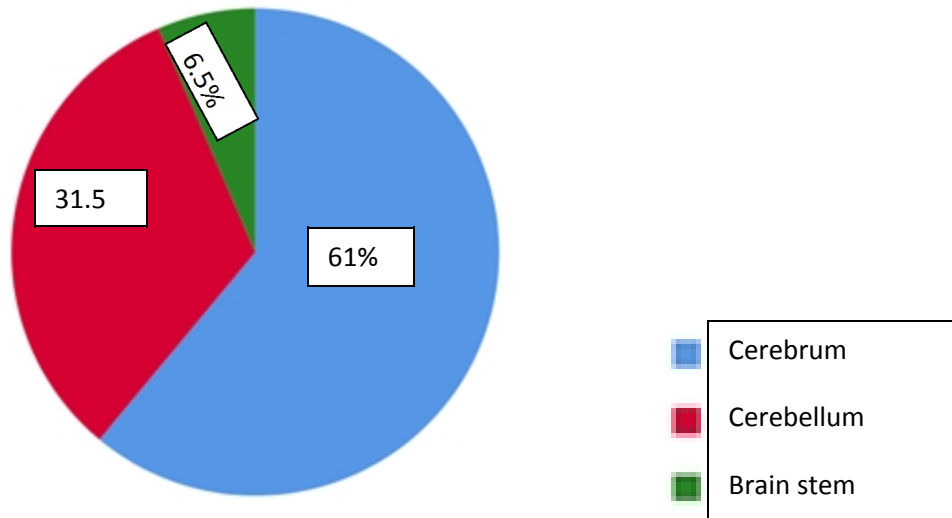
Part of the brain most involved

Cerebral metastasis was commonest part of brain involved which accounts 61% (47), followed by cerebellum and brainstem which accounts 32.5% (25) and 6.5%(5) respectively. The total number was 77 which are more than our sample size this is because of involvement of more than one part of the brain by single case. There were 22 cases with multiple site metastases among which 12 cases were breast cases accounts 54.5% of the whole breast case followed by lung ca 3 cases which makes 27.3% of the total lung ca .The rest were bladder ca accounts 2 cases and endometrial ca, GTD, colonic and thyroid ca one case for each. Among 22 cases 5 cases showed involvement of both infra and supratentorial brain including cerebrum, cerebellum and brain stem

Table 5 1 common part of brain involved

		Frequency of involvement of part of the brain by primary	
		N	Percent
part of brain involved by primary tumor	cerebrum	47	61.0%
	cerebellum	25	32.5%
	brainstem	5	6.5%
Total		77	100.0%

Figure 4 1 part of the brain involved



Number of lesions

On 36 cases of total 51 cases multiple lesions were seen and the rest of 15 patients the lesions were solitary. From most primary cases breast and lung ca showed multiple lesions on 15 and 9 cases respectively and most solitary cases were seen on breast and lung ca cases with 7 and 2 cases respectively

Table 6 1 number of lesions seen

		Frequency	Percent	Valid Percent
Valid	solitary	15	29.4	29.4

multiple	36	70.6	70.6
Total	51	100.0	100.0

Table 7 1 commonest primary VS number of lesions

Primary versus number of lesions Cross tabulation

		Number of lesions		Total
		solitary	Multiple	
where is the primary	bladder	2	2	4
	breast	7	15	22
	colonic	0	1	1
	Endometrial	0	1	1
	GTD	1	2	3
	lung	2	9	11
	melanoma	0	1	1
	nasal	0	1	1
	RCC	1	1	2
	STS	1	1	2
	thymic	1	0	1
	thyroid	0	2	2
	Total		15	36

Pattern of lesion

Most lesions were nodular in pattern which accounts 79.6% followed by hemmorrhagic pattern which accounts 11.1% the rests were cavitary and cystic respectively accounts 5.6 and 3.7 %.The total patients were 54 which excedes our total sample case this is due to existance of more one pattern on single case.Among the commonest primaries breast and lung ca showed 18 and 10 cases of nodular pattern among 43 total nodular cases

Table 8 1 pattern of lesion

		N	Percent
Pattern Of Lesions	Nodular pattern	43	79.6%
	cavitary pattern	3	5.6%
	Cystic pattern	2	3.7%
	hemorrhagic pattern	6	11.1%
Total		54	100.0%

Table 9 1 commonest primary versus pattern of lesion

Primary site with Pattern Of Lesions Cross tabulation

		Pattern Of Lesions				Total
		Nodular pattern	cavitory pattern	Cystic pattern	hemorrhagic pattern	
where is the primary	bladder	3	1	0	0	4
	breast	18	2	1	2	22
	colonic	1	0	0	0	1
	Endometrial	1	0	0	0	1
	GTD	2	0	0	1	3
	lung	10	0	1	1	11
	melanoma	1	0	0	0	1
	nasal	1	0	0	0	1
	RCC	1	0	0	2	2
	STS	2	0	0	0	2
	thymic	1	0	0	0	1
	thyroid	2	0	0	0	2
Total		43	3	2	6	51

Size of the lesion

Most of the lesions were in size range of 1-2.5 cm which accounts 27 cases (52.9%), 17 cases (33.3%) were in size of less than 1 cm and the rest 7 cases had size range of greater or equal to 2.5 cm. Most breast metastasis lesions were in size range of less than 1cm accounts 12 cases and most metastasis cases from lung ca had size range between 1cm-2.5 cm accounts 8 cases

Table 10 1 Largest size of the lesion

		Size of the largest lesion		
		Frequency	Percent	Valid Percent
Valid	<1cm	17	33.3	33.3
	1-2.5 cm	27	52.9	52.9
	> or = 2.5	7	13.7	13.7
	Total	51	100.0	100.0

Table 11 1 commonest primary VS largest size of the lesion

where is the primary * Size of the largest lesion Cross tabulation

		Size of the largest lesion			Total
		<1cm	1-2.5 cm	> or = 2.5	
where is the primary	bladder	0	2	2	4
	breast	12	8	2	22
	colonic	0	1	0	1
	Endometrial	0	1	0	1
	GTD	1	2	0	3
	lung	2	8	1	11
	melanoma	0	1	0	1
	nasal	0	1	0	1
	RCC	0	1	1	2
	STS	0	2	0	2
	thymic	1	0	0	1
	thyroid	1	0	1	2
Total		17	27	7	51

Enhancement pattern of the lesion

Most enhancement pattern of the lesion was ring type with 58.8% (30 cases) from which 13 cases were breast ca cases and 9 cases were lung ca followed by solid enhancement with 39.2% (20 cases) from which breast and lung ca had 9 and 4 cases respectively and non-enhancing lesions with 2%.of the total

Table 12 1 Enhancement pattern of the lesion

		N	Percent
Enhancement pattern of the lesion	solid enhancement	20	39.2%
	Ring enhancement	30	58.8%
	Non enhancing	1	2.0%
Total		51	100.0%

Table 13 1 commonest primary VS enhancement pattern

Primary versus Enhancement Pattern Cross tabulation

		Enhancement Pattern			Total
		solid enhancement	Ring enhancement	Non enhancing	
where is the primary	bladder	1	1	0	2
	breast	9	13	0	19
	colonic	0	1	0	1
	Endometrial	0	1	0	1
	GTD	1	1	1	2
	lung	4	9	0	10
	melanoma	1	0	0	1
	nasal	0	1	0	1
	RCC	2	0	0	2
	STS	1	1	0	2
	thymic	1	0	0	1
	thyroid	0	2	0	2
	Total		20	30	1

From those lesions having ring type of enhancement regular type of enhancement was seen on 43.1%, thick enhancement with 25.9%, thin type of ring enhancement on 24.1% and irregular type of enhancement of 6.9%

From those having solid type of enhancement homogeneous type of enhancement was seen on 59.1% and heterogeneous enhancement on 40.9%

There was associated perilesional edema for cases of 81.6% (40 cases) and the rest 18.4% (11 cases) didn't show perilesional edema. From those having perilesional edema 67.5% (27 cases) showed moderate degree of perilesional edema from which 11 cases were breast ca cases and 7 lung ca cases as well as 3 bladder cases and the rest 6 cases were from endometrial ca, GTD, nasal SCC, STS, thyroid and melanoma which had one case for each while 17.5% mild and 15% of cases extensive perilesional edema. Most lesions with size range from less than 1 cm to greater than 2.5 cm have moderate perilesional edema with no statistically significance($p=0.123$)

Table 14 1 degree of perilesional edema

		Frequency	Percent	Valid Percent
Valid	Mild	7	13	17.5
	Moderate	27	52.9	67.5
	Extensive	6	11.8	15.0
	Total	40	78.4	100.0

Table 15 1 commonest primary VS degree of perilesional edema

		Degree of perilesional edema			Total
		mild	moderate	extensive	
where is the primary	bladder	0	3	0	3
	breast	4	11	3	18
	colonic	0	0	1	1
	Endometrial	0	1	0	1
	GTD	1	1	0	2
	lung	1	7	1	9
	melanoma	0	1	0	1
	nasal	0	1	0	1
	RCC	1	0	1	2
	STS	0	1	0	1
	thyroid	0	1	0	1
Total		7	27	6	40

Table 16 1 size of the lesion VS degree of perilesional edema

		Size of the largest lesion			Total
		<1cm	1-2.5 cm	> or = 2.5	
Degree of perilesional edema	mild	2	4	1	7
	moderate	11	13	3	27
	extensive	0	5	1	6
Total		13	22	5	40

From MRI cases 64.3% cases show diffusion restriction on DWI image while 35.7% shows no restriction on DWI image

Table 17 1 study of diffusion restriction

		Diffusion restriction			Cumulative
		Frequency	Percent	Valid Percent	Percent
Valid	non restricting	10	19.6	35.7	35.7
	Restricting	18	35.3	64.3	100.0
	Total	28	54.9	100.0	

Discussion

This study showed total of 51 patients having known primary and metastasis to brain, among those 23 had CT and the rest 28 MRI with post contrast imaging

There were 51 patients included in this study of which females constitutes 42 (82.3%) and male accounts 9 (17.7%) from 12 different primary tumors and M: F proportion of (1:4.67). From one study which is nearly similar to our study done on Havana cancer center Cuba among 191 patients 117 were female and the rest 74 were male with M: F ratio of (1:1.5). This is because, on both study majority of primary is breast cancer which is 22 in our study and from those 21 are females.

Among 51 patients with different 12 primary sites, the commonest primary to metastasize to the brain was breast with 22 cases (43.1%), lung 11 cases (21.6%), bladder 4 cases (7.8%), GTD 3 (5.9%), RCC, STS, Thyroid each 2 cases (3.9%) and colonic, endometrial, melanoma, nasal SCC and thymic ca each 1 case (2%). On the same study mentioned above breast was the commonest primary accounts 78 cases (40.8%), and the second and the third primary sites were lung and melanoma accounts 61 cases (31.9%) and 24 cases (12.5%) respectively. The rest were taken by colon 22 cases (11.5%), kidney and unknown primary accounts 3 cases each with (1.5%). Comparing this to our study breast was the commonest in frequency followed by lung ca same with our result.

Cerebral metastasis was the commonest site which accounts 61% (47), followed by cerebellum and brainstem involvement which accounts 32.5 (25) and 6.5% (5) respectively. On the same study done on South America the involvement of the supratentorial brain was in about 92.7% and cerebellum 6.4% and brain stem 0.9%. This is due to major cerebral circulation goes to the cerebral hemisphere and as the metastasis is hematogenous this is why on both study cerebral hemisphere is the commonest part of the brain to be involved

Among 51 cases 36 cases (70.6%) had multiple lesions and on the rest 15 cases (29.4%) the lesions were solitary. From most primary cases breast and lung ca showed multiple lesions on 15 and 9 cases respectively and most solitary cases were also seen on 7 breast cases and 2 lung ca cases. One old study done at two hospitals receiving hospital and veteran administration hospital between 1952-1959, 63 patients at Receiving hospital and 111 patients at Veteran administration hospital solitary lesions were seen on 4.8% and 19% cases respectively with multiple lesions were seen on 95.2% and 81% on both hospitals. Similar results was seen on our study to which multiple lesions were the commonest

Most lesions were nodular in pattern which accounts 79.6% followed by hemorrhagic pattern which accounts 11.1% the rests are cavitory and cystic respectively accounts 5.6 and 3.7 %. Among the commonest primaries breast and lung ca had 18 and 10 cases of nodular pattern among 43 total nodular cases. Eventhough, due to small number of our study sample which makes difficult for conclusion most pattern is nodular

Most of the lesions were in size range of 1-2.5 cm which accounts 27 cases (52.9%), 17 cases (33.3%) less than 1 cm and the rest 7 cases had size of greater or equal to 2.5 cm. Most breast metastasis lesions size were in less than 1cm with 12 cases and most metastasis cases from lung ca were with size range of between 1cm-2.5 cm accounts 8 cases. Even though we couldn't find researches done over size of lesion metastasize to brain from all primaries there was a research done at the size of metastatic lesions from lung ca which was second most primary cases in our study. The study was MRI pattern of brain metastasis in lung cancer patients on 62 patients from which 27 cases (41.5%) were in size range of 1cm-2.5 cm which also commonest lesion size to our study

Most enhancement pattern of the lesion was ring type with 58.8% followed by solid enhancement 39.2% and non-enhancing lesions 2%. On one study done on France by M Reuou and M Caiil total of 68 patients with post contrast CT showed half of the cases showed ring type of enhancement while the other half showed homogeneous solid enhancement. In our study the frequency of ring enhancement was in 58.8% which is near similar result to mentioned study.

From those lesions having ring type of enhancement regular type of enhancement were on 43.1%, thick enhancement on 25.9%, thin type of ring enhancement 24.1% and irregular type of enhancement on 6.9%. From those having solid type of enhancement homogeneous type of enhancement were seen on 59.1% and heterogeneous enhancement on 40.9%. We could not find research done on this parameter Even though, this may not be conclusive due to small sample size regular and thick enhancement of ring type of enhancement and homogeneous type of solid enhancement is seen on the most cases.

There was associated perilesional edema for cases of 81.6% and the rest 18.4% didn't show perilesional edema. From those having perilesional edema 67.5% showed moderate degree while 17.5% mild and 15% of extensive perilesional edema with no statistical significance between size of lesion and perilesional edema ($p=0.123$). One study done on India with perilesional edema for implication of immune therapy showed no significant association with size of the lesion

From MRI cases 64.3% cases showed diffusion restriction while 35.7% shows no restriction on DWI image. Most of the lesions showed diffusion restriction on DWI image

Conclusion

There were total of 51 patients in this study from which 42 were female with 12 different primaries, breast, lung, bladder, thyroid, STS, nasal SCC, GTD, endometrial, RCC, colonic, melanoma and thymic ca with common age range of 31-45 years

The commonest primary to metastasize to brain was from breast ca with common site of cerebral metastasis and multiple nodular pattern and ring enhancement with thick and regular character.

Most lesions showed moderate type of perilesional edema with diffusion restriction on DWI

Recommendation

This study has described the overall primary sources to metastasize to the brain in our set up with their metastasis patterns as a baseline but a study of individual primary patterns is recommended for detailed/better understanding.

Future study of the metastatic patterns and their survival significance would be helpful in the management of this patients so further studies in this area is recommended

More time period is needed to get large sample size

Get ready nonfunctional MRI machine

MRI with specific sequences like GRE to detect small hemorrhagic metastasis

Prospective study is recommended for better understanding and to reach on common consensus on some issue having subjective values like perilesional edema

References

1. Leo J Schouten, Joost Rutten, Heans A, M. Huvenneers, Albert Twinistra, Incidence of brain metastasis in a cohort of patients with carcinoma of breast, colon, kidney, lung and melanoma, May 15, 2002/volume 94/ number 10
2. R. Soffietti, P. Cornu, J. Y. Dellatre, R. Grant, F. Graus, W. Grisold, J. Himans, J. Hildrand, P. Hoskin, M. Kalliji, P. Krasence, C. Marosi, T. Siegal and C. Vechut, EFNS guidelines on diagnosis and treatment of brain metastasis, European journal on neuroradiology 2006, 13:674-681
3. E. Tabounet, O. Chinot, P. Metillious, A. Tallers, P. Veins and A. Goncalves, Recent trends in epidemiology of brain metastasis overview, Anticancer research 32:4655-4662(2012)
4. April F. Eichler, Jay S. Loffer, multidisciplinary management of brain metastasis, 2007; 12:884-898
5. Whietny B. Pope, Brain metastasis neuroimaging, available in PMC 2018 August 31
6. Anna. S. Berghoff, Orsoly Rajiky, Frank Wikler, Rupert Bartsh, Ulin Furtner, Johannes A Hanfellen, Simon. L. Goodman, Michel Waller, Jenes Schitenhelm, and Matthias Preusser, Invasion pattern in brain metastasis of solid cancer, Revised May 11, 2013; accepted June 17, 2013
7. Kathleen R. Fink and James R. Fink, Imaging of brain metastasis, Published online 2013 May 3
6. Medscape, Brain metastatic imaging, updated May 15, 2018
8. Doung Anh Young. Son, Rehnad Busse, Extracranial metastatic pattern on occurrence of brain metastasis, Neurooncol(2011) 105:83-90
9. Taofekk. Owankiko, Jack Arbisonor, Amelon Zenlack, Hui-Kou G. Shu, Hyujiu Shim, Adem M. Robin, Steven N. Kalkonis, Timothy G. Whitset, Boudouner Salhai, Nha Nel. Tran, Thimotiy. Rykin, Michel K. Moore, Kathen M. Egan and Jeffrey J. Olson, current approach to the treatment of metastatic brain tumor, 2014 April; 11(4):203-222
10. Kathleen R. Fink, James R. Fink, Imaging of brain metastasis, Surgeneuro Int 2013; 4:S209-19

Data collection format

1) Socio demographic data

1.1 Age

- a) 15-30 b.) 31-45 c.) 46-60 d.) 61-75 e.) >75

1.2 Sex

- a) Male b.) female

2) Presence of primary

- Yes No

If yes

3) Where is the site?

4) Mention the histologic type

5) Is there more than 1 primary

Yes

no

6) Is there any brain involvement?

- Yes No

6.1 If yes which part is involved?

a. cerebrum

b. cerebellum

c. brain stem

7) Number of lesion

- a) Solitary b) multiple

7.1 size of the lesion for solitary and the largest lesion for multiple

- a), 1 cm b) 1cm- 2.5 cm c) > or = 2.5 cm

8) Pattern of the lesion

a) Nodular

b) Solitary

- c) Cavitory
- d) Calcified
- e) Cystic
- f) Hemorrhagic
- g) Other

8.1 enhancement pattern a) solid enhancement b) Ring enhancing c) non enhancing

8.2 For solid enhancing a) Homogeneous b) Heterogeneous

8.3 Degree of enhancement a) Mild b) moderate c) Avid intense

8.3 For ring enhancement a) thin b) thick c) regular d) irregular

9) Perilesional edema yes, No

9.1 If yes A) Mild, B) Moderate, C) Extensive

10) Restriction diffusion a) yes b) no

Is there pathology examination/result from the involved lesion?

Yes, no

If yes mention the diagnosis.....

